

Phytotherapy in the Treatment of Chronic Generalized Periodontitis

Shukurova U. A., Gaffarova S. S., Kurbanova Z. F., Sattarov B. B.

Tashkent State Dental Institute, Uzbekistan, Department of Propaedeutics of Therapeutic Dentistry

ABSTRACT

Clinical evaluation of the effectiveness of the treatment in comparison groups revealed a significant improvement in the condition periodontal tissues based on the values of periodontal indices. Assessing the level of hygiene of patients, the degree of bleeding of the dentogingival sulcus, significantly lower values were obtained in patients of the group to whom Chlorophyllipt phytopreparations and the innovative homogeneous Laminalife gel were used sequentially and in combination.

KEYWORDS: *chronic generalized periodontitis of moderate severity, Laminalife, Chlorophyllipt, Silnes-Loe index, Mullemann index in Cowell's modification.*

The relevance of research. Today, one of the leading places among dental diseases is occupied by chronic generalized periodontitis (CGP), which is not only a medical, but also a social and economic problem [6,9]. In the scientific space of medicine, the problem of treating periodontal diseases is widely discussed due to almost 100% prevalence and poor response to the proposed treatment [1,4,6,8]. It is noted that the prevalence of signs of periodontal tissue damage depends on the region of residence, the age of patients, without having a downward trend [2,3,5]. Loss of teeth, which has arisen as a complication of periodontal disease, is detected several times more often than due to complications of dental caries.

Arsenal of drugs for local treatment of periodontal diseases improved, however, the relevance of further research, in particular, the task of further improving and increasing the effectiveness of the complex treatment of mass periodontal diseases by searching for new and modern methods of herbal medicine, the scientific justification for the feasibility of their use is still an urgent task for practical health care, since research conducted in this area will certainly help to identify optimal methods of using dosage forms from plant materials in the pre- and postoperative periods in patients with generalized periodontitis, as well as to ensure the effectiveness of local therapeutic measures, and subsequently to prevent the progression and recurrence of inflammatory processes in periodontal tissues [2,3,5,7,8].

Laminalife is a homogenized, chilled gel with an extract of the Far Eastern Laminaria Angusta and trepang. In addition, the composition includes: polysaccharides (Alginate, Laminaran, Fucoidan - up to 21%); polyunsaturated fatty acids Omega-3; mannitol (up to 35% dry residue); fructose (up to 4%); complex of vitamins (A, C, D, B1, B2, B3, B6, B12, E, K, PP); alginic acid (10-35% dry matter); fiber (6-14%); iodides and diiodotyrosine (2.7-3%); micro- and macroelements (iodine, sodium, phosphorus, magnesium, calcium and others (37 items in total); water (at least 85%) [2,3,9,10].

This therapeutic and prophylactic drug has an immunostimulating, detoxifying, antioxidant, regenerating, antiallergic, antiaggregant effect. Due to the diversity of the natural composition, so far they have not found a worthy application in periodontology, which determined the purpose and objectives of this study. Laminaria and trepang – thins the blood, dissolves blood clots and cholesterol plaques, strengthens the walls of blood vessels.

<https://cejsr.academicjournal.io>

Purpose of the study: Improving the effectiveness of local treatment of chronic generalized periodontitis of moderate severity through the complex use of Laminalife.

Materials and research methods. In the course of this study, 24 patients with a diagnosis of chronic generalized periodontitis of moderate severity (CHGPS) were examined and treated. The diagnosis was made in accordance with the Modified Classification of Periodontal Diseases (2001) [Yanushevich, O.O]. Depending on the prescribed treatment, all patients were divided by stratified randomization of 12 people into 2 groups, comparable in terms of age, sex and basic dental parameters. The control group consisted of 10 practically healthy people without clinical signs of CGPST, including 4 men and 6 women, the average age was 47.6 ± 2.38 years.

After obtaining voluntary informed consent and collecting general somatic and dental history, patients underwent a complete dental examination. Assessment of the clinical state of periodontal tissues was carried out with using hygienic and periodontal indicators: Silnes-Loe index (Silness J., Loe H., 1962); Mullemann index (Muhlemann H.R., 1971) modified by Cowell (Cowell I., 1975); depth of the periodontal pocket; to assess the degree of tooth mobility, the Miller scale modified by Frezar was used (Miller M., Fleszar P., 1980). In order to clarify the preliminary diagnosis, as well as to assess state of the bone tissue after treatment, an x-ray was performed examination, including an orthopantomogram, as well as an intraoral sighting radiograph according to indications.

The developed complex for the treatment of CGP: for example, the patients of the control group underwent traditional basic therapy: the removal of cash and subgingival dental deposits by mechanical and physical means. PZK curettage, tooth surface polishing, remineralizing therapy. PZK was irrigated with 0.05% solution of chlorhexidine bigluconate.

The patients of the second group, in addition to the traditional basic therapy, were irrigated with PZK with a 2% oil solution of Chlorophyllipt. From the 2nd visit, a medical bandage was applied to the area of the PZK Laminalife under a protective-fixing bandage for 5-7 days.

Patients of the third group, in addition to the traditional basic therapy, were irrigated with PZK with a 2% oil solution of Chlorophyllipt. From the 2nd visit, a medical bandage was applied to the area of the PZK Laminalife under a protective-fixing bandage for 5-7 days. From the first day, Laminalife was taken orally 30 minutes before meals, 1 tablespoon, 2 times a day for 10 days.

Statistical processing of the study results was carried out using the STATISTICA 10 program and the Excel data analysis package. At a significance level of $p < 0.05$, the differences between the groups were recognized as significant, at $p > 0.05$ they were not significant.

Results and discussions. When studying the anamnesis, it turned out that the duration of the disease, according to the patients, was 4.33 ± 1.66 years. The main complaints of patients with CGPST were bleeding gums (81%), the presence of tartar (53%), pain when brushing teeth and eating (35%), bad breath (25%). Less often, patients noted a decrease in the level of the gums (11%) and tooth mobility (17%).

Values of measured indicators of the clinical state of tissues periodontium, obtained during the examination before treatment, allow us to conclude that the oral hygiene of all patients is unsatisfactory and the need for its correction, as well as the inflammatory pathological process in periodontal tissues of moderate severity. The presence of a significant amount of soft and hard supra- and subgingival deposits is noted in almost all patients of the comparison groups, which indicates the need for correction of the clinical condition. All patients were given recommendations on individual oral hygiene, quality control of its implementation was carried out, and additional oral care products were selected. Treatment of CHPST in patients was carried out in several visits.

1 month after conservative therapy, all patients noted a significant improvement in the state of the oral cavity, expressed in a decrease in bleeding gums and bad breath. However, along with this, there

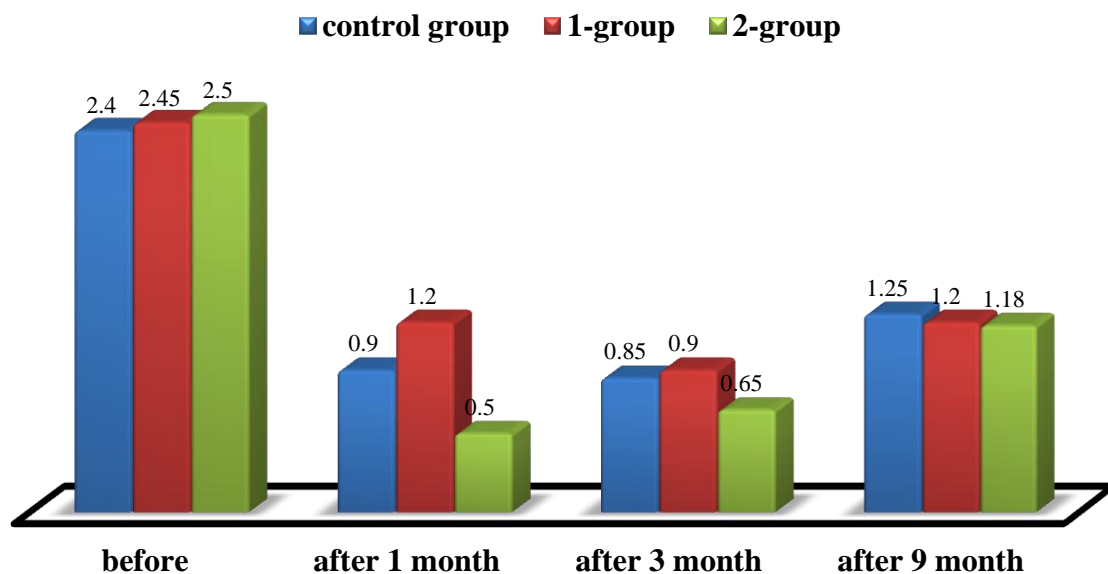
<https://cejsr.academicjournal.io>

were rarely complaints about the slight sensitivity of the teeth to temperature stimuli. When examining patients at different times after the conservative anti-inflammatory treatment, it is noted that the indicators of the state of the oral cavity of patients in all three groups improved statistically significantly compared to the indicators before treatment ($p < 0.001$). Note that this trend persists 6 months after treatment.

Assessing the change in the values of the determined Silnes-Loe plaque index, it is noted that this indicator 1 month after treatment statistically significantly decreased in patients of group 1 - by 45.5%, group 2 - by 80.0%, in the control group - by 66, 7% ($p < 0.001$).

3 months after treatment, there is a slight increase in values in groups 1 and control, while in group 2 the value is stable. The indicator of the presence and amount of plaque in all groups has a significant difference in comparison with the values before treatment, which in percentage terms is expressed in its decrease by 73.6% in group 2, by 65.4% in the control group ($p < 0.001$).

The value of the Silnes-Loe index as a result of the treatment after 9 months tends to increase, however, at this stage, it is statistically significantly lower than before treatment in patients of group 1 - by 45.5%, group 2 - by 53.6%, control - by 50.0% ($p < 0.001$) (Pict. 1).

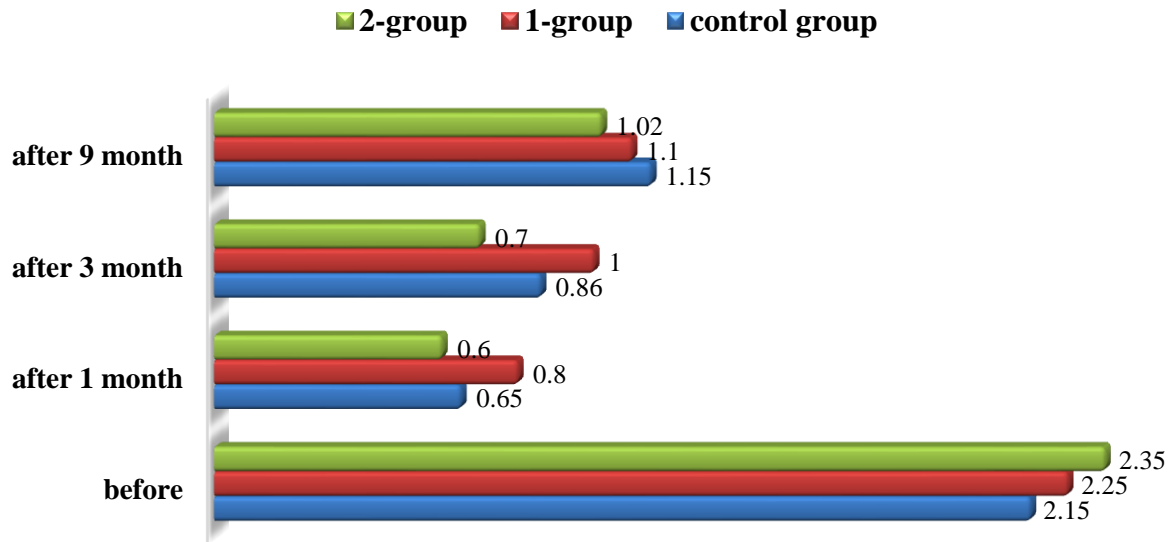


Pict. 1. Silnes-Loe index values before, after 1, 3 and 9 months.

Evaluating the results of measuring the Silnes-Loe plaque index, we have identified statistically significant differences in indicators at the stages before treatment and 1, 3 and 9 months after in all study groups. This indicates the effectiveness of conservative therapy in patients in each group.

Before treatment, the value of the Mullemann bleeding index corresponded to the indicators of the average degree of inflammation of the periodontal tissues. After the complex therapy, changes in the degree and duration of bleeding of the gingival sulcus are noted. Thus, 1 month after treatment in patients of the 1st group - decreased by 60.0%, in patients of the 2nd group - by 74.2%, in patients of the control group - by 69.7%, which has significant differences with indicators up to treatment ($p < 0.001$). An examination 9 months after treatment showed that the value of the Mullemann index was lower than before treatment by 42.9%. in patients of group 1, by 57.1% in patients of group 1 ($p < 0.001$) and by 46.8% in patients of the control group ($p < 0.05$). Based on the results obtained at different stages of the study after treatment, it can be argued that the degree of bleeding of the periodontal sulcus significantly decreased compared to the values before treatment, while the differences retain their statistical significance even 9 months after the treatment (Pict. 2).

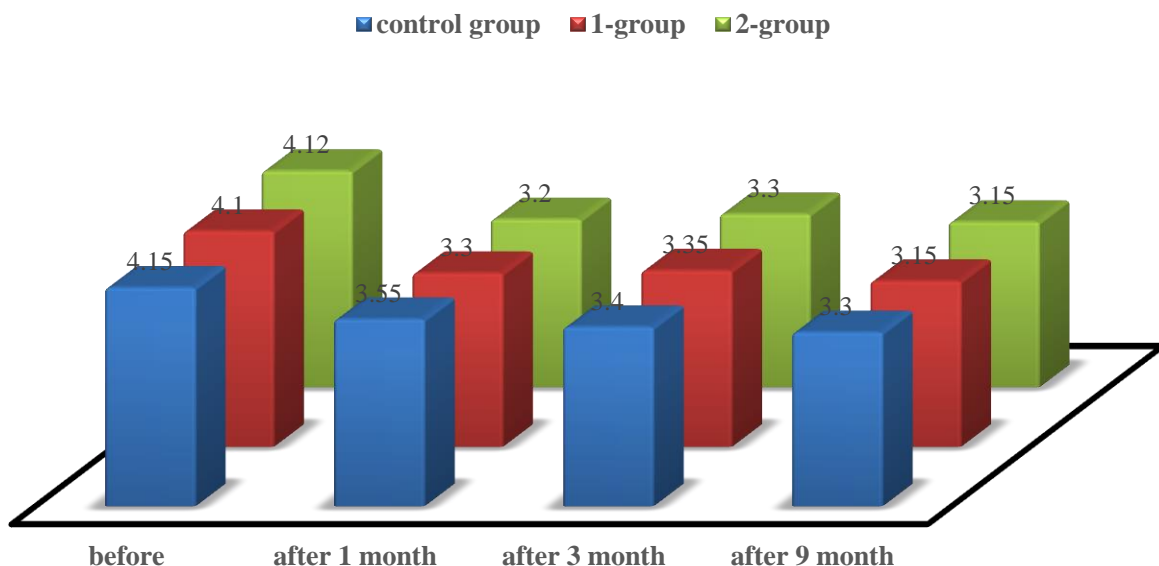
<https://cejsr.academicjournal.io>



Pict. 2. Indicators of the Mullemann bleeding index before, after 1, 3 and 9 months.

The effectiveness of the complex phytotherapy was also reflected in the values of the average depth of periodontal pockets. For a period of 1 month after conservative therapy, the average PC depth decreased relative to the initial values by 29.7% in group 1, by 27.6 and 32.6% in patients of group 1 and the control group, respectively, while the differences are statistically significant ($p < 0.001$). 3 months after the treatment, a relatively stable state of this indicator is observed in all study groups (Pict. 3).

When analyzing the results obtained in the course of a clinical study, it can be argued that the basic conservative therapy carried out using mechanical and physical removal of supra- and subgingival dental deposits, supplemented by irrigation of PC with a 2% Chlorophyllipt oil solution and a Laminalife therapeutic bandage under a protective-fixing bandage, as well as, taking Laminalife orally according to the scheme can have a pronounced positive effect on the condition of periodontal tissues.



Pict. 3. Indicators of the average depth of the PP before, after 1, 3 and 9 months.

<https://cejsr.academicjournal.io>

The results of a clinical study of patients in the control group also suggest a positive effect antiseptic 0.05% solution of chlorhexidine for hygiene and periodontal status of patients. However, in some cases, it was the consistent combined use of the used herbal remedies that showed statistically the best therapeutic efficacy according to the index indicators of periodontal tissues.

When performing an orthopantomogram, we found a decrease in the height of the interdental septa to ½ of the root of the tooth, bone resorption was up to 1/2 of the length of the root, a violation of the integrity of the cortical plate, destruction of the bone tissue of a mixed type and the presence of vertical bone defects.

An x-ray examination carried out after 9 months made it possible to identify signs characteristic of the chronic course of the process and the transition to remission. Namely: the absence of subgingival dental deposits, in most cases, the restoration of the integrity of the cortical plate throughout, a decrease in the width of the periodontal gap, the absence of a progressive decrease in the level of bone tissue.

Conclusions. Clinical evaluation of the effectiveness of the treatment in comparison groups revealed a significant improvement in the condition periodontal tissues based on the values of periodontal indices. Assessing the level of hygiene of patients, the degree of bleeding of the dentogingival sulcus, significantly lower values were obtained in patients of the group to whom Chlorophyllipt phytopreparations and the innovative homogeneous Laminalife gel were used sequentially and in combination ($p < 0.001$).

Bibliography

1. Boymirzaeva, Sh. (2021). The effectiveness of the use of "Alnident" in a comprehensive review of chronic generalized periodontitis. Actual problems of dentistry and maxillofacial surgery, 1 (01), 123-125.
2. Kamilov Kh., Takhirova K., Abduganiev U., Fozilova N. (2022). Methods for diagnosing inflammatory and destructive lesions of the periodontium. Actual problems of dentistry and maxillofacial surgery, (1), 59-61.
3. Bekzhanova O., Zaitkhanov A., Azizova Sh. (2022). Changes in periodontal tissues in complications of dental implantation. Actual problems of dentistry and maxillofacial surgery, (1), 242-243.
4. Shukurova Umida Abdurasulovna, and Sevara Sunnatulloevna Gafforova. "Influence of filling materials on the microbiocenosis of the oral cavity." (2020).
5. Abdulmejidova D. M. (2017). Risk factors for the development of periodontal disease in the adult population. Russian Dental Journal, 21(2), 72-75.
6. Makhmudov, M. M., & Satorov, S. (2017). Inflammatory diseases of the mucous membrane of the prosthetic bed in persons using dentures. Problems of Dentistry, (1), 75-78.
7. Fedortsev L. S., Gruzdev N. P., & Zafarov R. R. (2016). Modern methods of physiotherapy treatment. New Science: Current State and Ways of Development, (10-2), 27-33.
8. Shomurodova g. Kh., Yusupalikhodzhaeva s. Kh., & Mukhamedov i. M. (2022). Studying the sensitivity of oral microbes to drugs under in vitro conditions. Journal of biomedicine and practice, 7(2).
9. Abdurasulovna Sh. U., & Sunnatulloevna, g. S. Microbiological characteristics of the oral cavity after exposure of various filling materials. Process management and scientific developments, 146.
10. Yakhyoyeva M. Shukurova U.A. Comparative evaluation of the clinical efficacy of phytopreparations in the local treatment of chronic generalized periodontitis of moderate severity // Proceedings of IV International Scientific and Practical Conference "International scientific innovations in human life" Manchester, United Kingdom. 2021.