

We are IntechOpen, the world's leading publisher of Open Access books Built by scientists, for scientists

6,200

Open access books available

168,000

International authors and editors

185M

Downloads

Our authors are among the

154

Countries delivered to

TOP 1%

most cited scientists

12.2%

Contributors from top 500 universities



WEB OF SCIENCE™

Selection of our books indexed in the Book Citation Index
in Web of Science™ Core Collection (BKCI)

Interested in publishing with us?
Contact book.department@intechopen.com

Numbers displayed above are based on latest data collected.
For more information visit www.intechopen.com



Chapter

Outpatient Management of Chronic Pain

Franzes Anne Z. Liongson, Rina Bhalodi, Christopher McCarthy, Sanjay V. Menghani and Ajaz Siddiqui

Abstract

In this chapter, we provide an overview of the most current techniques in the evaluation, diagnosis, and treatment of pain in the outpatient setting. We performed a targeted literature review by searching for the terms such as “chronic pain” and “pain management.” Relevant articles were cited, and findings were described in the chapter text. Additionally, we supplemented our review with images from the Spine and Pain Associates’ offices at St. Luke’s University Health Network (SLUHN) in Bethlehem, PA, as well as medical illustrations by our authors. We begin the review with a description of pain—its definition, components, complexity, and classifications and then provide a stepwise outline of the pharmacologic approach beyond nonsteroidal anti-inflammatory drugs before delving into newer interventional pain management procedures. Subsequently, this chapter is not comprehensive as it does not provide extensive discussion on older, more established procedures such as epidural steroid injections as well as practices falling out of favor such as discograms and neurolysis. Instead, we focus on newer subacute to chronic nonmalignant pain interventions. Finally, we attempt to highlight future directions of the growing field. Overall, we provide an overview of the management of chronic by providing insights into updates to chronic pain management.

Keywords: chronic pain, interventional pain, outpatient medicine, opioids, narcotics

1. Introduction

Pain is a complicated, subjective sensation that results from physical stimuli as well as psychological factors. Pain can vary in location, severity, quality, and consistency. It can occur in response to either physical injury or emotional distress. While there are multiple definitions that have been proposed, the most widely accepted definition of pain, as described by Cohen *et al.* in 2018 is “an unpleasant sensory and emotional experience associated with actual or potential tissue damage or described in terms of such damage” [1].

The pain response is generated by the propagation of nociceptive signals by neurons in the central nervous system (CNS) and peripheral nervous system (PNS) in response to noxious stimuli. Fundamentally, the mechanism of pain comprises detection of noxious stimuli, transduction of noxious stimuli into electrochemical signals, transmission of the electrical signals by neuronal pathways, and modulation through the nervous system

to produce the sensation of pain. This process is facilitated by the axons, also known as nerve fibers, which propagate the nociceptive signals to the central nervous system [2].

Pain begins with detection of primary noxious stimuli. Research shows that Transient Receptor Potential (TRP) superfamily of ion channels play a vital role in the detection of pain [3]. Following detection, signals are sent along axons of sensory neurons toward the CNS. The nerve fiber types recognized to play a major role in pain include A δ and C fibers, two types of primary afferent (sensory) nociceptors. Type A δ fibers are myelinated nerve fibers with fast conduction speeds that are activated by thermal and mechanical stimuli. They are associated with prickling pain of short duration. Type C fibers are unmyelinated nerve fibers with slow conduction speeds that are activated by thermal, mechanical, and chemical stimuli. They are associated with poorly localized, dull pain. Some C-fibers may also be peptidergic, which means that they express neuropeptides such as substance P (SP), neurokinins, and calcitonin gene-related peptide (CGRP) [4]. There is association between specific TRP channels and specific types of nerve fibers; for example, TRPV1, which is the receptor for capsaicin is associated with sensory neurons having Type C fiber axons [5]. Alternatively, TRPM8, which responds to cold sensation and menthol, is associated with sensory neurons that have A δ and C fibers [6]. Nerve fibers carry the action potential, an electrochemical signal generated in response to the detected noxious stimuli.

The action potential generated by nociceptors in response to noxious stimuli is transmitted between neurons and culminates with the release of neurotransmitters. Common neurotransmitters and their effects on pain are listed in **Table 1**.

Neurotransmitter	Neurotransmitter Levels in Pain
Prostaglandins (PGE ₂ , PGI ₂)	↑
Leukotriene B ₄ (LTB ₄),	↑
Nerve Growth Factor (NGF)	↑
Bradykinin (BK)	↑
Adenosine Triphosphate (ATP)	↑
Adenosine	↓, However some evidence suggests prolonged increase in adenosine contributes to chronic pain
Tachykinins (Substance P (SP), Neurokinin A (NKA), and Neurokinin B (NKB))	↑
5-Hydroxytryptamine (5-HT)	Generally ↓ but also ↑ at times
Histamine	↓
Glutamate	↑
Norepinephrine (NE)	↑
Nitric Oxide (NO)	↑ or ↓
Calcitonin Gene-Related Peptide (CGRP)	↑
Gamma-aminobutyric acid (GABA)	↓
Opioid Peptides	↓
Glycine	↓
Cannabinoids	↓

Table 1.
Neurotransmitters and their effects on pain.

Neurotransmitters that act as inflammatory mediators include prostaglandins (PGE₂, PGI₂), leukotriene B₄ (LTB₄), nerve growth factor (NGF), bradykinin (BK), adenosine triphosphate (ATP), adenosine, tachykinins (substance P (SP), neurokinin A (NKA), and neurokinin B (NKB)), 5-hydroxytryptamine (5-HT), histamine, glutamate, norepinephrine (NE), and nitric oxide (NO). Neurotransmitters acting as non-inflammatory mediators include calcitonin gene-related peptide (CGRP), gamma-aminobutyric acid (GABA), opioid peptides, glycine, and cannabinoids [7]. These various neurotransmitters are involved with pain transduction, transmission, and modulation, thus facilitating the mechanism of pain [8, 9].

2. Classification of pain

2.1 Acute versus chronic pain

Pain is classified as either acute or chronic. Acute pain begins suddenly, often due to an injury to the body. It can be caused by, but not limited to, broken bones, burns, sprains, wounds, falls, and medical procedures. Acute pain is not a disease and better classified as a symptom that indicates an inflammatory process that brings attention to tissue damage. Acute pain may affect more than the injured part of the body and can be debilitating due to loss of function, fatigue, or sleep deprivation. Generally, acute pain resolves within 3 months as the body heals. Acute pain can often be treated with the application of ice, analgesics, immobilization, and support bandages.

Acute pain can become chronic pain. Chronic pain is ongoing pain that lasts for more than 6 months and is usually much harder to diagnose and treat than acute pain. Chronic pain occurs when the physical condition causing acute pain remains unresolved in cases such as cancer or arthritis. Chronic pain also occurs when the nervous system is damaged or malfunctions, sending pain signals to the brain without a specific cause. In 2012, the Journal of Pain estimated that the cost of chronic pain was around \$600 billion dollars when taking healthcare costs and lowered productivity into account [10]. In 2019, the National Institute for Health Services found that more than 50% of Americans were experiencing chronic pain, and back pain was the lead contributor at 39% [11–13]. Common causes of chronic pain include joint pain due to degenerative damage and overuse, migraines, neuropathic pain, and cancer. More in-depth discussion of chronic pain conditions and treatment options is in the following section of this chapter and summarized in **Table 2**.

2.2 Nociceptive versus neuropathic pain

The two most common types of pain are nociceptive pain and neuropathic pain. Nociceptive pain is caused by tissue damage or injury to the skin, bones, muscles, or joints. Examples include pain from a broken arm, a sprained ankle, a puncture wound, or a fall.

Neuropathic pain (commonly described as “pins and needles”) is a numbing or shooting pain that results from damage to the nerves. Common causes of nerve damage resulting in neuropathic pain include uncontrolled diabetes, infections, surgical procedures, radiation treatments, and physical trauma.

Condition	Management
Complex regional pain syndrome (CRPS)	Spontaneous resolution in early or mild cases Physical therapy, psychotherapy, medications (acetaminophen, NSAIDS, and topical anesthetics) Alternative treatments: nortriptyline, gabapentin, pregabalin, amitriptyline, duloxetine, corticosteroids (e.g. prednisolone, methylprednisolone) Severe cases: opioids (e.g. oxycodone, morphine, hydrocodone and fentanyl)
Arthritis	Physical therapy, exercise Symptom management: NSAIDS (ibuprofen, naproxen sodium), Acetaminophen, Counterirritant ointments, Corticosteroids (e.g. prednisone)
Fibromyalgia	Over the counter (OTC) pain relievers (acetaminophen, ibuprofen, naproxen sodium) Antidepressants (Duloxetine (Cymbalta), milnacipran (Savella), Amitriptyline) Anti-seizure drugs, cyclobenzaprine, gabapentin, Pregabalin (Lyrica) Aerobic exercise, muscle strengthening exercises, stress management techniques (meditation, yoga, and massage, sleep hygiene), cognitive behavioral therapy (CBT)
Cancer Pain	Non-opioid medications (e.g. paracetamol, dipyron, non-steroidal anti-inflammatory drugs, COX-2 inhibitors) Refractory pain: opioids (first: codeine, dextropropoxyphene, dihydrocodeine, tramadol, if pain is still uncontrolled: consider morphine, oxycodone, buprenorphine) Alternative options: Antidepressants, Anti-seizure drugs, Steroids; Other: Physical therapy, Nerve block, Acupuncture, Massage, Relaxation exercises, Meditation, Hypnosis
Chronic Pelvic Pain Syndrome	Physical therapy Hormone medications for pain associated with the menstrual cycle or hormonal changes Antibiotics for pain associated with infections Antidepressant medications (tricyclic antidepressants [TCAs]: amitriptyline, nortriptyline); Neurostimulation; Trigger point injections; Psychotherapy

Table 2.
Chronic pain conditions and treatment options.

3. Chronic pain conditions and their conservative management

3.1 Complex regional pain syndrome

Complex regional pain syndrome (CRPS) is broadly defined as prolonged and excess inflammation and pain following an injury. CRPS has both acute and chronic forms. CRPS is characterized by spontaneous or excessive pain following mild touch or allodynia. Other symptoms include changes in skin temperature, color and swelling. CRPS usually improves over time and severe and prolonged cases are rare but profoundly disabling. Most CRPS is caused by improper function of the peripheral C-fiber nerves. Excess firing of these nerve fibers sends pain messages to the brain and triggers inflammation. Injuries in CRPS typically are subtle and may go unnoticed.

Early or mild cases of CRPS generally resolve on their own. Primary treatments include physical therapy, psychotherapy, and medications. Several classes of medications have been reported as effective for CRPS, but none are FDA approved. Medications include acetaminophen, NSAIDS, and topical anesthetics. Drugs used for other neuropathic pain conditions (discussed in further detail in subsequent sections

of this chapter) such as nortriptyline, gabapentin, pregabalin, amitriptyline, and duloxetine have also been shown to be effective. Corticosteroids such as prednisolone and methylprednisolone can be used to treat inflammation, swelling, and edema. Opioids such as oxycodone, morphine, hydrocodone and fentanyl may be required for the most severe cases.

3.2 Arthritis

Arthritis is the swelling and tenderness of one or more joints. The main symptoms of arthritis are joint pain and stiffness, swelling, and decreased range of motion that typically worsens with age. The most common types of arthritis are osteoarthritis and rheumatoid arthritis. While osteoarthritis causes breakdown of cartilage, rheumatoid arthritis is a disease where the immune system attacks the lining of the joints. Treatments vary depending on the type of arthritis and focus on reducing symptoms and improving quality of life. Arthritis is usually diagnosed by physical examination. Analysis of body fluids can identify the type of arthritis. Imaging such as X-rays, CT, and MRI can detect problems within the joint causing symptoms.

Arthritis treatment focuses on relieving pain and improving joint function. The medications used to treat arthritis depend on the type of arthritis. NSAIDs such as ibuprofen and naproxen sodium can relieve pain and inflammation. Acetaminophen has been shown not to be as effective as NSAIDs for arthritis pain. Counterirritant ointments applied over the aching joint may interfere with the transmission of pain from the joint. Corticosteroid medications such as prednisone will reduce inflammation and pain and slow joint damage. Exercise can improve the range of motion, strengthen muscles, and reduce pain.

3.3 Fibromyalgia

Fibromyalgia is characterized by widespread musculoskeletal pain, cognitive difficulties, tenderness, fatigue, numbness or tingling in the arms and legs, heightened sensitivity, sleep disturbances, and emotional and mental distress. Newer guidelines from the American College of Rheumatology require the main factor for diagnosis to be widespread pain throughout the body for at least 3 months. Fibromyalgia affects about 2% of the adult population. Symptoms often begin after a physical trauma or psychological stress. Women are more likely than men to develop fibromyalgia. Fibromyalgia coexists with tension headaches, chronic fatigue syndrome, TMJ, irritable bowel syndrome, postural tachycardia syndrome, depression, and anxiety. The pain, fatigue, and poor sleep quality can interfere with function at home and at work.

The cause of fibromyalgia is unknown; however, many researchers believe that fibromyalgia amplifies painful sensations by affecting the way the brain and spinal cord process signals. This involves the increase in levels of certain chemicals in the brain that signal pain. The brain pain receptors become sensitized and overreact to painful and non-painful signals. Risk factors include sex, genetics, infections, and physical or emotional trauma. Patients with arthritis and lupus are more likely to develop fibromyalgia.

Fibromyalgia is treated with both medications and lifestyle strategies. The main focus of treatment is to reduce pain and improve the quality of life. Common medications to reduce pain include pain relievers, antidepressants, and anti-seizure drugs. Over-the-counter (OTC) pain relievers such as acetaminophen, ibuprofen, or naproxen sodium may be helpful. Opioid medications are not recommended due to significant

side effects and addiction and may worsen pain over time. Duloxetine (Cymbalta) and milnacipran (Savella) are FDA approved for treating fibromyalgia and may ease pain and fatigue associated with fibromyalgia. Amitriptyline or the muscle relaxant cyclobenzaprine may be prescribed to promote sleep. The epilepsy drug gabapentin is sometimes used to reduce fibromyalgia symptoms. Pregabalin (Lyrica) is used to treat nerve pain and is FDA approved for treating pain caused by fibromyalgia.

Lifestyle changes include aerobic exercise and muscle strengthening exercises, stress management techniques such as meditation, yoga, and massage, sleep habits to improve the quality of sleep, and cognitive behavioral therapy (CBT) to treat underlying depression.

3.4 Cancer pain

Cancer pain is often caused by cancer compressing on or infiltrating a part of the body, diagnostic procedures, or treatments or from skin, nerve, or other tissue damage caused by hormone imbalance or immune response. Tumors cause pain by crushing or infiltrating tissue, triggering inflammation or infection, or releasing chemicals that stimulate pain. Invasion of the bone by cancer is the most common source of cancer pain. When tumors compress, invade, or inflame parts of the nervous system, they can cause pain. Chronic pain may be continuous or intermittent. Despite pain being adequately controlled by long-acting drugs, breakthrough pain may occasionally occur and is treated with fast-acting analgesics. The presence of cancer pain depends on the location and stage of the cancer. About half of the patients diagnosed with cancer are in pain at a given time and two-thirds of patients with advanced cancer experience debilitating pain. Cancer pain can be either eliminated or adequately controlled in about 80–90% of the cases. Unfortunately, nearly 50% of cancer patients receive suboptimal pain care.

Cancer pain treatment aims to relieve pain with minimal side effects. WHO guidelines recommend prompt administration of drugs when cancer pain occurs. Non-opioid medications such as paracetamol, dipyron, non-steroidal anti-inflammatory drugs, or COX-2 inhibitors should be administered when pain is not severe. Refractory cancer pain may require more aggressive treatment with mild opioids such as codeine, dextropropoxyphene, dihydrocodeine, or tramadol. Mild opioids are replaced by stronger opioids such as morphine if pain control is still not adequate. More than half of patients with advanced cancer and pain will require strong opioids. Morphine is effective at relieving cancer pain although oxycodone shows superior tolerability and analgesic effect. Side effects of nausea and constipation are rarely severe enough to cause stopping treatment. Sedation and cognitive impairment usually occur with the initial dose and increase with the strength of the opioid. There is some evidence that buprenorphine is another opioid with some evidence of analgesic effect. Other medicines that can also relieve pain, including antidepressants, anti-seizure drugs, and steroids. A nerve block procedure can be used to stop pain signals from being sent to the brain. In this procedure, a numbing medicine is injected around or into a nerve. Pain relief may also be enhanced through acupuncture, massage, physical therapy, relaxation exercises, meditation, and hypnosis.

3.5 Chronic pelvic pain syndrome

Chronic pelvic pain occurs in the abdomen, genital area, lower back, or thighs and lasts more than 6 months. The pain may become worse when urinating, having

intercourse, walking, or during menstrual periods. Chronic pelvic pain is often caused by irritable bowel syndrome, interstitial cystitis, pelvic floor dysfunction, endometriosis, pelvic injury, and ovarian cysts. Determining the cause of chronic pelvic pain often involves a process of elimination as many different disorders can result in pelvic pain. Pelvic exam can reveal signs of infection, abnormal growths, or tense pelvic floor muscles. Blood and urine tests can check for infections. Ultrasound is useful for detecting masses or cysts in the ovaries, uterus, and fallopian tubes. X-ray, CT scans, and MRI can detect abnormal structure and growths. Laparoscopy allows for a view of pelvic organs to check for abnormal tissues or signs of infection.

There are several treatments depending on the cause of pelvic pain. Hormone medications may relieve pelvic pain that coincides with a particular phase of the menstrual cycle and the hormonal changes that control ovulation and menstruation. Antibiotics can be prescribed for infections that are a source of pelvic pain. Antidepressant medications can be effective for chronic pelvic pain. TCAs such as amitriptyline and nortriptyline have been shown to relieve chronic pelvic pain even in the absence of depression. Physical therapy, neurostimulation, trigger point injections, and psychotherapy can also be an effective part of the treatment plan.

4. Traditional pharmacologic approaches to pain

4.1 Opioids

According to the 2016 CDC Guideline for Prescribing Opioids for Chronic Pain, nonopioids are preferred to opioids for the treatment of chronic pain [14]. If pain cannot be adequately controlled with OTC medications, opioid therapy may be recommended for a limited time. The decision to initiate opioid therapy for the treatment of pain is challenging and should only be made after a thorough assessment has been performed to ascertain the complete nature of the pain, comorbid patient conditions, and pain treatments that have been trialed in the past. Opioids should be prescribed alongside both non-opioid medications and non-pharmacologic treatments and should be closely monitored as prolonged use is not recommended due to risks of addiction, tolerance, and misuse [15].

More than 191 million opioid prescriptions were dispensed to Americans in 2017. Thus, it is important to screen patients for mental illness and substance use disorders that would place them at increased risk for overdose. In an effort to reduce the risk of opioid addiction and misuse, medical societies including the CDC recommend utilizing risk reduction strategies, including written pain agreements prior to starting opioid treatment for chronic pain. These agreements provide opportunities to establish pain goals, discuss the risks and benefits of opioid therapy, and clearly outline the treatment plan that will be utilized to monitor and guide opioid use.

Opioids, sometimes referred to as narcotics, are strong painkillers derived from the opium poppy plant and are used to block pain signals between the brain and the body, providing immediate relief to intense pain by altering the brain's perception of pain. They may be prescribed for low back pain, neuropathic pain, or arthritis pain [14, 16]. Opioids act primarily by binding to the μ -opioid receptor (MOR) on the cell membrane of neurons. Respiratory depression is one of the most dangerous risks associated with opioids and in severe cases can cause apnea. The risk is higher if patients have underlying respiratory conditions such as asthma or sleep apnea. Constipation is also a common side effect associated with chronic opioid use.

Popular examples of opioids include hydrocodone, hydromorphone, methadone, fentanyl, meperidine, morphine, tramadol, and oxycodone. The most common drugs involved in prescription opioid overdose deaths include methadone, oxycodone, and hydrocodone. A recent study showed that 67% of patients who require opioid-based medications were also receiving one or more other prescription drugs. Adverse drug interaction events can be linked to polypharmacy. A recent analysis among chronic back pain patients on long-term opioid analgesics reported that the overall prevalence of drug–drug interactions (DDIs) was 27% [17].

There are numerous drugs that can interact with opioid medications. Several opioids (including codeine, oxycodone, hydrocodone, fentanyl, tramadol, and methadone) are metabolized by the cytochrome P450 (CYP450) system and are associated with DDIs that either reduce opioid efficacy or exacerbate side effects. Morphine, oxymorphone, and hydromorphone are not metabolized by the CYP450 system and are generally involved in fewer DDIs. When prescribing opioids, it is important to remember that they can exacerbate sedation and respiratory when utilized alongside alcohol, anxiolytics, and hypnotics. Opioids can also interact with certain antibiotics, antidepressants, anti-seizure medications, antifungals, and antiretrovirals.

Tramadol is a commonly prescribed opioid that has analgesic properties as well as alternative mechanisms of action. Tramadol is found as a racemic mixture of two enantiomers that have synergistic effects: one enantiomer works as a selective μ agonist and inhibits serotonin reuptake, while the other enantiomer inhibits serotonin and norepinephrine reuptake [18]. Tramadol and its active metabolite (M1) inhibit ascending pain pathways by binding to μ receptors in the central nervous system [18]. Inhibition of reuptake of serotonin and norepinephrine by tramadol and M1 inhibit descending pain pathways to aid in pain relief [18]. It is important to take into consideration that the side effects of tramadol include seizures, NMS, and serotonin syndrome.

Buprenorphine offers a safer alternative for patients who require opioids to manage chronic pain, given the unique pharmacological properties that allow it to provide adequate analgesia with less abuse potential. As a long-acting partial μ receptor agonist and κ receptor antagonist, it leads to analgesia. High dose administration of buprenorphine leads to μ receptor antagonism, achieving the opposite effect. Combination of buprenorphine and naloxone, the pure μ receptor antagonist, is available as Suboxone [18]. The combinatory effects of Suboxone are designed to prevent illicit intravenous use.

4.2 Non-opioid options for pain

There are several well-known and well-utilized non-opioid approaches to pain management beyond non-steroidal anti-inflammatory drugs (NSAIDs) and acetaminophen. Several examples include topical anesthetics, counterirritants, corticosteroids, muscle relaxants, anti-depressants, and anti-seizure medications. **Table 3** provides an overview of pharmacologic approaches and common side effects of each approach.

Topical anesthetics are valuable options in pain management as they achieve relief with a low risk of side effects and drug interactions. There are many formulations available such as creams, ointments, gels, lotions, and patches. Lidocaine 5% patch (Lidoderm) is also FDA approved for the treatment of postherpetic neuralgia. In addition to topical anesthetics, counterirritants (including salicylates, capsaicin, and menthol) can be utilized to provide local and temporary irritation that distracts and interrupts pain signals to the brain. Capsaicin, in the form of Qutenza, is FDA approved for the treatment of pain associated with postherpetic neuralgia.

Drug Class	Examples	Common Side Effects
Anti-seizure Medications	gabapentin, pregabalin	Sedation, dizziness, dry mouth, peripheral edema
Tricyclic Antidepressants (TCAs)	amitriptyline, nortriptyline	Dizziness, dry mouth, blurred vision, nausea, weight gain, constipation
Counterirritants	capsaicin, menthol, salicylates	Local skin irritation
SNRIs	duloxetine, venlafaxine	Diarrhea, nausea, dry mouth, chills
Muscle Relaxants	baclofen, carisoprodol, chlorzoxazone, methocarbamol, tizanidine	Sedation, dizziness, hypotension, nausea, constipation
Steroids	dexamethasone, prednisone	Acne, blurred vision, nausea, insomnia
Opioids	buprenorphine, codeine, fentanyl, hydrocodone, hydromorphone, meperidine, methadone, morphine, oxycodone, oxymorphone, tramadol	Sedation, dry mouth, constipation, nausea
Topical Anesthetics	creams, ointments, gels, lotions, and patches; lidocaine patch	Local skin irritation, bruising

Table 3.
 Common pharmacologic approaches to pain management with examples and common side effects.

Steroids are powerful anti-inflammatory medications that can be taken orally or injected. Corticosteroids are used to treat migraines, osteoarthritis, rheumatoid arthritis, and low back pain. Prednisone (Deltasone) and Decadron (Dexamethasone) are examples of corticosteroids.

Muscle relaxants are used to reduce aches and pains associated with muscle strains, sprains, or spasms by relaxing tight muscles and improving the quality of sleep. Muscle relaxants are not typically recommended for treating chronic pain, but they may help with fibromyalgia and low back pain symptoms. Examples of muscle relaxants include baclofen, tizanidine, chlorzoxazone, methocarbamol, and carisoprodol.

Tricyclic antidepressants (TCAs) and serotonin norepinephrine reuptake inhibitors (SNRIs) have been shown to be effective for treating chronic pain through their interactions with norepinephrine. SNRIs are the preferred treatment for neuropathic pain as they are generally better tolerated by patients than TCAs. The most commonly utilized SNRI for chronic pain is duloxetine (Cymbalta), which is FDA approved for treating fibromyalgia as well as diabetic neuropathy. SNRIs have a delayed onset of maximal effect and patients may have to wait weeks before achieving best results. Common side effects include diarrhea, nausea, dry mouth, and dizziness.

TCAs remain inexpensive options for treatment of depression as well as for pain control. The dose utilized for pain control is typically lower than the dose utilized

for antidepressant treatment. Commonly utilized TCAs for pain are amitriptyline (Elavil) as well as nortriptyline (Pamelor). Common side effects include dry mouth, dizziness, weight gain, and constipation.

In patients on serotonergic drugs, a rare, but potentially life-threatening condition known as serotonin syndrome can occur when excess serotonin builds up in the body (this can occur if two serotonergic medications are taken concurrently or if an excess of a serotonergic drug is consumed). Symptoms of serotonin syndrome can vary from mild symptoms including diarrhea and nausea to severe symptoms including fever, seizures, and hyperreflexia.

Anti-seizure medications treat chronic neuropathic pain by reducing overactive pain signals from damaged nerves. Examples of anti-seizure medications include pregabalin (Lyrica) and gabapentin (Neurontin). Gabapentin and pregabalin are both FDA approved for postherpetic neuralgia and pregabalin is also FDA approved for diabetic neuropathy and fibromyalgia. Side effects of gabapentin and pregabalin include weight gain, fluid buildup, sleepiness, and drowsiness. Gabapentin and pregabalin cannot be stopped abruptly; they must be withdrawn gradually to minimize withdrawal symptoms such as confusion, delusions, agitation, and sweating.

5. Novel pharmacologic approaches to chronic pain

5.1 Ketamine

Ketamine, a noncompetitive N-methyl-D-aspartate (NMDA) receptor antagonist originally labeled as CI-581, is a phencyclidine derivative that has been in clinical use since its FDA approval in 1970 after which it became recognized for its ability to safely induce short-term anesthesia and analgesia. Its use was limited in clinical practice because of its psychodysleptic, hallucinatory, effects. Recently, ketamine has become the subject of research interest and began to be used in acute, chronic, and cancer pain management [19]. Its potential to be a future pharmacologic treatment option for conditions ranging from major depressive disorder and addiction to asthma and cancer growth is also being studied [20].

Ketamine noncompetitively binds to the ligand-gated NMDA receptors in the central nervous system, particularly in the prefrontal cortex and hippocampus, which results in decreased channel opening frequency and duration. Since activation of the NMDA receptor is believed to play a major role in chronic pain, the effect of ketamine on the NMDA receptor in combination with its effects on non-NMDA pathways involved in pain regulation is believed to be responsible for its analgesic properties [21]. Non-NMDA pathways thought to be associated with the analgesic properties of ketamine include the nicotinic and muscarinic cholinergic receptor antagonism, sodium and potassium channel blockade, high-affinity D2 dopamine receptor and L-type voltage-gated calcium channel activation, GABA-A signaling, and descending modulatory pathway enhancement [22].

The increased use of intravenous ketamine infusions for chronic pain treatment in recent decades motivated the development of consensus guidelines in 2016 by the American Society of Regional Anesthesia and Pain Medicine, the American Academy of Pain Medicine, and the American Society of Anesthesiologists [23, 24]. The results of studies on efficacy of ketamine for chronic neuropathic pain and nociceptive pain are promising although results of the nociceptive pain studies are mixed. A meta-analysis of 211 patients from

seven studies showed IV ketamine infusions demonstrated analgesia compared to placebo [19, 25]. In this study, the average infusion duration was 5 hours with a median ketamine dose of 0.35 mg/kg, with maximum effect observed between 48 hours and 2 weeks after infusion [25].

Although many pain clinics may administer ketamine intravenously, clinical regimens may encompass either continuous infusion or involve a bolus dose. The most common continuous IV ketamine infusion dose is from 2.0 to 5.0 mcg/kg/min. In some clinics, that continuous infusion dose may be preceded by an IV ketamine bolus of 0.5–1.0 mg/kg [26]. Ketamine infusion time is typically from 30 to 60 minutes in duration for one treatment. In some cases, the infusion duration may be up to 2 hours. The ketamine infusion treatment series generally consists of a total of four to six treatments that are administered two to three times per week, with the number of treatments increased if the patient does not demonstrate adequate response. Adverse effects of ketamine include increased secretions, bronchodilation, hallucinations, visual disturbances, unpleasant dreams, dysphoria, hepatotoxicity, and cystitis. See **Table 4** for a summary of this discussion.

5.2 Cannabis/CBD

Cannabis, also known as hemp, is derived from a genus of flowering plant strains that produce active ingredients such as tetrahydrocannabinol (THC) and cannabidiol (CBD). The mechanism of action of THC comprises activation of cannabinoid receptor type 1 (CB1 receptor) and cannabinoid receptor type 2 (CB2 receptor) [27]. CB1 receptor expression is in the central and peripheral nervous system, while CB2 receptor expression is primarily in the periphery, mostly in cell types involved in immunity, hematopoietic cells, and glia cells [27]. These receptors result in both the analgesic and the psychotropic effects of cannabis [27]. CBD has demonstrated a negative allosteric effect on CB1 receptors and positive modulatory effects on the endocannabinoid system, which results in reduction of psychotropic effects from THC and potentiates the anticonvulsant and analgesic effects when administered concomitantly. Unlike THC, CBD is not psychotropic.

Although plant strains from which cannabis is derived have been grown for at least 12,000 years and there has been evidence of medicine use by Chinese emperors in 2700 BC, cannabis is still considered an investigational drug. Nabilone and dronabinol are synthetic derivatives of THC that are approved by the FDA for treating nausea and vomiting associated with chemotherapy. Clinical trials demonstrate potential for treatment of nausea and vomiting resulting from chemotherapy, appetite stimulation, chronic pain, and muscle spasms [27, 28]. Routes of administration for cannabis and its derivatives include inhalation via smoking, ingestion, rectal, sublingual, transdermal, ocular, and intravenous [28].

Adverse effects of short-term use of cannabis include impairments in memory, motor coordination, and judgment. At higher doses, cannabis can also result in paranoia and psychosis. Long-term use of use of large quantities of marijuana can lead to addiction, cognitive impairments, chronic bronchitis (if use is via inhalation or smoking), and increased risk of chronic psychotic disorders such as schizophrenia in individuals with a high predisposition [28, 29]. There is also evidence that THC and CBD, the active components of cannabis, act on cytochrome P450 isozymes to influence the metabolism of substances, with THC being an inducer of CYP1A2 and CBD being an inhibitor of CYP3A4 and CYP2D6 [30]. **Table 4** provides a summary of this discussion.

5.3 Infusion therapy

Infusion of IV lidocaine is a modality that can be considered. IV lidocaine is primarily indicated for treatment-resistant peripheral neuropathy [31].

Lidocaine, when used as a local anesthetic, blocks sodium-gated channels, which desensitize peripheral nociceptors. When used as an infusion, IV route, the lower dose blocks the sodium channels of the central nervous system (CNS), mainly affecting the spinal cord and dorsal root ganglia (DRG). Additionally, lidocaine can also affect potassium-gated channels at the DRG; hyperpolarization cyclic nucleotides channels (HCN); and N-methyl-D-aspartate, (NMDA). The effect on the potassium-gated channels and HCN can contribute to spinal anesthesia. Lidocaine also has anti-inflammatory properties as it decreases cytokines and increases acetylcholine in the CSF, which inhibits spinal pain pathway.

IV lidocaine dosing varies; however, per a recent systematic review, pain clinics have dosed in the following: weight-based of 1–2-mg/kg bolus, a fixed-bolus dose of 50–100 mg, and a 1-mg/kg/hour continuous infusion. Notably, there is also no standard for duration of administration, and serum monitoring is not common practice [32].

Though not an absolute contraindication, careful dosing in patients with cardiac or hepatic failure is essential. The volume of distribution is smaller and the half-life is shorter in the former and the volume of distribution is larger and the half-life is longer in the latter [33]. Other possible complications include headaches, tinnitus, nausea, lightheadedness, paresthesia, hypotension, arrhythmia, respiratory depression, and cardiac arrest [31]. **Table 4** provides a summary of this discussion.

Agent	Dosing	Benefits	Common side effects
Ketamine	continuous IV: 2.0 to 5.0 mcg/kg/min IV bolus: 0.5 to 1.0 mg/kg	chronic neuropathic pain, nociceptive pain	Increased secretions, bronchodilation, hallucinations, visual disturbances, unpleasant dreams, dysphoria, hepatotoxicity, cystitis
Cannabis/ CBD	mild effect: 1.0–2.5 mg moderate effect: 2.5–15 mg maximum: 40 mg/ day	nausea and vomiting resulting from chemotherapy, appetite stimulation, chronic pain, muscle spasms	Impaired memory, impaired motor coordination, impaired judgment, paranoia, psychosis
Lidocaine	continuous IV: 1.0 mg/kg/hour weight-based bolus: 1.0 to 2.0 mg/kg bolus fixed bolus: 50–100 mg	treatment-resistant peripheral neuropathy	Headaches, tinnitus, nausea, lightheadedness, paresthesia, hypotension, arrhythmia, respiratory depression, cardiac arrest
Botulinum toxin (Botox)		headaches, chronic lower back pain	Bruising, pain at the injection site, dysphagia if injections are near the neck and mouth

Table 4. Novel pharmacologic approaches to pain management with dosages, benefits, and common side effects.

5.4 Additional treatments

5.4.1 Paravertebral injection of botulinum toxin (Botox)

Paravertebral injection of the botulinum toxin (Botox), commonly used in the treatment of headaches, appears to also have a place in the treatment of chronic lower back pain [34]. Botox's mechanism of action involves the reduction of muscle hyperactivity and tension by blocking the presynaptic release of acetylcholine [35].

The most common side effects include bruising and pain at the injection site. Dysphagia can be caused by injections near the neck and mouth. Contraindications include infection near injection site, allergy to medication, Eaton Lambert syndrome, or Myasthenia Gravis. Patients must be 13 years or older and not pregnant or nursing. Botox should be used with caution in patients with neuromuscular conduction disease or taking medications that alter this as well as those with peripheral motor neuron disease [35].

5.4.2 Trigger point injection

Trigger point injections or dry needling is typically used for myofascial pain. They also have a role in alleviating pain from post-mastectomy pain syndrome (PMPS) [36]. These points are identified by palpation, observing for tenderness, referred pain or even twitching of muscle fibers when compressed, commonly referred to as "knots." A needle or an injection containing local anesthetic (avoid bupivacaine as this can be myotoxic) or even saline is inserted at these points directly into the muscle tissue. Care must be taken to avoid any major structures [37].

In order to carry out this procedure, a needle is inserted into the trigger point and "fanning" can be done, which theoretically disrupts connective tissue and causes muscle fiber relaxation and lengthening. Recent studies are currently exploring Radial Extracorporeal Shock Wave Therapy as an alternative to trigger point injections in the treatment of myofascial pain [38].

6. The use of external stimulation devices for chronic pain

6.1 Transcutaneous electric nerve stimulation (TENS)

Transcutaneous electrical nerve stimulation (TENS) is a safe, portable, cost-effective, and noninvasive treatment approach used for pain management in patients who are refractory to pharmacological intervention. Electrical pulses are delivered to adhesive electrode pads positioned on the patient's skin overlying the region where treatment is to be administered [39]. The duration, frequency, and intensity of the electrical pulses delivered by the device can be adjusted by the care provider. The electrode pads are attached to two or more electrode wires connected to the battery-powered TENS device. TENS is believed to relieve pain via decreasing dorsal horn neuron sensitization and increasing gamma-aminobutyric acid (GABA) and glycine levels. **Figure 1** below shows a common setup for outpatient TENS treatment.

Indications for use include musculoskeletal pain, neuropathic pain, osteoarthritis, fibromyalgia, pelvic pain, and lower back pain [40, 41]. The use of TENS is not recommended in patients who have electronic implants such as pacemakers and cardiac

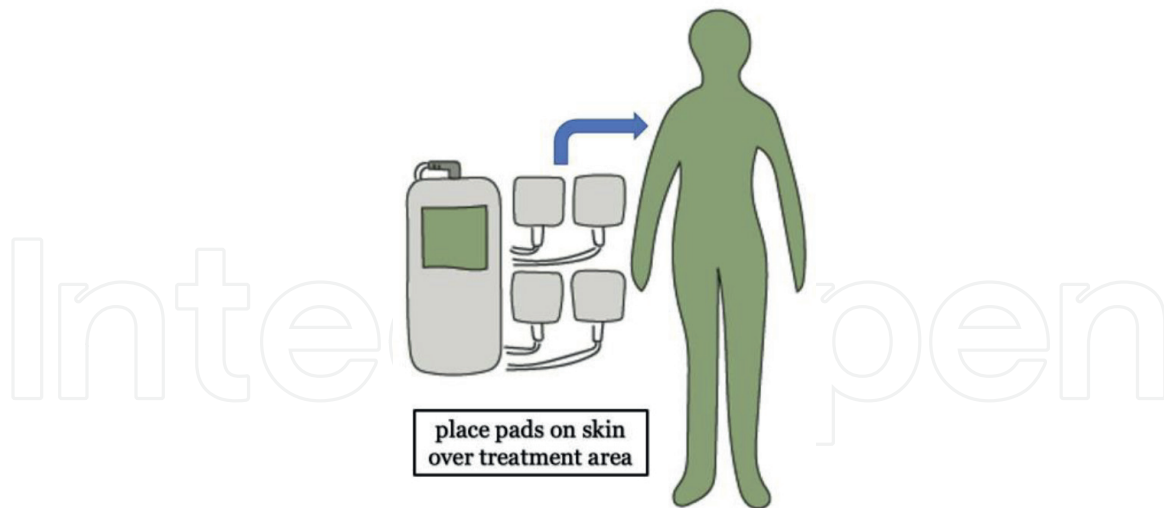


Figure 1.
A schematic of a common setup for TENS treatment.

defibrillators. Caution is also advised before use in individuals who are pregnant, have epilepsy, have active malignancy, have blood clots, have damaged skin, and are immunocompromised [42, 43]. Adverse effects of TENS include skin burns where electrode pads are placed and allergic reaction to electrode pad or its adhesive [39].

6.2 Interferential current stimulation

Interferential current stimulation (ICS) is a convenient, cost-effective, and noninvasive treatment approach used for pain management in patients who are refractory to pharmacologic intervention. In ICS, alternation of two or more sinusoidal currents simultaneously generates interference and maximizes the ability of the current to permeate tissues while maintaining minimal cutaneous nerve stimulation [44]. Intersection and interference of currents in the region to be treated are facilitated by the way the two or more electrodes are placed on the skin for ICS treatment. **Figure 2** shows a schematic of outpatient ICS treatment.

Indications for use include muscle stimulation such as for physiotherapy or rehabilitation, knee osteoarthritis, chronic low back pain, shoulder soft tissue pain, chronic jaw pain, fibromyalgia, incontinence, edema reduction, and myofascial syndrome pain [44–46]. The use of ICS is contraindicated in patients who have implanted electronic devices such as pacemakers, cardiac defibrillators, or hearing aids. Caution is advised before use in patients who are pregnant, have cardiovascular disease, have inflammation or fever, have active malignancy, and have thrombosis. Adverse effects include skin burns, bruises, blisters, or swelling of skin overlying treated region as well as discomfort or muscle soreness in the treated region.

6.3 Pulsed electromagnetic field therapy

Pulsed Electromagnetic Field Therapy (PEMF or PEMT) is a safe, noninvasive treatment approach used for pain management in patients who are refractory to pharmacologic intervention.

The PEMT device consists of a mat comprised of spiral coils and frequency generator that energizes the coils to generate a pulsed electromagnetic field [47, 48]. That electromagnetic field in turn induces electric fields in the patient's conductive

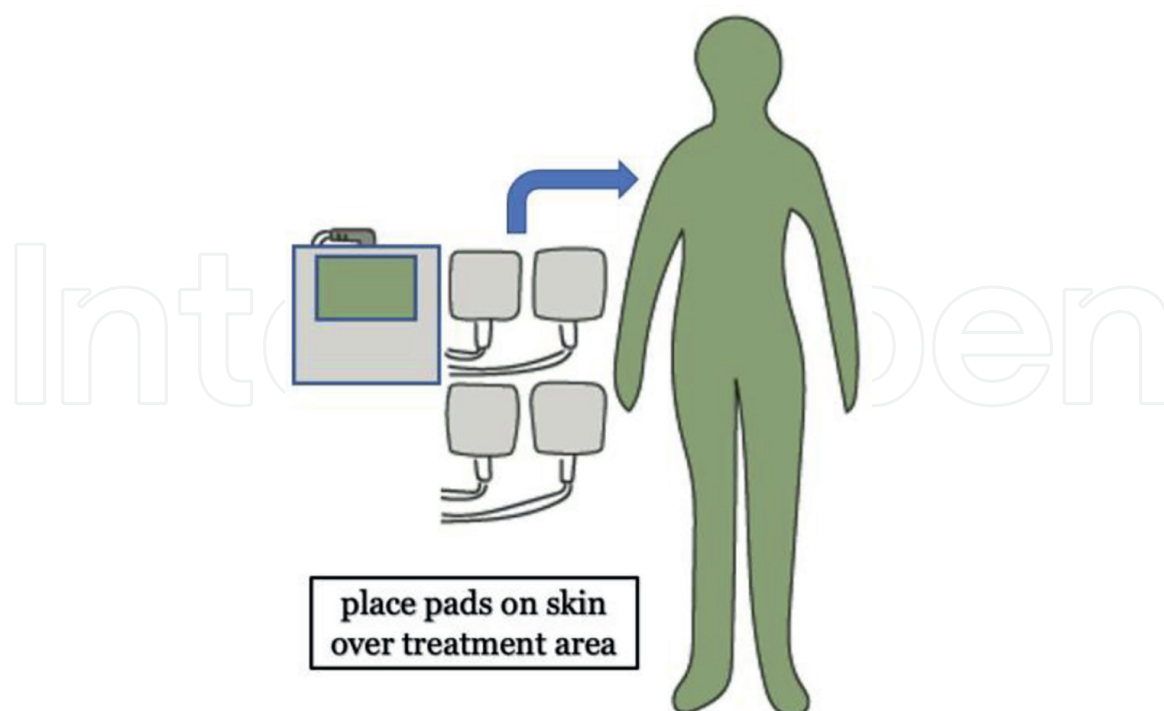


Figure 2.
A schematic of a common setup for ICS treatment.

tissues via inductive coupling. PEMT is believed to cause changes in cellular signaling and modulation of inflammatory cytokines, growth factors, and membrane receptors that produces an analgesic effect [49–51]. **Figure 3** shows a common setup for PEMF/PEMT treatment.

Indications for use include healing of non-union fractures, stress urinary incontinence, cervical fusion, depression, anxiety, brain cancer, fibromyalgia, rheumatoid arthritis, musculoskeletal pain, knee osteoarthritis, chronic pelvic pain, and chronic low back pain [52, 53]. The use of ICS is contraindicated in patients who have implanted devices such as cardiac defibrillators and pacemakers. Caution

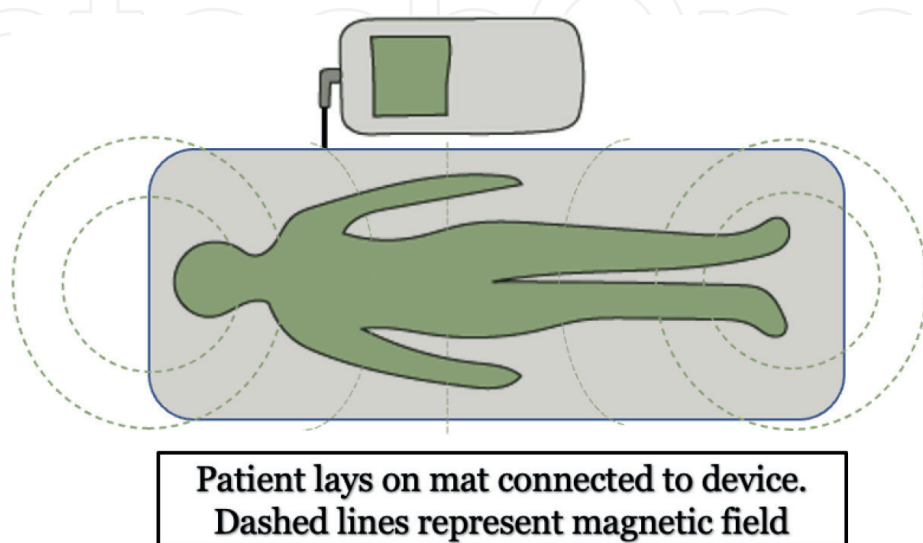


Figure 3.
A schematic of a common setup for PEMF treatment.

is advised before use in patients who are children, are pregnant, have cardiovascular disease, have inflammation or fever, have active malignancy, and have thrombosis. Adverse effects include possible cancer risk from exposure to low-frequency magnetic field.

6.4 Diathermy

Diathermy is a noninvasive treatment approach used for pain management in patients who are refractory to pharmacologic intervention. The technique involves the controlled production of heat within body tissues using high-frequency electromagnetic current generated by diathermies, deep-heating agents such as ultrasound, shortwave, and microwave [54]. The heat generated is believed to increase local circulation, thus promoting toxin removal, facilitating tissue repair, and providing pain relief [55]. **Figure 4** shows a schematic for a common diathermy setup.

Indications for use include rotator cuff disease, bursitis, tendinitis, osteoarthritis, peripheral neuropathy, low back pain, musculoskeletal pain, and fibromyalgia [56, 57]. The use of ICS is contraindicated over wet dressings, reproductive organs, and infected open wounds. It is also contraindicated in patients who are pregnant, have impaired thermal sensation, have implanted devices such as pacemakers, have metal implants, have severe edema, and have bleeding disorders. Caution is advised before use in patients who have cardiac disease, have vascular disease, have active infection or fever, have active malignancy, and have thrombosis. Adverse effects include burns in the treated and adjacent tissues, shock or burn, and excessive heating of metal implants in body such as dental fillings or bone pins.

7. Interventional management of subacute and chronic pain

Interventional pain management, borne of regional anesthesia and neural blockade, has evolved into a multimodal, multidisciplinary approach to treat the incredibly costly and debilitating symptoms of chronic pain. Due to the more

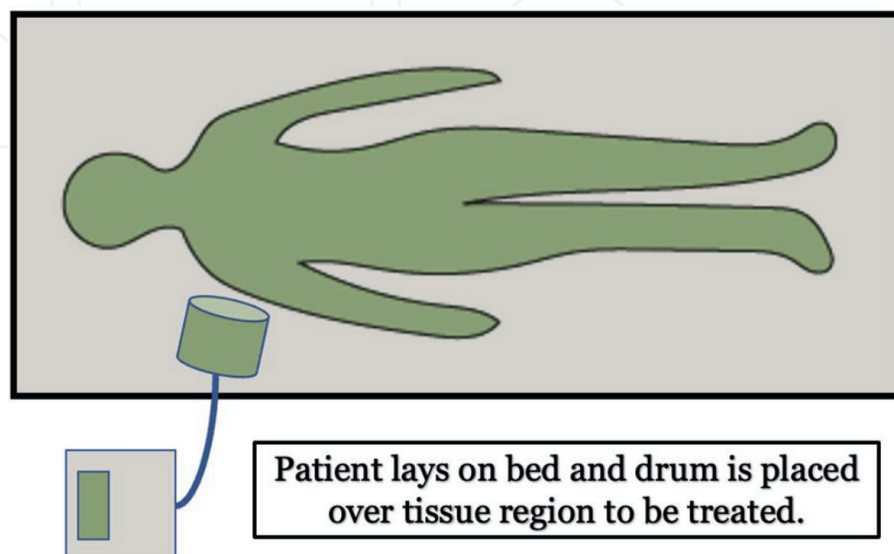


Figure 4.
A schematic of a common setup for induction diathermy treatment via drum method.

invasive nature of interventional procedures, they are not usually first line in the treatment of subacute to chronic pain. Typically, patients are seen in the pain management clinic after failure of pharmacological and/or physical therapy for at least 6 weeks. In 2016, low back and neck pain costs an estimated \$134.5 billion dollars and the most common symptom patients present with at interventional pain clinics [58].

Since the 1950s, epidural steroids injections (ESIs) have been used for pain relief of chronic lower back and neck pain, particularly for treatment of radiculopathy. ESI continues to be a mainstay of procedural pain management [59].

Interventional procedure steps may differ and depend on the physician's training and/or patient's body habitus, and the procedures described in this section take that into account in addition to two major pain society guidelines.

7.1 Injectates

7.1.1 Glucocorticoids

Long-acting (depot) glucocorticoids can be used in intra-articular and epidural injections. Two of the most used depot glucocorticoids include methylprednisolone acetate and triamcinolone acetonide. For peripheral intra-articular injections, there is no current standard for dosing of these steroids; however, it is common practice to base the dose on the size of the joint. For methylprednisolone acetate, 10–20, 40–60, and 40–80 mg are used in small, medium, and large joint sizes, respectively. Triamcinolone acetonide dosing is 8–10, 20–30, and 20–40 mg on small, medium, and large joint sizes, respectively.

Contraindications for injectates are septic arthritis due to risk of exacerbation of infection, juxta-articular osteoporosis due to risk of worsening bone density, periarticular fracture as glucocorticoids can inhibit bone healing, and joint instability due to risk of weakening adjacent ligaments and capsule [60].

7.1.2 Local anesthetics

The most utilized local anesthetics include lidocaine and bupivacaine, both amides. These anesthetics can be used with or without epinephrine. Epinephrine is added for its vasoconstriction effects that decrease uptake of the local anesthetic into the circulatory system, which affects the cardio- and neuro toxicity and allowing for higher dosages, increases duration of action of the local anesthetic (except for bupivacaine), and decreases bleeding. The addition of epinephrine to local anesthetics is not recommended in procedures on digits of patients with peripheral vascular disease.

In the adult patient, lidocaine without epinephrine dosing should not exceed 4 mg/kg. Lidocaine with epinephrine should not exceed 7 mg/kg. Bupivacaine without epinephrine dosing should not exceed 2 mg/kg meanwhile bupivacaine with epinephrine should not exceed 3 mg/kg. Notably, lidocaine has a higher allowable dose increase with epinephrine when compared to bupivacaine because bupivacaine is more cardiotoxic due to its slower rate of dissociation at diastole, cardiotoxicity being the dose-limiting adverse reaction.

Bupivacaine, typically used at 0.25–0.5% concentration, is longer acting than lidocaine [61]. **Table 5** compares the more commonly used local anesthetics in pain clinics.

Anesthetic Injectate	Concentration (%)	Onset of Action (min)	Duration of Action (min)	Maximum Allowable Dose (mg/kg)	Maximum Total Dose (mg)
Lidocaine	1	2-5	50-120	4	300
Lidocaine (w/epinephrine)	1 (1:200,000)	2-5	60-180	7	500
Bupivacaine	0.25	5-10	240-480	2	175
Bupivacaine (w/epinephrine)	0.25 (1:200,000)	5-10	240-480	3	225

Table 5. Comparison of commonly used local anesthetics for interventional pain procedures.

7.2 Imaging

Interventional pain clinics rely on either surface landmarks or image guidance such as computed tomography (CT), fluoroscopy, or ultrasound. Historically, surface landmarks were the choice among physicians in performing interventional pain procedures. Imaging is more common now for the accuracy and precision of a procedure as well as improved safety of the patient. Ultrasound guidance, the oldest of the aforementioned imaging modalities, had resurgence across multiple specialties including pain medicine as it is a bedside, point-of-care tool that provides real-time visualization of needle placement and advancement as well as adjacent structures. Ultrasound technology also reduces radiation exposure to both patient and interventionalist [62].

An ultrasound suite requires a smaller footprint when compared to a room that has a C-arm (used for fluoroscopic guidance). Room and equipment setups vary according to physician preference. **Figure 5** below shows an example of a common material setup for ultrasound-guided injection within a room.

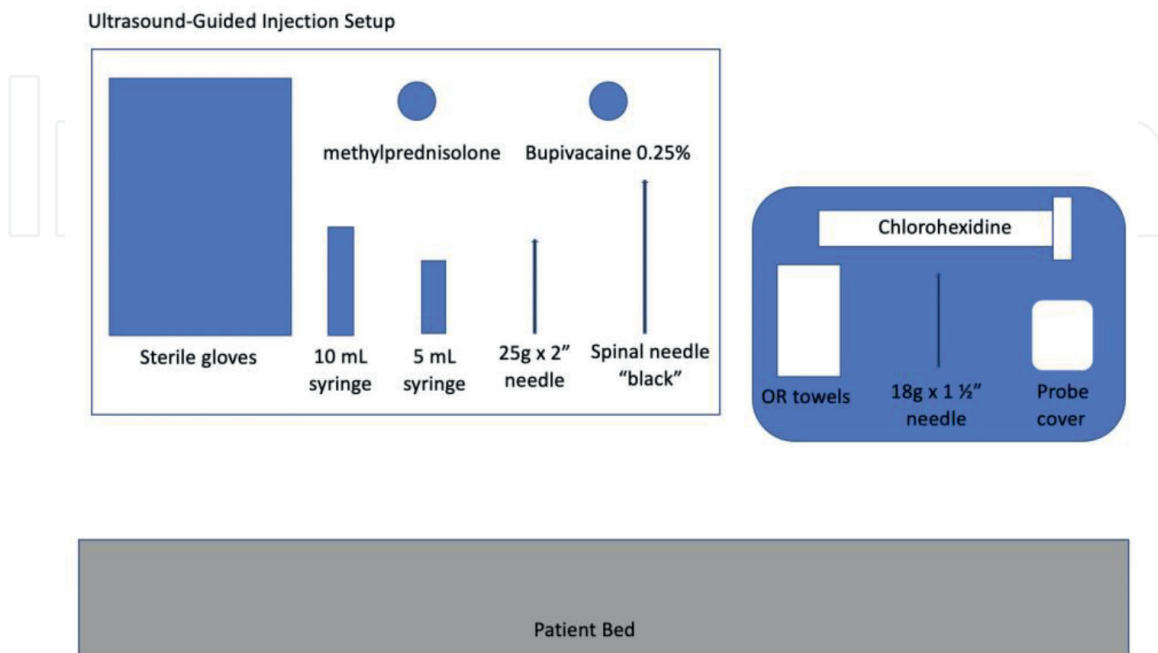


Figure 5. A schematic of a common setup for ultra-sounded guided procedures (not drawn to scale).

7.3 Joint injections

Most of the procedures listed below can be done with ultrasound or fluoroscopic guidance.

7.3.1 Hip joint injection

The hip joint is the articulation of the acetabulum and the femoral head, also known as the femoroacetabular joint, is essentially a ball-and-socket joint. Notably, 40% of the femoral head is in contact with the acetabulum, lubricated by synovium, at all times—in extension, flexion, rotation, which allow for steady gait, rising from a seated position and general mobilization. This major joint is stabilized by way of ligaments (ischiofemoral, pubofemoral, and iliofemoral) and cartilage, particularly, the labrum. Osteoarthritis of the hip is deterioration of the articular cartilage, and this wear and tear may cause pain that can significantly affect activities of daily living (ADLs) [63]. This procedure can be done via either ultrasound or fluoroscopic guidance.

For performing the procedure under fluoroscopic guidance, anatomical landmarks are first identified by way of fluoroscopy in the AP and oblique views. The patient's hip region is prepped and draped in sterile fashion. The skin and subcutaneous tissues at the needle entry site are infiltrated with a small amount of Lidocaine. The needle is then advanced incrementally under fluoroscopic guidance toward the point where the femoral head meets the femoral neck until os is contacted and the joint space is entered. After negative aspiration, a small amount of contrast solution is injected showing an appropriate arthrogram to ensure that needle termination is not in an adjacent bursa and thereby truly intra-articular. Then, a solution consisting of a local anesthetic mixed with a glucocorticoid is injected slowly. **Figure 6** is an image of a fluoroscopic-guided right hip injection.

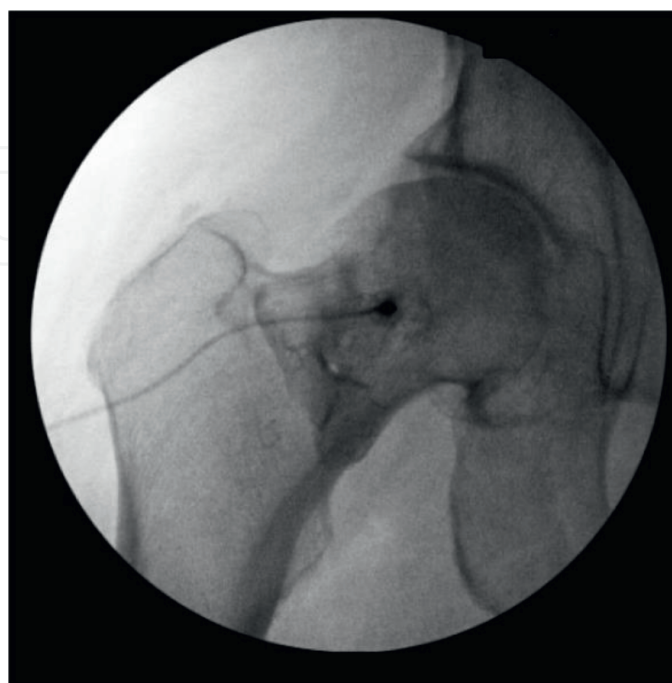


Figure 6.
An example of an image captured during fluoroscopic-guided right hip injection.

For performing the procedure under ultrasound guidance, the patient's hip region is prepped and draped in the usual sterile fashion. A needle is advanced incrementally under ultrasound guidance toward the femoral neck until os is contacted and the joint space is entered. The local anesthetic and glucocorticoid mixture is given after negative aspiration.

Potential risks and complications include infection, small vessel injury, and bleeding. Contraindications include, but are not limited to, acute fracture, bacteremia, septic arthritis, or infection at needle entry site.

7.3.2 Sacroiliac joint injection

Sacroiliac (SI) joint pain is a common cause of mechanical low back pain. It is a pain, when described by patients, radiates to the back, typically below L5, and groin. Typically, degenerative etiology, pregnancy, or trauma can also cause SI joint pain. SI joint injections can be diagnostic as well as therapeutic. The SI joint, as the name suggests, is located between the sacrum and the ilium, bilaterally. Sensory innervation of this joint is not clearly defined; however, it may be lateral branches from dorsal sacral foramen and possibly L5 dorsal rami as well as the superior gluteal nerve [64].

The procedure is typically done with the guidance of fluoroscopy. The patient is prepped in a prone position until the inferior borders of the SI bony plates are parallel on imaging. With intermittent fluoroscopy, needle inserted is inferior until popping sensation is appreciated. Contrast is injected and should outline the SI joint. As with other joint injections, injectate is local anesthetic and corticosteroid. This can also be done under CT or ultrasound guidance [65]. **Figure 7** shows an image of a right SI joint injection under fluoroscopy.

The risks to this procedure include increased pain at the site of insertion or injection, infection, trauma to nearby anatomy, including nerves. Unsuccessful pain reduction is also possible, when done under fluoroscopic guidance, this appears to be around 10% risk of failure [66].

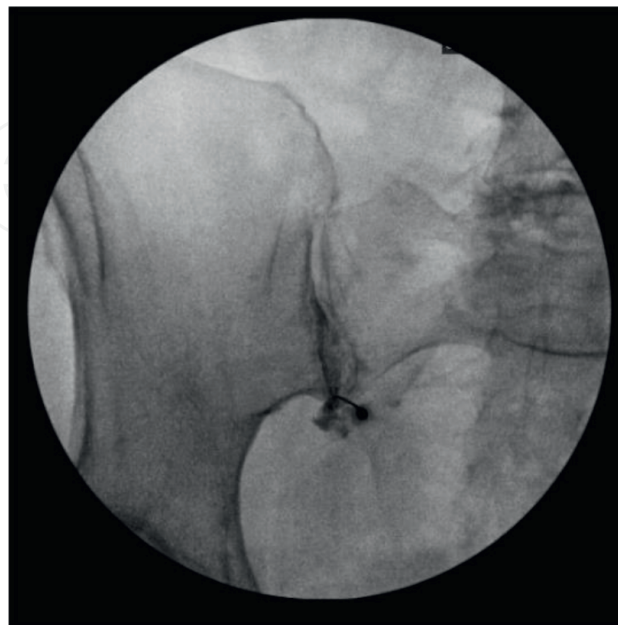


Figure 7.

An example of an image captured during fluoroscopic-guided right SI joint injection performed in the interventional pain clinic.

7.4 Neuronal blockade

Different forms of neural blockade, initially used for surgical anesthesia, have secured their positions in chronic pain management.

7.4.1 Greater occipital nerve

The greater occipital nerve (GON) block can be used as a primary treatment for multiple types of severe headaches or, more commonly, treatment-resistant headaches. A GON block can relieve migraines, cervicogenic headaches, post-dural puncture headaches, and even optic neuralgia. GON block is particularly useful for patients who are not able to tolerate more common pharmacologic regimens, such as those with multiple comorbidities, as well as the elderly and pregnant patient population [67]. The GON stems from the medial branches of dorsal primary rami of the cervical nerve roots C2 – C4, and occasionally C5 and innervates the posterior scalp [68].

To carry out the procedure, the patient is placed in a prone or seated position with slight flexion at neck. Identify the surface landmarks, typically palpated, mastoid process, and occipital protuberance ipsilateral to the headache pain. The GON is about two-thirds of the distance from the mastoid process to the occipital protuberance, about 2 cm lateral and 2 cm inferior from the protuberance. Insert needle from an infero-lateral approach until contact is made with the periosteum and then retract about 1 mm. Aspirate needle at this location to ensure that needle tip is not in the occipital artery and inject with or without a sweeping motion. This can be done with ultrasound guidance and should be noted that GON is typically medial to the occipital artery as shown in **Figure 8**.

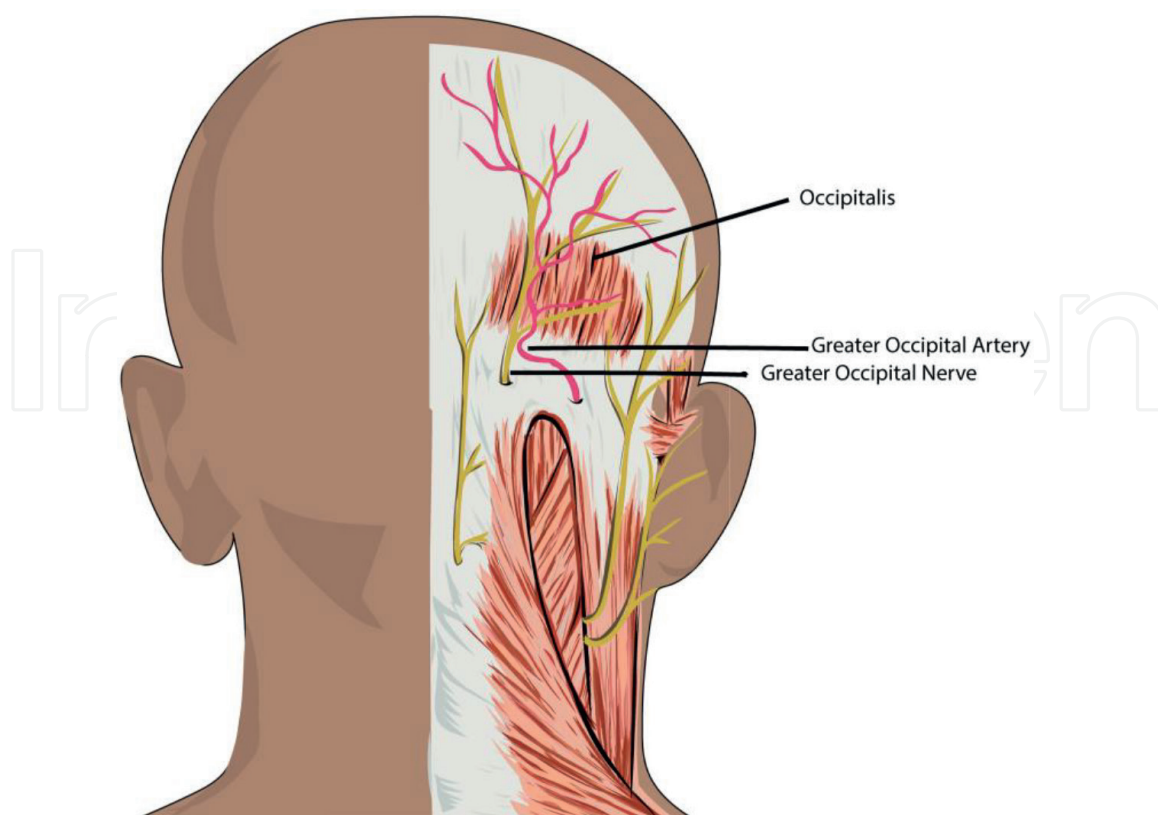


Figure 8.
Anatomic considerations for greater occipital nerve neuronal blockade.

Local anesthetic with or without glucocorticoid is commonly used as the injectate. The use of glucocorticoids can be specifically effective for certain types of headaches such as cluster headaches [69].

As with other nerve blocks, intravascular injection can lead to significant complications. Cushingoid, secondary to excess glucocorticoid, can occur with serial blocks that contain glucocorticoid treatment [70].

7.4.2 Celiac plexus

The blockade of the celiac plexus can be used for intractable abdominal pain, and most commonly pain caused pancreatic cancer [71, 72]. The celiac plexus has three major components, celiac, aortic, and superior mesenteric stemming from the anterolateral horn of the spinal cord at T5–T12. The celiac plexus innervates the gallbladder, liver, pancreas, and gastrointestinal tract from the stomach to the transverse colon [73].

To carry out this procedure, the patient is positioned in prone and with maximal kyphosis by bolster. Recent evidence suggests that ultrasound-guided celiac plexus blocks are safer and less costly [74]. The surface landmarks are T12 and L1 vertebral bodies. The needle is inserted at the inferior border of the 12th rib, about 6–8 cm from the midline, at a 45-degree posterior to anterior angle, and advanced toward the ventral surface of T12-L1 intervertebral space. Once contact is made with vertebral body, needle is advanced further by 1 cm into the prevertebral fascial plane. This can be confirmed by fluoroscopy [73]. **Figure 9** shows the anatomic considerations for the celiac plexus at vertebral level T12.

If a patient is unable to lie prone, an anterior para-aortic approach can be useful. At the anterior T12 vertebral body, the needle is inserted and advanced toward the abdominal aorta and injected into the antero-crural space. It must be noted that an anterior approach has a higher risk of organ injury [73]. In terms of the injectate used,

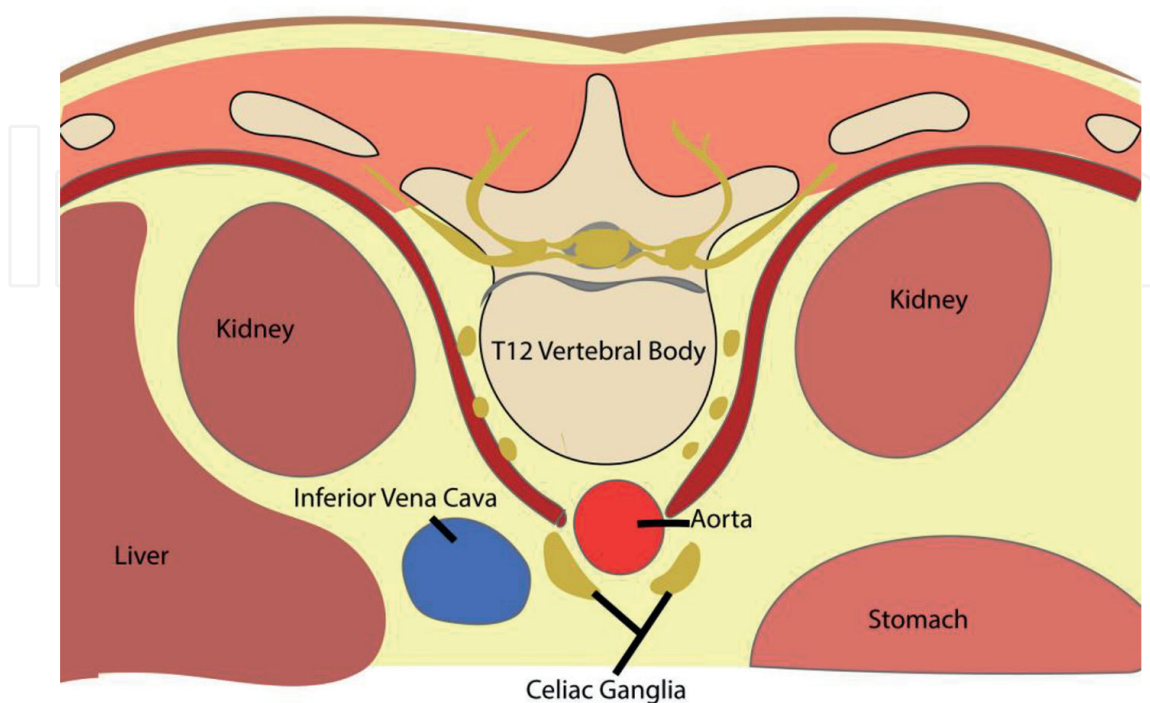


Figure 9.
Anatomic considerations for the celiac plexus.

steroid and local anesthetics are used for benign etiologies of pain and neurolytics are for malignant etiology.

The possible complications from a celiac plexus nerve block or neurolysis include but are not limited to the following: orthostatic hypotension, paresthesia, infection, pneumothorax, paraplegia, and a higher risk of organ damage with the anterior approach [75].

7.4.3 Superior hypogastric plexus

The blockade of the superior hypogastric plexus can be used for chronic pelvic pain caused by multiple etiologies including endometriosis, inflammatory processes, postoperative adhesions, and malignancy [76]. The superior hypogastric plexus is located in the retroperitoneal space, between L5-S1 vertebral bodies.

In the posterior approach, the patient is placed in prone position with emphasized flexion at the lumbar spine by bolster. The surface landmark of L4-L5 intervertebral space is identified, and under fluoroscopic-guidance, the needle is inserted 5–7 cm lateral of the middle of this space, from either side, at a 30-degree oblique and 30-degree caudad angle, toward the anterolateral L5-S1 paraspinous junction. Contrast should spread midline in the AP view and needle tip should be visualized at the anterolateral margin of L5 and spread anterior to the L5 vertebral body. It is important to emphasize the proximity of the superior hypogastric plexus to the iliac vessels [77]. Local anesthetic or neurolytic is commonly used as injectate.

This procedure can cause transient or even permanent retrograde ejaculation as the urogenital system is primarily innervated by the superior hypogastric plexus.

7.4.4 Medial branch block (MBB) injection

Facet joint injection is the injection of a combination of steroid and local anesthetic at the site of the joint, while medial branch block is injected right outside the joint at the medial branch of the dorsal rami. Theoretically, either may have prognostic value for radiofrequency ablation and the latter with more therapeutic value, however, mostly short-term. Common practice at pain management clinics usually requires successful diagnostic medial branch blocks on two separate occasions, which can be followed with radiofrequency ablation [78]. MBBs are indicated for spondylosis, post-laminectomy syndrome, facet arthropathy, and disk degeneration.

To carry out this procedure, the patient is placed in the prone (lumbar) or supine (cervical, anterior approach, other approaches include posterior or posterolateral, dependent on technique of interventionalist) position. Anatomical landmarks are identified with the aid of fluoroscopy in the PA and oblique views [77].

For the Lumbar Spine: The patient's lumbar region is prepped and draped in sterile fashion. The skin and subcutaneous tissues at each needle entry site are infiltrated with a small amount of lidocaine using a needle is incrementally advanced under fluoroscopic guidance in multiple views at each level such that the needle tip is advanced to contact os at the junction of the superior articulating process and the superomedial border of the transverse process at each of the cephalad levels as well as to contact os at the junction of the superior articulating process and the superomedial border of the sacral ala at the S1 level. After negative aspiration is confirmed, a small amount of lidocaine is injected into the cephalad needles and a small amount of 0.25% Bupivacaine is injected at the S1 level.

For the Cervical Spine: The patient's cervical region is prepped and draped in sterile fashion. The skin and subcutaneous tissues at each needle entry site are infiltrated with approximately a total of 3 mL of 1% lidocaine. Needles are advanced under fluoroscopic guidance from the lateral view such that the needle tips are positioned on os at the center of the cuboid masses of the posterior columns of targeted levels. Needle placement should be confirmed via fluoroscopy. At each level, following negative aspiration, a small amount of 0.25% Bupivacaine (or other anesthetic) is injected slowly.

After the procedure, the patient's skin is wiped clean and bandages are placed. **Figure 10** shows an example of an image capture by fluoroscopy for a medial branch block while **Figure 11** is an illustration that shows approximate location of the medial branch in relation to a vertebral body and facet joint.

In terms of anatomic considerations, the C3 deep medial branch, C4, and C6 medial branches are located slightly above the waist of their corresponding articular pillars and C5 medial branch tends to be located right at the waist of the articular pillar. The risks of the procedure include trauma or damage to nearby structures including the spinal cord or adjacent nerves, infection, epidural bleeding, or hematoma.

Other neuronal blocks include stellate ganglion as shown in **Figure 12** for head, neck, and upper arm pain, and genicular nerve for chronic osteoarthritis of the knee as shown in **Figure 13**.

Other procedures include shoulder injections as shown in **Figure 14** and piriformis injection as shown in **Figure 15** for piriformis syndrome, most commonly causing sciatic nerve entrapment and subsequent symptoms. Bursa injections provide relief for bursitis particularly trochanteric, ischial, subacromial, olecranon, and prepatellar.

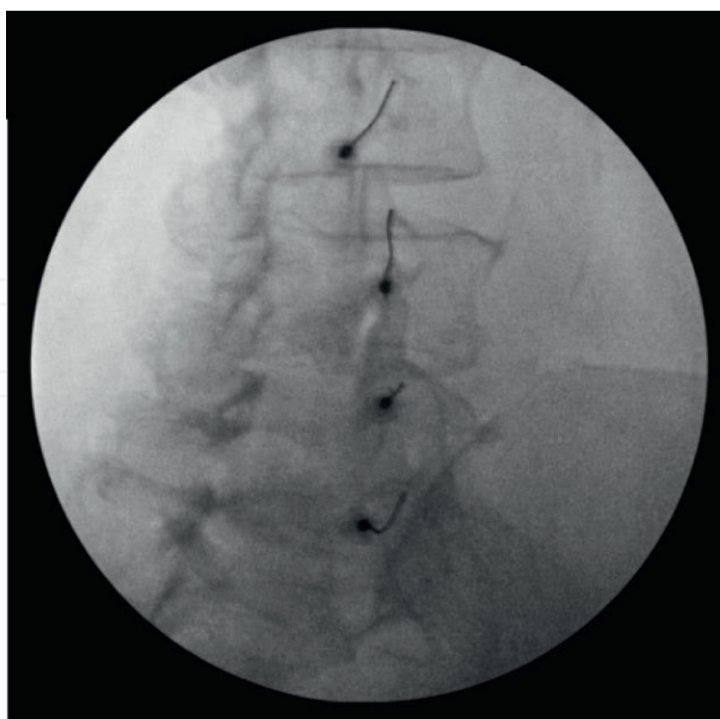


Figure 10.
An example of an image captured during fluoroscopic-guided medial branch block performed in the interventional pain clinic.

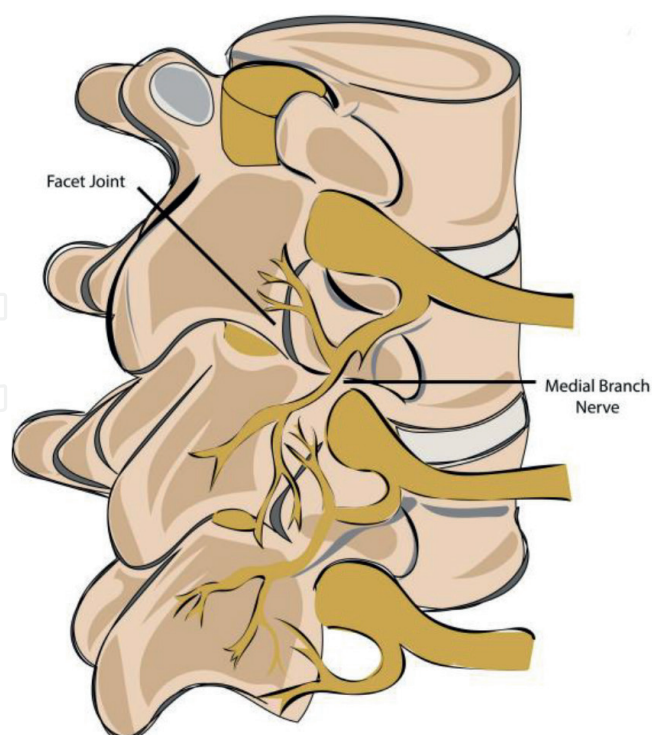


Figure 11.
Anatomical considerations for medial branch blocks.

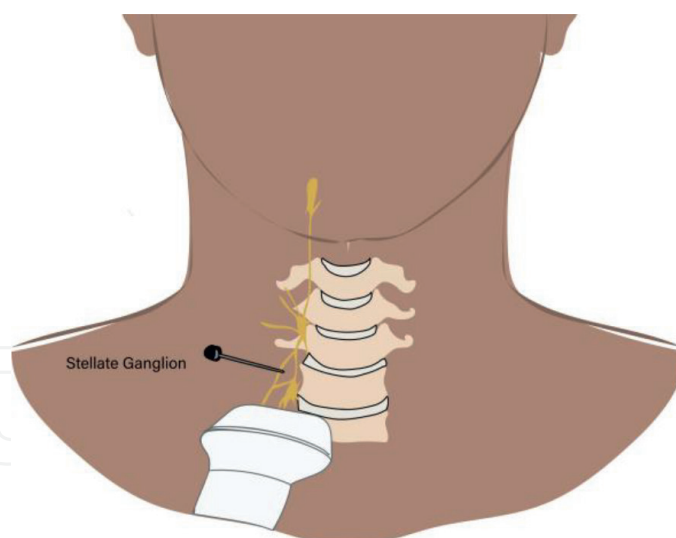


Figure 12.
Anatomical considerations for stellate ganglion blockade.

7.5 Radiofrequency ablation

Literature on radiofrequency ablation (RFA) continues to show mixed results on its cost effectiveness and therapeutic efficacy [79]; despite this, RFA continues to be commonly performed in interventional pain suites, most commonly for facet joint pain as well as SI joint pain.

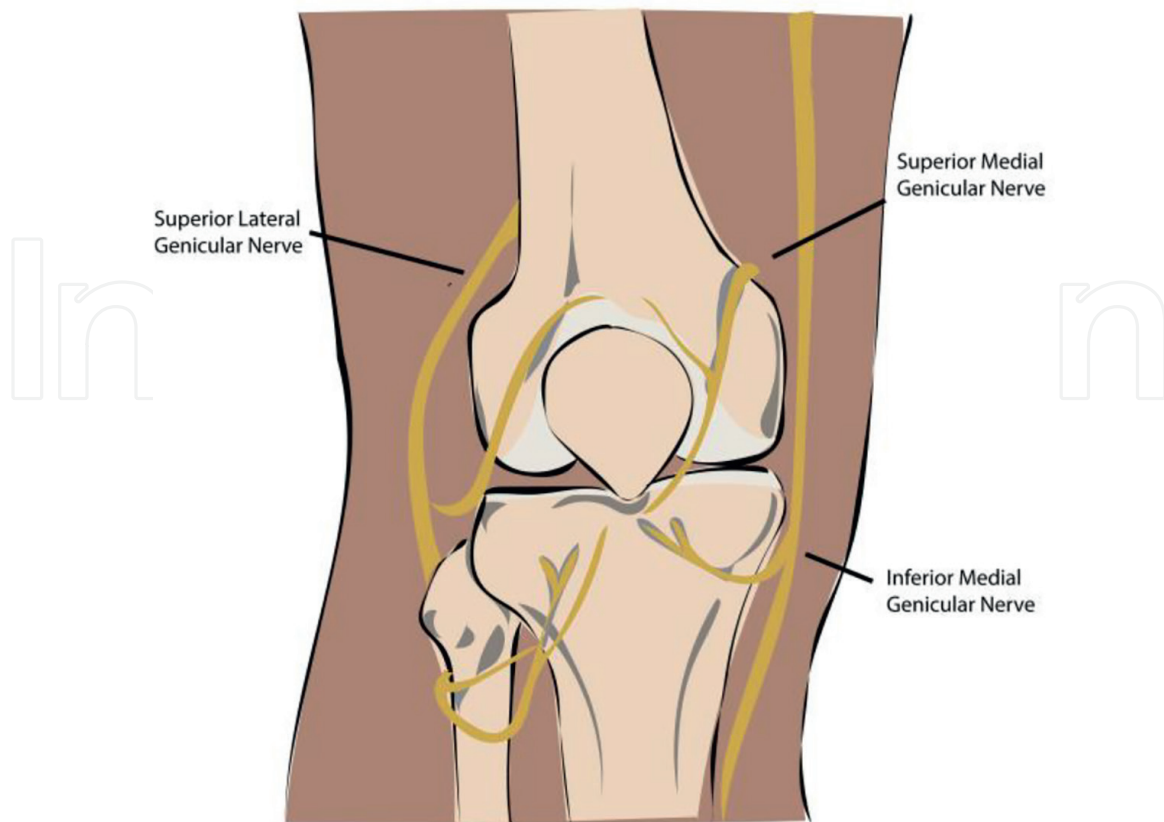


Figure 13.
Anatomical considerations for genicular nerve blockade.

Prior to first time ablation of the MBB for facet joint pain, at least two rounds of successful diagnostic MBBs are usually required. Some hospital systems, such as St. Luke's University Health Network (SLUHN), provide patients with a pain diary after MBB to gauge success of procedure prior to RFA. Repeat ablation may have different prerequisites in different locations. Patients are educated that the goal of RFA is a 50% reduction in pain for about 6–12 months since tempering patient expectations is a mainstay of pain management practice.

RFA is currently being used for facet joint pain by targeting the medial branch of the dorsal ramus (since reimbursement is trending away from intra-articular facet joint injections), discogenic pain (ramus communicans), SI joint pain as well as radicular pain (DRG).

To carry out RFA, the patient is placed in the prone position. Anatomical landmarks are identified by way of palpation with fluoroscopy in the PA and oblique views. The patient's lumbar region is prepped and draped in the usual sterile fashion using chlorhexidine. The skin and subcutaneous tissues are infiltrated with a small amount of 1% Lidocaine at each of the intended needle entry sites. Via fluoroscopy in the AP and oblique views, needle tip is incrementally advanced under fluoroscopic guidance at each level. At each of these levels, the needle tip contacts the os at the superior medial border of the junction of the transverse process of the lumbar levels and to contact the os at the medial aspect of the groove formed by the sacral ala in the superior articular process of S1.

After proper needle placement is confirmed with fluoroscopic guidance at each level, sensory and/or motor stimulation is performed at 2 Hz and 50 Hz, respectively. Small amount of 2% lidocaine is instilled at all levels. After a period of approximately 90 seconds, each level is lesioned at 90 degrees Celsius. Following the initial lesioning,

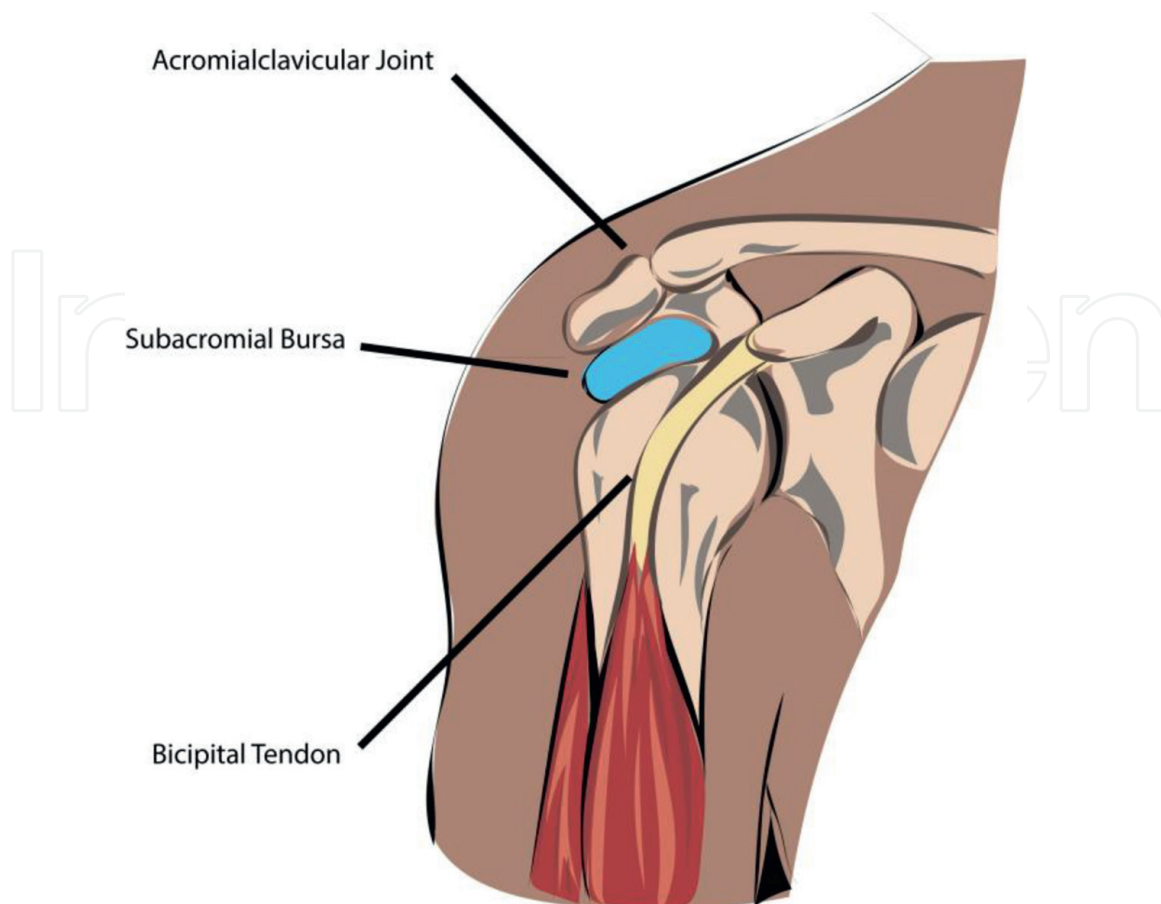


Figure 14.
Anatomical considerations for shoulder injections.

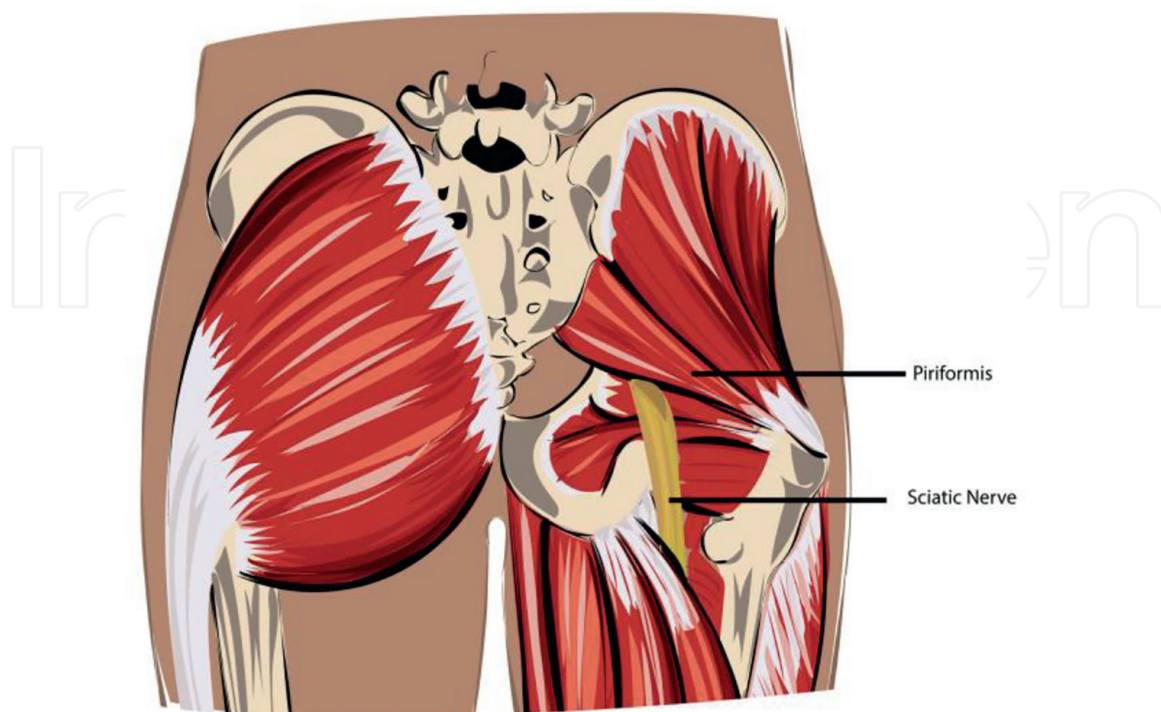


Figure 15.
Anatomical considerations piriformis injection.

each needle tip is repositioned x 2 under fluoroscopic guidance in a clockwise and counterclockwise fashion. Following each reposition, a total of two additional lesions at each side are performed for 90 seconds at 90 degrees Celsius. See **Figure 16** for common settings. After all needles are removed, skin is wiped clean and bandage is placed [77]. **Figure 17** is a schematic of a common room setup for an RFA procedure.



Figure 16.
Initial RFA settings are 90° C for 90 seconds.

Radiofrequency Ablation Room Setup

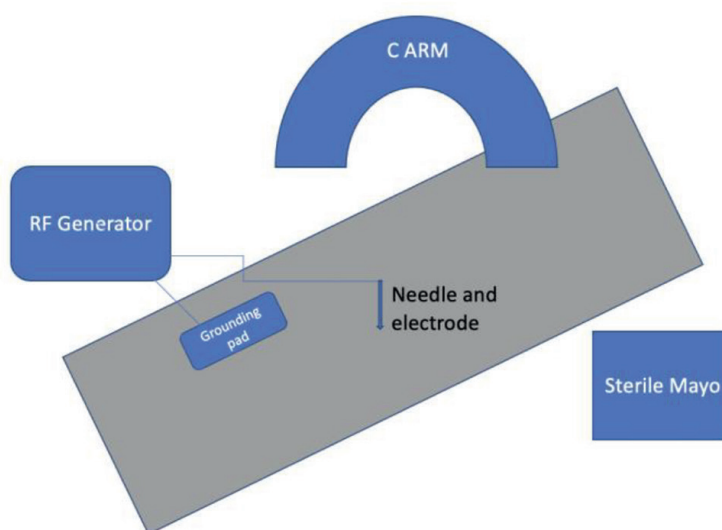


Figure 17.
A schematic of a common setup of an RFA room (not drawn to scale).

Classically, RFA involves thermal energy to cause a lesion and subsequent disruption of a nociceptive pain pathway, by way of Wallerian degeneration. There are currently other iterations including water-cooled radiofrequency ablation (WCRF), cryo-neurolysis, and pulsed radiofrequency ablation [80].

Dizziness and ataxia are possible complications, particularly with cervical RFA. There is also the possibility of infection, cutaneous numbness, dysesthesia, postprocedural pain, and trauma to adjacent structures.

The above discusses conventional continuous radiofrequency ablation. There is also pulsed radiofrequency ablation (PRF) that delivers sort bursts of current and water-cooled radiofrequency ablation (WCRF), a method that uses a continuous flow of water to regulate the flow of current and prevents the needle from overheating.

7.6 Spinal cord stimulation

Spinal cord stimulators (SCS) are indicated for persistent pain status post spinal surgery also known as failed back surgery syndrome (FBSS), and it is moderately effective for radicular pain. It can also be used for Complex Regional pain syndrome (CRPS), painful diabetic neuropathy, and even postherpetic neuralgia and axial low-back pain. Notably, in Europe, SCS is used in refractory angina and peripheral vascular disease [81]. Psychiatric evaluation clearance is common place practice prior to a SCS trial. SCS is typically done in two stages, including a trial device and if effective (50% reduction in pain [82],) final device placement, both done under fluoroscopy.

A SCS trial includes the following steps: The patient is placed in the prone position with legs, abdomen, and arms padded, neck should be noted in neutral position with minimal discomfort. Patient is prepped in sterile fashion. Anatomical landmarks are identified by way of palpation and fluoroscopy in the AP view and the skin overlying the initial intended insertion site is infiltrated with a small amount of 1% Lidocaine. A Touhy needle is incrementally advanced using a loss-of-resistance technique with the aid of fluoroscopy in both the AP and lateral views into the appropriate epidural space. An 8-contact lead is subsequently passed through the Touhy needle and advanced into the epidural space under the aid of fluoroscopy to where the tip of the lead was is at the targeted endplate. The lead is confirmed posterior by way of fluoroscopy in the lateral view and in the AP view [77].

The patient's pain is adequately captured with initial stimulation and the introducer needles are removed with tips in place. The electrodes are secured with adhesive strips. Impedance is checked and multiple electric combinations were utilized to provide coverage of the patients' area of pain. **Figure 18** shows an example of a fluoroscopic image of a trial spinal cord stimulator placed in the thoracic spine.

Of note, prophylactic and postsurgical broad-spectrum antibiotics are used at SLUHN for the placement of the trial device.

If the SCS trial is successful, the final device is placed where an incision is made for tunneling the cables leads and a second incision is made to place the pulse generator above the iliac crest after which the lead cables are connected by tunneling to the pulse generator.

General lead placement locations are navigated by the location of pain [83]. **Table 6** below shows suggested lead placement based on symptomatic location of pain.

One of the most common complications of SCS is lead migration or damage causing decreased efficacy of treatment [84]. A more rare but potentially catastrophic

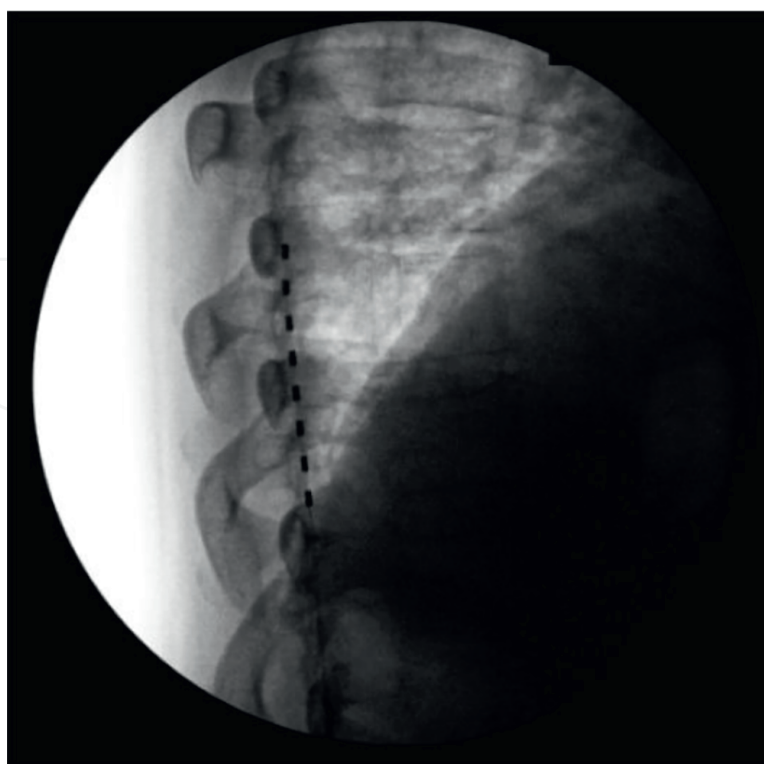


Figure 18.
An example of an image captured during fluoroscopic-guided thoracic epidural spinal cord stimulator leads trial.

Location of Pain	Lead Placement
Neck	C3 and Up
Shoulder	Above C5
Hand	C5-C6
Anterior Thigh	T7, T8, T11-12
Posterior Thigh	T11-L1
Foot	L1
Low Back	T9-T10

Table 6.
Location of pain and associated lead placement for spinal cord stimulation.

complication is a spinal epidural hematoma, which can occur days to weeks after completion of procedure. Spinal epidural hematoma is a medical emergency and should be considered if patient experiences new onset severe back pain and/or neurological impairment [85]. Other complications include spinal cord trauma and tolerance to treatment, particularly in long-term use [86].

The progressing advancement of SCS has allowed for broadening of indications and will likely continue to do so. Placement of the device after a successful trial is usually completed by a Neurosurgeon or Orthopedic Spine surgeon who specializes in this placement, which can lead to a bottleneck in demand for the device placement.

Table 7 provides a summary of this discussion.

Intervention	Indications	Complications
Spinal Cord Stimulator	Refractory to conservative management <ul style="list-style-type: none"> • Failed Back Surgery Syndrome (FBSS, post-laminectomy), usually about 12 months after surgery • Complex Regional Pain Syndrome • Painful diabetic neuropathy • Postherpetic neuralgia • Axial low-back pain In Europe <ul style="list-style-type: none"> • Refractory Angina • Peripheral Vascular Disease 	Decreased Efficacy <ul style="list-style-type: none"> • Lead migration • Instrument damage • Tolerance to treatment Rare but catastrophic <ul style="list-style-type: none"> • Spinal epidural hematoma • Spinal cord trauma

Table 7.
 Common indications and complications of Spinal Cord Stimulators indications.

8. Discussion

The primary goal of the outpatient pain clinic is to help patients improve their quality of life by reducing pain, decreasing dependence on narcotic pain medications, and supporting increased activity levels, thereby allowing a return to a sense of function. Pain may be complex, vague, and wildly subjective, but it can be targeted with a systematic approach that is consistently applied for every patient that presents to the clinic. A thorough history and physical should precede a decision on treatment approach.

The initial evaluation begins with a history of present illness (HPI) and a review of medical history. There are several “red flags” that may significantly alter the treatment plan and warrant further workup; therefore, a thorough history is essential to determine the appropriate treatment approach. When evaluating pain, it is important to take note of location, radiation of pain, duration, quality, severity, exacerbating factors, alleviating factors, history of trauma to the area, as well as the impact this pain has on activities of daily living (ADL). It is also important to note what treatments have already been trialed, including pain medications, external stimulation devices, and surgeries. Pain procedures and alternatives methods are helpful for patients who are not appropriate for more invasive surgical treatment, or for those whom surgery has failed, such as spinal cord stimulators for Failed Back Surgery Syndrome.

The physical exam begins the moment the patient steps foot into the office. General inspection includes overall gait, posture, range of motion, effort, even work of breathing. A neurological exam includes deep tendon reflexes, dermatome and myotome distributions, as well as strength (which can be indicative of neurological and/or musculoskeletal impairment), and tenderness on palpation. Provocation tests are helpful in discerning between symptoms that correlate with more than one etiology and a cluster of positive provocative tests increases accuracy of a diagnosis. For example, if a patient presents with neck pain, a Spurling’s test is sensitive but not specific for acute radiculopathy if pain radiates into ipsilateral arm and Lhermitte is specific but not sensitive for cervical spinal cord compression.

Typically, interventional procedures are considered only after a patient has not improved or has experienced only limited improvement on more conservative measures such as medications and/or physical therapy for about 6 weeks. Those whose pain impedes on their ability to participate in physical therapy may also benefit from interventional procedures. Different prerequisites depend on the proposed treatment, and they are illustrated in the charts below (**Figures 14-18**). It can be argued that some procedures, especially less invasive procedures such as ultrasound-guided large joint injections, may be appropriate before this timeframe if the goal is to prevent dependence on narcotics, polypharmacy, or the multitude adverse effects pain medications can have.

Since back pain is the most commonly presenting chief complaint in an outpatient pain clinic, it is important to differentiate between organic and nonorganic back pain etiologies. Nonorganic back pain is more suspected if three or more of the following symptoms are positive: pain with axial compression or passive rotation, negative straight-leg raise with patient distraction, regional disturbance that does not follow dermatomal distributions, overreactions to physical examination, and non-anatomic specific tenderness. This does not mean this patient is not feeling pain; however, it may mean that certain procedures are not indicated. Avoidance of more invasive procedures would be prudent if organic back pain is ruled out. Patient with nonorganic back pain may benefit from optimization of medical and mental health, perhaps further workup, or appropriate referrals in addition to other treatments such as aforementioned external stimulation devices for distraction therapy, trigger point injections and/or SNRIs for conditions such as fibromyalgia, or even cannabis/CBD.

When a patient's back pain is suspicious for organic causes, it is helpful to keep broad stroke interventional mainstays in mind. Classically, radicular symptoms, spinal stenosis, and discogenic pain improve with ESI, facet joint dysfunction responds well to MBB, and SI joint dysfunction with SI joint injections. Newer interventions include RFA after a certain number of successful MBBs as well as the ablation of SI joint nerve, SCS for FBSS, and even radicular pain may be appropriate. Pain Management Physicians may wait at least 12 months after surgery prior to considering a trial of SCS for FBSS as it may take this long to recover from spinal surgery. External stimulation devices can be used in patients who cannot or will not undergo more invasive procedures. The chart seen in **Figure 19** is a general guide on how an interventionalist can organize the initial presenting symptoms with a potential treatment.

Research regarding number of ESIs prior to indications of surgical intervention is limited. For some interventional pain medicine physicians, surgery may be considered if subsequent ESIs continue to provide waning or minimal levels of relief either by percent of relief or temporal measures. There are multiple reasons why a patient may never be an appropriate candidate for surgery independent of ESI count.

Navigating the course of action, prerequisites and expectations of different treatments can be daunting for both patient and referring physician. The diagrams below illustrate example steps of some of the major interventional pain procedures, from the moment a patient walks into the clinic until day of procedure. The steps to a diagnostic MBB can be seen in **Figure 20** while the prerequisites for radiofrequency ablation of the Medial Branch can be seen in **Figure 21** as well as its continued use for treatment. **Figure 22** shows the process prior to an epidural steroid injection and in **Figure 23** the steps prior to SI joint injection. These may differ in different practices and can change as literature and policies are updated. It should be noted that the initial treatment is sometimes also known as diagnostic since a failure in that treatment may warrant further workup for source of pain.

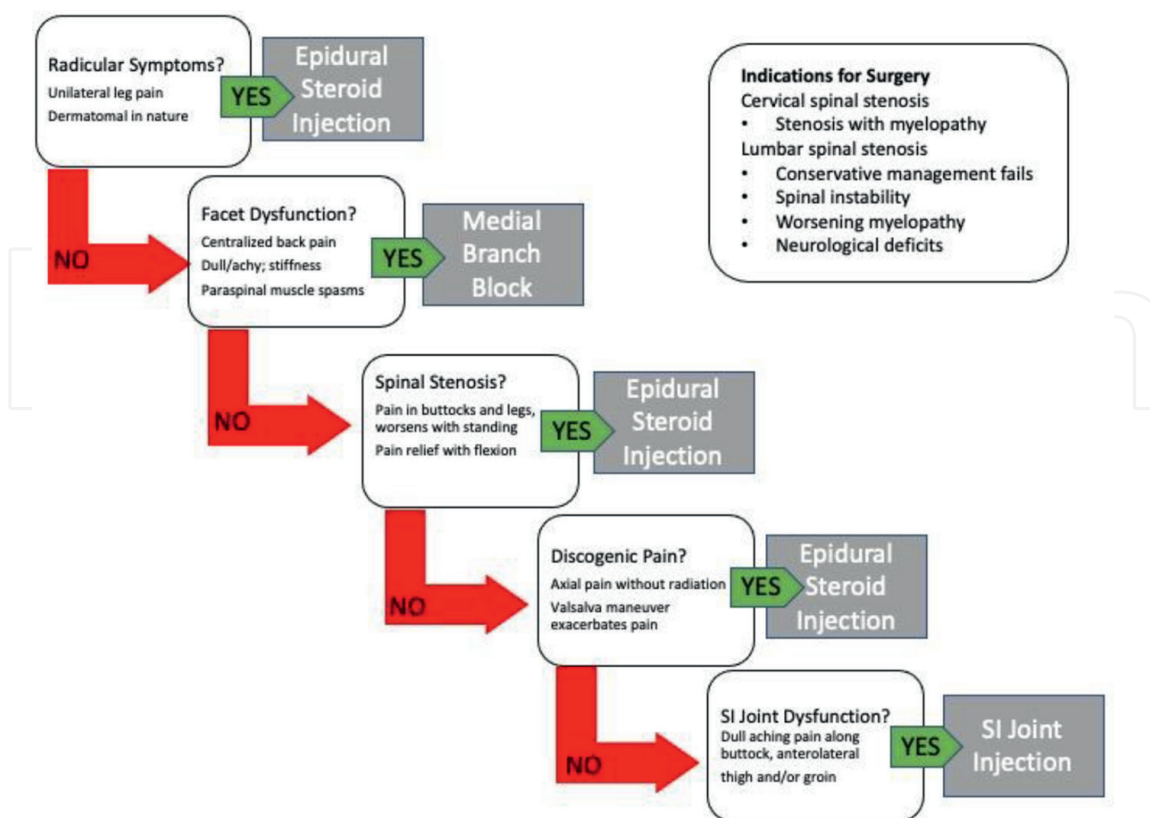


Figure 19.
 An example of a common pathway for epidural steroid injection and SI joint injection.

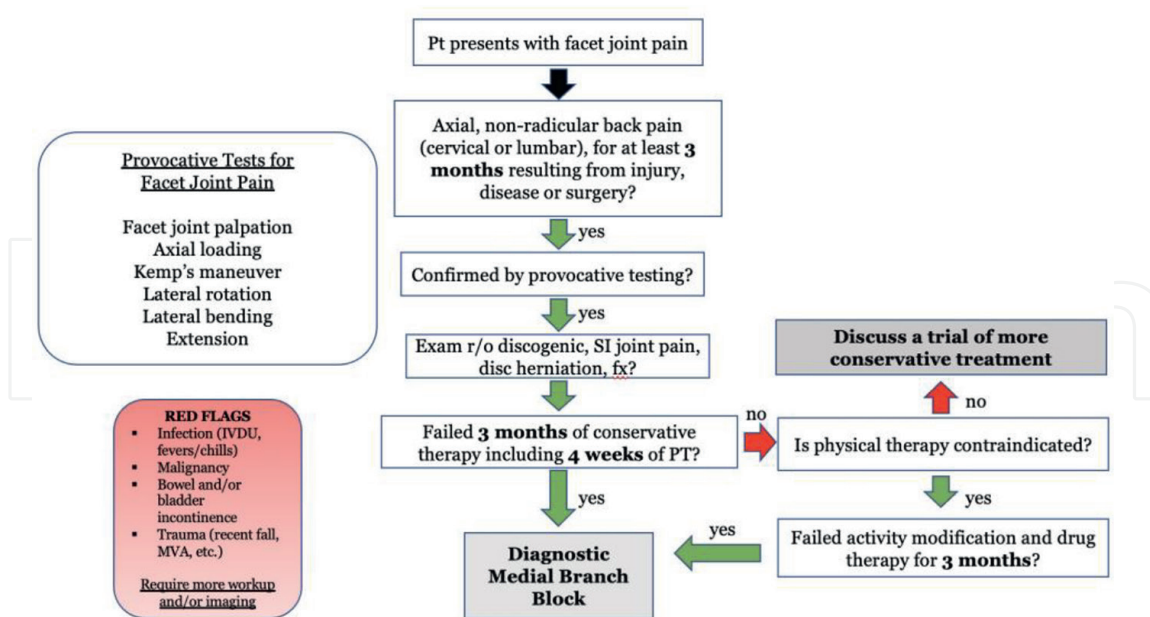


Figure 20.
 An example of a common pathway including requirements prior to a diagnostic MBB.

The benefits pain management contributes to medicine are vast and the potential contributions are boundless. This chapter pays tribute to the foundations of this specialty while highlighting newer innovations and expanding on already-established

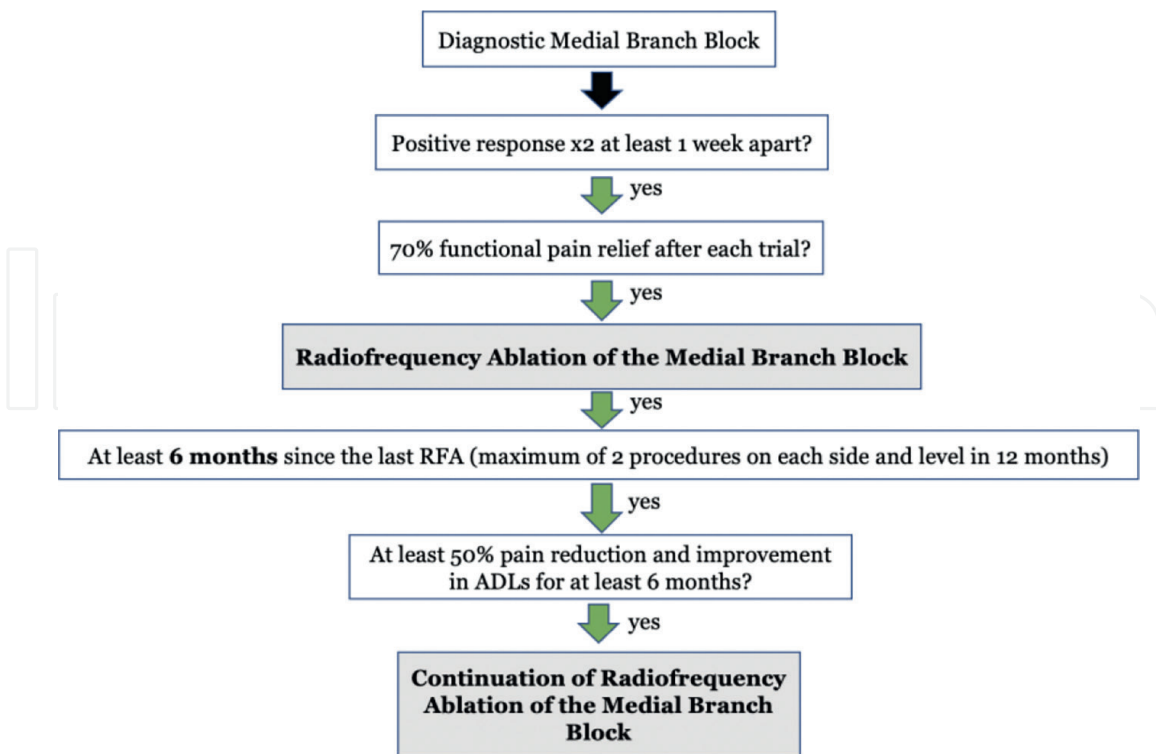


Figure 21.
An example of a common pathway including requirements prior to initial RFA of the MBB and continuation treatment.

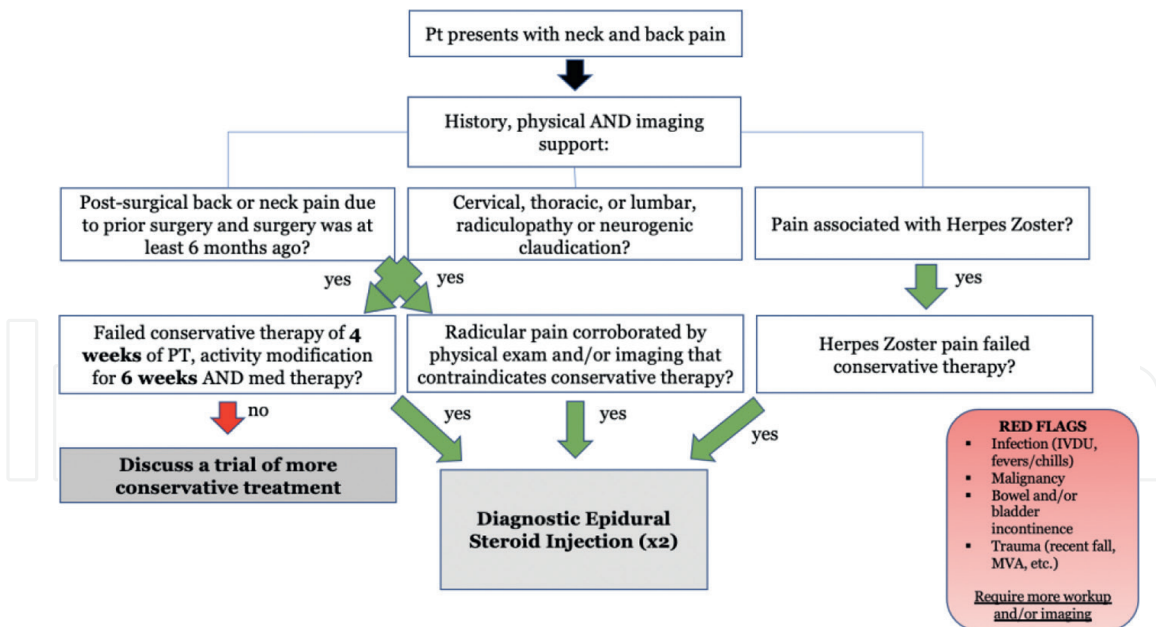


Figure 22.
An example of a common pathway including requirements prior to diagnostic ESI.

modalities that may be safer, faster, and more accessible such as ultrasound-guided procedures or advancement of current technology.

In 2019, COVID-19, a disease caused by the virus SARS-Cov-2, quickly spread resulting in a global pandemic and subsequent lockdown. The organic effects of this disease as well as the mental health consequences may have an interesting effect on the patient population presenting to outpatient pain clinics. The importance of a

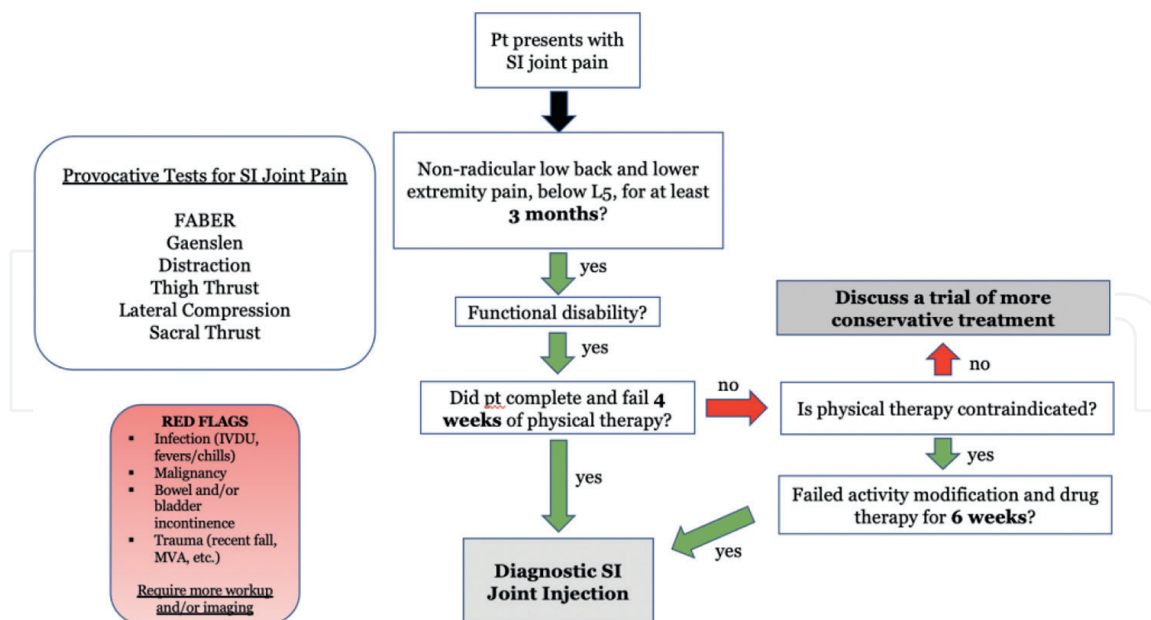


Figure 23.
 An example of a common pathway including requirements prior to diagnostic SI joint injection.

targeted evaluation as well as continued advancement of safer more efficacious treatments, invasive and noninvasive, will likely be more important than ever.

This chapter review is not comprehensive as there is a less detailed focus on already-established procedures such as epidural steroid injections and the multitude of peripheral nerve blocks, which are arguably the pillars of interventional pain management. Instead, this chapter focuses on the innovations that are becoming more common in clinical practice. Since pain management is a robust and advancing field, this chapter may not include newer procedures or lesser studied ones.

There are multiple procedures that have grown out of favor from common practice including discograms as they are painful, facet joint injections as medial branch block, and subsequent ablation provides longer relief for this type of back pain, neurolysis due to its increased risks when compared to neural blockade and ablation, and even intrathecal pumps, which are a good treatment option but require long-term maintenance and troubleshooting.

In contrast, there are forms of therapy such as prolotherapy, which is essentially the repeated injection of irritant or platelet-rich plasma (PRP) injections, which is the injection of autologous platelets into affected joint space to trigger connective tissue growth and/or repair and subsequent theoretical pain relief that are awaiting larger, more in-depth studies prior to acceptance into common practice.

Pain medicine's core specialties include Anesthesiology, Psychiatry, Physical Medicine and Rehabilitation, and Neurology. The diversity of the specialty allows for a multifaceted projection of innovation such as aforementioned prolotherapy and PRP injection as well as the augmentation of the perception of pain and visualizing biomarkers of pain, which expands the scope and impact of outpatient pain management.

9. Conclusions

This chapter briefly describes the mechanism and pathways contributing to the perception of pain before discussing the current pharmacologic and non-pharmacologic

agents that modulate these pathways as well as interventional pain approaches that are becoming more commonly used. In the outpatient pain management clinic, the focus is on subacute to chronic, non-cancer pain—its etiologies, evaluation, and subsequent management including the wide array of noninvasive treatments such as ketamine, external stimulation devices, and CBD, as well as more invasive modalities of treatment. We review the mainstay of interventional pain procedures and highlight its innovations such as radiofrequency ablation and spinal cord stimulators. As more research is conducted and technology advances, it is imperative to update medical health professionals on how to better help patients improve their quality of life and regain their function.

Acknowledgements

Sanjay V. Menghani's training is supported by an F30 Ruth L. Kirschstein individual predoctoral NRSA fellowship from the NIGMS (5F30GM139246-02).

Conflict of interest

The authors declare that the work for this book chapter was conducted in the absence of any commercial or financial relationships that could be considered a conflict of interest.

Author details

Franzes Anne Z. Liongson^{1*}, Rina Bhalodi¹, Christopher McCarthy¹,
Sanjay V. Menghani^{2,3} and Ajaz Siddiqui⁴

1 St. Luke's University Hospital Network (SLUHN), Bethlehem, USA


2 University of Arizona College of Medicine – Tucson, Tucson, USA

3 Medical Scientist Training MD-PhD Program, University of Arizona College of Medicine – Tucson, Tucson, USA

4 Spine and Pain Associates, St. Luke's University Hospital Network (SLUHN), Bethlehem, USA

*Address all correspondence to: franzas.liongson@sluhn.org

IntechOpen

© 2022 The Author(s). Licensee IntechOpen. This chapter is distributed under the terms of the Creative Commons Attribution License (<http://creativecommons.org/licenses/by/3.0>), which permits unrestricted use, distribution, and reproduction in any medium, provided the original work is properly cited. 

References

- [1] Cohen M, Quintner J, van Rysewyk S. Reconsidering the international association for the study of pain definition of pain. *Pain Reports*. 2018;**3**(2):e634
- [2] Basbaum AI, Bautista DM, Scherrer G, Julius D. Cellular and molecular mechanisms of pain. *Cell*. 2009;**139**(2):267-284
- [3] Stucky CL, Dubin AE, Jeske NA, Malin SA, McKemy DD, Story GM. Roles of transient receptor potential channels in pain. *Brain Research Reviews*. 2009;**60**(1):2-23
- [4] Dubin AE, Patapoutian A. Nociceptors: The sensors of the pain pathway. *The Journal of Clinical Investigation*. 2010;**120**(11):3760-3772
- [5] Tominaga M, Caterina MJ, Malmberg AB, Rosen TA, Gilbert H, Skinner K, et al. The cloned capsaicin receptor integrates multiple pain-producing stimuli. *Neuron*. 1998;**21**(3):531-543
- [6] Lawson SN, Waddell PJ. Soma neurofilament immunoreactivity is related to cell size and fibre conduction velocity in rat primary sensory neurons. *The Journal of Physiology*. 1991;**435**:41-63
- [7] Yam MF, Loh YC, Tan CS, Khadijah Adam S, Abdul Manan N, Basir R. General pathways of pain sensation and the major neurotransmitters involved in pain regulation. *International Journal of Molecular Sciences*. 2018;**19**(8):2164
- [8] Pak DJ, Yong RJ, Kaye AD, Urman RD. Chronification of pain: Mechanisms, current understanding, and clinical implications. *Current Pain and Headache Reports*. 2018;**22**(2):9
- [9] Kuner R, Kuner T. Cellular circuits in the brain and their modulation in acute and chronic pain. *Physiological Reviews*. 2021;**101**(1):213-258
- [10] Gaskin DJ, Richard P. The economic costs of pain in the United States. *The Journal of Pain*. 2012;**13**(8):715-724
- [11] Manchikanti L, Singh V, Falco FJ, Benyamin RM, Hirsch JA. Epidemiology of low back pain in adults. *Neuromodulation*. 2014;**17**(Suppl 2):3-10
- [12] Almomani F, Alghwiri AA, Alghadir AH, Al-Momani A, Iqbal A. Prevalence of upper limb pain and disability and its correlates with demographic and personal factors. *Journal of Pain Research*. 2019;**12**:2691-2700
- [13] Lucas J, Connor E, Bose J. Back, lower limb, and upper limb pain among U.S. adults, 2019. *NCHS Data Brief*. 2021;(415):1-8
- [14] Dowell D, Haegerich TM, Chou R. CDC guideline for prescribing opioids for chronic pain - United States, 2016. *MMWR - Recommendations and Reports*. 2016;**65**(1):1-49
- [15] Rosenblum A, Marsch LA, Joseph H, Portenoy RK. Opioids and the treatment of chronic pain: Controversies, current status, and future directions. *Experimental and Clinical Psychopharmacology*. 2008;**16**(5):405-416
- [16] Katz N, Benoit C. Opioids for neuropathic pain. *Current Pain and Headache Reports*. 2005;**9**(3):153-160
- [17] Pergolizzi JV Jr, Labhsetwar SA, Puenpatom RA, Joo S, Ben-Joseph RH,

- Summers KH. Prevalence of exposure to potential CYP450 pharmacokinetic drug-drug interactions among patients with chronic low back pain taking opioids. *Pain Practice*. 2011;**11**(3):230-239
- [18] Edinoff AN, Kaplan LA, Khan S, Petersen M, Sauce E, Causey CD, et al. Full opioid agonists and tramadol: Pharmacological and clinical considerations. *Anesthesiology and Pain Medicine*. 2021;**11**(4):e119156
- [19] Culp C, Kim HK, Abdi S. Ketamine use for cancer and chronic pain management. *Frontiers in Pharmacology*. 2020;**11**:599721
- [20] Nowacka A, Borczyk M. Ketamine applications beyond anesthesia - A literature review. *European Journal of Pharmacology*. 2019;**860**:172547
- [21] Niesters M, Martini C, Dahan A. Ketamine for chronic pain: Risks and benefits. *British Journal of Clinical Pharmacology*. 2014;**77**(2):357-367
- [22] Yang Y, Maher DP, Cohen SP. Emerging concepts on the use of ketamine for chronic pain. *Expert Review of Clinical Pharmacology*. 2020;**13**(2):135-146
- [23] Cohen SP, Bhatia A, Buvanendran A, Schwenk ES, Wasan AD, Hurley RW, et al. Consensus guidelines on the use of intravenous ketamine infusions for chronic pain from The American Society of Regional Anesthesia and Pain Medicine, The American Academy of Pain Medicine, and The American Society of Anesthesiologists. *Regional Anesthesia and Pain Medicine*. 2018;**43**(5):521-546
- [24] Orhurhu V, Orhurhu MS, Bhatia A, Cohen SP. Ketamine infusions for chronic pain: A systematic review and meta-analysis of randomized controlled trials. *Anesthesia and Analgesia*. 2019;**129**(1):241-254
- [25] Bell RF, Kalso EA. Ketamine for pain management. *Pain Reports*. 2018;**3**(5):e674
- [26] Clark JD. Ketamine for chronic pain: Old drug new trick? *Anesthesiology*. 2020;**133**(1):13-15
- [27] Romero-Sandoval EA, Fincham JE, Kolano AL, Sharpe BN, Alvarado-Vázquez PA. Cannabis for chronic pain: Challenges and considerations. *Pharmacotherapy: The Journal of Human Pharmacology and Drug Therapy*. 2018;**38**(6):651-662
- [28] Aviram J, Samuelly-Leichtag G. Efficacy of Cannabis-based medicines for pain management: A systematic review and meta-analysis of randomized controlled trials. *Pain Physician*. 2017;**20**(6):E755-Ee96
- [29] Volkow ND, Baler RD, Compton WM, Weiss SRB. Adverse health effects of marijuana use. *New England Journal of Medicine*. 2014;**370**(23):2219-2227
- [30] Chayasirisobhon S. Mechanisms of action and pharmacokinetics of Cannabis. *The Permanente Journal*. 2021;**25**(1):1-3
- [31] Kim YC, Castañeda AM, Lee CS, Jin HS, Park KS, Moon JY. Efficacy and safety of lidocaine infusion treatment for neuropathic pain: A randomized, double-blind, and placebo-controlled study. *Regional Anesthesia and Pain Medicine*. 2018;**43**(4):415-424
- [32] Masic D, Liang E, Long C, Sterk EJ, Barbas B, Rech MA. Intravenous lidocaine for acute pain: A Systematic Review. *Pharmacotherapy*. 2018;**38**(12):1250-1259

- [33] Thomson PD, Melmon KL, Richardson JA, Cohn K, Steinbrunn W, Cudihee R, et al. Lidocaine pharmacokinetics in advanced heart failure, liver disease, and renal failure in humans. *Annals of Internal Medicine*. 1973;**78**(4):499-508
- [34] Jazayeri SM, Ashraf A, Fini HM, Karimian H, Nasab MV. Efficacy of Botulinum Toxin Type A for Treating Chronic Low Back Pain. 2011;**1**(2):77-80
- [35] Sim WS. Application of botulinum toxin in pain management. *The Korean Journal of Pain*. 2011;**24**(1):1-6
- [36] Khoury AL, Keane H, Varghese F, Hosseini A, Mukhtar R, Eder SE, et al. Trigger point injection for post-mastectomy pain: A simple intervention with high rate of long-term relief. *npj Breast Cancer*. 2021;**7**(1):123
- [37] Borg-Stein J, Iaccarino MA. Myofascial pain syndrome treatments. *Physical Medicine and Rehabilitation Clinics of North America*. 2014;**25**(2):357-374
- [38] Suputtitada A, Chen CPC, Ngamrungsiri N, Schmitz C. Effects of repeated injection of 1% lidocaine vs. radial extracorporeal shock wave therapy for treating myofascial trigger points: A randomized controlled trial. *Medicina*. 2022;**58**(4):479
- [39] Johnson MI, Paley CA, Howe TE, Sluka KA. Transcutaneous electrical nerve stimulation for acute pain. *Cochrane Database of Systematic Reviews*. 2015;**2015**(6):Cd006142
- [40] Bjordal JM, Johnson MI, Ljunggreen AE. Transcutaneous electrical nerve stimulation (TENS) can reduce postoperative analgesic consumption. A meta-analysis with assessment of optimal treatment parameters for postoperative pain. *European Journal of Pain*. 2003;**7**(2):181-188
- [41] Mulvey MR, Bagnall AM, Johnson MI, Marchant PR. Transcutaneous electrical nerve stimulation (TENS) for phantom pain and stump pain following amputation in adults. *Cochrane Database of Systematic Reviews* 2010(5):Cd007264.
- [42] Wu LC, Weng PW, Chen CH, Huang YY, Tsuang YH, Chiang CJ. Literature review and meta-analysis of transcutaneous electrical nerve stimulation in treating chronic back pain. *Regional Anesthesia and Pain Medicine*. 2018;**43**(4):425-433
- [43] Huang J, Yang C, Zhao K, Zhao Z, Chen Y, Wang T, et al. Transcutaneous electrical nerve stimulation in rodent models of neuropathic pain: A meta-analysis. *Frontiers in Neuroscience*. 2022;**16**:831413
- [44] Dias LV, Cordeiro MA, Schmidt de Sales R, Dos Santos M, Korelo RIG, Wojciechowski AS, et al. Immediate analgesic effect of transcutaneous electrical nerve stimulation (TENS) and interferential current (IFC) on chronic low back pain: Randomised placebo-controlled trial. *Journal of Bodywork and Movement Therapies*. 2021;**27**:181-190
- [45] Fuentes JP, Armijo Olivo S, Magee DJ, Gross DP. Effectiveness of interferential current therapy in the management of musculoskeletal pain: A systematic review and meta-analysis. *Physical Therapy*. 2010;**90**(9):1219-1238
- [46] Moore JS, Gibson PR, Burgell RE. Neuromodulation via interferential electrical stimulation as a novel therapy in gastrointestinal motility disorders. *Journal of Neurogastroenterology and Motility*. 2018;**24**(1):19-29
- [47] Yang X, He H, Ye W, Perry TA, He C. Effects of pulsed electromagnetic field therapy on pain, stiffness, physical function, and quality of life in patients

- with osteoarthritis: A systematic review and meta-analysis of randomized placebo-controlled trials. *Physical Therapy*. 2020;**100**(7):1118-1131
- [48] Ross C, Overholt T, Xu R, Badlani G, Evans RJ, Matthews CA, et al. Pulsed electromagnetic field (PEMF) as an adjunct therapy for pain management in interstitial cystitis/bladder pain syndrome. *International Urogynecology Journal*. 2022;**33**(3):487-491
- [49] Tepper OM, Callaghan MJ, Chang EI, Galiano RD, Bhatt KA, Baharestani S, et al. Electromagnetic fields increase in vitro and in vivo angiogenesis through endothelial release of FGF-2. *The FASEB Journal*. 2004;**18**(11):1231-1233
- [50] Schnoke M, Midura RJ. Pulsed electromagnetic fields rapidly modulate intracellular signaling events in osteoblastic cells: Comparison to parathyroid hormone and insulin. *Journal of Orthopaedic Research*. 2007;**25**(7):933-940
- [51] Capone F, Dileone M, Profice P, Pilato F, Musumeci G, Minicuci G, et al. Does exposure to extremely low frequency magnetic fields produce functional changes in human brain? *Journal of Neural Transmission*. 2009;**116**(3):257-265
- [52] Martiny K, Lunde M, Bech P. Transcranial low voltage pulsed electromagnetic fields in patients with treatment-resistant depression. *Biological Psychiatry*. 2010;**68**(2):163-169
- [53] Hug K, Rösli M. Therapeutic effects of whole-body devices applying pulsed electromagnetic fields (PEMF): A systematic literature review. *Bioelectromagnetics*. 2012;**33**(2):95-105
- [54] Page MJ, Green S, Mrocki MA, Surace SJ, Deitch J, McBain B, et al. Electrotherapy modalities for rotator cuff disease. *Cochrane Database of Systematic Reviews*. 2016;**2016**(6):Cd012225
- [55] Rabini A, Piazzini DB, Tancredi G, Foti C, Milano G, Ronconi G, et al. Deep heating therapy via microwave diathermy relieves pain and improves physical function in patients with knee osteoarthritis: A double-blind randomized clinical trial. *European Journal of Physical and Rehabilitation Medicine*. 2012;**48**(4):549-559
- [56] Ferreira RM, Torres RT, Duarte JA, Gonçalves RS. Non-pharmacological and non-surgical interventions for knee osteoarthritis: A systematic review and meta-analysis. *Acta Reumatológica Portuguesa*. 2019;**44**(3):173-217
- [57] Fu T, Lineaweaver WC, Zhang F, Zhang J. Role of shortwave and microwave diathermy in peripheral neuropathy. *The Journal of International Medical Research*. 2019;**47**(8):3569-3579
- [58] Dieleman JL, Cao J, Chapin A, Chen C, Li Z, Liu A, et al. US health care spending by payer and health condition, 1996-2016. *Journal of the American Medical Association*. 2020;**323**(9):863-884
- [59] Manchikanti L, Knezevic NN, Boswell MV, Kaye AD, Hirsch JA. Epidural injections for lumbar radiculopathy and spinal stenosis: A comparative systematic review and meta-analysis. *Pain Physician*. 2016;**19**(3):E365-E410
- [60] Pountos I, Georgouli T, Blokhuis TJ, Pape HC, Giannoudis PV. Pharmacological agents and impairment of fracture healing: What is the evidence? *Injury*. 2008;**39**(4):384-394
- [61] Tetzlaff JE. The pharmacology of local anesthetics. *Anesthesiology Clinics of North America*. 2000;**18**(2):217-233 v

- [62] Neal JM, Brull R, Chan VW, Grant SA, Horn JL, Liu SS, et al. The ASRA evidence-based medicine assessment of ultrasound-guided regional anesthesia and pain medicine: Executive summary. *Regional Anesthesia and Pain Medicine*. 2010;**35**(2 Suppl):S1-S9
- [63] Glenister R, Anatomy SS. Bony Pelvis and Lower Limb, Hip. In: *StatPearls*. Treasure Island (FL): StatPearls Publishing LLC; 2022
- [64] Cox RC, Fortin JD. The anatomy of the lateral branches of the sacral dorsal rami: Implications for radiofrequency ablation. *Pain Physician*. 2014;**17**(5):459-464
- [65] Harmon D, O'Sullivan M. Ultrasound-guided sacroiliac joint injection technique. *Pain Physician*. 2008;**11**(4):543-547
- [66] Polly DW Jr. The sacroiliac joint. *Neurosurgery Clinics of North America*. 2017;**28**(3):301-312
- [67] Xavier J, Pinho S, Silva J, Nunes CS, Cabido H, Fortuna R, et al. Postdural puncture headache in the obstetric population: A new approach? *Regional Anesthesia & Pain Medicine*. 2020;**45**(5):373
- [68] Fernandes L, Randall M. Idrovo L Peripheral nerve blocks for headache disorders *Practical Neurology*. 2021;**21**:30-35
- [69] Brandt RB, Doesborg PGG, Meilof R, de Coö IF, Bartels E, Ferrari MD, et al. Repeated greater occipital nerve injections with corticosteroids in medically intractable chronic cluster headache: A retrospective study. *Neurological Sciences*. Feb 2022;**43**(2):1267-1272
- [70] Lavin PJ, Workman R. Cushing syndrome induced by serial occipital nerve blocks containing corticosteroids. *Headache*. 2001;**41**(9):902-904
- [71] Rana MV, Candido KD, Raja O, Knezevic NN. Celiac plexus block in the management of chronic abdominal pain. *Current Pain and Headache Reports*. 2014;**18**(2):394
- [72] Rosland JH, Geitung JT. CT guided neurolytic blockade of the coeliac plexus in patients with advanced and intractably painful pancreatic cancer. *Scandinavian Journal of Pain*. 2018;**18**(2):247-251
- [73] Kambadakone A, Thabet A, Gervais DA, Mueller PR, Arellano RS. CT-guided celiac plexus neurolysis: A review of anatomy, indications, technique, and tips for successful treatment. *Radiographics*. 2011;**31**(6):1599-1621
- [74] Minaga K, Takenaka M, Kamata K, Yoshikawa T, Nakai A, Omoto S, et al. Alleviating pancreatic cancer-associated pain using endoscopic ultrasound-guided neurolysis. *Cancers*. 2018;**10**(2):1-17
- [75] Yousefshahi F, Tahmasebi M. Long-lasting orthostatic hypotension and constipation after celiac plexus block; A case report. *Anesth Pain Medicine*. 2018;**8**(1):e63221
- [76] Hou S, Novy D, Felice F, Koyyalagunta D. Efficacy of superior hypogastric plexus neurolysis for the treatment of cancer-related pelvic pain. *Pain Medicine*. 2019;**21**(6):1255-1262
- [77] Stogicza AR. *Interventional Pain: A Step-by-step Guide for the FIPP Exam*. 1st ed 1 online resource (XVIII, 205 p. 148 illus., 80 illus. in color.) p
- [78] Cohen SP, Doshi TL, Constantinescu OC, Zhao Z, Kurihara C, Larkin TM, et al. Effectiveness of lumbar facet joint blocks and predictive value before radiofrequency denervation: The facet treatment study (FACTS), a randomized, controlled clinical trial. *Anesthesiology*. 2018;**129**(3):517-535

[79] Maas ET, Juch JNS, Ostelo R, Groeneweg JG, Kallewaard JW, Koes BW, et al. Cost-effectiveness of radiofrequency denervation for patients with chronic low back pain: The MINT randomized clinical trials. *Value in Health*. 2020;**23**(5):585-594

[80] Lee CH, Chung CK, Kim CH. The efficacy of conventional radiofrequency denervation in patients with chronic low back pain originating from the facet joints: A meta-analysis of randomized controlled trials. *The Spine Journal*. 2017;**17**(11):1770-1780

[81] Caylor J, Reddy R, Yin S, Cui C, Huang M, Huang C, et al. Spinal cord stimulation in chronic pain: Evidence and theory for mechanisms of action. *Bioelectronic Medicine*. 2019;**5**(1):12

[82] Deer TR, Mekhail N, Provenzano D, Pope J, Krames E, Leong M, et al. The appropriate use of neurostimulation of the spinal cord and peripheral nervous system for the treatment of chronic pain and ischemic diseases: The neuromodulation appropriateness consensus committee. *Neuromodulation*. 2014;**17**(6):515-550 discussion 50

[83] Barolat G, Massaro F, He J, Zeme S, Ketcik B. Mapping of sensory responses to epidural stimulation of the intraspinal neural structures in man. *Journal of Neurosurgery*. 1993;**78**(2):233-239

[84] Kumar K, Buchser E, Linderoth B, Meglio M, Van Buyten JP. Avoiding complications from spinal cord stimulation: Practical recommendations from an international panel of experts. *Neuromodulation*. 2007;**10**(1):24-33

[85] Franzini A, Ferroli P, Marras C, Broggi G. Huge epidural hematoma after surgery for spinal cord stimulation. *Acta Neurochirurgica*. 2005;**147**(5):565-567 discussion 7

[86] Hayek SM, Veizi E, Hanes M. Treatment-limiting complications of percutaneous spinal cord stimulator implants: A review of eight years of experience from an academic center database. *Neuromodulation*. 2015;**18**(7):603-608 discussion 8-9