



## *Moringa oleifera* seeds attenuate benzene-induced alterations in lipid peroxidation and antioxidant enzymes in liver and kidney tissues of Wistar rats

R Rajkumar<sup>1</sup>, B Ilango<sup>2</sup>, K Vinothkumar<sup>3</sup>, R Savidha<sup>4</sup>, S Senthilkumar<sup>5</sup>, D Ezhilarasan<sup>6</sup> & E Sukumar<sup>3\*</sup>

<sup>1</sup>A2 Pathlabs India Private Limited, Tatabad, Coimbatore-641 012, Tamil Nadu, India

<sup>2</sup>Department of Pediatrics, Division of Hematology/Oncology/BMT, University of Colorado, Aurora-80045, USA

<sup>3</sup>Research & Development, VPro Biotech, Arumparthapuram Main Road, Puducherry-605 110, Union Territory, India

<sup>4</sup>Department of Chemistry, Providence College for Women, Coonoor, Ooty-643 104, Tamil Nadu, India

<sup>5</sup>Department of Research and Development, Saveetha Institute of Medical and Technical Sciences (Deemed University), Thandalam Campus, Chennai-602 105, Tamil Nadu, India

<sup>6</sup>Department of Pharmacology, Saveetha Dental College and Hospitals, Saveetha Institute of Medical and Technical Sciences (Deemed University), Chennai-600 077, Tamil Nadu, India

Received 10 October 2021; revised 13 December 2022

Benzene is a notorious toxicant that is responsible for a host of diseases including leukemia. Its concentration in the environment is increasing day-by-day due to excessive automobile use, accelerated industrial activities and cigarette smoke. The awareness on the harmful effects of benzene on health is limited and no antidote has been reported yet. In this study, an attempt has been made to find out a suitable remedy to overcome benzene toxicity in a living organism from a natural source with the seeds of the plant *Moringa oleifera* (MO). Thirty six Wistar rats were considered for the study and divided into six groups (n=6). While group I remained as control with normal animals, those in groups II – VI received benzene by oral route (800 mg/kg body weight) for 28 consecutive days. On day 29, the benzene-treated animals in groups III – VI received respectively the standard drug ascorbic acid (AA, 25 mg/kg body weight) and MO (50, 100 and 200 mg/kg body weight) for the following 7 days. Group II rats that received only benzene served as negative control without any treatment. On day 36, all the animals were sacrificed and vital organs liver and kidney were removed for studying lipid peroxidation (LPO) and antioxidant markers [Superoxide dismutase (SOD), Total reduced glutathione (TRG), Glutathione peroxidase (GPx) and Catalase (CAT)] in addition to histopathological changes in the tissues. The results of the study revealed that significant changes occurred in the above parameters due to benzene dosing to animals were reverted to near normal values on MO administration in the liver and kidney tissues as compared to untreated animals, suggesting MO's pro-active role in attenuating benzene toxicity.

**Keywords:** Animal model, Chemical toxicity, Enzymes, Histopathology, Lipid peroxidation, *Moringa* seeds

Benzene (Bz) is one of the world's major industrial chemicals used in the manufacture of a wide variety of domestic and industrial products. Gasoline used in the automobiles contains as high as 5% benzene to maintain optimum octane levels and antiknock properties<sup>1</sup>. Due to these factors, it is ubiquitous in environment frequently found in air, water and human biological samples<sup>2</sup>. It is a hematopoietic poison and bone marrow depressant<sup>3</sup> besides being an immunotoxicant<sup>4</sup>. The chemical has many adverse clinical effects that are well documented in the literature<sup>5</sup>.

Of late, increased attention is focused on countering toxicity-related issues with environment friendly<sup>6</sup> as well as natural materials having antioxidant properties. The

latter can significantly reduce free radical damage to the tissues<sup>7</sup>. In continuation of our earlier work on tackling toxicity issues with plant products<sup>8,9</sup>, this investigation was undertaken with the seeds of *M. oleifera* (MO) for studying their effect on benzene-induced alterations in vital parameters in rat model. This work assumes importance as so far very limited work has been done in finding antidotes for benzene poisoning. *M. oleifera* Lam. (Syn: *M. pterygosperma* Gaertn.; Family: Moringaceae), locally known as Horsh radish tree or Drum stick tree, is a medium sized, drought resistant plant that grows in almost all types of soils and cultivated all over India. The plant is grown by Indian families as a vegetable and all its parts possess nutritive and medicinal values. The seeds are reported to exhibit antipyretic properties while the oil of seeds is used in rheumatism and gout as external application<sup>10</sup>.

\*Correspondence:  
E-mail: drsuku3@gmail.com

## Materials and Methods

### Chemical, plant material and animals

Commercially available benzene was procured from S D Fine Chemicals, Mumbai. *M. oleifera* fruits were purchased from the local market and authenticated by a taxonomist. The seeds were separated from fruits, shade-dried, ground well with mortar and pestle and sieved to get a fine powder. Adult male Wistar rats (180-190 g) were obtained from Tamil Nadu University of Veterinary and Animal Sciences, Chennai and maintained according to the guidelines of CPCSEA. Necessary permission for the study was obtained from the Institutional Animal Ethics Committee (No.: BRULAC/SDCH/SIMATS/IAEC/4-2017/06). The animals were fed with commercial pellet feed (supplied by Poultry Research Station, Chennai) and water was provided *ad libitum*.

### Experimental protocol

Thirty six animals were randomly segregated into six groups (n=6) with Group-I as control that received only food and water. Remaining animals received 800 mg/kg of body weight of benzene, suspended in corn oil administered orally by intubation for a period of 28 consecutive days (This highest dose of benzene was found to cause toxic effects in rats as reported in the previous studies<sup>11-13</sup>). On day 29, benzene exposed animals were further divided into five more groups (II – VI) and treated for seven days as follows. Ascorbic acid (AA), a natural antioxidant has been included as a standard drug in the study and its dosage was fixed based on the earlier report<sup>14</sup>.

- Group I --- Normal Control
- Group II --- Bz treated (800 mg/kg bw, p. o.)
- Group III --- Bz + AA (25 mg/kg bw, p. o.)
- Group IV --- Bz + MO (50 mg/kg bw, p. o.)
- Group V --- Bz + MO (100 mg/kg bw, p. o.)
- Group VI --- Bz + MO (200 mg/kg bw, p. o.)

### Estimation of lipid peroxidation and antioxidant enzymes

On day 36, overnight fasted animals were sacrificed under light ether anesthesia and dissected to remove liver and kidney. They were weighed separately and stored. A portion of the tissue of known weight was cut into small pieces with sharp scissors and homogenized in cold condition with 0.01M Tris HCL buffer (pH 7.4), using a high speed potter – Elevehjem Teflon Homogenizer to obtain a 10% homogenate<sup>15</sup>. Aliquots of this homogenate were used for estimating LPO, TRG, SOD, GPx and CAT

by established methods<sup>16-20</sup>. The enzyme assays were completed within 24 h of sacrifice of rats.

### Histopathological studies

From the remaining tissues of the liver and kidney, sizeable portions were excised, cut into small pieces and fixed in phosphate-buffered formal saline. Then they were dehydrated and fixed in paraffin wax as blocks. The wax blocks were sectioned (8 micron thickness), spread on glass slides, after a series of water and ethanol wash, hematoxylin and eosin staining was done. The stained slides were de-stained and mounted<sup>21</sup>.

### Statistical analysis

The data obtained from the experiments were analyzed by One way analysis of variance (ANOVA) followed by Dunnett's *t*-test for multiple comparisons and expressed as mean  $\pm$  SD of six observations. Values with *P* < 0.05 were considered to be significant.

## Results

The liver tissues of benzene treated animals (Group-II) showed a significant increase in LPO, SOD and GPx while TRG and CAT were decreased when compared to the control animals. The kidney tissues also showed the same pattern except TRG, which increased due to benzene toxicity (Fig. 1).

Ascorbic acid treatment in benzene exposed rats (Group-III) revealed a significant decrease in LPO and SOD levels in liver whereas TRG, GPx and CAT were elevated and found statistically significant. In kidney, the LPO, SOD, GPx and CAT showed a significant decrease, whereas an increase in TRG was noted.

MO treatment showed a dose dependent decrease in LPO and SOD in liver. TRG and CAT showed a decrease in 50 mg/kg group but increased in 100 and 200 mg/kg doses. GPx showed a dose dependent increase when compared to benzene exposed rats (Group-II). MO treated rats showed a significant decrease in LPO levels in kidney whereas TRG and CAT showed a significant decrease in all the doses.

In histopathological studies, the control liver tissues showed normal architecture while chronic benzene exposure caused sinusoidal congestion and inflammatory changes around the central vein of the liver. Benzene pre-exposed rats treated with ascorbic acid did not show full recovery. However, benzene induced inflammatory changes in other groups were markedly reduced after the administration of 50, 100

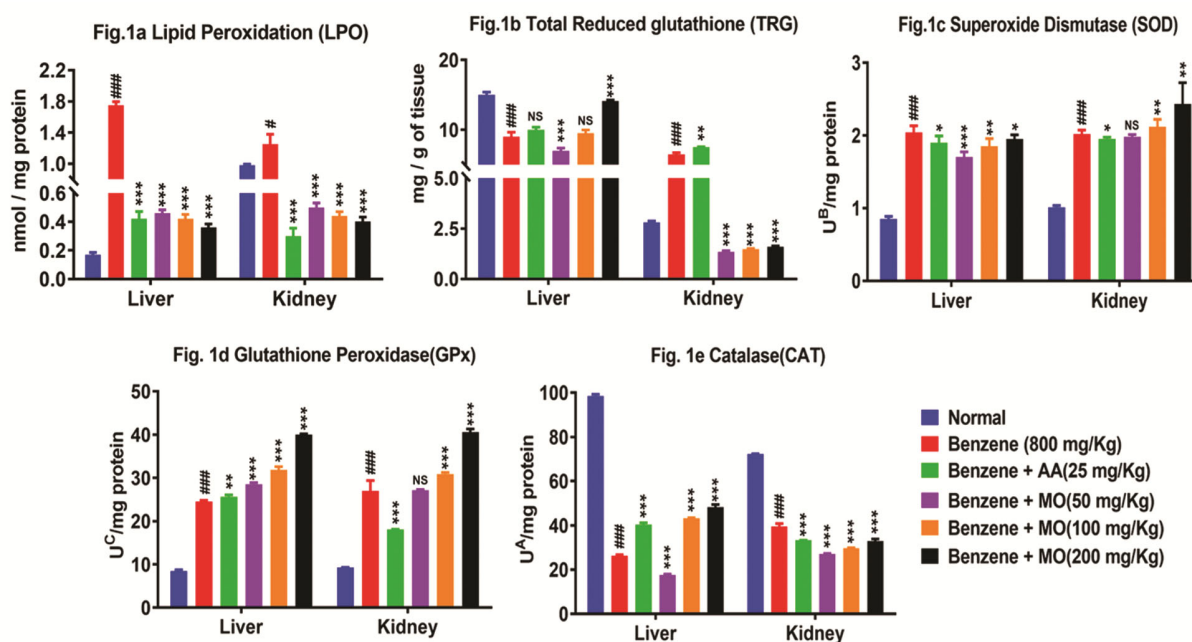


Fig. 1 — Effect of benzene on the liver and kidney tissues of rats. Values represent mean  $\pm$  SD of six animals. # – Compared with control rats, ###  $P < 0.001$ ; \* - Compared with benzene treated rats; \*  $P < 0.05$ , \*\*  $P < 0.01$ , \*\*\*  $P < 0.001$ ; NS -Non-significant. LPO - Lipid peroxidation (nmol/mg protein); TRG - Total reduced glutathione (mg/g of tissue); SOD - Superoxide dismutase (UB/mg protein); GPx - Glutathione peroxidase (UC/mg protein); CAT – Catalase (UA/mg protein)  $U^A$  -  $\mu$ moles of  $H_2O_2$  utilized/sec/mg protein;  $U^B$  - Amount of enzyme required to give 50% inhibition of NBT reduction;  $U^C$  -  $\mu$ moles of GSH utilized/minute

and 200 mg/kg of MO. The control kidney tissues showed normal tubular architecture with intact glomerulus. Benzene intoxication caused lobular epithelial swelling and glomerular congestion. AA and MO treatments especially at high doses (100 and 200 mg/kg) reversed the benzene-induced nephrotoxicity to near normalcy (Fig. 2).

## Discussion

Benzene toxicity and related issues pose great challenge to scientists and clinicians all over the world. The environmental issues due to this highly harmful pollutant are not widely discussed and no suitable remedial measures to overcome the toxicity issues have been reported till date. At times, benzene toxicity affects even the community as a whole. For example, the drinking water supplied in Lanzhou province of China has been found to contain excessive levels of benzene (200  $\mu$ g/L), about 20 times more than the National limit<sup>22</sup> which has been later found to be caused by a leak in the pipeline<sup>23</sup>. Unknowingly these pollutants messed up with every day used items leading to many clinical conditions.

In the present study, the seed powder of *M. oleifera* (MO) has been considered for exploring its

antioxidant potential in benzene pre-treated rats. Administration of MO in various doses caused significant reduction in LPO and notable changes in antioxidant enzymes in the tissues of liver and kidney of benzene pre-treated animals as compared to untreated ones confirming its remedial role in combating toxic effects. Cell and tissue destruction can often lead to more lipid peroxidation as antioxidants are diluted out and transition metal ions that can stimulate the peroxidation process are released from the disrupted cells<sup>24</sup>. In the present study, the levels of LPO increased in the liver of benzene treated rats, evincing the fact that benzene toxicity increased free radical production in tissues. Antioxidant enzymes undergo changes during oxidative stress and involve in the elimination of reactive oxygen species<sup>25</sup> accounting for the increase of SOD, GPx and decrease of TRG and CAT levels as observed in this study on benzene exposure.

Treatment with AA or MO inhibited LPO significantly and normalized TRG status indicating a form of adaptation by the system to counteract the oxidative stress. Liver is viewed as a glutathione-generating organ, which supplies the kidney and intestine with other constituents for glutathione re-synthesis. Intra-hepatic glutathione serves as a

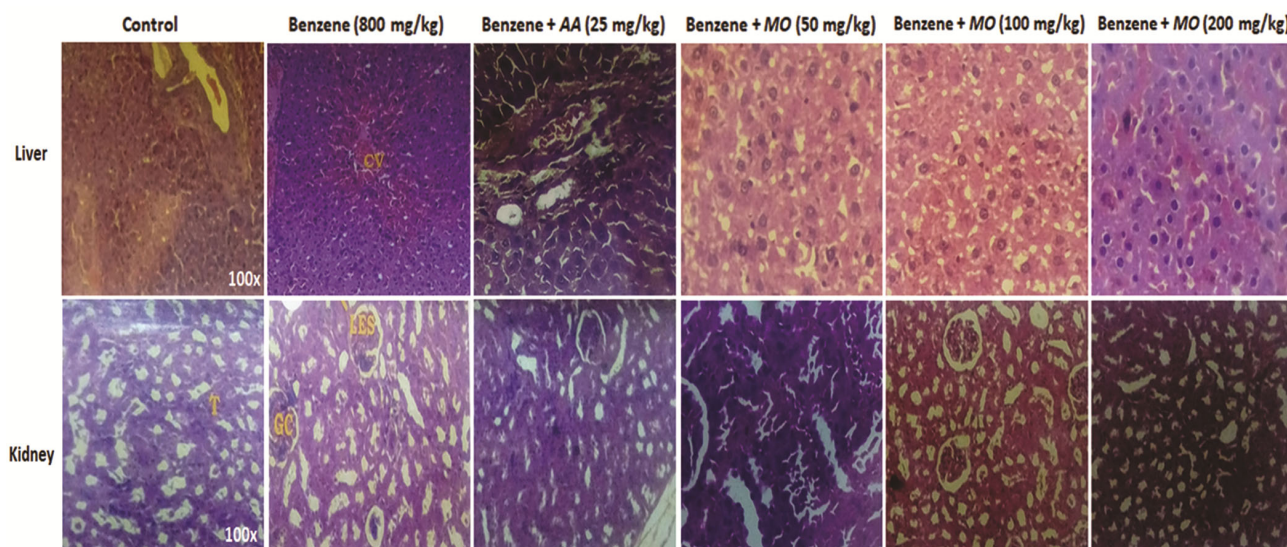


Fig. 2 — Histopathology of liver and kidney tissues of rats. CV – Central vein, GC – Glomerular congestion, T – Urinary tubules, LEC – Lobular epithelial swelling

substrate for glutathione peroxidase and reduces a large variety of hydroperoxides. Reduced glutathione as substrate of glutathione-S-transferase enables the liver to detoxify many exogenous compounds<sup>26</sup>. TRG, a reasonable marker in the evaluation of oxidative stress is important as it acts as antioxidant both extracellularly and intracellularly<sup>27</sup>.

Increased levels of SOD and decrease in CAT, TRG were found in benzene exposed rats which are in accordance with the earlier reported observations that SOD, an enzymatic antioxidant, catalytically scavenges the superoxide radical providing first line of defense against the free radical damage<sup>28</sup>. SOD eliminates oxygen giving rise to hydrogen peroxide that can be destroyed either by CAT, GPx or glutathione-S-transferase consisting of basic defensive system against oxidative stress. On treatment with AA or MO, the levels of SOD in liver have increased which might be due to anti-lipidperoxidation and antioxidant properties of AA and MO.

Glutathione peroxidase (GPx) plays an important role in the protection of cells from damage caused by intracellular process<sup>19</sup>. Elevated level of GPx was observed in benzene treated rats and it increased further on the administration of AA and MO. The increase of GPx levels and subsequent decrease of LPO might be due to the antioxidant properties of MO. This observation is in agreement with the earlier studies that indicated the role of glutathione peroxidase system in removing lipid peroxides as and when formed thereby preventing lipid degradation

and membrane disordering<sup>29</sup>. It was found that GPx is probably responsible for most of the decomposition of peroxides in liver cells protecting the latter from deleterious effects of peroxides<sup>30</sup>.

Catalase is a heme protein localized in the peroxisomes. It forms a major antioxidant defense component that catalyses the decomposition of hydrogen peroxide to water and oxygen apart from protecting the cell from oxidative damage<sup>31</sup>. A drastic decline of CAT in benzene treated rats is in agreement with the earlier study<sup>32</sup>. Catalase, a flavin linked oxidase, efficiently detoxifies hydrogen peroxide when the latter exceeds normal levels. Administration of AA or MO in various doses brought increased CAT levels to near normal values.

In the histopathological studies of liver and kidney tissues, AA and MO treatments especially at high doses (100 and 200 mg/kg) significantly reversed the benzene-induced hepato and nephrotoxic changes to near normalcy. There were no apparent benzene-induced lesions observed after AA and MO post-treatments. The ameliorative potential of MO could be attributed to its inherent antioxidant and membrane stabilizing properties. Thus histopathological investigations also supported the results obtained from biochemical studies.

## Conclusion

Benzene toxicity is a compounding problem that affects the society as a whole and the menace is showing an increasing trend day by day. Many people are unaware of the serious impacts caused by the



pollutant. As overcoming this issue through natural materials is the subtle way, the seeds of *M. oleifera* have been studied for their remedial action in animal model. The results of the study clearly indicated the pro-active role of *M. oleifera* seeds in combating benzene toxicity. Studies of this type on cost effective and easily available materials as antidotes to overcome toxicity issues shall pave way for finding more and more useful agents from natural sources in future.

### Conflict of interest

All authors declare no conflict of interest.

### References

- Manno M, Update on benzene: from industrial toxicant to environmental carcinogen. *G Ital Med Lav Ergon*, 35 (2013) 247.
- Conte S, Lagacé F, Netchiporouk E, Sasseville D & Litvinov IV, Benzene, a Known Human Carcinogen, Detected in Suncare Products. *J Cutan Med Surg*, 25 (2021) 650.
- Sun R, Xu K, Ji S, Pu Y, Yu L, Yin L, Zhang J & Pu Y, Toxicity in hematopoietic stem cells from bone marrow and peripheral blood in mice after benzene exposure: Single-cell transcriptome sequencing analysis. *Ecotoxicol Environ Saf*, 207 (2021) 111490.
- Qiao Y, Zhao Y, Wang G, Song Y, Wei Z, Jin M, Yang D, Yin J, Li J & Liu W, Protection from benzene-induced immune dysfunction in mice. *Toxicology*, 468 (2022) 153103.
- Rana SV & Verma Y, Biochemical toxicity of benzene. *J Environ Biol*, 26 (2005) 157.
- Shubham, Role of biologically synthesized nanoparticles in environmental pollution remediation. *Indian J Biochem Biophys*, 59 (2022) 1148.
- Gupta R & Flora SJS, Protective value of *Aloe vera* against some toxic effects of arsenic in rats. *Phytother Res*, 19 (2005) 23.
- Rajkumar R, Sharief SD, Vinothkumar K, Ilango B & Sukumar E, Effect of *Emblica officinalis* fruits in lowering bioaccumulation of lead in rats. *Pollut Res*, 29 (2010) 441.
- Rajkumar R, Ilango B, Savidha R, Vinothkumar K, Ezhilarasan D & Sukumar E, Effect of *Emblica officinalis* fruits against metallic-lead induced biochemical and hematological alterations in Wistar rats. *Indian J Biochem Biophys*, 58 (2021) 451.
- Anonymous, *The Wealth of India – A Dictionary of Indian Raw Materials and Industrial Products*, Vol. 6, Council of Scientific and Industrial Research - Nisclair, New Delhi, (2009) 426.
- Heijne, WHM, Jonjer D, Stierum RH, Ommen BV & Groten JP, Toxicogenomic analysis of gene expression changes in rat liver after a 28-day oral benzene exposure. *Mut Res*, 575 (2005) 85.
- Hasegawa R, Koizumi HM, Takahasi M, Kamata E & Ema M, Comparative susceptibility of new born and young rats to six industrial chemicals. *Congenit Anom (Kyoto)*, 45 (2005) 137.
- Wilbur S, Wohlers D, Paikoff S, Keith LS & Faron O, ATSDR evaluation of potential for human exposure to benzene. *Toxicol Ind Health*, 24 (2008) 399.
- Elmore AR & Andersen FA, Final report on the safety assessment of L-ascorbic acid, Calcium ascorbate, Magnesium ascorbate, Magnesium ascorbyl phosphate, Sodium ascorbate and Sodium ascorbyl phosphate as used in cosmetics. *Int J Toxicol*, 24 Suppl 2 (2005) 51.
- Simpson RJ, Homogenization of mammalian tissue. *Cold Spring Harbor Protocols*, 2010.
- Ohokawa H, Ohisi N & Yagi K, Assay for lipid peroxides in animal tissues by thiobarbituric acid reaction. *Analyt Biochem*, 95 (1979) 351.
- Moron MS, Despierra JW & Mannervik B, Levels of Glutathione reductase and glutathione-S- transferase activities in rat lung and liver. *Biochem Biophys Acta*, 582 (1979) 67.
- Marklund S & Marklund G, Involvement of superoxide anion radical in the auto-oxidation of pyrogallol and a convenient assay for superoxide. *Eur J Biochem*, 47 (1974) 469.
- Rotruck JT, Pope AL, Ganther HE, Swanson AB, Hafeman DG & Hoekstra WG, Selenium: Biochemical role as a component of glutathione peroxidase. *Science*, 179 (1973) 588.
- Sinha AK, Colorimetric assay of catalase. *Analyt Biochem*, 47 (1972) 389.
- Bancroft JD & Cook BC, Manual of Histological Techniques. Churchill Livingstone, Edinburgh, 1984, pp. 49.
- China faces toxic water chaos now. *Deccan Chronicle* (National Daily of India), April 12, 2014.
- Oil company blamed for toxic tap water in China. [www.phys.org/news/2014-04-oil-company-blamed-toxic-China.html](http://www.phys.org/news/2014-04-oil-company-blamed-toxic-China.html).
- Ito F, Sono Y & Ito T, Measurement and Clinical Significance of Lipid Peroxidation as a Biomarker of Oxidative Stress: Oxidative Stress in Diabetes, Atherosclerosis, and Chronic Inflammation. *Antioxidants (Basel)*, 8 (2019) 72.
- Forman HJ & Zhang H, Targeting oxidative stress in disease: promise and limitations of antioxidant therapy. *Nat Rev Drug Discov*, 20 (2021) 689.
- Pizzorno J, Glutathione! *Integr Med (Encinitas)*, 13 (2014) 8.
- Mandal PK, Roy RG & Samkaria A, Oxidative Stress: Glutathione and Its Potential to Protect Methionine-35 of Aβ Peptide from Oxidation. *ACS Omega*, 7 (2022) 27052.
- Ighodaro OM & Akinloye OA, First line defence antioxidants - Superoxide dismutase (SOD), Catalase (CAT) and Glutathione peroxidase (GPX): Their fundamental role in the entire antioxidant defence grid. *Alexandria J Med*, 54 (2017) 287.
- Gaschler MM & Stockwell BR, Lipid peroxidation in cell death. *Biochem Biophys Res Commun*, 482 (2017) 419.
- Ezhilarasan D & Karthikeyan S, Silibinin alleviates N-nitrosodimethylamine-induced glutathione dysregulation and hepatotoxicity in rats. *Chin J Nat Med*, 14 (2016) 40.
- Antonucci S, Di Lisa F & Kaludercic N, Mitochondrial reactive oxygen species in physiology and disease. *Cell Calcium*, 94 (2021) 102344.
- Ezhilarasan D, Oxidative stress is bane in chronic liver diseases: Clinical and experimental perspective. *Arab J Gastroenterol*, 19 (2018) 56.