

Organised by:



# MOA50 | AOA40



SOUVENIR PROGRAMME BOOK

**50<sup>th</sup> Malaysian Orthopaedic Association**  
Annual Scientific Meeting 2021  
incorporating  
**40<sup>th</sup> ASEAN Orthopaedic Association**  
Annual Congress 2021



Virtual:  
**22nd to 26th  
June 2021**



Replays  
available until  
**30 June 2022**



[secretariat@moaasm.com](mailto:secretariat@moaasm.com)



012-655 9542



50thMOA2021



[moaasm.com](http://moaasm.com)

V I R T U A L   C O N F E R E N C E >>>>

- 3 >> Message from President of Malaysian Orthopaedic Association (MOA) and Organising Chairperson of 50<sup>th</sup> MOA ASM 2021 incorporating 40<sup>th</sup> AOA Annual Congress 2021
- 4 >> MOA Office Bearers 2020 - 2021
- 5 >> Organising and Scientific Committee
- 6 >> Faculty
- 9 >> Citation of Keynote Speaker
- 9 >> Programme Overview
- 12 >> Scientific Programme – Day 1 Lecture Hall A & B
- 14 >> Scientific Programme – Day 2 Lecture Hall A & B
- 17 >> Scientific Programme – Day 3 Lecture Hall A & B
- 19 >> Scientific Programme – Day 4 Lecture Hall A
- 20 >> Scientific Programme – Day 5 Lecture Hall A / Awards
- 22 >> Sponsored Symposiums – Masterclass
- 2 >> Sponsored Symposiums – Lunch Symposiums
- 28 >> Sponsored Symposiums – Satellite Symposiums
- 29 >> Sponsored Symposiums – Virtual Product Theatre
- 30 >> Awards Page
- 31 >> Free Paper Oral Presentations
- 39 >> Free Paper E-Poster Presentations
- 74 >> Exhibition Booth Layout
- 75 >> Acknowledgement Page



Platinum Sponsor

**Smith+Nephew**

Gold Sponsor

**MENARINI**

Silver Sponsors











ZIMMER BIOMET  
Your progress. Our promise.

## » Message from

### **President of Malaysian Orthopaedic Association (MOA) and Organising Chairperson of 50th MOA ASM 2021 incorporating 40th AOA Annual Congress 2021**

The Malaysian Orthopaedic Association (MOA) Annual Scientific Meeting (ASM) is the largest gathering point for the Malaysian Orthopaedic fraternity. In 2019, the ASM gathered a record attendance of 1556 Orthopaedic surgeons, master trainees, medical doctors, house officers, research assistants, nurses, and allied health professionals. Apart from updating knowledge, it was an opportunity to reunite with friends and colleagues as well as catch up with the latest offerings in the industry. For the junior associates, it provided the chance to present your work in the meeting and to start connecting with leading figures in our field.

Unfortunately, the COVID-19 pandemic has shaken our world and as a result, the 2020 MOA ASM had to be rescheduled. Most importantly, the MOA has had to review how this meeting should be conducted.

In the interest of protecting the health, safety and well-being of our members, guests and industry partners, the MOA Council and ASM Organising Committee has decided to run the meeting virtually with the last day of the meeting dedicated to the eagerly anticipated and highly contested awards presentations.

The 50th MOA ASM in conjunction with the 40th AOA Annual Congress will be held from 22nd to the 26th of June 2021, a five day virtual event. This is the first time in our history that we will be attempting this, so we are indeed excited about it. The scientific team have a stimulating scientific programme in the wings, with debates, discussions, contests, and virtual booths where you can 'walk in'!

It is said that this pandemic has accelerated the way we adopt technology and digitalisation in our lives. Thus, we encourage our fellow colleagues to actively participate and embrace the new future of the MOA ASM.

See you online!  
Take care, stay safe.

**Dr Sharifah Roohi Syed Waseem Ahmad**  
President  
Malaysian Orthopaedic Association 2020 – 2021  
&  
Organising Chairperson  
50th Malaysian Orthopaedic Association  
Annual Scientific Meeting  
*Incorporating*  
40th ASEAN Orthopaedic Association Annual Congress





**President**  
Dr Sharifah Roohi Syed Waseem Ahmad



**President-Elect**  
Dr Suhail Abdullah @ Suresh Kumar



**Immediate Past President**  
Dr Chye Ping Ching



**Hon. Secretary**  
Dr Fahrudin Che Hamzah



**Hon. Treasurer**  
Prof Dr Tunku Kamarul Zaman  
Tunku Zainol Abidin



**Council Member**  
Assoc Prof Dr Tengku Muzaffar  
Tengku Mohamed Shihabudin



**Council Member**  
Dr Mohd Fairuz Suhaimi



**Editorial Secretary**  
Assoc Prof Dr Gandhi Nathan Solayar



**Hon. Auditor**  
Prof Dato' Dr Tunku Sara  
Tunku Ahmad Yahaya



**Hon. Auditor**  
Prof Dr David Choon Siew Kit

>> Organising and Scientific Committee



**Organising Chairperson**  
Dr Sharifah Roohi Syed Waseem Ahmad



**Scientific Chairperson**  
Prof Dr Azlina Amir Abbas



**Arthroplasty**  
Assoc Prof Dr Gandhi  
Nathan Solayar



**Foot & Ankle**  
Assoc Prof Dr Mohd Yazid  
Bajuri



**Hand**  
Assoc Prof Dr Shalimar  
Abdullah



**Humanitarian**  
Dr Mohamed Ashraff  
Mohd Ariff



**Oncology**  
Prof Dr Wan Faisham  
Nu'man Wan Ismail



**Paediatrics**  
Dr Muhammad Kamal Mohd  
Abdul Jamil



**Spine**  
Prof Dr Chris Chan Yin Wei



**Sports**  
Dr Charanjeet Singh



**Trauma / LLRS**  
Dr Ashraf Hakim Ab Halim



**Trauma / LLRS**  
Dr Azammuddin Alias

>> Faculty



Professor Dr Abdul Razak Sulaiman



Adjunct Professor Dr Abhijeet L Wahegaonkar



Dr Ahmad Arieff Atan



Dr Ahmad Munawwar Helmi Salim



Dr Ajoy Prasad Shetty T



Dr Albiruni R Abdul Razak



Professor Dr Alexander Cherkashin



Professor Dr Aminudin Che Ahmad



Dr Anthony Foo Tun-Lin



Assistant Professor Dr Aryadi Kurniawan



Associate Professor Dr Beat Hintermann



Associate Professor Dr Brendan C. Dickson



Dr Charanjeet Singh



Professor Dr Chris Chan Yin Wei



Dr Chua Hwa Sen



Adjunct Associate Professor Dr Chua Yeok Pin



Associate Professor Dr Daisuke Sakai



Professor Dr Denis Barritault



Assistant Professor Dr Dennis Hey Hwee Weng



Professor Dr Domenico Campanacci



Dr Edi Mustamsir



Dr Enrique Leonardo C. Pasion



Associate Professor Dr Ferdiansyah Mahyudin



Associate Professor Dr Gabriel Liu Ka-Po

» Faculty



Dr Gowreeson Thevendran



Professor Dr Hiroyuki Tsuchiya



Professor Dr James Hui



Associate Professor Dr Jason Cheung Pui Yin



Professor Dr Jay Steven Wunder



Dr Jeffrey Jaya Raj



Dr Jeremy Prakash Silvanathan



Dr Kamarul Al-Haqq Abdul Ghani



Associate Professor Dr Kamarul Ariffin Khalid



Dr Kamarul Arifin Abdul Razak



Dr Khairul Anwar Ayob



Dr Khairul Rizal Zayzan



Dr Lewis Chan Ping Keung



Dr Lim Beng Hai



Dr Low Tze Choong



Dr Mafeitzeral Mamat



Dr Mohamad Saifudin Othman



Dr Mohd Fairuz Ali



Dr Mohd Hafiz Mohd Hassim



Dr Mohd Yusof Ibrahim



Dr Nathan Peter White



Professor Dr Nazri Mohd. Yusof



Associate Professor Dr Nor Hamdan Mohamad Yahaya



Dr Paul Magill

>> Faculty



Professor Dr Perry Schoenecker



Professor Dr Peter Choong



Dr Piyabuth Kittithamvongs



Professor Dr Rafael C. Bundoc



Professor Dr Rajiv Shah



Dr Ranjit Singh Gill



Professor Dr Reiko Imai



Dr Roxa Ruiz



Dr Sachin Tapasvi



Dr Sahran Yahaya



Dr Samuel J MacDessi



Dr Sasidaran Ramalingam



Professor Dr Saw Aik



Emeritus Professor Datuk Dr Shad Saleem Faruqi



Associate Professor Dr Shalimar Abdullah



Dr Siti Hawa Tahir



Dr Umer Butt




Professor Dr Wan Azman Wan Sulaiman



Associate Professor Dr Yu Yamato



# Citation of Keynote Speaker



**Emeritus Professor Datuk  
Dr Shad Saleem Faruqi**

Professor Dr Shad is a holder of the Tunku Abdul Rahman Foundation Chair At The Faculty Of Law, University Of Malaya. He is also the holder of the Noah Foundation Chair at The Institute of Strategic and International Studies Malaysia. Professor Dr Shad is also an Adjunct Professor at Taylor's University Malaysia and an Elected Fellow of The Academy of Sciences Malaysia. He is also a member, and part of the Board of Trustees, Of the Tunku Abdul Rahman Foundation. (Appointed By Minister of Higher Education 2020).

VIRTUAL		22nd June 2021 (Tuesday)	
Time		Lecture Hall A	Lecture Hall B
8.00am	12.00pm		
11.50am	12.00pm	Opening Ceremony	
12.00pm	1.00pm	LS1 = A Menarini	LS2 = NOVO Nordisk
1.00pm	2.00pm	Free Paper Presentations / On Demand Sessions / Visit Exhibition Booths	
2.00pm	2.30pm	Spine	Arthroplasty
2.30pm	3.00pm		
3.00pm	3.30pm		
3.30pm	3.45pm	Advertisements	
3.45pm	4.15pm	Spine	Arthroplasty
4.15pm	4.45pm		
4.45pm	5.15pm		
5.15pm	5.30pm	Advertisements	
5.30pm	6.00pm	Keynote Lecture	

VIRTUAL		23rd June 2021 (Wednesday)	
Time		Lecture Hall A	Lecture Hall B
8.00am	12.00pm	Masterclass D2A = Smith & Nephew	
11.50am	12.00pm		
12.00pm	1.00pm		LS4 = Amgen
1.00pm	2.00pm	Free Paper Presentations / On Demand Sessions / Visit Exhibition Booths	
2.00pm	2.30pm	Sports	Hand
2.30pm	3.00pm		
3.00pm	3.30pm		
3.30pm	3.45pm	Advertisements	
3.45pm	4.15pm	Sports	Humanitarian
4.15pm	4.45pm		
4.45pm	5.15pm		
5.15pm	5.30pm	Advertisements	
5.30pm	6.00pm	Plenary 2	

VIRTUAL		24th June 2021 (Thursday)	
Time		Lecture Hall A	Lecture Hall B
8.00am	12.00pm		
11.50am	12.00pm		
12.00pm	1.00pm	LS5 = Pfizer	
1.00pm	2.00pm	Free Paper Presentations / On Demand Sessions / Visit Exhibition Booths	
2.00pm	2.30pm	Foot & Ankle	LLRS
2.30pm	3.00pm		
3.00pm	3.30pm		
3.30pm	3.45pm	Advertisements	
3.45pm	4.15pm	Paediatrics	Oncology
4.15pm	4.45pm		
4.45pm	5.15pm		
5.15pm	5.30pm	Advertisements	
5.30pm	6.00pm	Plenary 3	

VIRTUAL		25th June 2021 (Friday)	
Time		Lecture Hall A	
8.00am	12.00pm		
11.50am	12.00pm		
12.00pm	1.00pm		
1.00pm	2.00pm	Free Paper Presentations / On Demand Sessions / Visit Exhibition Booths	
2.00pm	2.30pm	Foot & Ankle	
2.30pm	3.00pm		
3.00pm	3.30pm		
3.30pm	3.45pm	Advertisements	
3.45pm	4.15pm	Trauma	
4.15pm	4.45pm		
4.45pm	5.15pm		
5.15pm	5.30pm	Advertisements	
5.30pm	6.00pm		

VIRTUAL		26th June 2021 (Saturday)	
Time		Lecture Hall A	
9.00am	10.00am	Free Paper Presentations / On Demand Sessions / Visit Exhibition Booths	
10.00am	10.30am	Best Published Papers Award Presentation	
10.30am	10.45am	Free Paper Presentations / On Demand Sessions / Visit Exhibition Booths	
10.45am	11.30am	Best Basic Science Poster Award Judging	
11.30am	12.00pm	Subir Sengupta Memorial Lecture	
12.00pm	12.15pm	On Demand Sessions / Visit Exhibition Booths	
12.15pm	1.30pm	Mahmood Merican Best Masters Thesis Judging	
1.30pm	1.35pm	Advertisements	
1.35pm	2.20 pm	Plenary 4	
2.20pm	2.30pm	Award Presentation & Closing Ceremony	
END			

11:50 AM 12:00 PM **OPENING CEREMONY**

12:00 PM 1:00 PM **LUNCH SYMPOSIUM BY A MENARINI**

*Chairperson: Prof Dr Azlina Amir Abbas, Malaysia*

**The Art and Science of Acute Pain Management**

*Prof Dr Edward Wang, Philippines*

Q & A and Discussion

1:00 PM 2:00 PM **FREE Paper Presentations / On Demand Sessions / Visit Exhibition Booths**

2:00 PM 3:30 PM **SPINE: MEETING MASTERS OF THE ASIA PACIFIC REGION**

*Chairperson: Assoc Prof Dr Chiu Chee Kidd, Malaysia*

**Clinical Implications Of Lumbar Development Spinal Stenosis**

*Assoc Prof Dr Jason Cheung Pui Yin, Hong Kong*

**Utility Of Office Based 3D Printing For Complex Spine Surgeries**

*Prof Dr Rafael Bundoc, Philippines*

**Current Status Of Surgical Treatment For Adult Spinal Deformity**

*Assoc Prof Dr Yu Yamato, Japan*

**How to Choose Anterior Vs Posterior Approach In Cervical Myelopathy Patients?**

*Assoc Prof Dr Gabriel Liu, Singapore*

Q & A and Discussion

All speakers above

3:30 PM 3:45 PM **Advertisements**

3:45 PM 5:15 PM **SPINE: UNDERSTANDING THE FUNDAMENTALS OF COMMON CONDITIONS IN SPINE SURGERY**

*Chairperson: Assoc Prof Dr Chiu Chee Kidd, Malaysia*

**Assessment Of Patients With Ossified Posterior Longitudinal Ligament**

*Assoc Prof Dr Daisuke Sakai, Japan*

**Radiological Assessment Of Patients With Adolescent Idiopathic Scoliosis**

*Prof Dr Chris Chan Yin Wei, Malaysia*

**Importance Of Sagittal Balance Of The Spine: Understanding The Compensatory Mechanisms**

*Asst Prof Dr Dennis Hey, Singapore*

**Updates In The Management Of Patients With Spinal Tuberculosis**

*Dr Ajoy Prasad Shetty, India*

Q & A and Discussion

All speakers above

5:15 PM 5:30 PM **Advertisements**

5:30 PM 6:00 PM **KEYNOTE LECTURE**

*Citation By: Dr Sharifah Roohi Syed Waseem Ahmad, Malaysia*

**The Medical Act: A Constitutional and Legal Perspective**

*Emeritus Prof Datuk Dr Shad Saleem Faruqi, Malaysia*

**End of Day 1**

12:00 PM 1:00 PM

**LUNCH SYMPOSIUM BY NOVO NORDISK***Chairperson: Assoc Prof Dr Gandhi Nathan Solayar, Malaysia***Weight Loss – The Sleeping Giant In Osteoarthritis Management***Dato' Dr Tikfu Gee, Malaysia*

Q &amp; A and Discussion

1:00 PM 2:00 PM

**Free Paper Presentations / On Demand Sessions / Visit Exhibition Booths**

2:00 PM 3:30 PM

**ARTHROPLASTY: HIP***Chairperson : Assoc Prof Dr Gandhi Nathan Solayar, Malaysia***Robotics & Navigation In THR***Dr Chua Hwa Sen, Malaysia***Reducing Dislocation***Dr Paul Magill, United Kingdom***Live Debate**

- **Debate: Cement**  
*Assoc Prof Dr Nor Hamdan Mohamad Yahaya, Malaysia*
- **Debate: Uncemented**  
*Dr Paul Magill, United Kingdom*

**Live Debate**

- **Debate: Antero-lateral**  
*Dr Jeffrey Jaya Raj, Malaysia*
- **Debate: Posterior Approach**  
*Dr Chua Hwa Sen, Malaysia*

Q&amp;A and Discussion

All speakers above

3:30 PM 3:45 PM

**Advertisements**

3:45 PM 5:30 PM

**ARTHROPLASTY: KNEE***Chairperson : Assoc Prof Dr Gandhi Nathan Solayar, Malaysia***Principles Of Knee Balancing In TKA. Getting It Right Every Time***Dr Samuel J MacDessi, Australia***Robotics & Navigation In TKR***Dr Nathan White, Australia***Live Debate**

- **Debate: Resurfacing The Patella. Yes**  
*Dr Samuel J MacDessi, Australia*
- **Debate: Resurfacing The Patella. No**  
*Dr Mohd Yusof Ibrahim, Malaysia*

**Live Debate**

- **Debate: Cruciate Retaining**  
*Dr Khairul Anwar Ayob, Malaysia*
- **Debate: Cruciate Sacrificing**  
*Dr Nathan White, Australia*

**Incidence And Risk Factors Of Hypovitaminosis D in Patients Undergoing Joint Replacement Surgery – A Multiple Regression Analysis.***Dr Lewis Chan Ping-Keung, HKOA Ambassador*

Q&amp;A and Discussion

All speakers above

5:15 PM 5:30 PM

**Advertisements**

5:30 PM 6:00 PM

**Return to Virtual Hall A for Keynote Lecture**

End of Day 1

8:00 AM 12:00 PM

**SMITH & NEPHEW MASTERCLASS****SESSION 1: SPORTS MEDICINE, KNEE ARTHROSCOPY****All Inside ACL Reconstruction: Optimal Solution To Maximize Our Graft Size!***Dr Teo Seow Hui, Malaysia***Surgical Demonstration: All Inside ACL Reconstruction & Radial Tear***Dr Teo Seow Hui, Malaysia*

Q &amp; A

**SESSION 2 : KNEE RECONSTRUCTION, REVISION KNEE ARTHROPLASTY****Knee Reconstruction: The Way I Approach It***Assoc Prof Dr Gandhi Nathan Solayar, Malaysia***Surgical Demonstration: Revision Total Knee Replacement***Assoc Prof Dr Gandhi Nathan Solayar, Malaysia*

Q &amp; A

**SESSION 3 : TOTAL HIP ARTHROPLASTY****Direct Anterior Approach- Avoiding Pitfalls***Dr Pang Hee Nee, Singapore***Surgical Demonstration on THA Direct Anterior Approach***Dr Pang Hee Nee, Singapore***Panel Discussion and Q&A***Dr Pang Hee Nee, Singapore**Dr Chua Hwa Sen, Malaysia***SESSION 4 : ENABLING TECHNOLOGY****Robotics Assisted TKA: Personalized Planning***Dr David Rovinsky, USA***NAVIO Robotics Case Demonstration: A Step by Step Guide***Dr David Rovinsky, USA***Panel Discussion: The Future of Robotics***Dr David Rovinsky**Assoc Prof Dr G. Ruslan Nazaruddin Simanjuntak**Dr Pang Hee Nee***End of Masterclass**

12:00 PM 1:00 PM

**LUNCH SYMPOSIUM BY AMGEN IN HALL B***continue next page*

**1:00 PM      2:00 PM      Free Paper Presentations / On Demand Sessions / Visit Exhibition Booths**

**2:00 PM      3:30 PM**

**SPORTS: ACL DEMO**

*Chairperson: Dr Charanjeet Singh, Malaysia*

**ACL Anatomy: What You Need To Know.**

*Dr Enrique Leonardo C. Pasion, Philippines*

**Clinical Evaluation Of ACL Injuries**

*Dr Siti Hawa Tahir, Malaysia*

**ACL Graft Selection**

*Dr Edi Mustamsir, Indonesia*

**Cadaveric Demo Video By Dr Freddie Fu: ACL**

Q&A and Discussion

**3:30 PM      3:45 PM**

**Advertisements**

**3:45 PM      5:15 PM**

**SPORTS: EXTRA ARTICULAR**

*Chairperson: Dr Charanjeet Singh, Malaysia*

**The Failed Primary ACL Reconstruction, Tips and Tricks in Management**

*Dr Charanjeet Singh, Malaysia*

**Who Needs An Extra Articular Procedure**

*Dr Sachin Tapasvi, India*

**ACL Repair: Where Are We Now?**

*Dr Umer Butt, Pakistan*

**Cadaveric Demo Video by Dr Alan Getgood: Extra Articular Tenodesis**

Q & A Discussion

**5:15 PM      5:30 PM**

**Advertisements**

**5:30 PM      6:00 PM**

**PLENARY 2**

*Chairperson: Prof Dr Azlina Amir Abbas, Malaysia*

**Surgical Site Complications In Orthopaedic & Standard Of Care With sNPWT For High Risk Patient**

*Dr Sasidaran Ramalingam, Malaysia*

**End of Day 2**

12:00 PM	1:00 PM	<p><b>LUNCH SYMPOSIUM BY AMGEN</b>  <i>Chairperson: Dato' Dr Lee Joon Kiong, Malaysia</i></p> <p><b>Expanding The Role Of Orthopedic Surgeon In The Treatment Of Osteoporosis</b>  <i>Dr Paul Anderson, USA</i></p> <p>Q&amp;A and Discussion</p>
1:00 PM	2:00 PM	Free Paper Presentations / On Demand Sessions / Visit Exhibition Booths
2:00 PM	2:40 PM	<p><b>HAND: ACUTE TFCC INJURY SYMPOSIUM</b>  <i>Chairperson: Dr Mohamad Sallehuddin Hassan, Malaysia</i></p> <p><b>Acute TFCC Injury Discussion: Sugar Tong Splinting</b>  <i>Dr Ranjit Singh Gill, Malaysia</i></p> <p><b>Acute TFCC Injury Discussion: For Open TFCC Repair</b>  <i>Dr Anthony Foo Tun Lin, Singapore</i></p> <p><b>Acute TFCC Injury Discussion: For Arthroscopic Repair</b>  <i>Dr Jeremy Prakash Silvanathan, Malaysia</i></p> <p>Q &amp; A and Discussion</p>
2:40 PM	3:30 PM	<p><b>HAND</b>  <i>Chairperson: Dr Mohamad Sallehuddin Hassan, Malaysia</i></p> <p><b>Double Crush Syndrome As A Caveat For Carpal Tunnel Release Surgery</b>  <i>Adj Prof Dr Abhijeet L Wahegaonkar, India</i></p> <p><b>Radial Head Fractures - Resect, Reconstruct Or Replace?</b>  <i>Dr Piyabuth Kittithamvongs, Thailand</i></p> <p><b>Scaphoid Non-Union / AVN : Can I Get Away With Avascularised Bone Graft Only?</b>  <i>Dr Lim Beng Hai, Singapore</i></p> <p>Q &amp; A and Discussion</p>
3:30 PM	3:45 PM	Advertisements
3:45 PM	5:15 PM	<p><b>HUMANITARIAN</b>  <i>Chairperson : Dr Muhamad Karbela Reza, Malaysia</i></p> <p><b>Mobile Unit Surgical Trailer (MUST)</b>  <i>Dr Kamarul Al-Haqq Abdul Ghani, Malaysia</i></p> <p><b>Behind The Scenes In Sg Buloh And Semporna's ICU During COVID-19</b>  <i>Dr Mafeitzeral Mamat, Malaysia</i></p> <p><b>Bringing Relief To The Minorities Affected By The COVID-19 Pandemic. MRA's Nationwide Effort</b>  <i>Dr Mohd Fairuz Ali, Malaysia</i></p> <p><b>IMARET: Filling The Gaps During Crisis &amp; Disaster</b>  <i>Dr Ahmad Munawwar Helmi Salim, Malaysia</i></p> <p><b>World Health Organisation (WHO) Emergency Medical Team Verification Standards</b>  <i>Assoc Prof Dr Shalimar Abdullah, Malaysia</i></p>
5:15 PM	5:30 PM	Q & A and Discussion
5:30 PM	6:00 PM	<p><b>Return to Virtual Hall A for Plenary Lecture</b></p> <p>End of Day 2</p>



12:00 PM	1:00 PM	<p><b>LUNCH SYMPOSIUM BY PFIZER</b> <i>Chairperson: Dato' Dr Suresh Chopra, Malaysia</i></p> <p><b>Current Challenges And Opportunities Of 5th Generation Cephalosporins To Treat cSSTI</b> <i>Dr Chow Ting Soo, Malaysia</i></p> <p>Q &amp; A and Discussion</p>
1:00 PM	2:00 PM	Free Paper Presentations / On Demand Sessions / Visit Exhibition Booths
2:00 PM	3:30 PM	<p><b>FOOT &amp; ANKLE: TREATMENT OPTIONS IN ANKLE ARTHRITIS</b> <i>Chairperson: Assoc Prof Dr Mohd Yazid Bajuri, Malaysia</i></p> <p><b>Joint Preserving Osteotomy In Severe Stage Of Ankle Arthritis</b> <i>Assoc Prof Dr Beat Hintermann, Switzerland</i></p> <p><b>Ankle Arthrodesis: The Treatment Potential And Limitations</b> <i>Prof Dr Rajiv Shah, India</i></p> <p><b>Role Of TI-Hex In Severe Ankle Arthritis And Deformity</b> <i>Prof Dr Alexander Cherkashin, United States</i></p> <p><b>Total Ankle Replacement: The Current Updates</b> <i>Assoc Prof Dr Beat Hintermann, Switzerland</i></p> <p>Q&amp;A and Discussion</p>
3:30 PM	3:45 PM	Advertisements
3:45 PM	5:15 PM	<p><b>PAEDIATRICS: NON-UNION IN PAEDIATRIC CONDITIONS</b> <i>Chairpersons: Dr Muhammad Kamal Mohd Abdul Jamil, Malaysia &amp; Dr Luvan Markandan, Malaysia</i></p> <p><b>Non-Union In Congenital Pseudoarthrosis Of Tibia: Ilizarov Treatment</b> <i>Prof Dr Saw Aik, Malaysia</i></p> <p><b>Biocellular Approach In Congenital Pseudoarthrosis Of Tibia</b> <i>Asst Prof Dr Aryadi Kurniawan, Indonesia</i></p> <p><b>Non-Union In Osteogenesis Imperfecta: Surgical Management</b> <i>Prof Dr Abdul Razak Sulaiman, Malaysia</i></p> <p><b>Strategies To Avoid Non-Union In Osteogenesis Imperfecta And Congenital Pseudoarthrosis Of Tibia</b> <i>Prof Dr James Hui, Singapore</i></p> <p>Q&amp;A and Discussion</p>
5:15 PM	5:30 PM	Advertisements
5:30 PM	6:00 PM	<p><b>PLENARY LECTURE</b> <i>Chairperson: Dr Sharifah Roohi Syed Waseem Ahmad, Malaysia</i></p> <p><b>Matrix Therapy In Regenerative Medicine: Translational Medicine From Bench To Bedside</b> <i>Prof Dr Denis Barritault, France</i></p> <p><b>End of Day 3</b></p>

12:00 PM 1:00 PM **LUNCH SYMPOSIUM BY PFIZER IN HALL A**

1:00 PM 2:00 PM Free Paper Presentations / On Demand Sessions / Visit Exhibition Booths

2:00 PM 3:30 PM **LLRS**

*Chairperson: Dr Basir Towil, Malaysia*

**Strategies In Minimising Complication Of Bone Transport: "The Art Of War"**

*Dr Khairul Rizal Zayzan, Malaysia*

**Multifocal Distraction Osteogenesis For Treatment Of Long Bone Defect**

*Dr Mohamad Saifudin Othman, Malaysia*

**Acute Tibialisation Of Fibula For Tibia Bone Defect**

*Dr Kamarul Arifin Abdul Razak, Malaysia*

**Cross-Ankle Ring Fixator Revisited: IEF for Management Of Ankle Septic Arthritis & Wound**

*Dr Ahmad Arieff Atan, Malaysia*

**Use Of Flap In The Bone Reconstruction Procedure**

*Prof Dr Nazri Mohd Yusof, Malaysia*

Q & A and Discussion

3:30 PM 3:45 PM Advertisements

3:45 PM 5:30 PM **ONCOLOGY: NEW ADVANCEMENT IN SARCOMA MANAGEMENT**

*Chairpersons: Prof Dr Wan Faisham Wan Ismail & Prof Dr Zulmi Wan*

**3D Printing For Bone Reconstruction – Present Status And Future Progress**

*Prof Dr Peter Choong, Australia*

**Molecular Diagnosis In Sarcoma**

*Assoc Prof Dr Brendan Dickson, Canada*

**Personalised And Targeted Therapy In Sarcoma**

*Dr Albiruni Ryan Abdul Razak, Canada*

**Molecular Diagnosis - New Approach In Sarcoma Surgery**

*Prof Dr Jay S Wunder, Canada*

**Carbon Ion Therapy For Chordoma And Chondrosarcoma**

*Prof Dr Reiko Imai, Japan*

**Cryosurgery 'Liquid Nitrogen' In Sarcoma**

*Prof Dr Hiroyuki Tsuchiya, Japan*

**How I Started Cryotherapy In Indonesia And Outcome**

*Assoc Prof Dr Ferdiansyah Mahyudin, Indonesia*

**Cryotherapy: Malaysia's Experience**

*Dr Sahran Yahaya, Malaysia*

**Biological Reconstructions In Intercalary Resections**

*Prof Dr Domenico Campanacci, Italy*

**Advancement Of Plastic Reconstruction In Sarcoma Surgery**

*Prof Dr Wan Azman Wan Sulaiman, Malaysia*

Q & A and Discussion

5:15 PM 5:30 PM Advertisements

5:30 PM 6:00 PM **Return to Virtual Hall A for Plenary Lecture**

End of Day 3

1:00 PM 2:00 PM Free Paper Presentations / On Demand Sessions / Visit Exhibition Booths

2:00 PM 2:40 PM **FOOT & ANKLE: FLATFOOT RECONSTRUCTION**

*Chairperson: Dr Yeap Ewe Juan, Malaysia*

**Tips And Tricks In Flatfoot Problems**

*Dr Roxa Ruiz, Switzerland*

**What To Do In A Failed Flatfoot Reconstruction**

*Dr Gowreeson Thevendran, Singapore*

Q&A and Discussion

2:40 PM 3:30 PM **FOOT & ANKLE PEARLS AND PITFALLS IN TRAUMA AROUND THE ANKLE**

*Chairperson: Dr Low Tze Choong, Malaysia*

**Fixation Strategies For Syndesmotic Injury**

*Dr Low Tze Choong, Malaysia*

**Surgical Treatment Of Difficult Pilon Fracture**

*Prof Dr Aminudin Che Ahmad, Malaysia*

**Talar Neck Fracture And How To Deal With Complication**

*Adj Assoc Prof Dr Chua Yeok Pin, Malaysia*

Q&A and Discussion

3:30 PM 3:45 PM Advertisements

3:45 PM 5:15 PM **TRAUMA**

*Chairperson: Dr Azammudin Alias, Malaysia*

**Current Update On Scapular Fracture Management**

*Dr Ahmad Arieff Atan, Malaysia*

**Reconstruction Pelvic Plate For Buttressing Of Quadrilateral Plate In Acetabular Fracture**

*Dr Mohd Hafiz Mohmad Hassim, Malaysia*

**MIS (Minimally Invasive Surgery) In Pelvic Fracture**

*Dr Kamarul Al-Haqq Abdul Ghani, Malaysia*

Q&A and Discussion

5:15 PM 5:30 PM Advertisements

**End of Day 4**

9:00 AM 10:00 AM Free Paper Presentations / On Demand Sessions / Visit Exhibition Booths

10:00 AM 10:15 AM **P. BALASUBRAMANIAM BEST PUBLISHED TRANSLATIONAL MEDICINE (NON-CLINICAL) PAPER WINNER PRESENTATION**

*Chairperson: Prof Dato' Dr Tunku Sara Tunku Ahmad Yahaya, Malaysia*

**Uniaxial Cyclic Tensile Stretching At 8% Strain Exclusively Promotes Tenogenic Differentiation Of Human Bone Marrow-Derived Mesenchymal Stromal Cells**

*Prof Dr Tunku Kamarul Zaman Tunku Zainol Abidin, University of Malaya*

10:15 AM 10:30 AM **SUBIR SENGUPTA BEST PUBLISHED CLINICAL PAPER AWARD WINNER PRESENTATION**

*Chairperson: Prof Dato' Dr Tunku Sara Tunku Ahmad Yahaya, Malaysia*

**After-Hours Elective Spine Deformity Corrective Surgery For Patients With Adolescent Idiopathic Scoliosis: Is It Safe?**

*Assoc Prof Dr Chiu Chee Kidd, University of Malaya*

10:30 AM 10:45 AM Free Paper Presentations / On Demand Sessions / Visit Exhibition Booths

10:45 AM 11:30 AM **BEST BASIC SCIENCE POSTER AWARD JUDGING**

*Chairperson: Prof Dr Azlina Amir Abbas*

**BBS01 Rabbit Articular Cartilage Defect Treatment Using The Combined Effect Of Bone Marrow Aspirate Concentrate And Platelet Rich Plasma**

*Ms. Nabillah Abd Radzak*

**BBS02 Metformin Improves Extracellular Matrix Homeostasis Related Genes And Tenogenic Expressions On Insulin Resistance Induced-Human Tenocytes In Vitro**

*Ms. Tan Hui Yee*

**BBS03 From Osteoarthritic Synovium To Synovial-Derived Cells Characterization: Obese Vs Non-Obese**

*Dr Chiew Chiaw Lee*

**BBS04 The Prospective Role Of Decellularised Human Amniotic Membrane Incorporated With Platelet-Rich Plasma In Moderating Fibroblast Characteristics Of Mesenchymal Stromal Cells For Acute Large Wound Healing**

*Mr. Ahmad Fuad Ahmad Kamal*

**BBS05 Perivascular Stem Cells Demonstrate Similar Level Of Stemness, Chondrogenic Ability And Osteoarthritis Repair Potential To Mesenchymal Stromal Cells**

*Mr. Shan Xiaolong*

11:30 AM 12:00 PM **SUBIR SENGUPTA MEMORIAL LECTURE**

*Chairperson: Prof Dr Saw Aik, Malaysia*

**Slipped Capital Femoral Epiphysis --- Acute, Chronic, and Late Presentation**

*Prof Dr Perry Schoenecker, USA*

12:00 PM 12:15 PM On Demand Session / Exhibition Booth Visit

*continue next page*

12:15 PM	1:30 PM	<b>MAHMOOD MERICAN BEST MASTERS RESEARCH AWARD JUDGING</b> <i>Chairperson: Dr Norsaidatul Nadriah Ahmad Shuhiamy</i>
	MMA01	<b>A Biomechanical Comparison of Flexor Tendon Repair Techniques on Fresh Frozen Human Tendon</b> <i>Dr Rahul Lingam</i>
	MMA02	<b>Development And Clinical Trial Of Prototype External Digit Device For Correction Of Digit Flexion Deformity</b> <i>Dr Nicholas Soong JinYih</i>
	MMA03	<b>Comparison Between The Effect Of Immersive Virtual Reality Training Versus Conventional Rehabilitation On Limb Loading And Functional Outcomes After ACL Reconstruction: Prospective Randomized Controlled Trial</b> <i>Dr Muhindra Rao</i>
	MMA04	<b>Improving Tendon Repair: The Use Of Human Amniotic Membrane Seeded With Tenogenic Mesenchymal Stem Cells In A Rat Model</b> <i>Dr Sarah Sheena Toyat</i>
	MMA05	<b>Low Level Laser Therapy After Neurotization (Oberlin Procedure) In Brachial Plexus Injury: A Randomized Controlled Trial</b> <i>Dr Foo Yi Hui</i>

1:30 PM 1:35 PM Advertisements

1:35 PM 2:20 PM **PLENARY LECTURE**  
*Chairperson: Dato' Dr Mohd Anwar Hau Abdullah, Malaysia*

**Introduction To The National Orthopaedic Curriculum (NOC) – What To Expect?**  
*Assoc Prof Dr Kamarul Ariffin Khalid, Malaysia*

Q & A

2:20 PM 2:30 PM **PRESENTATION OF AWARDS AND CLOSING CEREMONY**

Thank You & See You In 2022

# + Masterclass Symposium

## R2R repair to reconstruction

Wednesday, 23 June 2021

**Smith+Nephew**

Medical Education

### Invited Speakers



**Dr David Rovinsky, University of Hawaii, USA**

is a Clinical Assistant professor specializing in hip and knee reconstruction. His expertise is the integration of technology into orthopaedic surgery including robotic assisted knee replacement and total hip navigation.



**Dr Pang Hee Nee, Singapore General Hospital, Singapore**

is a Consultant Orthopaedic Surgeon specializing in hip and knee surgery- primary, complex primary and revision joint replacement surgery. Dr Pang completed his clinical fellowship in London, Ontario, Canada. Dr Pang is familiar with the various hip approaches in joint replacement, including the direct approach to total hip replacement.



**Assoc Prof Dr G Ruslan Nazaruddin, KPJ Tawakal Specialist Hospital, Malaysia**

is a senior surgeon in joint replacement surgery, comes across as a very dedicated doctor who is continuously updating himself to the latest practices and technology in orthopaedic with a vision eventually to establish a dedicated Joint Replacement Centre of Excellence in Malaysia.



**Assoc Prof Dr Gandhi Nathan Solayar Ara Damansara Medical Centre, Malaysia**

is a Consultant Orthopaedic Surgeon specializing in sports and joint replacement. Dr Solayar is currently part of the MOA ASM 2021 Organising & Scientific Committee and have been invited by several society as speaker and faculty.



**Dr Chua Hwa Sen, Sunway Medical Center, Malaysia**

is an experienced Consultant Orthopaedic Surgeon, specialising in Orthopaedic and Trauma Surgery with a sub-speciality in Arthroplasty. His areas of expertise include adult hip and knee joint reconstruction and revision surgery, pelvic and acetabulum trauma management.



**Dr Teo Seow Hui, Faculty of Medicine, University of Malaya, Malaysia**

is a Medical Lecturer and Orthopaedic Surgeon specializing in Sports Injury and Arthroscopy Surgery Dr Teo chaired and conducted several hands-on instructional courses in Malaysia and have been invited as speaker and faculty for several national and regional congresses and meetings.

# Agenda

## R2R repair to reconstruction

Welcome to R2R Repair to Reconstruction Master Class Forum at Smith + Nephew; we take pride in life unlimited. The high-level discussions will focus on early intervention to reconstruction, demonstrating the healthcare eco-system of SNN.

Join our world-renowned faculty expert panel as they share their expertise through surgical demonstration and discuss clinical data and hot topics and the current trends in orthopaedics.

Time	Session 1: Sports Medicine, Knee Arthroscopy	Speaker
08:00-08:15	All Inside ACL Reconstruction: Optimal Solution To Maximize Our Graft Size!	Dr Teo Seow Hui
08:15-08:30	Surgical Demonstration: All Inside ACL Reconstruction & Radial Tear	Dr Teo Seow Hui
08:30-09:00	Q&A	
Time	Session 2: Knee Reconstruction, Revision Knee Arthroplasty	Speaker
09:00-09:10	Knee Reconstruction: The Way I Approach It	Assoc Prof Dr Gandhi Solayar
09:10-09:25	Surgical Demonstration: Revision Total Knee Replacement	Assoc Prof Dr Gandhi Solayar
09:25-10:00	Q&A	
Time	Session 3, Total Hip Arthroplasty	Speaker
10:00-10:10	Direct Anterior Approach – Avoiding Pitfalls	Dr Pang Hee Nee
10:10-10:20	Surgical Demonstration on THA Direct Anterior Approach	Dr Pang Hee Nee
10:20-11:00	Panel Discussion and Q&A	Dr Pang Hee Nee Dr Chua Hwa Sen
Time	Session 4, Enabling Technology	Speaker
11:00-11:10	Robotics Assisted TKA: Personalized Planning	Dr David Rovinsky
11:10-11:20	NAVIO Robotics case demonstration: A Step by Step Guide	Dr David Rovinsky Dr David Rovinsky
11:20-12:00	Panel Discussion: The Future of Robotics	Assoc Prof Dr Ruslan Nazarudin Dr Pang Hee Nee





**VIRTUAL CONFERENCE**

**50<sup>th</sup> Malaysian Orthopaedic Association**  
Annual General Meeting / Annual Scientific Meeting 2021

incorporating  
**40<sup>th</sup> ASEAN Orthopaedic Association**  
Annual Congress 2021

# MENARINI LUNCH SYMPOSIUM

“The Art and Science of Acute Pain Management”

Date : 22 June 2021

Time : 12.00pm - 1.00pm

Speaker : Prof. Edward H. Wang

Orthopaedic Surgeon, Philippines

Moderator : Prof Azlina Amir Abbas

## Speaker PROFILE



Professor Edward Wang

- Professor Wang is a Professor at the University of Philippines College of Medicine and Philippines General Hospital in Manila.
- He completed his residencies in Manila and then a Fellowship at University of Toronto in Canada. After his return to the Philippines, he obtained an MS in Clinical Epidemiology at the UP Department of Clinical Epidemiology.
- Professor Wang is the Program Lead of the Medicine Surgical Innovation and Biotechnology Laboratory and Biomedical Innovation Research and Translational Hub at UP.
- He is also an Associate Editor for the Journal of Bone & Joint Surgery Open Access and on the Editorial Board for the Journal of Orthopaedic Surgery and Malaysian/ASEAN Orthopaedic Journal.



**MENARINI**

A. Menarini Asia-Pacific Pte Ltd. (994247-1)  
B-18-2, Level 18, The Ascent Paradigm, No.1, Jalan SS7/26A, Kelana Jaya, 47301 Petaling Jaya, Selangor D.E. Malaysia.  
Tel: (+603) 7985 7000 / 7985 7100 Fax: (+603) 7955 3530  
www.menariniapac.com

MY/SKU/06/20201/07

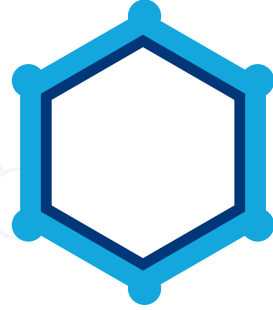

**Weight Loss : The Sleeping  
Giant in Osteoarthritis**

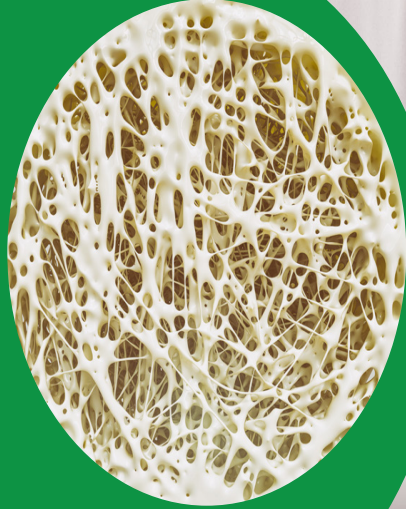
Speaker:  
Dato Dr Tikfu Gee

**June | 22 | 2020**

Time  
12.00pm -  
1.00pm



# Expanding the Role of Orthopedic Surgeons in the Treatment of Osteoporosis



**23 June '21**  
**12.00PM – 1.00PM**

Chairperson



**Dato' Dr. Lee Joon Kiong**

*Consultant Orthopedic Surgeon,*  
Beacon Hospital

Speaker



**Dr. Paul A. Anderson**

*Orthopedic Spine Surgeon,*  
Professor of Orthopedic Surgery and Adjunct Professor in  
Neurological Surgery and Biomedical Engineering, University of Wisconsin

**For Medical/Healthcare Professionals Only**

Before prescribing, please refer to the full prescribing information, which is available upon request.

Please contact Medical Information at 1800 818 227 or [medinfo.JAPAC@amgen.com](mailto:medinfo.JAPAC@amgen.com) for further information or any query.

**AMGEN**

Amgen Biopharmaceuticals Malaysia Sdn. Bhd. (001901011190/1320518-U)  
Suite 9.01, Level 9, Menara Summit, Perstarian Kewajipan, USJ 1,  
UEP, 47600 Subang Jaya, Selangor.

All images are for illustration purposes only.

**prolia**  
(denosumab)injection

10 YEARS  
**STRONG**

Pfizer's lunch symposium is going live. Save the date!

# Current challenges and opportunities of 5<sup>th</sup> generation cephalosporins in treating **COMPLICATED SKIN AND SOFT TISSUE INFECTION (CSSTI)**

24 June 2021 (Thursday)  
Time: 12.00–1.00pm



## Invited speaker

### Dr Chow Ting Soo

Consultant Physician &  
Infectious Disease Consultant,  
Hospital Pulau Pinang,  
Malaysia

Dr Chow Ting Soo is a Consultant Physician and Infectious Disease Consultant at the Infectious Disease Unit at Hospital Pulau Pinang, Malaysia. She is also the Penang State Infection Prevention and Control Coordinator since 2016 and a member of antimicrobial team (AMT) in Hospital Pulau Pinang. She has also been appointed as the Lead Investigator in Malaysia for WHO Solidarity trial during this COVID-19 pandemic.

### What to expect in this symposium?

- Addressing the gaps and challenges in managing cSSTI
- Exploring the role and clinical benefits of ceftaroline in the management of cSSTI
- Case sharing on the efficacy and tolerability of ceftaroline in cSSTI

For Healthcare Professionals Only



**Pfizer (Malaysia) Sdn Bhd** 197801003134 (40131-T)  
Level 10 & 11, Wisma Averis, Tower 2, Avenue 5, Bangsar South,  
No. 8, Jalan Kerinchi, 59200 Kuala Lumpur  
Tel: 603- 2281 6000 Fax: 603- 2281 6388

PP-ZFO-MYS-0156-26APRIL2021

**All around the Meniscus: Meniscal Expert Forum***Brought to you by***Smith+Nephew****Knee Arthroplasty Web Series On Asian Knees***Brought to you by***Smith+Nephew****The Art and Science of Acute Pain Management***By Prof Dr Edward Wang**Brought to you by***MENARINI****Tailoring Osteoporosis Therapy To The Patient's Risk Profile***By S. Ferarri**Brought to you by***AMGEN****Pain Management After Joint Replacement Surgery***By Assoc Prof Dr G Ruslan Nazaruddin Simanjuntak**Brought to you by***Pfizer****Mako Partial Knee And Total Knee***By Dr Hitt and Dr Sastry**Brought to you by***stryker®****Technologies In Total Knee Arthroplasty***By Prof Dr Nor Hamdan, Dr Suhail Suresh, Dato' Dr Lee Keat Hwa**Brought to you by***ZIMMER BIOMET**  
Your progress. Our promise.™**A New Clavicle Plate: Development & First Clinical Experience***By Prof Dr Rainer Meffert**Brought to you by***medartis®****Management of Complex Distal Radius Fracture***By Scott G. Edwards**Brought to you by***medartis®****Innovative Solution for Neck of Femur Trimmed***By Prof Dr Stoffel**Brought to you by***Johnson & Johnson****Inflammatory Back Pain & Ankylosing Spondylitis: Updates For Orthopaedic Surgeons***By Dr Amir Azlan Zain & Prof Dato' Dr Sabarul Afian Mokhtar**Brought to you by***NOVARTIS****The Role of Calcium And Vitamin D In The Treatment Of Osteoporosis***By Dr Yeap Swan Sim**Brought to you by***GlaxoSmithKline**

**>> Virtual Product Theatre****Skudexa Kettesse Virtual Product Theatre Video***Brought to you by***Medartis Virtual Product Theatre Video***Brought to you by***medartis®****Management of Osteoporosis - An Expert Opinion***By Prof Felicia Cosman**Brought to you by***ZBEdge***Brought to you by***Caltrate Virtual Product Theatre Video***Brought to you by***Zinforo – Anti-infectives***Brought to you by***Total Femur – FNS, FRN, TFNA***Brought to you by***Johnson & Johnson****Mako Total and Partial Knee***By Dr Jim Nevelos**Brought to you by***stryker®**

**BEST BASIC SCIENCE POSTER AWARD FINALISTS**

**BBS01** **Rabbit Articular Cartilage Defect Treatment Using The Combined Effect Of Bone Marrow Aspirate Concentrate And Platelet Rich Plasma**  
*Nabillah Abd Radzak, Tunku Kamarul Zaman Tunku Zainol Abidin, Krishnamurthy Genasan, Murali Malliga Raman*

**BBS02** **Metformin Improves Extracellular Matrix Homeostasis Related Genes And Tenogenic Expressions On Insulin Resistance Induced-Human Tenocytes In Vitro**  
*Tan Hui Yee, Tunku Kamarul Zaman Tunku Zainol Abidin, Tan Sik Loo, Teo Seow Hui, Margaret M Roebuck, Simon P Frostick*

**BBS03** **From Osteoarthritic Synovium To Synovial-Derived Cells Characterization: Obese Vs Non-Obese**  
*Chiew Chiaw Lee, Tan Sik Loo, Teo Seow Hui, Khairul Anwar Ayob, Azlina Amir Abbas, Tunku Kamarul Zaman Tunku Zainol Abidin*

**BBS04** **The Prospective Role Of Decellularised Human Amniotic Membrane Incorporated With Platelet-Rich Plasma In Moderating Fibroblast Characteristics Of Mesenchymal Stromal Cells For Acute Large Wound Healing**  
*Ahmad Fuad Ahmad Kamal, Azlina Amir Abbas, Tunku Kamarul Zaman Tunku Zainol Abidin, Sofiah Sulaiman, Krishnamurthy Genasan*

**BBS05** **Perivascular Stem Cells Demonstrate Similar Level Of Stemness, Chondrogenic Ability And Osteoarthritis Repair Potential To Mesenchymal Stromal Cells**  
*Shan Xiaolong, Chong Pan Pan, Tunku Kamarul Zaman Tunku Zainol Abidin*

**P. BALASUBRAMANIAM BEST PUBLISHED TRANSLATIONAL MEDICINE (NON CLINICAL) PAPER AWARD WINNER**

**Uniaxial Cyclic Tensile Stretching At 8% Strain Exclusively Promotes Tenogenic Differentiation Of Human Bone Marrow-Derived Mesenchymal Stromal Cells**  
*Tunku Kamarul Zaman Tunku Zainol Abidin, Nam Hui Yin, Belinda Pinguan-Murphy, Azlina Amir Abbas, Azhar Mahmood Merican*

**MAHMOOD MERICAN BEST MASTERS RESEARCH AWARD FINALISTS**

**MMA01** **A Biomechanical Comparison Of Flexor Tendon Repair Techniques On Fresh Frozen Human Tendon**  
*Rahul Lingam, Shalimar Abdullah, Jamari Sapuan*

**MMA02** **Development And Clinical Trial Of Prototype External Digit Device For Correction Of Digit Flexion Deformity**  
*Nicholas Soong Jin Yih, Sachin Shivdas, Tunku Sara Tunku Ahmad Yahya, Jayaletchumi Gunasagaran, Shams Amir Shamsul Bahar, Khoo Saw Sian*

**MMA03** **Comparison Between The Effect Of Immersive Virtual Reality Training Versus Conventional Rehabilitation On Limb Loading And Functional Outcomes After ACL Reconstruction: Prospective Randomized Controlled Trial**  
*Muhindra Rao Gsangaya, Rashidah Hj Ismail @ Ohnmar Htwe, Murugeaswaran Silvaraju*

**MMA04** **Improving Tendon Repair: The Use Of Human Amniotic Membrane Seeded With Tenogenic Mesenchymal Stem Cells In A Rat Model**  
*Sarah Sheena Toyat, Tan Hui Yee, Mappiare Sahrinanah, Yasmin Fadzlin Ahmad Fikri, Hak Savatey, Tan Lye Hock, Tan Sik Loo, Tunku Kamarul Zaman Tunku Zainol Abidin*

**MMA05** **Low Level Laser Therapy After Neurotization (Oberlin Procedure) In Brachial Plexus Injury: A Randomized Controlled Trial**  
*Foo Yi Hui, Tunku Sara Tunku Ahmad Yahya, Chung Tze Yang, Jeremy Prakash Silvanathan*

**SUBIR SENGUPTA BEST PUBLISHED CLINICAL PAPER AWARD WINNER**

**After-Hours Elective Spine Deformity Corrective Surgery For Patients With Adolescent Idiopathic Scoliosis: Is It Safe?**  
*Chiu Chee Kidd, Chris Chan Yin Wei, Josephine Rebecca Chandren, Ong Jun Yin, Loo Shweh Fern, Mohd Shahnaz Hasan, Kwan Mun Keong*

## Arthroplasty

**10-YEAR OUTCOME OF ELDERLY PATIENTS WITH HIP FRACTURE TREATED WITH BIPOLAR HEMIARTHROPLASTY VS TOTAL HIP ARTHROPLASTY**

*Andrew Lam Weii Cheak*

**ASSESSMENT OF BIOMECHANICAL PROPERTIES OF BONE CEMENT WITH DIFFERENT SEQUENCE OF ADDING VANCOMYCIN POWDER**

*Nur Azree Ferdous Kamudin, Nor Hamdan Mohamad Yahaya, Rizal Abd Rani*

**EARLY EXPERIENCE OF REVERSE TOTAL SHOULDER ARTHROPLASTY IN A PUBLIC HOSPITAL, MALAYSIA**

*Sam Chi Xuan, Abdul Rauf Ahmad, Gandhi Nathan Solayar*

**EFFECTS OF LOW-INTENSITY PULSED ULTRASOUND AS AN ADJUNCT TO CONVENTIONAL PHYSIOTHERAPY ON POST-OPERATIVE PAIN AND FUNCTIONAL ABILITY OF TOTAL KNEE ARTHROPLASTY PATIENTS**

*Munayati Munajar@Munajat, Nor Azlin Mohd Nordin, Ahmad Hafiz Zulkifly, Nor Hamdan Mohamad Yahaya*

**IMPENDING PERIPROSTHETIC FEMUR FRACTURE AROUND A LOOSE FEMORAL STEM**

*Mohammed Harris Anwarali Khan, Kunalan Gantheel, Sasidaran Ramalingam*

**NECK OF FEMUR FRACTURE: TOTAL HIP REPLACEMENT OR BIPOLAR HEMIARTHROPLASTY?**

*Ng Chin Eng, Yeoh Jing Min, Boon Huck Wee, Ngim Hui Ling Joanne*

**NOISE PRODUCTION DURING TOTAL KNEE ARTHROPLASTY: IS IT HAZARDOUS TO SURGEONS AND PATIENTS?**

*Lee Huang Shen, Ng Yee Guan, Imma Isniza, Khairil Anwar Ahmad Hanif, Sasidaran Ramalingam, Tan Chen Wee, Fahrudin Che Hamzah*

**ORAL TRANEXAMIC ACID FOR AN ADDITIONAL 24 HOURS POST-OPERATIVELY VERSUS A SINGLE PRE-OPERATIVE INTRAVENOUS DOSE AT REDUCING BLOOD LOSS FOR TOTAL HIP AND KNEE ARTHROPLASTY - RESULTS OF A RANDOMISED CONTROLLED TRIAL (TRAC-24)**

*Paul Magill*

**OUTCOME OF TOTAL ELBOW ARTHROPLASTY (TEA) AS BAIL OUT PROCEDURE IN COMPLEX ELBOW TRAUMA**

*Sandeep Singh Bhagat Singh, Prashant Narhari, Azuhairy Azid, Indrarajah Asokumaran, Sassidharen Ponnalagu*

**OUTCOME OF TREATMENT OF INFECTED TOTAL HIP REPLACEMENT IN UNIVERSITY MALAYA MEDICAL CENTRE (UMMC) FROM 2010-2019**

*Satpal Singh Charl, Azlina Amir Abbas*

**OUTCOMES OF A CUSTOM MADE ARTICULATING SPACER (CUMARS) IN THE MANAGEMENT OF PERIPROSTHETIC JOINT INFECTION: COMBINING ONE AND TWO STAGE INFECTION ERADICATION STRATEGIES**

*Veenesh Selvaratnam, Jarome Bentley, Sarah J Whitehouse, Matthew JW Hubble, Matthew J Wilson, Jonathan R Howell, John Timperley, John Charity, Al-Amin Kassam*

**PIRIFORMIS-SPARING HIP ARTHROPLASTY IN FEMORAL NECK FRACTURE - SINGLE CENTER EXPERIENCE**

*Tan Shun Herng, Boon Huck Wee, Joanne Ngim Hui-ling, Zulkiflee Osman*

**ROBOTIC ASSISTED PATELLOFEMORAL REPLACEMENT – CORRELATION OF PRE OPERATIVE PLANNING WITH INTRA OPERATIVE IMPLANT POSITION AND EARLY CLINICAL EXPERIENCE: A MINIMUM OF 2 YEARS FOLLOW UP**

*Veenesh Selvaratnam, Andrew Cattell, Keith Eyres, Andrew Toms, Jonathan Phillips, Vipul Mandalia*

**SHORT TERM RADIOLOGICAL EVALUATION FOR ACETABULAR EROSION WITH DIFFERENT BIPOLAR HEMIARTHROPLASTY HEAD SIZE**

*Nor Hamdan Yahaya, Thiru Karthikeyan Ramu, Rizal Rani*

**THE CLINICAL OUTCOMES OF DIRECT ANTERIOR APPROACH IN TOTAL HIP ARTHROPLASTY – KPJ TAWAKKAL EXPERIENCE**

*Parthiban Sivasamy, G Ruslan Simanjuntak, Mohd Yazid Bajuri*

**TRUST YOUR WISDOM OR COMPUTER NAVI: POST TRAUMATIC KNEE ARTHRITIS**

*Mohammed Harris Anwarali Khan, Kunalan Gantheel, Sasidaran Ramalingam*

## Foot &amp; Ankle

**A NOVEL TECHNIQUE OF ISOLATED GASTROCNEMIUS RESECTION: A CADAVERIC COMPARISON WITH STRAYER PROCEDURE AND ITS CLINICAL OUTCOMES***Kow Ren Yi, Aminudin Che Ahmad, Mohd Adham Shah Ayeop, Muhammad Wafiuddin Ahmad, Shahril Yusof***CHRONIC ACHILLES TENDON RUPTURE REPAIRED USING PARS JIG SYSTEM: A CASE REPORT***Syahril Izwan Alias, Mohd Adham Shah Yeop, Aminudin Che Ahmad***COST MANAGING DIABETIC FOOT ULCER BURDEN AT DISTRICT HOSPITAL; PREVENTION IS BETTER THAN CURE***Ahmad Baihaqi Abd Rahman***FOOT CARE PRACTICE: AN INDEPENDENT RISK FACTOR FOR DIABETIC FOOT ULCER IN TYPE 2 DIABETES MELLITUS***Khaw Yam Chuan, Emil Fazliq Mohd, Chew Xin Wee***THE "COMBO FIXATION" FOR UNUSUAL LARGE SIZE CALCANEAL FRACTURE***Asogaameteran Loganathan, Azrul Rashid, Aidilyana Mohamad Shalan, Azammuddin Alias, Mohd Shahril Jaapar***THE DEVELOPMENT OF NEWLY HINGED ANKLE EXTERNAL FIXATOR AND ITS BIOMECHANICAL STABILITY OUTCOME***Muhammad Fathi Hayyun, Mohd Yazid Bajuri, Ahmad Kamal Ariffin Mohd Ihsan*

## Hand

**10 YEAR OUTCOME OF PAEDIATRIC REIMPLANTATION AND REVASCULARIZATION IN HOSPITAL SELAYANG***Syahril Rizal Arsad, Wan Nurulfaiza Akmal Wan Salam, Rashdeen Fazwi Muhammad Nawawi***A COMPARISON OF DELTA WIRE TECHNIQUE VERSUS EXTENSION BLOCK PINNING IN THE TREATMENT OF BONY Mallet Finger***Chee Wai Hong, Jayaletchumi Gunasagaran, Tunku Sara Tunku Ahmad Yahaya***A RANDOMISED CONTROLLED TRIAL BETWEEN BURIED VS EXPOSED KIRSCHNER WIRES IN HAND & WRIST FIXATIONS***Ngiam Choong Jin, Shalimar Abdullah, Jamari Sapuan, Parminder Singh***A RANDOMISED CONTROLLED TRIAL OF FLEXOR TENDON TRACTION TENOLYSIS IN TRIGGER FINGER RELEASE***Syed Jeffrey Syed Ahmad Kabeer, Shalimar Abdullah***CARPAL TUNNEL SYNDROME POST TRIGGER FINGER RELEASE. A PROSPECTIVE COHORT STUDY***Azrul Syamin Hisyam Yong, Fadzli Ramidi, Aaron Gerard Paul, Mohd Hisam Ariffin, Azmi Baharudin***CASE SERIES OF NON SPECIFIC VOLAR WRIST SWELLINGS IN AN URBAN TERTIARY CENTRE***Emir Mustaqim Zulkharnain***CORRELATION BETWEEN VOLAR PLATE POSITION IN DISTAL END RADIUS FRACTURE FIXATION AND IMPLANT REMOVAL FOLLOWING SURGERY***Syed Jeffrey Syed Ahmad Kabeer***DE QUERVAIN'S TENOSYNOVITIS: A RANDOMIZED CONTROL STUDY COMPARING SINGLE CORTICOSTEROID INJECTION VERSUS PHYSIOTHERAPY WITH SPLINT***Herman Jana Mulok, Shalimar Abdullah***DIAMETER OF DIGITAL ARTERIES AND THEIR CORRELATION WITH FINGER ANTHROPOMETRIC MEASUREMENTS – A PRELIMINARY CADAVERIC STUDY***Lau Chun Liang***DISTAL HUMERUS EPIPHYSEAL SEPARATION IN NEWBORN: A CASE REPORT***Mohd Radzi Khairudin, Bardrul Aznil Ismail, Muhammad Farhan Yahaya, Sopian Shuib, Anizar Faizi Anoar, Muhammad Sallehuddin Hassan***EVALUATION OF CARPAL TUNNEL PRESSURE IN SUPRARETINACULAR ENDOSCOPIC CARPAL TUNNEL RELEASE COMPARED TO CONVENTIONAL ENDOSCOPY CARPAL TUNNEL RELEASE: A CADAVERIC STUDY***William Choo Ch'ng Hwei*



**FLEXOR TENDON DEGENERATION: DOES IT INFLUENCE THE OUTCOME OF OPEN TRIGGER FINGER RELEASE?***Mardhiyah Abdul Nasir***FUTILE CLOSED REDUCTION OF DISLOCATION OF CARPOMETACARPAL JOINT OF THUMB – CASE REPORT***Mooi Sung Siang, Jeremy Prakash Silvanathan***HAND AND MICROSURGERY: BEYOND THE UPPER LIMB***Rashdeen Fazwi Muhammad Nawawi, Syahril Rizal Arsad***MINIMIZING PAIN EXPERIENCE IN TRIGGER FINGER STEROID INJECTION***Chuah Sion Keat, Shalimar Abdullah, Jamari Sapuan***MODEL FOR MICROSURGICAL TRAINING: COMPARISON OF BIOMECHANICAL PROPERTIES BETWEEN HUMAN CADAVERIC DIGITAL ARTERY, RAT FEMORAL ARTERY AND LATEX MICROTUBE***Muhd Husyaini Hasni, Tunku Sara Tunku Ahmad Yahaya, Shams Amir Shamsul Bahar***“MY NAIL LOST ITS BED” - A CASE OF SPLIT THICKNESS TOE NAIL BED GRAFT FO LARGE NAIL BED DEFECT***Selvakumar Murthy, Mastura Hassim, Denny Clare***PRELIMINARY RESULTS OF VEIN WRAPPING FOR TREATING HYPERAESTHESIA OF THE SUPERFICIAL SENSORY RADIAL NERVE***Nur Azree Ferdaus Kamudin, Shalimar Abdullah***TIME OF INTERVENTION IN CONTRIBUTING TO OUTCOME OF BRACHIAL PLEXUS INJURY: AN EIGHT YEARS EPIDEMIOLOGY OUTCOME STUDY***Tan Yin Ying***TRIGGER FINGER OR SOMETHING ELSE? – A CASE REPORT***Mooi Sung Siang, Jeremy Prakash Silvanathan, Mohd Reza Mohd Aridz***UPPER LIMB INFECTIONS: A COMPARISON BETWEEN DIABETIC AND NON-DIABETIC PATIENTS***Lim Shan Hua, Jayaletchumi Gunasagaran***LLRS****BONE CHIPPING TECHNIQUE IN TREATING DOCKING SITE NON-UNION AS COMPARED TO AUTOLOGOUS ANTERIOR ILIAC BONE GRAFT***Siti Munira Seri Masran, Rohaman Tasarib***BONE TRANSPORT OVER LOCKING COMPRESSION PLATE FOR A CASE OF FEMUR NON-UNION***Khairul Rizal Zayzan***EXPERIMENT ON THE EFFECT OF IRRIGATION VIA DOUBLE BARREL DRILL SLEEVE ON CORTICAL BONE TEMPERATURE DURING DRILLING***Muhammad Lutfi Abdul Rashid, Saw Aik, Muhammad Ziyad Abduljabbar Albaker, Saravana Ramalingam, Mohd Rusdi Draman@Yusof, Devarani Pancharatnam***QUALITY OF LIFE & FUNCTIONAL OUTCOME OF OPEN TIBIAL FRACTURE TREATED WITH ILIZAROV EXTERNAL FIXATOR AS DEFINITIVE MANAGEMENT***George Ezekiel, Nazri Mohd Yusof, Rohaman Tasarib***RAPID RECOVERY OF SEVERE PROSTHETIC JOINT INFECTION FOLLOWING KNEE ARTHRODESIS VIA ILIZAROV EXTERNAL FIXATOR***Khairul Rizal Zayzan***TREATMENT OF HUMERUS NON-UNION USING MONORAIL GRADUAL COMPRESSION: A CASE SERIES***Khairul Rizal Zayzan*

## Oncology

**A COMPARISON OF CONTINUOUS LOCAL ANAESTHESIA INFUSION AND PARENTERAL NARCOTICS FOLLOWING WIDE RESECTION SURGERY OF SOFT TISSUE TUMORS: A PRELIMINARY STUDY**

*Mohd Daniel Djamalludin, Nor Faissal Yassin, Vivek Ajit Singh*

**A PECULIAR CASE OF A RECURRENT METACHRONOUS MYXOFIBROSARCOMA OF THE LEFT LOWER LIMB IN THE YOUNG**  
*Ng Xiang Yin, Alexander Samuel Thavamany Devapitchai, Yong Dianah Mohd Ali Yeo, Logheswaren Suppiah, Azuhairi Azid*

**A RETROSPECTIVE STUDY OF PROGNOSTIC FACTORS, TREATMENT MODALITIES AND OUTCOME OF SOFT TISSUE SARCOMA OF EXTREMITIES: AN UKMMC EXPERIENCE**

*Law Soon Kang, Nor Hazla Mohamed Hafilah*

**DENOSUMAB IN GIANT CELL TUMOUR OF BONE. PENANG EXPERIENCE**

*Tan Shun Herng, Prashant Narhari, Sanjeevan Radhakrishan, Choong Chee Leong, Azuhairy Azid, Zulkiflee Osman*

**ESTABLISHING SARCOMA NETWORK FOR NORTHERN PENINSULAR MALAYSIA. 1ST STEP INTO A WONDERFUL JOURNEY**

*Prashant Narhari*

**HAND AND FOOT TUMORS : A 10 YEARS RETROSPECTIVE ANALYSIS**

*Choo Tze Yong, Nor Faissal Yasin*

**OUR EXPERIENCE IN PSEUDOTUMOUR IN HEMOPHILIC PATIENTS - PERIOPERATIVE AND SURGICAL APPROACH**

*Tan Shun Herng, Mohd Firdaus Hafni Ahmad, Prashant Narhari, Sanjeevan Radhakrishnan, Choong Chee Leong, Azuhairy Azid, Zulkiflee Osman*

**THE CLINICAL OUTCOME OF PULMONARY METASTECTOMY IN MUSCULOSKELETAL SARCOMA PATIENTS IN A SINGLE CENTRE: A RETROSPECTIVE COHORT STUDY**

*Thinesh Varan Subramaniam*

## Orthopaedic Research

**A STUDY TO DETERMINE THE EFFECTS OF IN VITRO CELL CULTURE AND OXIDATIVE STRESS ENVIRONMENTS ON THE CYTOKINE PROFILE OF BONE MARROW STROMAL CELLS ISOLATED FROM OSTEOARTHRITIC AND DIABETIC OSTEOARTHRITIC PATIENTS**

*Loh Kar Wai, Balaji Raghavendran Hanumantharao, Tunku Kamarul Zaman Tunku Zainol Abidin*

**COMPARISON BETWEEN INJECTABLE AND IMPLANTABLE COMBINATION OF MESENCHYMAL STEM CELLS, PLASMA RICH PLATELET AND CERAMIC IN TREATMENT OF CRITICAL SIZE LONG BONE DEFECT**

*Nur Dina Azman, Nor Hazla Mohd Hafilah, Angela Min Hwei*

**THE PRESENCE OF DIFFERENTIAL STRAIN PATTERNS AND MECHANICAL PROPERTIES IN TENDONS ARE DEPENDENT ON REGIONAL CROSS-SECTIONAL CIRCUMFERENCE**

*Tan Han Ling, Nam Hui Yin, Tunku Kamarul Zaman Tunku Zainol Abidin*

## Others

**ADHERENCE TO ANTI-OSTEOPOROTIC MEDICATION AFTER ONE YEAR FOLLOW-UP WITH FRACTURE LIAISON SERVICE IN HOSPITAL CANSELOR TUANKU MUHRIZ, MALAYSIA**

*Juzaily Fekry Leong, Siti Syakirah Mohd Shaibi, Kimberley Xi Ling Law, Mei Kuan Yin, Shun Ting Ooi, Levin Kesu Belan, Rizal Abdul Rani, Sabarul Afian Mokhtar*

**CAN BIOMECHANICAL PROPERTIES OF LONG BONE ALLOGRAFTS BE PRESERVED DESPITE UNDERGOING GAMMA RADIATION? A SECRET SHARED**

*Saravana Ramalingam, Suhaili Mohd, Tuti Erwani Aswoto, Norimah Yusof, Azura Mansor*

**COMPARISON OF LOW VERSUS HIGH PRESSURE NEGATIVE PRESSURE WOUND THERAPY (NPWT) IN DIABETIC FOOT WOUND ON WOUND SIZE REDUCTION AND WOUND BED PREPARATION: A RANDOMIZED SINGLE BLINDED STUDY**

*Amran Ahmed Shokri, Muhammad Rajaei Ahmad @ Mohd Zain, Nor Hafizah Zairullail, Shaifuzain Abd Rahman*

**EFFECT AND SAFETY OF CULTURE-EXPANDED HUMAN WHARTON'S JELLY-DERIVED MESENCHYMAL STEM CELL INTRA-ARTICULAR INJECTION INTO ANIMAL MODEL OF OSTEOARTHRITIC KNEE**

*Or Su-Yin, Badrul Akmal Hisham Md. Yusoff, Ahmad Farihan Md. Don, Norlelawati Mohamad, Reena Rahayu Md Zin*

**EVALUATION OF FUNCTIONAL AND PSYCHOLOGICAL OUTCOME OF MAJOR AMPUTATION OF LOWER LIMBS**

*Hrishinilaavenn Muthusamy, Ardilla Hanim Abdul Razak, Salmah Anim Abu Hassan*

**IS CANAL-TO-DIAPHYSIS RATIO A VALID PARAMETER TO ASSESS BONE MINERAL DENSITY IN ELDERLY POPULATION WITH HIP FRACTURE?**

*Tan Yong Lin, Mohd Adham Shah Ayeop, Zulkefli Atan*

**MORTALITY AND MORBIDITY FOLLOWING OSTEOPOROTIC FRACTURE IN A FRACTURE LIAISON SERVICE HOSPITAL - A PROSPECTIVE STUDY**

*Juzaily Fekry Leong, Divan Ganesh, Shin Ting Ooi, Levin Kesu Belani, Rizal Abdul Rani, Ahmad Farihan Mohd Don, Mei Kuan Yin, Sabarul Afian Mokhtar*

**OSTEOPOROSIS KNOWLEDGE AND AWARENESS AMONG MEDICAL STUDENTS IN MALAYSIA**

*Kimberly Law Xi Ling, Ooi Shun Ting, Nuraina Shaheera Zainal Abidin, Juzaily Fekry Leong, Sabarul Afian Mokhtar*

**RISK ASSESSMENT OF FRAX: WITH OR WITHOUT BMD?**

*Juzaily Fekry Leong, Zer Liang Ng, Kimberley Xi Ling Law, Shun Ting Ooi, Rizal Abdul Rani, Levin Kesu Belani, Ahmad Farihan Mohd Don, Sabarul Afian Mokhtar*

**U-SHAPED SPINOPELVIC DISSOCIATION TREATED WITHOUT OPEN SACRAL DECOMPRESSION**

*Esanikarupiah Jagathisen*

## Paediatric

**A 20 YEAR STUDY OF CLINICAL AND RADIOLOGICAL OUTCOME OF DEVELOPMENTAL DYSPLASIA OF HIP (DDH) SURGERY**

*Mohammad Rostam Saharuddin, Muhammad Kamal Muhd Abdul Jamil, Abdul Halim Abdul Rashid, Sharaf Ibrahim*

**A COMPARISON STUDY ON HINDFOOT CORRECTION BETWEEN CLUBFOOT PATIENTS TREATED WITH PERCUTANEOUS ACHILLES TENDON TENOTOMY VERSUS CASTING ALONE USING PONSSETI METHOD**

*Saturveithan Chandirasegaran, Roshan Gunalan, Saw Aik, Shaleen Kaur*

**ASSESSMENT OF TREATMENT OUTCOMES OF CONGENITAL FIBULAR HEMIMELIA: TO PRESERVE OR TO AMPUTATE?**

*Sakinah Mohd Razali, Abdul Halim Ab Rashid, Sharaf Ibrahim*

**DOES RANGE OF MOTION IMPROVEMENT INCREASE FUNCTIONAL MOBILITY IN ALL CEREBRAL PALSY CHILDREN? A SINGLE CENTRE STUDY**

*Syed Azhariff Syed Yahya, Rashidah Ismail @ Ohnmar Htwe, Manimalar Selvi Naicker, Abdul Halim Ab Rashid, Brenda Saria, Amaramalar Selvi Naicker*

**OUTCOME OF NON-OPERATIVE TREATMENT OF T-TYPE SUPRACONDYLAR HUMERUS FRACTURE IN CHILDREN: A CASE SERIES**

*Raimi Adam Chen, Johan Abdul Kahar, Ahmad Anuar Sofian, Muhammad Najmi Ab Ghani, Imma Isniza Ismail, Anand Sobhraj Devnani*

**POTT'S DISEASE WITH DISSEMINATED TUBERCULOSIS IN A 2-YEAR-OLD TODDLER: A CASE REPORT**

*Dinesh Rajandran*

**Spine****ACCURACY AND ADEQUACY OF FLUOROSCOPIC ASSISTED PERCUTANEOUS TRANSPEDICULAR BIOPSY IN COMPARISON TO CT GUIDED PERCUTANEOUS TRANSPEDICULAR BIOPSY IN SPINAL LESIONS**

*Zamzuri Zakaria, Abdullah A Rahim*

**ACCURACY, SAFETY AND DIAGNOSTIC OUTCOME OF PERCUTANEOUS FLUOROSCOPIC VS CT GUIDED TRANSPEDICULAR CORE NEEDLE BIOPSY FOR SPINAL INFECTIONS AND TUMOURS. A PROSPECTIVE RANDOMIZED TRIAL**

*She Ann Lee, Chee Kidd Chiu, Chris Yin Wei Chan, Nur Adura Yaakup, Jeannie Hsiu Ding Wong, Khairul Azmi Abd Kadir, Mun Keong Kwan*

**BREAST ASYMMETRY IN ADOLESCENT IDIOPATHIC SCOLIOSIS (AIS) PATIENTS WITH STRUCTURAL THORACIC CURVE: A COMPUTED TOMOGRAPHY (CT) ANALYSIS AND ASSESSMENT OF PATIENTS' PERCEPTION USING THE BREAST-Q QUESTIONNAIRE**

*Chris Chan Yin Wei, Tan Heng Keat, Siti Mariam Mohamad, Chung Weng Hong, Chiu Chee Kidd, Kwan Mun Keong*

**CERVICAL SPINE TUBERCULOSIS – A CASE SERIES IN SABAH**

*Jimmy Lim Teik Loong, Foo Choong Hoon, Bong Chin Pei, Norisyam Yusoff*

**CLINICAL OUTCOME OF LUMBAR FACET JOINTS INJECTION IN PATIENTS WITH FACET JOINTS SYNDROME**

*Loh Li Loong, Zamzuri Zakaria, Rajandra Kumar*

**LUMBAR RADICULOPATHY SECONDARY TO SOLITARY SPINAL OSTEOCHONDROMA – A RARE CAUSE OF A COMMON COMPLAINT**

*Jimmy Lim Teik Loong, Foo Choong Hoon, Bong Chin Pei, Norisyam Yusoff, Rosalind Wong Huey Yin*

**MULTIETHNIC STUDY OF PELVIC PARAMETERS IN A MALAYSIAN COHORT**

*Rahayu Fazleen Radzuan, Isma Liza Mohd Isa, Ng Bing Wui, Tan Jin Aun, Faizah Mohd Zaki, Sabarul Afian Mokhtar*

**POSTERIOR DECOMPRESSION, INSTRUMENTATION AND TRANSPEDICULAR BONE GRAFTING IN THORACOLUMBAR TUBERCULOUS SPONDYLODISCITIS**

*Abdul Rahman Nik Mazian, Mohd Shukry Mat Eil @ Ismail, Che Mohd Hanif Che Mat, Zakaria Yusoff, Ahmad Sabri Omar*

**SPINAL FUSION FOR ADOLESCENT IDIOPATHIC SCOLIOSIS: DOES FUSION AT T2, T3 OR T4 AFFECT THE RANGE OF MOTION OF CERVICAL SPINE AND THE FUNCTIONAL OUTCOME AT THE CERVICAL SPINE?**

*Kesavan Ramachandran, Kamalnizat Ibrahim, Mohd Hisam Muhammad Arrifin, Azmi Baharudin, Sabarul A. Mokhtar*

## Sports

**COMBINED HIGH TIBIAL OSTEOTOMY AND ANTERIOR CRUCIATE LIGAMENT RECONSTRUCTION FOLLOWING FEMORAL FRACTURES. A CASE SERIES**

*Janusya Sivananthan, Dinesh Noel Gomez, Abdul Rauf Ahmad, Gandhi Nathan Solayar*

**HOW SAFE IS THE MEDIAL PORTAL IN SHOULDER ARTHROSCOPIC SURGERY: A CADAVERIC STUDY**

*Wong Yih Jiun, Teo Seow Hui, Ng Wuey Min*

**INJURY INCIDENCE, PATTERNS AND RISK FACTORS IN FUNCTIONAL TRAINING ATHLETES IN AN ASIAN POPULATION**

*Timothy Cheng, Azura Mansor, Lim Yi Zhen, M Tanveer Hossain Parash*

**REGENERATION OF MEDIAL HAMSTRING TENDONS FOLLOWING HARVEST FOR ANTERIOR CRUCIATE LIGAMENT RECONSTRUCTION: A COMPARISON BETWEEN TWO DIFFERENT HARVESTING TECHNIQUES**

*Low Chin Aun, Teo Seow Hui, Ng Wuey Min*

## Trauma

**A DEMOGRAPHIC STUDY OF NON-UNION RATE OF ISOLATED TIBIA SHAFT FRACTURE WITH INTACT FIBULA IN A SINGLE CENTRE**

*Vernon Tan Sze Yuen, Ong Lik Han*

**BILATERAL ATYPICAL FEMORAL FRACTURE SECONDARY TO LONG TERM USE OF INTRAVENOUS BISPHOSPHONATE TREATMENT IN METASTATIC BONE DISEASE - SEREMBAN EXPERIENCE**

*Denesh Kumar Shunmugam, Aruna Rama Jayam, Rajesh Rampal, Abdul Rauf Ahmad*

**BRIDGING THE GAP: MONORAIL EXTERNAL FIXATOR ACHIEVING OSTEOSYNTHESIS IN COMPLEX LONG SEGMENT DEFECT OF HUMERUS**

*Darshan Krishna Kumar, Sree Raja Lakshmy Chandra Sekaran, Low Chin Aun, Dziya Faqhran, Razin John Shah, Velman Shri Jaya, Mohammad Nuril Anwar, Mohd Azrin Muhammad Asihin*

**CASE REPORT: TWO IS BETTER THAN ONE; DOUBLE-PLATING OF COMPLEX C3-TYPE DISTAL FEMUR FRACTURES**

*Esther Lee Hui Li, Tie Teck Liang*

**CASE SERIES: A "LISFRANC" INJURY OF THE HAND**

*Esther Lee Hui Li, William Hau Wuei Huang*

**CORONA MORTIS IN MULTIRACIAL ASIAN HEMIPELVIS IN A MALAYSIAN TERTIARY HOSPITAL: A STUDY OF 82 CADAVERS**

*Nur Ayuni Khirul Ashar, Imma Isniza Ismail, Paisal Hussin, Mohd Nizlan Mohd Nasir, Mohd Hezery Harun*

**EFFICACY OF POVIDONE-IODINE IN ERADICATING STAPHYLOCOCCUS AUREUS BIOFILM ON STAINLESS STEEL ALLOY 316L USING COLONY FORMING UNIT AND SCANNING ELECTRON MICROSCOPE AS VERIFICATION**

*Ahmad Anuar Sofian, Fahrudin Che Hamzah, Syafinaz Amin Nordin, Narcisse Joseph, Vasantha Kumari Neela, Khairul Anwar, Ashraf Hakim Ab Halim*

**EXPOSED TRUTHS: MANAGING MRSA SURGICAL SITE INFECTION WOUND WITH EXPOSED IMPLANT USING ANTIBIOTIC CEMENT POUCH AND NPWT**

*Danial Fa-iz Ibrahim, Muhammad Azrin Mohd Asihin*

**EXTERNAL FIXATION OF INFECTED NONUNION OF THE HUMERAL SHAFT: A RETROSPECTIVE STUDY OF 14 CASES**

*Nuradeen Altine Aliyu*

**FRACTURE LIAISON SERVICE (FLS) IN MANAGING OSTEOPOROTIC FRACTURE, UKM MEDICAL CENTRE EXPERIENCE**

*Juzaily Fekry Leong, Divan Ganesh, Shin Ting Ooi, Levin Kesu Belani, Rizal Abdul Rani, Ahmad Farihan Mohd Don, Mei Kuan Yin, Norhazlina Abdul Wahab, Hazlina Mahadzir, Devinder Kaur Ajit Singh, Zunaidah A Samah, Sabarul Afian Mokhtar*

**IMPLANT-ASSOCIATED TUBERCULOSIS INFECTION - ANOTHER MANIFESTATION OF THE GREAT MIMICKER**

*Jimmy Lim Teik Loong, Foo Choong Hoon, Bong Chin Pei, Norisyam Yusoff*

**INCIDENCE OF DEEP VEIN THROMBOSIS IN PATIENTS WITH PELVIC AND ACETABULUM FRACTURES IN UNIVERSITI SAINS MALAYSIA: IS PREOPERATIVE SCREENING WITH DOPPLER ULTRASOUND NECESSARY?***Mohd Hadizie Din, Yolanda Boniface Deyoi***IPSI LATERAL SUBTROCHANTERIC AND SUPRACONDYLAR FEMUR FRACTURE, FRACTURE FIXATION EXPERIENCE: A CASE REPORT***Normawathy Amir Osman, Sanjeevan Radhakrishnan, Wan Assanul Azfan Wan Ali***IS TIMING OF INITIAL DEBRIDEMENT REALLY CORRESPOND TO FRACTURE-RELATED INFECTION IN OPEN TIBIA FRACTURE?***Kor Yee Sang, Mohd Hadizie Din***MODIFIED SUPRA-ACETABULAR EXTERNAL FIXATION FOR INITIAL MANAGEMENT OF PELVIC RING INJURY: A CASE REPORT***Sree Raja Lakshmy Chandra Sekaran, Darshan Kumar***MORTALITY OUTCOME OF OSTEOPOROTIC HIP FRACTURE IN HOSPITAL CANSOLOR TUANKU MUHRIZ: OPERATIVE VERSUS NON-OPERATIVE INTERVENTION***Nuraina Shaheera Zainal Abidin, Kimberly Law Xi Ling, Juzaily Fekry Leong, Rizal Abdul Rani, Sabarul Afian Mokhtar***NEGLECTED COMPARTMENT SYNDROME OF LEFT FOREARM IN A 2 YEARS OLD BOY: A CASE REPORT***Lai Min Chung, Goh Teik Chiang, Jeeva Shanumugam, Dinesh Rajadran, Hesootharan Govindarajan***OPERATIVE MANAGEMENT OF LATERAL THIRD CLAVICLE FRACTURES; A FIVE YEAR REVIEW IN A REGIONAL TRAUMA UNIT***Patrick Hickland, Christopher Goodland, Sunil Zachariah, Lynn Murphy, Martyn Neil***OUTCOME OF HUMERAL SHAFT FRACTURES TREATED WITH INTRAMEDULLARY NAIL***Kathleen Teo Khai Ling, Rushdi Isnin, Tiew Sei Kern***OUTCOMES OF ACUTE FIX AND REPLACE IN COMPLEX HIP POSTERIOR FRACTURE DISLOCATIONS WITH ACETABULAR FRACTURES: A MINIMUM OF 3 YEARS FOLLOW UP***Veenesh Selvaratnam, Sunil Panchani, Henry Wynn Jones, Amol Chitre, Anthony Clayson, Nikhil Shah***OUTCOMES OF ANTEGRADE NAILING VERSUS RETROGRADE NAILING IN TREATMENT OF FEMORAL DIAPHYSEAL FRACTURES***Low Jian Wei, Eo Chun Keat, Tharumaraja Thiruselvam***OUTCOMES OF LOCKED INTRAMEDULLARY NAIL PROCEDURE IN CLOSED DIAPHYSEAL FEMUR FRACTURE IN RELATION TO TIMING OF SURGERY***Ng Min Guan, Bryan Teoh Ching Eng, Rajandra Kumar Karupiah, Zamzuri Zakaria***RIM PLATING USING MODIFIED EXTENDED ANTEROLATERAL APPROACH FOR POSTEROLATERAL TIBIAL PLATEAU FRAGMENT – CASE REPORT***Eo Chun Keat***SUPRAPATELLAR ENTRY FOR INTRAMEDULLARY NAILING OF TIBIAL SHAFT FRACTURE – CASE SERIES***Eo Chun Keat, Tharumaraja Thiruselvam***THE TERRIBLE TRIAD OF THE FLOATING SHOULDER - A CASE OF COMPLEX IPSILATERAL SCAPULA, CLAVICLE & PROXIMAL HUMERUS FRACTURES***Ahmad Arieff Atan, Zamri Ab Rahman, Khairul Rizal Zayzan, Norhaslinda Bahaudin, Abdul Rauf Ahmad*

## Arthroplasty

**CABLE PLATING IN TREATING PERI-IMPLANT FRACTURE OF FEMUR**

*Ooi Tek Zwee, Leong Jie Xiang, Kularaj Subramaniam, Syed Addi Usmi Syed Othman*

**CASE REPORT: DEATH OF BIPOLAR HEMIARTHROPLASTY - MEETING PATIENT EXPECTATION**

*Mohammed Harris Anwarali Khan, Kunalan Ganthel, Sasidaran Ramalingam*

**CASE REPORT: SEVERE VALGUS KNEE TOTAL KNEE ARTHROPLASTY**

*Mohd Shahir Aziz, Muhammad Warith Effendi, Mohamad Fauzlie Yusof, Mohd Norfahmi Md Hashim, Ammar Abdol Hamid*

**CEFZOLIN-INDUCED NEUTROPENIA CAUSING STREPTOCOCCUS MITIS SEPSIS IN PATIENT UNDERGOING TREATMENT FOR PROSTHETIC JOINT INFECTION**

*Samuel John Jebasingam Issace, Fahrudin Che Hamzah, Khairil Anwar Ahamd Hanif*

**DOUBLE WHAMMY – METACHRONOUS PROSTHETIC JOINT INFECTION**

*Nadiya Hazizan, Muhamad Amiruddin Abdul Razak, Shahrul Hisham Sulaiman, Satriya Sabir Husin Athar*

**DOUBLE WHAMMY: PROSTHETIC HIP TUBERCULOSIS SUPERIMPOSED WITH ESBL INFECTION**

*Maria Mardi, Sharifah Nor Tasnim Alsagoff, Shahrul Hisham Sulaiman, Satriya Sabir Husin Athar*

**FEMORAL STEM FRACTURE IN POST TOTAL HIP REPLACEMENT**

*Nanchappan Selvanathan, Sasidaran Ramalingam, Suresh Chopra*

**I CHOOSE TO MAKE THE REST OF MY LIFE THE BEST OF MY LIFE: AVASCULAR NECROSIS OF FEMUR HEAD WITH PELVIS ADDUCTION CONTRACTURE**

*Mohammed Harris Anwarali Khan, Kunalan Ganthel, Sasidaran Ramalingam*

**IMPACTED BUT SHE'S UNAFFECTED. A CASE REPORT**

*Muhammad Ikhwan Yusuf, Mohd Syazwan Che Seman, Mohd Ihsan Hamdan, Jaya Thilak Shaanmugam*

**LET THE RAIN WASH AWAY ALL THE PAIN OF YESTERDAY - HEMIARTHROPLASTY REVISION**

*Gan Yun Han*

**MODULAR DUAL MOBILITY DISLOCATION POST REVISION OF FAILED PROXIMAL FEMORAL NAIL FOR COMMUNUTED INTERTROCHANTER FRACTURE**

*Nanchappan Selvanathan, Noor Sa'adah Kasim, Ahmad Fauzey Kassim*

**NEGLECTED 4 PART HUMERUS FRACTURE WITH IPSILATERAL BRACHIOCEPHALIC FISTULA (BCF), TO FIX OR REPLACE?**

*Megat Mohammad Fakhri Kamaruzaman, Narinder Singh Joginder Singh*

**NEGLECTED DEVELOPMENTAL DYSPLASIA OF HIP: A CASE REPORT**

*Ling Lii Tat, Ong Lik Han, Faris Kamaruddin*

**NEGLECTED NECK OF FEMUR FRACTURE WITH ACETABULAR EROSION REQUIRING INTRAOPERATIVE CHANGE OF DECISION**

*Jagjoth Singh Darshan Singh, Leong Li Theng, Terence Michal Dass*

**OUTCOME OF RADIAL HEAD REPLACEMENT IN TRAUMA: A CASE REPORT**

*Sree Raja Lakshmy Chandra Sekaran, Low Chin Aun, Muhammad Azrin Mohd Asihin, Shangeetha Tharmalinggam, Darshan Krishnan, Tungku Naziha Tunku Zainudin, Nur Rahimah Abdul Rahim*

**PENANG PROTOCOL : STANDARDIZED WASH OUT REGIME FOR INFECTED ARTHROPLASTY**

*Kenneth Chun Kok Sheng, Chang Hui Xian, Boon Huck Wee, Ngim Hui-ling Joanne, Chua Hwa Sen, Lee Keat Hwa*

**PERI-PROSTHETIC FEMUR FRACTURE POST HIP ARTHROPLASTY, A CHALLENGE IN TREATMENT: CASE REPORT**

*Nur Hazwani Halim, Normughni Fikirudin, Wong Chia Sing*

**POSSIBILITY OF A LATE INFECTION OF TOTAL KNEE ARTHROPLASTY FOLLOWING DENTAL PROCEDURE**

*Tan Joo Boon, Ngim Hui-Ling Joanne, Zulkiflee Osman*

**POSTERIOR DISLOCATION OF MENISCAL BEARING IN UNICOMPARTMENTAL KNEE ARTHROPLASTY: CASE REPORT***Lee Zhi Cheong, Chuah Jia Peng, Shahrul Hisham Sulaiman***PSEUDOMONAS AERUGINOSA AND MYCOBACTERIUM TUBERCULOSIS CO-INFECTION IN A PATIENT WITH PERIPROSTHETIC JOINT INFECTION***Diyanthini Panneerselvan, Jade Pei Yuik Ho, Tejinderpal Singh***QUADRICEPS MUSCLE RUPTURE RARE COMPLICATION OF TOTAL KNEE ARTHROPLASTY: A CASE REPORT***Mohd Shahir Aziz, Muhammad Warith Effendi, Mohamad Fauzlie Yusof, Mohd Norfahmi Md Hashim, Ammar Abdol Hamid***RECURRENT SYNOVIAL CHONDROMATOSIS WITH SECONDARY OSTEOARTHRITIS***Chin Siang Leon, Ngo Pei Ern, Ho Shu Chien***REVISION TOTAL HIP ARTHROPLASTY WITH PROXIMAL BONE LOSS USING WAGNER FEMORAL STEM, PLATE AND CABLE FIXATION***Nicholas Soong Jin Yih, Khairul Anwar Ayob, Azhar Mahmood Merican***SHOULDER SEPTIC ARTHRITIS - A CASE REPORT***Muhd Ilyasa Muhammad Khidir***THE CHALLENGES OF TOTAL HIP ARTHROPLASTY IN ADULT DYSPLASTIC HIP***Tan Yin Ying, Khairul Anwar Ayob, Azhar Mahmood Merican***THE CURRENT PRACTICE OF FILIPINO ORTHOPEDIC SURGEONS IN THE MANAGEMENT OF ELDERLY HIP FRACTURES***Sean Paulo C. Padilla, Michael DR. Munoz***THERE IS A DIFFERENCE BETWEEN GIVING UP AND KNOWING WHEN YOU HAVE HAD ENOUGH: CANDIDA PARAPSILOSIS***Mohammed Harris Anwarali Khan, Kunalan Gantheel, Sasidaran Ramalingam***THERE'S ALWAYS A TOMORROW AND THE HOPE OF SOMETHING NEW - REVISION ASEPTIC LOOSENING BIPOLAR HEMIARTHROPLASTY***Mohammed Harris Anwarali Khan, Kunalan Gantheel, Sasidaran Ramalingam***TOTAL HIP REPLACEMENT IN ADULT DYSPLASTIC HIP. A CASE REPORT***She Ann Lee, Khairul Anwar Ayob, Azlina Amir Abbas, Azhar Mahmood Merican***TOTAL HIP REPLACEMENT IN DEVELOPMENTAL DYSPLASIA OF THE HIP: A CHAPTER OF QUARTER CENTURY***Sasidaran Ramalingam, Kunalan Gantheel, Mohammed Harris Anwarali Khan, Lee Chong Meng***TOTAL KNEE ARTHROPLASTY IN GOUTY ARTHRITIS KNEE: A CASE REPORT***Mohd Subhan Safie, Rajaei Ahmad Mohd Zain, Shaifuzain Ab Rahman, Amran Ahmed Shokri***TOTAL KNEE ARTHROPLASTY IN TERTIARY SYPHILIS NEUROPATHIC ARTHROPATHY***Ling Lee Siang, Seo Soon Teck, Sivapathasundaram C. Nadarajah***WRONG SIDE IMPLANT TOTAL KNEE REPLACEMENT***Muhammad Najib Omar, Sudhagar Krishinan*



## Foot &amp; Ankle

**ABDUCTOR HALLUCIS MUSCLE FLAP FOR THE COVERAGE OF THE MEDIAL MALLEOLAR WOUND***Navindravadhanam Sockalingam, Tharumaraja Thiruselvam***AN ISOLATED DORSO-MEDIAL TARSAL NAVICULAR DISLOCATION: A CASE SERIES***Muhammad Nizamuddin Ghazali, Farrel Mukhesh Rajenthiran, Tan Hong Quan, Mohd Hafizi Mohd Yusof, Zareze Abd Rahman***AN OPEN 180 DEGREE TALUS DISLOCATION WITHOUT FRACTURE: A CASE REPORT***Alexander Samuel, Sivashni Supramaniam, Lingash Therumurteji, Suriya Maniam, Sopain Suhub***A RARE CASE OF CLOSED TOTAL TALUS DISLOCATION IN HTAN: A CASE REPORT***Amri Dahdi, Hamizah Zainal, Faisal Mohd Nor, Muhammad Fahmi Ibrahim, Mohd Shaharil Abd Aziz***A RARE CASE OF PAINFUL FIBROMA ARISING FROM TENDON SHEATH OF FLEXOR HALLUCIS LONGUS***Faris Indra Prahasta Didi Indra, Mohd Yazid Bajuri, Nurwahyuna Rosli***A RARE ENTITY: ISOLATED TALONAVICULAR INSTABILITY IN DIABETIC FEET***Nur Hafizah Mohamad Nor, Yang Sofia Ab Rahim, Hazizul Helmy Hamat @ Ahmad***ATYPICAL PRESENTATION OF LISFRANC FRACTURE DISLOCATION ASSOCIATED WITH HIGH VELOCITY INJURY***Nasrul Hanif Mohamad, Amrik Singh Ranjit Singh, Gurmeet Singh Sewa Singh, Zulkiflee Osman***BACTERIOLOGY OF DIABETIC FOOT INFECTION IN HOSPITAL TELUK INTAN***Kathiravan Murugan, Thaneshwara Rao Apanna, Muhammad Taufiq Mohd Jailani, Shukur Ahmad, Yeoh Kian Hua, Mohd Sharifudin Said***BAXTER NEUROPATHY: A CASE OF STUBBORN HEEL PAIN***Abdul Hakim Mohd Hamsari, Mohd Yusoff Yahaya, Satriya Sabir Husin Athar***BRINGING HEMI-CASTAING BACK TO THE LIMELIGHT: A COST EFFECTIVE TECHNIQUE FOR AUGMENTATION IN CHRONIC LATERAL ANKLE INSTABILITY***Kishaani Pathamanathan, Leow Voon Chin, Benny Ewe, Devarani Pancharatnam, Tharumaraja Thiruselvam***CHRONIC POST TRAUMATIC POSTERIOR TIBIAL NERVE NEUROMA***Mohamad Aizat Mohamad Zahari, Mohamad NorAzrin Abas, Thiru Kumaran Mootha Kumaran, Norzatulsyima Nasirudin***COMPLETE TALUS DISLOCATION WITH COMMUNATED FRACTURE AROUND ANKLE JOINT - A CASE REPORT***Mohd Hafiz Syazwan, Muhammad Fadhil Mat Salleh***CONGENITAL HALLUX VARUS: A RARE FOREFOOT PROBLEM***Mohd Yazid Bajuri, Azwan Zhafri Bashir Ridha, Husna Mohd Apanji, Faris Aiman Sarifulnizam***"CONSTANT LENGTH PHENOMENA" OF THE FHL AND FDL MANAGED BY MIDFOOT Z-PLASTY: A SIMPLE & EFFECTIVE APPROACH***Mohd Yusoff Yahaya, Mohamed Faizal Sikandar, Mohd Fairudz Mohd Miswan, Haszianaliza Haslan***FUNCTIONAL SUBTOTAL HEEL RECONSTRUCTION WITH OSTEOFASCIOTANEOUS FLAP FOR OPEN CALCANEAL FRACTURE***Amber Haseeb, Nik Aizah Nabilla Faheem, Muhammad Ridwan Mirza Asfan, Alizan Abdul Khalil***GIANT NEURILEMOMA OF BIG TOE – A CASE REPORT***Ling Lee Siang, Seo Soon Teck, Sivapathasundaram C. Nadarajah***HAGLUND SYNDROME: A PECULIARITY CAUSE OF HEEL PAIN***Khaw Yam Chuan, Hwang Puoh Xieh, Nur Sabrina Abdul Ghani, Mohd Hadizie Din***IATROGENIC HALLUX VARUS – COMPLICATION POST HALLUX VALGUS CORRECTION - A RARE CASE REPORT***Yeo Siang Yew, Mohd Yazid Bajuri*

**INTRAARTICULAR FIBROUS BAND OF THE ANKLE, A FREQUENTLY MISSED LESION***Lim Ming Yong, Siti Hawa Tahir, Siva Thangaraju, Che Wan Mohd Shaiful Nizam Che Wan Nik***ISELIN'S DISEASE: A RARE DIAGNOSIS CONSIDERATION FOR A CHILD WITH BILATERAL LATERAL FOOT PAIN***Sui Khen Chaw, Abdul Kahir Misnan***IT ALWAYS SEEMS IMPOSSIBLE UNTIL ITS DONE – MODIFIED PIROGOFF AMPUTATION, A CASE REPORT***Mohamad Hazwan Zulkifli, Mohammed Harris Anwarali Khan, Jasvinder Singh Jagindar Singh***JOINT PRESERVING SURGERY USING SUPRAMALLEOLAR OSTEOTOMY IN ANKLE OSTEOARTHRITIS***Tan Yin Ying, Mohd Yazid Bajuri***LATERAL TALAR BODY FRACTURE FIXATION VIA A FIBULA DOOR OSTEOTOMY: OUR EXPERIENCE***Jagjoth Singh Darshan Singh, Edewet Daun***LOCALISED ANKLE PIGMENTED VILLODULAR SYNOVITIS, A CASE REPORT***Megat Mohammad Fakhri Kamaruzaman, Narinder Singh Joginder Singh***METHODS OF REDUCING MEDIAL SUBTALAR JOINT DISLOCATION***Kathleen Teo Khai Ling, Abdul Muhaimin Aziz, Kamarul Al-Haqq Abdul Ghani***MINIMALLY INVASIVE REDUCTION AND PERCUTANEUS SCREW FIXATION FOR INTRA-ARTICULAR CALCANEAL FRACTURE***Naga Bharathi Nesan, Yeoh Kian Hua, Shukur Ahmad, Mohd Sharifudin Said***NEGLECTED AVULSION FRACTURE OF CALCANEAL TUBEROSITY: IT'S NEVER TOO LATE TO FIX A FRACTURE!***Theenesh Theyvan Balakrishnan, Navin Sockalingam, Tharumaraja Thiruselvam, Leow Voon Chin***NEGLECTED CHRONIC TALONAVICULAR SUBLUXATION***Kenneth Yap Wei Sheng***NEGLECTED TALONAVICULAR JOINT DISLOCATION WITH CONCOMITANT TALUS FRACTURE***Muhammad Afji Idris, Narinder Singh Joginder Singh, Chelsia Ezrin Azlan Shah Gibbs, Mohamed Shafiq Mohamed Rusdi***OPEN DISLOCATION OF TALUS; A CASE REPORT***Aidy Azuan Afji Ismail, Mohd Arif Mohd Nor, Nurhanani Abu Bakar***PRESERVATION OF ANKLE JOINT IN TALUS FRACTURE DISLOCATION: A DISTRICT HOSPITAL EXPERIENCE***Kishanraj Hari Kharan, Azamuddin Alias, Ahmad Fazly Abd Rasid, Dinesh Earnest Kunasingh, Wan Yuhana Wan Md Yusof, Muhammad Raimi Ab Hurairah***REAPPRAISAL OF THE USE OF XRAYS IN ACUTE ANKLE INJURIES: A PROSPECTIVE EVALUATION OF OTTAWA ANKLE RULES IN A SINGLE MALAYSIAN TERTIARY CENTER***Mohd Ariff Sharifudin, Ramzi Ali Saleh Hussen, Amran Ahmed Shokri, Nur Azree Ferdaus Kamudin, Nordin Simbak***REVIEW AND OUTCOME OF SYME AMPUTATION PERFORMED ON TRAUMA, MALIGNANCY AND INFECTION CASES IN A NON-TERTIARY CENTRE***Muhammad Nazirul Mubin Khalid, Muhammad Ashraf Sulaiman, Muhammad Nuratiq Saharudin, Mustaqim Afji@apipi, Sazli Mohd Nor***REVISION OF A POLYETHYLENE FRACTURE IN TOTAL ANKLE REPLACEMENT: A CASE REPORT***Mohd Saiful Adzuwan Mat Rodi, Tanawat Vaseenon***SINUS TARSII APPROACH IN TREATING INTRA-ARTICULAR CALCANEAL FRACTURE***Navindravadhanam Sockalingam, Leow Voon Chin, Tharumaraja Thiruselvam***SUCCESSFUL TREATMENT OF OSTEOCHONDRAL LESION OF TALUS WITH BONE MARROW STIMULATION AND PLATELET-DERIVED EXTRACELLULAR VESICLES***Nik Aizah Nabilla Faheem, Amber Haseeb, Chong Pan Pan, Rukmanikathan Shanmugam, Tunku Kamarul Zaman Tunku Zainol Abidin***SURGICAL FIXATION OF AN EXTRAARTICULAR CALCANEAL AVULSION FRACTURE IN AN ELDERLY: A CASE REPORT***Loh Ling Hui*

**SUSPENSION TENODESIS OF TIBIALIS ANTERIOR FOR CORRECTING FOOT DROP IN NEUROMUSCULAR DISORDERS***Amber Haseeb, Nik Aizah Nabilla Faheem, Rukmanikanthan Shanmugam***TEMPORARY BRIDGE PLATING OF MEDIAL COLUMN IN MIDFOOT INJURY***Norhana Mohamed Ali, Denny Clare Embun, Norzatulsyima Nasirudin***THE ANALYSIS OF PLANTAR PRESSURE AMONG DIABETIC PATIENTS: OBSERVATIONAL STUDY***Shankari Sinnasamy, Aminuddin Che Ahmad***THE ANKLE WITHOUT TALUS : A RARE CASE OF AN OPEN TALAR EXTRUSION WITH DISTAL TIBIA FIBULA FRACTURE***Muhammad Dzulhusni Mohd Dzulkifri, Norisyam Yusoff, Teh Ban Heng, Mus'ab Norhamidi***THE STUBBORN HEEL PAIN: A CASE REPORT***Mohd Yusoff Yahaya, Mohamed Faizal Sikkandar, Mohd Fairudz Mohd Miswan, Haszianaliza Haslan***TIBIOTALAR AND TRANSYNDERMOTIC SCREW FIXATION ARTHRODESIS***Adzhar Abdul Latib, Mohamad Fauzlie Yusof, Zoran Arif Mat Hussin, Mohd Hazim Mohd Azhar***TIBIOTALOCALCANEAL FUSION USING HINDFOOT ARTHRODESIS NAIL IN DIABETIC CHARCOT NEUROARTHROPATHY: A CASE REPORT***Wong Yih Jiun, Mohd Yazid Bajuri***TRAUMATIC PANNICULITIS OSSIFICANS FOLLOWING CALCANEAL FRACTURE: A CASE REPORT***Muhammad Abdul Rahman Abu Bucker, Shukur Ahmad, Yeoh Kian Hua, Mohd Sharifudin Said***V-Y LENGTHENING FOR TREATMENT OF CHRONIC ACHILLES TENDON RUPTURE***Mohd Idham Hasan, Ahmad Afiq Mohd Rozain, Hasry Faris Aris, Zulasri Azan Zain, Ruqayyah Syakirah Mazwar***WALANT: AN ALTERNATIVE FOR POSTERIOR TIBIALIS TENDON REPAIR DURING PANDEMIC***Sarah Sheena Toyat, Yazid Bajuri***Hand****10 YEAR OUTCOME OF PAEDIATRIC COMPOSITE GRAFTING IN FINGERTIP INJURIES IN HOSPITAL SELAYANG***Wan Nurulfaiza Akmal Wan Salam, Rashdeen Fazwi Muhammad Nawawi, Syahril Rizal Arsad***A CASE REPORT: FINGER FLEXION CONTRACTURE DUE TO TOPHACEOUS GOUT OVER THE WRIST***Mohamad Hafiz Mohamad Zaini, Theenesh Theyvan, Kuharajan Ramalingam, Mawardi Mustafa, Teh Wei Bin, Mohd Fadhil Sulong, Khalid Isa***ACUTE REPAIR OF TRIANGULAR FIBROCARILAGE COMPLEX IN TRAUMATIC DETACHMENT***Suraya Zulkhairi, Muhammad Shukri Muhammad Safian***ACUTE SCAPHOID FRACTURE WITH EXTENSOR POLLICIS LONGUS TENDON RUPTURE: A CASE REPORT***Kishaani Pathamanathan, Eo Chun Keat***ADULT PREAXIAL POLYDACTYLY: A CASE SERIES***Tan Lip Siang, Sachin Shivdas, Jayaletchumi Gunasagaran***A HINGED EXTERNAL FIXATOR FOR NEGLECTED CHRONIC ELBOW DISLOCATION: A RARE CASE REPORT***Magdalen Anthony, Phughalenthira Ganesan Panchanathan, Ruben Sivanoli***AN UNUSUAL ORIGIN OF GANGLION CYST: A CASE REPORT***Wong Yih Jiun, Khoo Saw Sian***A RARE AND LIFE THREATENING SCAPULOTHORACIC DISSOCIATION WITH ASSOCIATED CLAVICLE FRACTURE AND COMPLETE BRACHIAL PLEXUS INJURY***Mohd Luqman Haji Anuar, Nurhanani Abu Bakar*

**A RARE CASE FIXATION OF TRAUMATIC PISIFORM BONE DISLOCATION USING WALANT TECHNIQUE: A CASE REPORT***Mohamed Irsyad Mohamed Haniffa, Abdul Qayyum Mohd Raziff, Amir Adham Ahmad***A RARE CASE OF DIABETIC CHARCOT NEUROARTHROPATHY OF THE HAND***Mohd Luqman Haji Anuar***A RARE CASE OF EXTRAPULMONARY TUBERCULOSIS OF THE THUMB WHICH MIMICS OSTEOMYELITIS CHANGES:****A CASE REPORT***Mohd Shafiee Johan Chin, Liau Chai Jiun, Jeremy Prakash Silvanathar, Rashdeen Fazwi Muhammad Nawawi***A RARE CASE OF MULTIFOCAL GIANT CELL TUMOR OF THE TENDON SHEATH***Shival Tharmaseelan, Kuhaendra Jeyasingam, Jeremy Prakash Silvanathan***A RARE CASE OF TRAUMATIC MULTIPLE CARPO-METACARPAL DISLOCATION***Harrison Wh Danapala, Collin Looi Seng Kim, Ng Tiong Soon***A RARE CAUSE FOR CARPAL TUNNEL SYNDROME***Khadijah Nordin, Muhammad Nazri Amahd Unonis, Ahmad Fadhil Aminolhuda, Mohd Zaim Mohd Rashid, Kamalruzaman Mohd Ali***A RARE ISOLATED FRACTURE OF BODY OF THE HAMATE***Chin Siang Leon, Nik Ahmad Fauzan, Muhammad Nizamuddin, Mohd Hafizi***A RARE PRESENTATION OF COMPLETE ISOLATED SCAPHOID DISLOCATION***Mohd Fadhil Sulong, Nik Muhammad Shahid Nik Jaffar, Muhammad Hilmi Nasir, Ahmad Afiq Fadhli Ramli***A RARE PRESENTATION OF FLEXOR DIGITORUM PROFUNDUS TYPE V AVULSION INJURY WITH ASSOCIATED****INTRA-ARTICULAR FRACTURE: A CASE REPORT***Loo Wen Chern, Liau Chai Jiun, Liew Siew Khei, Jeremy Prakash Silvanathan, Rashdeen Fazwi Muhammad Nawawi***A THUMBS UP: A SUCCESSFUL PRIMARY FULL THICKNESS SKIN GRAFT OVER THE THUMB FOLLOWING TRAUMATIC HAND INJURY DONE IN A NON-TERTIARY CENTRE AMIDST COVID-19 PANDEMIC***Muhammad Ashraf Sulaiman, Muhammad Nazirul Khalid, Mustaqim Afifi@ Apipi, Muhamad Nurasnol Khamis, Sazli Mohd Nor***CASE REPORT: EVERYTHING IS SIMPLER THAN YOU THINK AND AT THE SAME TIME MORE COMPLEX THAN YOU IMAGINE – CORONAL SHEAR CAPITELLUM FRACTURE***Muhamed Ismeth Samsudeen, Sanjeevan Radhakrishnan, Carolyn Choong Yoke Lin, Zulkiflee Osman***CENTIPEDE BITE WITH COMPARTMENT SYNDROME: TO RELEASE OR NOT TO RELEASE?***Dominic C Bopulas, Mohd Shawal Sjahrial, Fadzly Ramidi***CLINICAL AND FUNCTIONAL OUTCOMES FOLLOWING TOTAL ARTHROPLASTY OF THE THUMB CARPOMETACARPAL JOINT USING THE TOUCH IMPLANT***Oh Yong Yun Yu, Lim Beng Hai, Maria Downey***COMPARTMENT SYNDROME COMPLICATING TRANSRADIAL CARDIAC CATHETERISATION: A CASE SERIES***Nur Ayuni Khirul Ashar, Imma Isniza Ismail, Naadira Faa'iza Mazlan, Nur Syahirah Azmi, Rahul Lingam***COMPOSITE GRAFTING FOR TRAUMATIC FINGERTIP AMPUTATIONS IN AN ADULT; A CASE REPORT***Fauziana Abd Jabar, Shalimar Abdullah, Jamari Sapuan***CONCOMITANT GIANT CELL TUMOR OF TENDON SHEATH IN A DORSAL WRIST GANGLION CYST - A CASE REPORT***Yeo Siang Yew, Jayaletchumi Gunasagaran***CUBITAL TUNNEL SYNDROME SECONDARY TO ANCONEUS EPITROCHLEARIS LIGAMENT***Lim Chia Hua, Amaleswaran Anbarasan, Jeremy Prakash Silvanathan, Rashdeen Fazwi Muhammad Nawawi***DEEP FUNGAL OSTEOMYELITIS RESEMBLES MALIGNANCY***Selvakumar Murthy, Bharatikannan Sivalingam, Tuan Muhd Ridzuan, Denny Clare*

**DELAYED THUMB DYSFUNCTION AFTER DISTAL RADIAL VOLAR PLATING IN ABSENCE OF TENDON RUPTURE***Carolyn Choong, Zulkiflee Osman***DIAMOND KIRSCHNER-WIRE FIXATION ARE A SURGEONS BEST FRIEND: APPROACH TO SCAPHOLUNATE DISSOCIATION***Darshan Krishna Kumar, Azlan Sofian, Mohd Azrin Mummud Asihin, Sree Raja Lakshmy Chandra Sekaran, Philemon Paul***DILEMMA IN POST TRAUMATIC KIENBOCK'S DISEASE***Gan Yun Han, Jasvinder Singh Jagindar Singh, Mohammed Harris Anwarali Khan, Mohamad Sallehuddin Hassan***DISTAL HUMERUS RECONSTRUCTION USING IPSILATERAL RADIAL HEAD AUTOGRAFT FOR TREATMENT OF NEGLECTED COMPLEX ANTERIOR ELBOW DISLOCATION: A CASE REPORT***Umar Hakim Mohd Ghani, Naim Mohd Nasir, Ruban Sivanoli***DOUBLE CRUSH SYNDROME: SYRINGOMYELIA AND CUBITAL TUNNEL SYNDROME – WHICH IS THE TRUE CULPRIT?***Mohd Daniel Djamalludin, Tunku Sara Tunku Ahmad Yahaya***DUPUYTREN'S CONTRACTURE IN THE MALAY PATIENT: CASE REPORT***Vijayanagan Veramuthu, Mohd Hanifah Jusoh, Mohammad Paiman, Abdul Nawfar Sadagatullah***ECTRODACTYLY WITH COMPLEX SYNDACTYLY OF THUMB AND INDEX FINGER: A GRIP OF HOPE***Sopian Shuib, Mohamad Sallehuddin Hassan, Anizar Faizi Anoar, Ahmad Fauzey Kassim***ENCHONDROMA: AN INCIDENTAL FINDINGS ON IMAGE INTENSIFIER MACHINE***Tan Yin Ying, Teh Kai Hean, Shams Amir Shamsul Bahar, Khoo Saw Sian, Jayaletchumi Gunasagaran, Sachin Shivdas, Tunku Sara Tunku Ahmad Yahaya***EXPECT THE UNEXPECTED-RADIAL HEAD REPLACEMENT WITH MINI PLATE AUGMENTATION***Mohd Hafizuddin Ahmad Sabri, Mohammed Harris Anwarali Khan, Jasvinder Singh Jagindar Singh***EXTENSOR INDICIS PROPRIUS OPPONENSPLASTY - CHOICE OF TRANSFER AND TIPS FOR A SUCCESSFUL SURGERY***Khairul Azmi Ghazali, Shalimar Abdullah***EYE CAN'T SEE WHAT THE MIND DOES NOT KNOW: EXTENSOR CARPI RADIALIS LONGUS AVULSION FRACTURE FIXATION UNDER WALANT SURGERY***Abdul Hamid Mohamed Yassin, Gunaseelan Ponnusamy, Hishamuddin Salam***GIANT CELL TUMOUR OF EXTENSOR TENDON SHEATH IN THE HAND– A CASE REPORT AND STRATEGIES TO PREVENT RECURRENCE***Ling Lee Siang, Seo Soon Teck, Sivapathasundaram C. Nadarajah***GOODBYE TO A CHILDHOOD FRIEND – EPIDERMAL CYST***Teng Hong Ling***HAMATOMETACARPAL FRACTURE DISLOCATION AN EASILY MISSED INJURY***Muhammad Dzulhusni Mohd Dzulkifri, Norisyam Yusoff, Teh Ban Heng, Mus'ab Norhamidi***IMMEDIATE EMERGENCY FREE ANTEROLATERAL THIGH FLAP WITH TENSOR FASCIA LATA AS TENDON GRAFTS IN COMPLEX DORSAL HAND INJURY: A COMPLETELY VASCULARIZED SINGLE-STAGE RECONSTRUCTION***Fauziana Abd Jabar, Shalimar Abdullah***IMPLANON MIGRATION!! – AN ORTHOPEDIC SAVIOUR***Thaneshwara Rao Appannan, Shukur Ahmad, Mohd Sharifudin Said***IMPORTANCE OF FRACTURE STABILITY IN ACHIEVING WOUND CLOSURE & UNION IN AN OPEN FRACTURE OF THE PHALANX***Abilash Kumar, Manohar Arumugam, Firdati Mohamed Saaid, Collin Looi Seng Kim, Liew Siew Khei***IRREDUCIBLE THUMB INTERPHALANGEAL JOINT DISLOCATION: A SERIES OF FOUR CASES***Muhammad Yasir Ahmad Muslim, Amaleswaran Anbarasan*

**ISOLATED CAPITELLUM FRACTURE: A RARE FRACTURE ENTITY***Ros Aniza Ahmad, Rashdeen Fazwi Muhammad Nawawi, Syahril Rizal Arsad***ISOLATED COMMINUTED TRAPEZIUM FRACTURE***Pathmarooban Damoderam, Surendra Sabramaniam, Faisal Md Noor***ISOLATED RIGHT HAND COMPARTMENT SYNDROME, AN UNUSUAL PRESENTATION OF EVAN SYNDROME***Ahmad Nadzir Tarmizi, Muhammad Farhan Mohd Yusoff, Nik Muhammad Shahid Nik Jaafar, Muhammad Fadhil Mat Salleh, Kartinawati Mohammad***ISOLATED TRAUMATIC DISLOCATION OF THE PISIFORM***Priyadarssini Karunakaran, Harmony Tan Chern Yang, Hishamuddin Salam***KAPLAN'S DISLOCATION IN PAEDIATRICS: A CASE REPORT***Vinodharan Nagaretnam, Kishaani Pathamanathan, Mohamad Sallehuddin Hassan***LEFT WRIST ABSCESS; A RARE PRESENTATION OF TUBERCULOUS OSTEOMYELITIS OF LEFT RADIAL BONE IN A 6 MONTH OLD CHILD. A CASE REPORT***Normughni Mohd Fikirudin, Nurhazwani Halim, Goh Hong Huat***LEPROSY HAND COMPLICATED WITH OSTEOMYELITIS, A FORGOTTEN DISEASE: A CASE REPORT***Mohamad Norazrin Mohd Abas, Nur Shakinah Ajak, Lee Sing Huat, Thiru Kumaran Mootha Kumaran***LIGAMENOUS RECONSTRUCTION OF CHRONIC TRAUMATIC THUMB CARPOMETACARPAL DISLOCATION***Wong Jia Yen, Aida Nurani Sobri, Ng Lim Hong, Teo Yu Meng***LISFRANC INJURY OF HAND?: A CASE REPORT OF COMPLEX VOLAR CARPOMETACARPAL DISLOCATION OF HAND***Mohd Afiq Muhamed Fuad, Mohd Reza Mohd Aridz***LISFRANC INJURY OF THE HAND? A RARE CASE OF ISOLATED DORSAL DISLOCATION OF THE LEFT SECOND TO FIFTH CMC JOINTS***Muhammad Dzulhusni Mohd Dzulkifri, Mus'ab Norhamidi, Norisyam Yusoff, Puravi Ganesh Shanmugam, Teh Ban Heng***MALAYSIA EPIDEMIOLOGICAL STUDY OF TRAUMATIC BRACHIAL PLEXUS INJURY***Wan Muhammad 'Ali Wan Jalaludin, Rashdeen Fazwi Muhammad Nawawi, Syahril Rizal Arsad***MEETING PATIENT'S EXPECTATIONS - A CASE REPORT***Gan Yun Han***MELORHEOSTOSIS IN MELAKA HOSPITAL: A CASE REPORT OF RARE DISEASE***Adzhar Abdul Latib, Norlizam Mohd Nor, Zoran Arif Mat Hussin, Mohd Hazim Mohd Azhar***MISTAKING A TUMOR FOR AN INFECTION: ACROMETASTASIS OF THE FINGER***Asrul Syamin Hisyam Yong, Parminder Singh Gill, Shalimar Abdullah, Jamari Sapuan***MULTIPLE CONTIGUOUS SCHWANNOMAS IN A SOLITARY DIGITAL NERVE: AN UNUSUAL CASE OF MULTIPLE SWELLINGS ON A SINGLE FINGER***Ooi Hooi Shieng, Syahril Rizal Arsad, Rashdeen Fazwi Muhammad Nawawi***NEGLECTED RIGHT WRIST TUBERCULOUS ARTHRITIS WITH SEVERE DEFORMITY IN PULMONARY TUBERCULOSIS PATIENT***Tan Joo Boon, Normawathy Amir Osman, Amaleswaran Anbarasan, Zulkiflee Osman***NON INFECTIVE RICE BODIES FORMATION WITH WRIST TENOSYNOVITIS***Roysten Silvanathan, Muhammad Shukri Muhammad Safian, Wong Bah Huang***OBLIQUE TRIANGULAR FLAP FOR OBLIQUE FINGERTIP AMPUTATION***Mohd Hanifah Jusoh, Abdul Nawfar Sadagatullah, Mohammad Paiman***PAEDIATRIC FINGERTIP AMPUTATION-A GOOD OUTCOME FOLLOWING SIMPLE LOOSE SUTURING OF AMPUTATED PART***Mohd Hanifah Jusoh, Abdul Nawfar Sadagatullah, Mohammad Paiman*

**PEDUNCULATED HEMORRHAGIC CYST OF A NEWBORN***George Ezekiel, Rohaman Tasarib***PLATING OF CLAVICLE USING WALANT: THIS IS HOW I DO IT***Tan Yong Lin, Kamarul Ariffin Khalid, Raffael Ismail***PRIMARY SOLITARY METACARPAL OSTEOMYELITIS CAUSED BY KLEBSIELLA PNEUMONIAE: A CASE REPORT***Koogulakanth Chandra Sekaran, Nantha Kumar V P Baskaran, Arvin Valuyeetham, Abdul Rauf Kamarul Zaman, Akmal Hadi Minghat***PSEUDOTUMOR MIMICKING A SOFT TISSUE TUMOR IN THE HAND***Abilash Kumar, Manohar Arumugam, Firdati Mohamed Saaid, Collin Looi Seng Kim, Liew Siew Khei***PULVERTAFT TECHNIQUE (PT)-A CASE REPORT OF CHRONIC EXTENSOR TENDON HAND INJURY***Adzhar Abdul Latib, Norlizam Mohd Nor, Zoran Arif Mat Hussin, Mohd Hazim Mohd Azhar***RARE CASE OF NEGLECTED LEFT ELBOW DISLOCATION COMPLICATED WITH COMPARTMENT SYNDROME SECONDARY TO TRADITIONAL MASSAGE AND COAGULOPATHY: A CASE REPORT***Kee Hoe Teong, S.L Vijaya Kumar Suppan***RECCURENT NORA'S LESION OF MIDDLE PHALANX OF RIGHT LITTLE FINGER FOLLOWING LOCAL EXCISION: A RARE CASE***Elsonmond Vick Duin, Mohammad Zaki Haji Mohd Amin, Rashdeen Fazwi Muhammad Nawawi, Jeyasilan Karpudewan***RECONSTRUCTION OF THUMB AMPUTATION WITH A DEGLOVING WOUND AT CARPOMETACARPAL JOINT LEVEL WITH A GROIN FLAP***Lim Chia Hua, Amaleswaran Anbarasan, Vijayan Gopal, Mooi Sung Siang, Jeremy Prakash Silvanathan, Rashdeen Fazwi Muhammad Nawawi***RECURRENT DIGITAL MUCOUS CYST IN AN ADOLESCENT TREATED WITH EXCISION AND BILOBED FLAP***Beatrix Hii Yung Siang, Jayaletchumy Gunasagaran***STAGED SURGERY FOR FUNCTIONAL SPASTIC HAND: A CASE REPORT***Leong Jiahour, Lim Chee Yang, Mohd Radzi Khairudin, Mohammad Sallehuddin Hassan, Anizar Faizi Anoar, Sopian Shuib, Suresh Chopra***SURPRISES DURING FINGER SURGERIES***Weng Vei Chiam Tah Kong, Ong Ren Ling, Lim Soo May***SUZUKI FRAME WITH EARLY MOBILIZATION FOR TREATMENT OF COMPLEX INTRAARTICULAR FRACTURE OF PROXIMAL INTERPHALANGEAL JOINT - A CASE REPORT***Abdul Muhaimin Aziz, Tiew Siew Kern, Kamil Mohd Kasim***TALE OF A LUMP ON THE PALM***Chong Jung Syn, Shukriah Aqilah Zakaria, Raeross Anak Jabul, Mohd Aizat Azfar Soldin***TB TENOSYNOVITIS IN IMMUNOCOMPROMISED PATIENT - A CASE REPORT***Muhammad Luqman Abu Bakar, Norsaidatul Nadriah Ahmad Suhaimi, Satriya Sabir Husin Athar***THE EVIL IN THE PANDORA BOX – NECROTISING FASCIITIS OF FINGER SECONDARY TO INFECTED EPIDERMAL CYST***Teng Hong Ling***THE EYES DON'T SEE WHAT THE MIND DOESN'T KNOW: MISSING A CARPOMETACARPAL JOINT DISLOCATION***Nurul Qisti Ab. Razak, Chin Siang Leon, Zareze Abd Rahman, Zaharul Azri Mustapha @ Zakaria***THUMB TROUBLE: CASE OF GLOMUS TUMOUR MISTAKENLY TREATED AS THE MORE COMMON CARPAL TUNNEL SYNDROME AND DE QUERVAIN'S TENOSYNOVITIS***Ruqnuddin Al Hamdi Roosli, Mohd Reza Mohd Aridz***"TOO MANY FINGERS" TRAUMA***Sopian Shuib, Mohamad Sallehuddin Hassan, Anizar Faizi Anoar, Ahmad Fauzey Kassim*

**TRANSSCAPHOID PERILUNATE DISLOCATION***Qutaibah N.A. Erman, Mohd Hanifah Jusoh, Abdul Nawfar Sadagatullah, Mohammad Paiman***UPPER LIMB SOFT TISSUE SWELLING: DEMOGRAPHY AND MANAGEMENT***Ahmed Suparno Bahar Moni, Tunku Sara Tunku Ahmad Yahaya, Wing-Yuk Josephine IP***VENOUS OCCLUSION POST PACEMAKER IMPLANTATION***Maatharasi Balan, Muhindra Rao Gsangaya, Ruben Jaya Kumar***VOLAR WRIST LIPOMA IN GUYON'S CANAL CAUSING ULNAR NERVE NEUROPATHY***Yolanda Boniface Deyoi, Mohd Hanifah Jusoh, Mohammad Paiman, Abdul Nawfar Sadagatullah***WRIST ARTHRODESIS: A SALVAGE FOR FAILED WRIST RECONSTRUCTION***Kuhaendra Jeyasingam, Shival Tharmaseelan, Jeremy Prakash Silvanathan, Amaleswaran Anbarasan***LLRS****A CASE REPORT ON ADJUNCT SINGLE CIRCULAR EXTERNAL FIXATOR' FOOT FRAME IN TREATING COMPLEX FRACTURE-DISLOCATION OF THE TARSAL NAVICULAR BONE***Mohamad Saifudin Othman, Ong Kean Chao, Teo Soo Lin, Wan Kwong Lee, Syed Azmi Ahmad Shah, Azlan Mohd Sofian, Basir Towil***A CASE REPORT ON MANGLED FOOT WITH OPEN LISFRANC INJURY TREATED WITH ILIZAROV EXTERNAL FIXATOR***Ong Kean Chao, Mohamad Saifudin Othman, Fatin Farhana Manas, Wan Kwong Lee, Syed Azmi Ahmad Shah, Azlan Mohd Sofian, Basir Towil***BIFOCAL BONE TRANSPORT :DISTRICT HOSPITAL EXPERIENCE IN MANAGING LONG SEGMENT TIBIA BONE DEFECT***Mohd Azmi Sulaiman, Hudzairy Ahmad, Arneemarlina Wahab***FEMORAL-TIBIAL FUSION WITH LENGTHENING: A SALVAGE METHOD FOR FAILED KNEE ARTHRODESIS***Kamarul Arifin Abdul Razak, Kamarul Al-Haqq Abdul Ghani***FUSE OR NOT TO FUSE? A CASE REPORT ON DISTRACTION ARTHROPLASTY OF POST TRAUMATIC ANKLE OSTEOARTHRITIS WITH ILIZAROV EXTERNAL FIXATOR***Mohamad Saifudin Othman, Ong Kean Chao, Fatin Farhana Manas, Wan Kwong Lee, Syed Azmi Ahmad Shah, Azlan Mohd Sofian, Basir Towil***ILIZAROV EXTERNAL FIXATION (IEF) IN DISTAL FEMUR FRACTURES: A LIMB SAVIOUR - OUR EXPERIENCE IN SABAH***Hemakugan Patma Jothy, Wengvei Chiam Tah Kong, Lim Soo May, Gerry Maxmillan Hou Jen Pang***RE-INTERNAL VS EXTERNAL? A CASE REPORT ON SEPTIC NON UNION OF HUMERUS WITH TWICE IMPLANT FAILURE TREATED WITH ILIZAROV EXTERNAL FIXATOR***Mohamad Saifudin Othman, Ong Kean Chao, Teo Soo Lin, Basir Towil***SHORT SEGMENT FRACTURE DISTRACTION TO TREAT MALUNION OF TIBIA VIA ILIZAROV METHOD***Kishanraj Hari Kharan, Dinesh Earnest Kunasingh, Wan Yuhana Wan Md Yusof, Gopindran Muthusamy, Wan Muhammad Wan Afif***THE COACH ON THE RAILWAY –A CASE OF HEMICORTICAL TRANSPORT FOR ANTERIOR DIAPHYSEAL TIBIA DEFECT***Ahmad Arieff Atan, Zamri Ab Rahman, Norhaslinda Bahaudin, Abdul Rauf Ahmad*



## Oncology

**A CASE OF ILIAC BONE METASTASIS AS A CAUSE OF SCIATICA**

*Mohd Faieq Mohd Rosli, Muhamad Faiz Zulkapli, Ruben Jaya Kumar, Muhamad Nazrin Mustafa*

**A CASE REPORT OF MULTIPLE BENIGN FIBROUS HISTIOCYTOMA**

*Rowena Nagentharan, Indrarajah Asokumaran*

**ADULT SOLITARY MYOFIBROMA IN THE WRIST WITH MEDIAN NERVE COMPRESSION**

*Fauziana Abd Jabar, Ahmad Nawawi Mohd Radzuan*

**A FOUR-YEAR OLD GIRL WITH A UNILATERAL TIBIA BONE OSTEOFIBROUS DYSPLASIA-LIKE ADAMANTINOMA AND TREATMENT - A CASE REPORT**

*Yeo Siang Yew, Nor Faissal Yasin, Azura Mansor, Vivek Ajit Singh*

**ANEURYSMAL BONE CYST OF TALUS: THE RARE ENTITY**

*Syed Mohd Esmat Hussaini, Tiw Zhung Shen, Wan Zainuddin Wan Ab Rahman, Mohamad Razip Sirat*

**ANGIOMATOID FIBROUS HISTIOCYTOMA: FIRST CASE REPORTED IN KUANTAN**

*Muhammad Jaszizal Jasni, Muhammad Wafi Ahmad*

**ANTERIOR KNEE PAIN POST-CEMENTING OF DISTAL FEMUR GIANT CELL TUMOUR: A CASE REPORT**

*Low Chin Aun, Vivek Ajit Singh, Norfaissal Yassin*

**AN UNUSUAL CASE OF UNICAMERAL BONE CYST IN ADULT**

*Izzul Faiz Razali, Mohd Karim Md Isa*

**A RARE CASE OF SACROCOCCYGEAL SQUAMOUS CELL CARCINOMA**

*Elsonmond Vick Duin, Ravin Prabakaran, Mohammad Zaki Haji Mohd Amin, Chan Wai Hoong*

**A RARE CASE OF SYNCHRONOUS PRIMARY PAROSTEAL OSTEOSARCOMA AND PRIMARY MEDIASTINAL SEMINOMA**

*Lim Chia Hua, Mohamed Hafizudin Abdullah Sani, Nor Hazla Mohamed Hafiah*

**A RARE PRESENTATION OF THE ONE, VERY COMMON ORGANISM; A CASE REPORT OF SOFT TISSUE TUBERCULOSIS WRIST AND HAND**

*Irwan Ab Aziz*

**ATYPICAL PEDUNCULATED SCHWANNOMA OF THE FOOT**

*Jian How Wong, Lik Han Ong, Vwrene Chia*

**AWAKE LARGE SHOULDER LIPOMA EXCISION WITH TUMESCENT LOCAL ANAESTHESIA (TLA)**

*Naga Bharathi Nesan, Shukur Ahmad, Yeoh Kian Hua, Mohd Sharifudin Said*

**BONE TRANSPORT AS A RECONSTRUCTIVE OPTION FOR PATIENT WITH COMPLICATED GIANT CELL TUMOR OF DISTAL TIBIA: A CASE REPORT**

*Muhammad Amerul Nordin, Prashant Narhari, Firdaus Hafni Ahmad, Azuhairy Azid*

**BRIDGING THE GAP - BILATERAL SUBTOTAL CLAVICULECTOMY WITH STERNECTOMY 'THE RECON NECKLACE': A CASE REPORT**

*Puravi Ganesh Shanmugam, Dinesh Rajandran, Hesootharan Govindarajan, Muhammad Dzulhusni Mohd Dzulkifri*

**CASE REPORT: MEDICAL THERAPY FOR NECK DESMOID-TYPE FIBROMATOSIS**

*Lim Chiao Yee, Suryasmi Duski, Maizatul Jamny Mahmud, Muthukkumaran Thiagarajan, Noraini Mohd Dusa, Chye Ping Ching*

**CONDENSING OSTEITIS OF CLAVICLE: A RARE CASE REPORT**

*Bharatikannan Sivalingam, Dhineshkumar Chandarasegran, Selvakumar Murthy, Norzatulsyima Nasirudin*

**CONDROSARCOMA OF THE SPINE : A CASE REPORT IN SARAWAK GENERAL HOSPITAL**

*Hernany Shamsuddin, Chan Wai Hoong, Mohamad Zaki Mohd Amin*

**COST AND QUALITY OF LIMB SALVAGE SURGERY, 4 YEARS FOLLOW UP OF MODIFIED PROXIMAL HUMERUS IMPLANT**

*Mohamad Faris Md Ariff, Hariharan Kumarasamy, Mazlina Awang, Muhammad Anwar Hau Abdullah*

**DIAGNOSTIC DILEMMA: A RARE CASE SPIRADENOMA OF FOREARM***Mohd Naiman Fahimy Hj Mustapa, Lim Wei Khang, Nur Dini Mohd Yusof***DIAGNOSTIC DILEMMA OF A METASTATIC HYDRADENOCARCINOMA OF AXILLA: A CASE REPORT OF A RARE TUMOR***Ong Ting Jie, Prashant Narhari, Azuhairy Azid***DISPLACED PATHOLOGICAL NECK OF FEMUR FRACTURE IN YOUNG ADULTS – PROMISING OUTCOME WITH NON-VASCULARIZED FIBULA STRUT GRAFT***Nur Aidurra Zainudin, Mohamad Shawal Sjahrial, Fadzly Ramidi***EPITHELIOID SARCOMA OF WRIST – A DIAGNOSTIC CHALLENGE***Ling Lee Siang, Seo Soon Teck, Sivapathasundaram C. Nadarajah***EXTRASKELETAL SOFT TISSUE CHONDROMA OF RIGHT THUMB: A RARE CASE***Ravin Prabakaran, Elsonmond Vick Duin, Chan Wai Hoong, Vijayan Gopal, Mohammad Zulkarnaen Ahmad Narihan***EXTREMITY SOFT TISSUE SARCOMAS IN A SERIES OF 18 PATIENTS TREATED AT A SINGLE INSTITUTION: SHORT-TERM FOLLOW-UP***Lim Chiao Yee, Suryasmi Duski, Maizatul Jamny Mahmood, Noraini Mohd Dusa, Chye Ping Ching***GIANT CELL TUMOUR OF PATELLA; THE DARK HORSE OF ANTERIOR KNEE PAIN***Soh Chiang Joo***GIANT FINGER***Mohamad Aizat Mohamad Zahari, Tuan Muhamad Ridzuan Tuan Hussin, Denny Clare, Norzatulsyima Nasirudin***GOOD OUTCOME WITH LIMB SALVAGE POST WHOOPS PROCEDURE OF DISTAL FEMUR OSTEOSARCOMA***Muhammad Redza Ihsan Rosli, Prashant Narhari, Azuhairy Azid, Zulkiflee Osman***GREAT MIMICRY. HAND RHABDOMYOSARCOMA IN CHILD SUPERIMPOSED WITH HAND ABSCESS***Abdul Rahman Nik Mazian, Mohammad Anwar Hau Abdullah***INTRA-ARTICULAR SYNOVIAL CHONDROMATOSIS: A RARE CAUSE OF THE KNEE PAIN***Umar Hakim Mohd Ghani, Jeffrey Chong Wei Jie, Kamarulzaman Haji M.S Kadir***JOINT SALVAGE USING SANDWICH TECHNIQUE FOR DISTAL FEMUR GIANT CELL TUMOR***Tan Yin Ying, Nor Faissal Yasin, Vivek Ajit Singh***KNEE CAPSULE RECONSTRUCTION USING ILIOTIBIAL BAND IN A CASE OF UNDIFFERENTIATED PLEOMORPHIC SARCOMA***Wong Yih Jiun, Vivek Ajit Singh, Nor Faissal Yasin***LYMPHANGIOMAS OF FOOT IN TODDLER: A CASE REPORT***Hesootharan Govindarajan, Goh Teik Chiang, Aaron Gerarde Paul, Dinesh Rajandran, Lai Min Chung, Jeeva Shanumugam***MELORHEOSTOSIS: A RARE BONE DISORDER***Manharpreet Singh Sandhu***METASTATIC ERECTOR SPINAE TUMOR UNDERLYING PRIMARY LUNG ADENOCARCINOMA WITH PARANEOPlastic SECRETING BETA-HUMAN CHORIONIC GONADOTROPIN HORMON: A RARE CASE REPORT***Elsonmond Vick Duin, Ravin Prabakaran, Chan Wai Hoong, Mohammad Zulkarnaen Ahmad Narihan***METASTATIC VASCULAR PLEOMORPHIC LEIOMYOSARCOMA IN A PREVIOUSLY TREATED CERVICAL CARCINOMA PATIENT: A DIAGNOSTIC DILEMMA***Umar Hakim Mohd Ghani, Mohamed Hafizudin Abdullah Sani, Nor Hazla Mohamed Hafilah, Nor Hafizah Mohd Zain, Nurwahyuna Rosli, Reena Rahayu Md Zini***MISDIAGNOSIS IN SIMPLE AVULSION FRACTURE OF TIBIAL TUBEROSITY - A RARE CASE OF POLYOSTOTIC PAGET DISEASE***Muhammad Amerul Nordin, Prashant Narhari, Azuhairy Azid, Lily Lim Hooi Min***MODIFIED EXTERNAL HEMIPELVECTOMY: A SALVAGE SURGERY FOR SQUAMOUS CELL CARCINOMA***Kuhaendra Jeyasingam, Shival Tharmaseelan, Lim Chiao Yee, Suryasmi Duski, Chye Ping Ching*

**NEGLECTED GIANT SQUAMOUS CELL CARCINOMA OF PALM – AN EXTREMELY INFREQUENT TUMOUR***Ling Lee Siang, Seo Soon Teck, Sivapathasundaram C. Nadarajah***NOVEL TECHNIQUE OF PREPARING ARTICULATED HIP SPACERS - TECHNICAL NOTE***Mohammed Harris Anwarali Khan, Kunalan Gantheel, Suryasmi Duski, Lim Chiao Yee, Sasidaran Ramalingam***OSTEOMYELITIS OF HUMERUS MIMICS MALIGNANCY: A CASE REPORT***Lim Kgai Ter, Dinesh Earnest Kunasingh, Wan Yuhana Wan Md Yusof***OSTEOMYELITIS OF TIBIA MIMICKING TUMOUR***Adzhar Abdul Latib, Akmal Hadi Minghat, Zoran Arif Mat Hussin, Mohd Hazim Mohd Azhar***POLYOSTOTIC FIBROUS DYSPLASIA: BIZARRE AND A RARE CASE REPORT***Dinesh Rajandran, Goh Teik Chiang, Rubinderan Muthusamy, Hesootharan Govindarajan, Lai Min Chung, Jeeva Shanumugam***PROXIMAL HUMERUS OSTEOSARCOMA ‘WHOOPS’: IS LIMB SALVAGE POSSIBLE?***Charlene Yeoh Su Yin, Prashant Narhari, Azuhairy Azid, Ker Hooi Fang***RARE GIANT CELL TUMOUR OF THE SECOND METATARSAL: DIAGNOSTIC AND MANAGEMENT CHALLENGES***Nicholas Aw Shao Jiun, Noradila Ishak, Prashant Narhari, Azuhairy Azid, Zulkiflee Osman***RAREST OF THE RARE: SYNCHRONOUS MULTIFOCAL SMALL CELL OSTEOSARCOMA***Sui Khen Chaw, Abdul Kahir Misnan***RECOGNIZING ANGIOMATOID FIBROUS HISTIOCYTOMA***Fauziana Abd Jabar, Ed Simor Khan Mor Japar Khan***SCARCE AS HEN’S TEETH- PRIMARY BONY LYMPHOMA***Mohamad Faris Md Ariff, Hariharan Kumarasamy, Noreen Fazlina, Muhammad Anwar Hau Abdullah***SOFT TISSUE TUBERCULOSIS HYPOTHENAR OF THE HAND***Syed Nashraf Shah, Wan Faisham Wan Ismail***THE DILEMMA OF A SWOLLEN CLAVICLE: FIBROUS DYSPLASIA OF CLAVICLE***Muhammad Syafiq Hamidan, Hariharan Kumarasamy, Mohammad Anwar Hau Abdullah***THE GREAT IMPOSTOR: RUNNING INCOGNITO***Choong Chee Leong, Charlene Yeoh Su Yin, Sanjeevan Radhakrishnan, Prashant Narhari, Azuhairy Azid***THE MISPLACED GIANT, GCT ULNAR. 4 YEARS REVIEW***Mohamad Faris Md Ariff, Nurul Wahida Mohamad Zaki, Mazlina Awang, Muhammad Anwar Hau Abdullah***TUBERCULOSIS THE ULTIMATE IMITATOR: INTRAMUSCULAR TUBERCULOSIS IN AN IMMUNOCOMPETENT PERSON IMITATING SOFT TISSUE SARCOMA***Tan Joo Boon, Wan Faisham Nu’man Wan Ismail, Nor Azman Mat Zin, Sahran Yahaya***UNEXPECTED INTRAMUSCULAR PECTORALIS MUSCLE METASTASIS OF GALLBLADER CARCINOMA***Abdul Rahman Nik Mazian, Sahran Yahaya, Wan Faisham Nu’man Wan Ismail***UNUSUAL PRESENTATION OF A LARGE UPPER LIMB PRIMARY MALIGNANT MELANOMA: A CASE REPORT***Ooi Gaik Khim, Shaun De Silva, Mohamed Hafizudin Abdullah Sani, Nor Hazla Muhammad Hafilah***WHERE IS MY CLAVICLE? MULTIPLE MYELOMA MANIFESTATION IN BOTH CLAVICLES***Raimi Adam Chen, Muhamad Nazrin Mustafa, Ronny Arul Arumugam***WHOOH! NOT AN ABSCESS.. WHAT TO DO? JUXTACORTICAL CHONDROMYXOID FIBROMA. A RARELY ENCOUNTERED TUMOUR***Muhamad Amir Azfar Sahadun, Wan Faisham Nu’man Wan Ismail***WIDE RESECTION OF DISTAL ULNA GCT AND STABILIZATION OF ULNAR STUMP BY ECU TENDON***Tan Lip Siang, Nor Faissal Yasin, Azura Mansor, Vivek Ajit Singh*

## Orthopaedic Research

**AN IN VIVO BIOCOMPATIBLE STUDY OF ANTIMICROBIAL BIOCOMPOSITE MEMBRANE: PRELIMINARY OUTCOME**

*Sarah Haryati Mohd Zohari, Ahmad Hafiz Zulkifly, Rosnani Abd Jalil, Nurul Hafiza Mohd Jan, Muhamad Ezham Zainal Abdullah, Che Nor Zarida Che Seman, Mohd Zulfadzli Ibrahim, Zahana Abd Hamid*

**A REVIEW OF BASIC SCIENCE EVIDENCE SUGGESTING THE ROLE OF PLATELET-RICH PLASMA DERIVATIVES IN TREATING OSTEOARTHRITIS**

*Nur Hidayah Hassan, Chong Pan Pan, Tunku Kamarul Zaman Tunku Zainol Abidin*

**EFFECTS OF ADIPONECTIN ON THE MORPHOLOGY AND PROLIFERATION OF HUMAN ADIPOSE DERIVED MESENCHYMAL STROMAL CELLS**

*Shaliny Hari Rama Krishnan, Nam Hui Yin, Tunku Kamarul Zaman Tunku Zainol Abidin*

**THE EFFECTS OF HYPOXIA-INDUCIBLE FACTOR-1 $\alpha$  (HIF-1 $\alpha$ ) ON THE PROLIFERATION AND MIGRATION OF HUMAN ADIPOSE DERIVED MESENCHYMAL STROMAL CELLS IN VITRO**

*Amirah Mahfuzah Zulkifli, Nam Hui Yin, Tunku Kamarul Zaman Tunku Zainol Abidin*

**THE EFFECTS OF OXYGEN CONCENTRATION ON THE PROLIFERATION OF HUMAN ADIPOSE-DERIVED MESENCHYMAL STROMAL CELLS IN VITRO**

*Peggy Kong, Nam Hui Yin, Chan Mun Chiang, Tunku Kamarul Zaman Tunku Zainol Abidin*

**THE ROLE OF MESENCHYMAL STROMAL CELL-DERIVED SECRETOME IN ENHANCING THE POLARIZATION OF ANTI-INFLAMMATORY (M2) FROM PRO-INFLAMMATORY (M1) MACROPHAGE PHENOTYPE IN OSTEOARTHRITIC CONDITION**

*Tarini Veerappan, Krishnamurithy Genasan, Tunku Kamarul Zaman Tunku Zainol Abidin*

## Others

**A DYNAMIC WOUND CLOSURE METHOD USING CABLE TIES**

*Darshan Krishna Kumar, Low Chin Aun, Mohd Azrin Muhammad Asihin, Sree Raja Lakshmy Chandra Sekaran, Dziya Faqhran, Philemon Paul, Velman Shri Jaya, Nur Rahimah Abdul Rahim*

**AN UNCOMMON BUT COMMONLY MISSED CAUSE OF SHOULDER PATHOLOGY: TUBERCULOSIS**

*Jeffrey Jie Hao Chan, Jade Pei Yuik Ho, Angeline Madatang*

**A RARE CASE OF ISOLATED WRIST TUBERCULOSIS**

*Loh Ling Hui*

**A RARE CAUSE OF FOREARM INJURY: SNAKEBITE BY NON-VENOMOUS MALAYAN PYTHON**

*Eric Hong Qiu Weng, Kevin Kong Jun Wai, Tan Shun Heng, Jerome Hansel, Jagdish Krishnan*

**ARTHROCENTESIS IN ACUTE EXACERBATION OF KNEE OSTEOARTHRITIS – BENEFICIAL OR BARMY?**

*Nur Ayuni Khirul Ashar, Naadira Faa'iza Mazlan, Nur Syahirah Azmi, Rahul Lingam*

**A UNIQUE CASE OF UNILATERAL KNEE EFFUSION**

*Aishah Najihah Zainal Abidin*

**BIBLE BUMP OF ACROMIO-CLAVICULAR JOINT**

*Naga Bharathi Nesan, Chooi Yuo Joe, Mohd Yusof Mahidin, Yeoh Kian Hua, Shukur Ahmad, Mohd Sharifudin Said*

**BILATERAL THIGH TUBERCULOSIS SUBCUTANEOUS ABSCESS - A CASE REPORT**

*Ammar Abdol Hamid, Mohd Zoran Arif Mat Husin*

**BRONJ: THE RARE COMPLICATION OF PROLONGED USAGE OF BISPHOSPHONATE**

*Jeeva Sivashanumugam, Goh Teik Chiang, Rubinderan Muthusamy, Lai Min Chung, Dinesh Rajendran, Hesootharan Govindarajan*

**CABLE TIE WOUND CLOSURE: FIRST IN KENINGAU**

*Noorriyanti Fazreen Al Shaari, Faisal Mohd Noor*

**CASE REPORT TITLE: RARE PRESENTATION OF OSTEOMYELITIS-UNICORTICAL OSTEOMYELITIS***Yogaraj S. Balasubramaniam, Nurul Fakhri Amir, Tevanthiran Gobal***CHALLENGES IN DIAGNOSING AND MANAGING STERNOCLAVICULAR JOINT(SCJ) INFECTION: A CASE SERIES***Muhammad Hafizuddin Hanafiah, Nur Akmal Ismail Mansor, Mohamad Razip Sirat***CHRONIC OSTEOMYELITIS IN UNITED LONG BONE FRACTURE***Nur Azhani Indra Gunawan, Norsaidatul Nadriah Ahmad Shuhiamy, Satriya Sabir Husin Athar***COMMUNITY ACQUIRED CARBAPENEM RESISTANT ENTEROBACTER (CRE) MONOMICROBIAL NECROTISING FASCIITIS (NF) OF THE LOWER LIMB***Soo-Lin Teo, Soon-Yong Thow, Kwong-Lee Wan***DEADLY INJECTION: AN UNUSUAL PRESENTATION OF NECROTISING FASCIITIS***Farrel Mukhesh Rajenthran, Tan Hong Quan, Mohd Asrul Che Rahim, Mohd Nizamuddin Ghazali, Ahmad Mahyuddin Mohamed, Muhammad Hafiz Hamzah***DEMOGRAPHY OF SACRAL SORE IN HOSPITALISED PATIENTS IN HOSPITAL PAKAR SULTANAH FATIMAH MUAR IN THE YEAR 2019***Wan Afif Hafizi Wan Marzuki, Mohamad Razip Sirat***EFFECTIVENESS OF DIFFERENT SKIN PREPARATION SOLUTIONS IN PREVENTION OF SURGICAL SITE INFECTION***Jaya Thilak Shaanmugam, Mohd Hadizie Din***EXPERIENTIAL LEARNING DURING COVID-19 DISRUPTION: THE INTRODUCTION OF VIRTUAL ORTHOPEDIC CLINIC (VOC) IN HOSPITAL TENGGU AMPUAN AFZAN, KUANTAN***Lim Zhuang Li, Jacob Abraham, Kamariah Nor, Premchandran Menon, Sazali Salleh, Khairullina Khalid, Marazuki Perwira, Firdaus Sauliman, Kwan Ee Wei, Chiew Siow Yeh, Norazmi Abdullah***EXTENSIVE CHRONIC OSTEOMYELITIS OF HUMERUS AND MASQUELET TECHNIQUE***Kong Yee Sean, Tan Tiam Siong***EXTENSIVE LEFT PSOAS ABSCESS AND SEPTIC ARTHRITIS OF THE HIP WITH CONTRALATERAL SACROILITIS DUE TO STAPHYLOCOCCUS AUREUS ORGANISM FOLLOWING AN INFECTED CAESAREAN WOUND: A CASE REPORT***Syarifah Sarah Liyana Syed Osman Abadi, Muhammad Syukri Ab Hamid, Nurul Fakhri Amir, Mohamad Razip Sirat***EXTENSIVE NECROTIZING FASCIITIS COMPLICATED WITH SEPTIC ARTHRITIS: A TAWAU APPROACH OF WOUND MANAGEMENT***Sughilan Sundara Murthi, Lee Khong Wee, Mustaqim Afifi, Sazli Mohd Nor***FATAL INFECTION OF NECROTIZING FASCIITIS OF THE UPPER LIMB: A CASE REPORT***Shyful Nizam Sumari, Murali Govindasamy, Mohamad Saifudin Othman***FEMORAL ARTERY ANEURYSM CAMOUFLAGE BY DEEP SUBCUTANEUS ABSCESS***Abdullah Aqeel Musa, Felix Lau Huey Yih, Mohd Arief Mohd Yusof, Mohd Ashraf Akhtar Mokhtar***INVESTIGATING OSTEOPOROSIS KNOWLEDGE AMONG PHYSICIANS AND MEDICAL STUDENTS IN A TERTIARY HOSPITAL***Gabriel Baluyut, Carlo Emmanuel Sumpaico***LOWER LIMB PAIN IN METHICILLIN-SUSCEPTIBLE STAPHYLOCOCCUS AUREUS INFECTION: THE LIMB INTRUDER***Muhamad Faiz Zulkapli, Muhd Ilyasa Muhamad Khidir, Mohd Faieq Mohd Rosli, Ruben Jaya Kumar***NECROTISING FASCIITIS: THE RARE COMPLICATION IN A CHILD WITH PERFORATED APPENDICITIS***Ong Ren Ling, Mohd Aqiuddin Naim, Mohd Hijaz Zainuddin, Nur Syahida Mohd Termizi***NECROTIZING FASCIITIS FOLLOWING A CAT BITE***Muhammad Syahid Awang, Wong Ba Huang, Divenno Anak Jamel, Muhammad Shukri Muhammad Safian***NECROTIZING SOFT TISSUE INFECTION: MICROBIOLOGICAL DISTRIBUTION FROM DISTRICT REGION***Amri Dahdi, Hamizah Zainal, Faisal Mohd Nor, Muhammad Fahmi Ibrahim, Mohd Shaharil Abd Aziz*

**PATIENT FROM THE TWILIGHT SAGA?: A CASE REPORT OF NASTY HUMAN BITE**

*Sree Raja Lakshmy Chandra Sekaran, Low Chin Aun, Muhammad Azrin Mohd Asihin, Darshan Krishnan, Shangeetha Tharmalingam, Nur Rahimah Abdul Rahim*

**PESTILENT PARAQUAT- CURSE OF A FAMILY**

*Lim Ting Chung, Divenno Anak Jamel, Wong Ba Huang, Muhammad Shukri Muhammad Safian*

**PSOAS ABSCESS WITH SEPTIC ARTHRITIS COMPLICATED WITH SEPTIC NECROSIS OF HIP**

*Muhammad Arif Yusri, Tan Ban Song, Mohd Hudzairy Ahmad*

**PUBLIC SATISFACTION WITH ORTHOPAEDIC OUTPATIENT SERVICES IN HOSPITAL LAHAD DATU: A MINI SURVEY**

*Lai Min Chung, Goh Teik Chiang, Jeeva Shanumugam, Dinesh Rajandran, Hesootharan Govindarajan*

**RARE CASE OF SEPTIC ARTHRITIS CAUSED BY AEROMONAS HYDROPHILIA AND TUBERCULOUS CO-INFECTION: A CASE REPORT**

*Rosalind Wong Huey Yin, Chay Guo Qin, Foo Choong Hoon, Bong Chin Pei, Norisyam Yusoff*

**RARE CASE OF SYMMETRICAL PERIPHERAL GANGRENE DUE TO SEPTIC SHOCK AND INOTROPIC USE**

*Nur Hanna Safii, Ainna Marissa Kamalul Ariffin, Mohammed Harris Anwarali Khan*

**RETROSPECTIVE EPIDEMIOLOGY STUDY OF ANIMAL BITE INJURIES IN LAHAD DATU: 5 YEARS SURVEY**

*Hesootharan Govindarajan, Goh Teik Chiang, Dinesh Rajandran, Lai Min Chung, Jeeva Shanumugam*

**RUPTURED BAKER'S CYST CAUSING LIMB THREATENING ISCHEMIA: A CASE REPORT**

*Belzinder Pal Singh, Marazuki Haji Perwira, Aziah Abdul Aziz*

**SKIN ALLERGY TO SILVER DRESSING POST TOTAL KNEE REPLACEMENT MIMICKING SURGICAL SITE INFECTION**

*Kugan Ramachandran, Vikneswaran Govindasamy, Azlan Mohd Sofian*

**TB ANKLE: A DIAGNOSIS EASIER SAID THAN DONE**

*Mohamad Faris Md Ariff, Nurul Wahida Mohamad Zaki, Samsuddin Mat Hassan, Muhammad Anwar Hau Abdullah*

**TB KNEE IN HIV PATIENT: THE ELUSIVE VILLAIN**

*Syed Mohd Esmat Hussaini, Tiw Zhung Shen, Suhana Samsul Baharin, Mohamad Fauzlie Yusof*

**THE ASSOCIATION BETWEEN THE WEIGHT OF DONATED FEMORAL HEADS AND THE DONORS' RACE, AGE AND GENDER**

*Mohammed Ziyad Albaker, Nor Faissal Yasin, Saravana Ramalingam, Norimah Yusof, Azura Mansor*

**THE MIMICKER, TUBERCULOSIS KNEE!**

*Mah Yew Leng, Andrew Lim Yu In, Boon Huck Wee, Joanne Ngim*

**TWO STAGE RECONSTRUCTIVE SURGERY IN CHRONIC OSTEOMYELITIS OF ISOLATED ULNA**

*Khaw Yam Chuan, Sahran Yahaya, Nor Azman Mat Zin, Wan Faisham Wan Ismail*

**UNLIKELY ELBOW SEPTIC ARTHRITIS? A CASE REPORT**

*Muhamad Nazrin Mustafa*

**WALKING BAREFOOT ON THE BEACH: BE CAREFUL!**

*Xian Ee Yong, Jade Pei Yuik Ho*

**WHEN STRATIFIED FOR AGE, DO OUTCOME SCORES REFLECT PATIENT SATISFACTION LEVELS?**

*Enda McGinley, Ronan McKeown, Tim Doyle*

**WRIST TUBERCULOSIS: A RARE MANIFESTATION OF EXTRAPULMONARY TUBERCULOSIS**

*Aishah Najihah Zainal Abidin, Norsaidatul Akmal Abdul Malek*

## Paediatric

**A BOY WITH A RIFLE - A CASE OF AN UNTREATED DISTAL HUMERAL PHYSEAL SEPARATION***Mohd Saperi Zool Kipele, Muhammad Kamal Mohd Abdul Jalil, Ahmad Fazly Abd Rasid***A CASE OF CONGENITAL KNEE DISLOCATION***Patrina Chan Ke Jing***A CASE REPORT OF INFANTILE HAND CELLULITIS PRESENTING WITH RAPID ONSET HEMORRHAGIC BULLAE***Chua Jia Jing, Wan Kong Lee, Mooi Sung Siang, Rashdeen Fazwi Muhammad Nawawi***A CASE REPORT ON CPT: FD NAIL AND BMP USAGE AS ADJUNCT WITH ILLIZAROF FIXATION TO PROMOTE UNION***Mohd Firdaus Hafni Ahmad, Muhamed Ismeth Samsudeen, Zulkiflee Osman***A CASE REPORT: STAPHYLOCOCCUS AUREUS INTRAMUSCULAR ABSCESS ASSOCIATED WITH DEEP VEIN THROMBOSIS IN CHILD***Mohamad Hafiz Mohamad Zaini, Mohamad Hafiz Hamzah, Atikah Amirah Suzzana Abdullah, Nor Hidayah Abdullah, Mohd Faizal Nik Man Lee, Kuharajan Ramalingam, Nor Hafizah Mohd Nor, Nurul Akma Azmi, Ong Kiat Yee***A COMPLETE CASE REPORT OF GOLLOP-WOLFGANG COMPLEX: SURGERY, BOULEVARD TO REJUVENATE FUNCTIONALITY – AN UPDATE AFTER 3 YEARS OF SURGERY***Mohammad Farid Azmi, Nor Hidayah Abdullah, Atikah Amirah Suzanna Abdullah***ACUTE HEMATOGENOUS OM OF THE DISTAL FEMUR IN A TEENAGER WITH THALASSEMIA***Abilash Kumar, Imma Isniza Ismail, Fahrudin Che Hamzah***A MALGAIGNE FRACTURE WITH AN OPEN COMMINUTED FRACTURE PROXIMAL 3RD LEFT FEMUR. A SAD CASE REPORT OF NEGLIGENCE DRIVING***Syed Nashraf Shah, Syurahbil Abdul Halim, Wan Faisham Wan Ismail***AN EXTREMELY RARE CASE OF BILATERAL RING FINGER TRIGGER FINGER IN CHILDREN: A CASE STUDY***Sujendra Prasad Rao Sivarao, Chathiya Seelan Baskeran, Sashitharan V. Ampalakam, Muhammad Affji Idris, Ngo Pei Ern, Teo Yu Meng***ANGULAR DEFORMITY IN TRANSTIBIAL AMPUTATION IN PEDIATRIC PATIENT***S Suresh Sri Ramulu, Nik Alyani Abdul Adel, Ardilla Hanim Abdul Razak, Mohd. Shukrimi Awang***ANKLE JOINT SEPTIC ARTHRITIS WITH SUBSEQUENT PAN-OSTEOMYELITIS IN A PAEDIATRIC PATIENT DESPITE EARLY TREATMENT AND SURGICAL DEBRIDEMENT: A CASE REPORT***Fatin Farhana Manas, Mohd Reza Mohd Aridz***ANKLE SEPTIC ARTHRITIS IN AN UP-TO-DATE IMMUNIZED INFANT***Danial Faris Hilmi, Richford Anak Jonathan, Chan Zhi Yung***ANKLE TUBERCULOSIS IN INFANCY: A NIGHTMARE IN DIAGNOSING, A CONFLICT IN TREATING***Maria Mardi, Sharifah Nor Tasnim Alsagoff, Norsaidatul Nadriah Ahmad Shuhiamy, Satriya Sabir Husin Athar***A NOVEL APPROACH TO TREAT LEG LENGTH DISCREPANCIES***Paul Tan Boon King, Mohd Anuar Ramdhan Ibrahim, Haniza Sahdi, Faris Indra Prahasta***AN UNUSUAL CASE REPORT OF HIP JOINT SEPTIC ARTHRITIS COMPLICATED WITH FEMUR OSTEOMYELITIS AND PANDIAPHYSITIS IN A CHILD***Koh Pei Khen, Fadzly Ramidi, Sugesh Rhagavan, Allan Ravi Rajagopal***A RARE CASE OF INFANTILE BACILLE CALMETTE-GUÉRIN (BCG) OSTEOMYELITIS IN URBAN SETTING***Nicholas Soong Jin Yih, Maria Shelynn Wong, Devarani Pancharatnam, Saw Aik***A RARE CASE OF MANIFESTING FEMALE CARRIER IN PATIENTS WITH DUCHENNE MUSCULAR DYSTROPHY***Kerryn-Anne Shalini Shelton, Leong Li Theng, Abdul Razak Sulaiman, Emil Fazliq Mohd, Ismail Munajat***A RARE CASE OF TRAUMATIC POSTERIOR SHOULDER DISLOCATION: A CASE REPORT***Sree Raja Lakshmy Chandra Sekaran, Muhammad Azrin Mohd Asihin, Low Chin Aun, Shangeetha Tharmalingam, Darshan Krishnan, Tungku Naziha Tunku Zainudin, Nur Rahimah Abdul Rahim*

**A RARE PRESENTATION OF MISSED ATLANTO-AXIAL SUBLUXATION WITH FRACTURE CLAVICLE***Ong Kiat Yee, Hazizul Helmy Hamad@ Ahmad, Iqmal Hakeem Isa, Mubsirah Mohd Fadzhil***CASE REPORT: METAPHYSEAL BANDS IN OSTEOGENESIS IMPERFECTA***Syarul Arwiz Sahruzaman, Lim Wee Cheong, Anwar Azhari Abdul Karim, Anuar Ali, Mashayati Muhamad***CLOSE INTERTHROCANTERIC FRACTURE OF FEMUR IN PAEDIATRIC AGE GROUP TREATED WITH CONTRALATERAL PROXIMAL HUMERAL INTERNAL LOCKING SYSTEM (PHILOS): A CASE REPORT***Mohd Naiman Fahimy Hj Mustapa, Lim Wei Khang, Nanchappan Selvanathan***COMPOSITE GRAFT REPAIR FOR TRAUMATIC TOTAL AMPUTATION OF DISTAL FINGERTIP: A CASE REPORT***Lim Kgai Ter, Hedaayah Himmi, Dinesh Earnest Kunasingh***CRYING INFANT WITH SWOLLEN TOES, HAIR-THREAD TOURNIQUET SYNDROME***Sri Arun Sellvam, Madya Shalimar Abdullah, Jamari Sapuan***DCP, THE LOYAL SAVIOR – A RARE CASE OF A DELBET IV FRACTURE***Mohd Syazwan Che Seman, Muhd Ikhwan Yusuf, Muhd Ihsan Hamdan, Jaya Thilak Shanmugam***DEVELOPMENTAL DYSPLASIA OF HIP IN CORNELIA DE LANGE SYNDROME: A CASE REPORT***Tengku Akmal Faris Tengku Ahmad, Norsaidatul Nadriah, Satriya Sabir Husin Athar***DIAGNOSTIC DILEMA: MONOARTHRITIS IN CHILDREN –SEPTIC ARTHRITIS OR ACUTE RHEUMATIC FEVER?***Carolyn Choong, Zulkiflee Osman***EXTRAARTICULAR EXTERNAL FIXATION AND K WIRING FOR CLOSED COMMUNUTED SUPRACONDYLAR FRACTURE OF HUMERUS***Muhammad Haniff Azman, Chu Hui Xin, Mohd Nazri Nor***FACTORS CONTRIBUTING ACUTE COMPARTMENT SYNDROME IN A FRACTURED ARM***Kathleen Teo Khai Ling, Kamarulzaman HJ M.S Kadir, Rifa Aqidah Subhan, Kamarul Al-Haqq Abdul Ghani***FAMILIAL ECTRODACTYLY: A RARE REPORT OF LOBSTER-CLAW IN A MALAY FAMILY***Nur Ayuni Khirul Ashar, Imma Isniza Ismail, Naadira Faa'iza Mazlan, Nur Syahirah Azmi, Rahul Lingam***FIBULAR DEFICIENCY WITH BONE LENGTHENING: A CASE REPORT***Syahril Izwan Alias, Mohd Shukrimi Awang, Ardilla Hanim Abdul Razak, Nik Alyani Nik Abdul Adel***FLOATING ANKLE IN PAEDIATRIC A CASE REPORT***Ling Lii Tat, Mohd Anuar Ramdhan Ibrahim, Mohd Rifhan Syahmi Mohd Rusdi***FLOPPY FOOT: A CASE OF NEONATAL SCIATIC NERVE INJURY***Muhammad Ameer Faris, Mohd Nazri Nor***FRACTURE WHILE SWIMMING IN A POOL OF AMNIOTIC FLUIDS***Muhammad Faliqhakim Mohd Razip Wee, Mohd Azhar Hussein, Tan Ban Song***HAIR TOURNIQUET SYNDROME; RARE BUT POTENTIALLY HARMFUL***Aidy Azuan Afifi Ismail, Mohd Arif Mohd Nor, Nurhanani Abu Bakar***INCOMPLETE SLIPPED CAPITAL FEMORIS EPIPHYSIS WHICH IS MIMICKING SEPTIC HIP ARTHRITIS: A CASE REPORT***Siek Ing Mou, Mohd Zulkifli Shafii, Deepanesh M P Lakshmanan, Kamarulzaman Mohd Ali***ISOLATED PEDIATRIC ELBOW DISLOCATION WITH MEDIAN NERVE INJURY: A CASE REPORT***Siek Ing Mou, Mohd Zulkifli Shafii, Deepanesh M P Lakshmanan, Kamarulzaman Mohd Ali***IS THE END-CAP THE END-GAME? TRANSTIBIAL AMPUTATION IN A SEVERE CASE OF AMNIOTIC BAND SYNDROME INCORPORATING OSTEOCHONDRAL END-CAP TO PREVENT STUMP OVERGROWTH***Danial Fa-iz Ibrahim, Nurhanani Abu Bakar***LATERAL HUMERAL CONDYLE FRACTURE IN PRE-EXISTING POST-TRAUMATIC SUPRACONDYLAR HUMERUS FRACTURE WITH CUBITUS VARUS DEFORMITY***Jude Cornelius Savarirajo, Mohd Asraf Mohd Aris, Emil Fazliq Mohd, Ismail Munajat, Abdul Razak Sulaiman*



**LISFRANS INJURY IN PEDIATRIC; AN UNCOMMON CASE REPORT***Aishah Najihah Zainal Abidin, Noorriyanti Fazreen Al Shaari***MANAGEMENT OF A PEDIATRIC BASICERVICAL FRACTURE WITH K-WIRE INSERTION AND HIP SPICA***Mohd Syazwan Che Seman, Muhd Ikhwan Yusuf, Muhd Ihsan Hamdan, Jaya Thilak Shanmugam***MIRACLE RE-MODELLING OF BONE NECROSIS IN PANOSTEOMYELITIS IN PEDIATRIC AGE GROUP***Ker Hooi Fang, Zulkiflee Osman, Mohd Firdaus Hafni Ahmad, Chin Siang Leon, Charlene Yeoh Su Yin, Andrew Lim Yu In***NEONATAL SEPTIC KNEE ARTHRITIS – A CASE REPORT***Cheong Jo-Yi, Mohd Reza Aridz***NEUROBLASTOMA: COMMONLY MISSED COMMONEST PAEDIATRIC METASTATIC BONE DISEASE***Sandeep Singh Bhagat Singh, Mohd Firdaus Hafni Ahmad, Sia Ung, Nur Syahida Mohd Termizi, Zulkiflee Othman***NON UNION LATERAL CONDYLE HUMERUS WITH CUBITAL VARUS: UNION AFTER CORRECTIVE OSTEOTOMY***Nurul Hanani Abdul Hami, Norzakiah Abu Mansor Matardiah, Syed Addi Usmi Syed Othman***“NOT WHAT IT SEEMS TO BE”: A RARE CASE OF LEFT ULNA BRODIE’S ABSCESS IN CHILDREN***Elsonmond Vick Duin, Chan Wai Hoong, Mohammad Zaki Haji Mohd Amin***OGDEN INJURY OF TIBIAL EPIPHYSEAL IN ADOLESCENT: A CASE REPORT***Wan Mahafeez Wan Kamarul Zaman, Murali Govindasamy, Basir Towil***OUTCOME OF SUBTALAR ARTHROEREISIS IN PAEDIATRIC FLEXIBLE FLATFOOT***Sia Ung, Nur Syahida Mohd Termizi, Mohd Firdaus Hafni Ahmad, Zulkiflee Osman***PAEDIATRIC PELVIC FRACTURE: NOT YOUR TYPICAL TYPE FRACTURE***Shanjay Letchumanan, Ling Jian Loong, Manoharan Krishnan***PAEDIATRIC POST-TRAUMATIC CYST LIKE LESION FORMATION FOLLOWING A DISTAL END RADIUS GREENSTICK FRACTURE***Deepak Singh Peram Singh, Abdul Kahir Misnan***PAEDIATRIC SEPTIC ARTHRITIS WITH PSEUDOPARALYSIS: A CASE REPORT***Danial Fa-iz Ibrahim, Ong Yu Yi, Felix Lau Huey Yih***PERIARTICULAR SWELLING IN CHILDREN: A BENIGN MIMICKER***Jeffrey Chong Wei Jie, Cheong Yuen Zhi, Choo Qi Qi, Kamarul Al-Haqq Abdul Ghani***PINK PULSELESS SUPRACONDYLAR FRACTURE OF HUMERUS WITH IPSILATERAL RADIUS AND ULNA FRACTURE: A CASE REPORT***Muhammad Syafiq Hamidan, Hariharan Kumarasamy, Mohammad Anwar Hau Abdullah***PLEASE HANDLE ME WITH CARE, I BREAK EASILY!***Paul Tan Boon King, Mohd Anuar Ramdhan Ibrahim, Haniza Sahdi, Sia Ung***POST-TRAUMA PAIN IN CHILDREN – IS IT REALLY A SOFT TISSUE INJURY?***Nur Fatin Fariza Fauzi, Norsaidatul Akmal Abdul Malek, Faisal Mohd Noor***RARE CASE OF PSEUDOMONAS AERUGINOSA ASSOCIATED PATELLAR OSTEOMYELITIS IN PAEDIATRIC***Ng Lim Hong, Lee Sin Yen, Wong Jia Yen, Teo Yu Meng***RARE OCCURANCE OF TIBIA PLATEAU FRACTURE IN A THIRD TRIMESTER PREGNANT LADY WITH UNDIAGNOSED OSTEOGENESIS IMPERFECTA***Syed Nashraf Shah, Abdul Nawfar Sadagatullah***RARE RECURRENT SPONTANEOUS ATRAUMATIC BILATERAL ANTERIOR SHOULDER DISLOCATION: A CASE REPORT***Lim Kgai Ter, Dinesh Earnest Kunasingh, Ahmad Fazly Abd Rasid*

**RAYTEX GAUZE FOR CONFIRMATION OF FEMUR HEAD POSITION IN DIFFICULT OPEN REDUCTION OF IMMATURE HIP DISLOCATION**

*Ker Hooi Fang, Zulkiflee Osman, Mohd Firdaus Hafni Ahmad, Chin Siang Leon, Andrew Lim Yu In, Muhammad Reezal Mohd Abadi*

**RECALCITRANT WINDSWEP KNEE DEFORMITY WITH UNDERLYING BLOUNT DISEASE**

*Khaw Yam Chuan, Emil Fazliq Mohd, Ismail Munajat, Abdul Razak Sulaiman*

**RETT SYNDROME: A RARE DISEASE WITH LOW ENERGY FEMUR FRACTURE**

*Adzhar Abdul Latib, Ahmad Faizal Abdullah, Zoran Arif Mat Hussin, Mohd Ariff Salleh*

**SALMONELLA SHOULDER SEPTIC ARTHRITIS: CASE REPORT**

*Yogeshwaran Nadeson, Jagjoth Singh Darshan Singh*

**SEPTIC ARTHRITIS OF ELBOW IN A NEONATE: A CASE REPORT**

*Izzul Faiz Razali, Fabian Chong Tien Fook*

**SEQUALAE OF PAEDIATRIC OSTEOARTICULAR INFECTION: A CASE OF ISOLATED PAN OSTEOMYELITIS OF FIBULA**

*Shukriah Aqilah Zakaria, Chong Jung Syn, Mohd Aizat Azfar Soldin, Raeross Anak Jabul*

**SEVERE INFANTILE BLOUNT'S DISEASE: A CASE REPORT**

*Chin Siang Leon, Ker Hooi Fang, Mohd Firdaus Hafni, Zulkiflee Osman*

**SLEEVE PATELLA FRACTURE OF INFERIOR POLE IN A CHILD: A CASE REPORT**

*Muhammad Redza Ihsan Rosli, Muhammad Najib Omar, Mohd Firdaus Hafni Ahmad, Zulkiflee Osman*

**SPECIAL TECHNIQUE IN PERCUTANEOUSLY FIXATION OF RADIAL NECK FRACTURE (SALTER HARRIS TYPE II) IN PEDIATRIC AGE GROUP: A RARE CASE REPORT**

*Premdas Velumyilum Baladas, Mohammad Arshad Ikram, Fazrina Ayu Abd Sani, Abdul Rauf Hj Ahmad*

**THE MASQUERADE: TUBERCULOUS OSTEOMYELITIS OF TIBIA IN A 1 YEAR OLD INFANT**

*Chin Siang Leon, Zareze Abdul Rahaman*

**TOE MACRODACTYLY, MACRODYSTROPHIA LIPOMATOSA, FIBROLIPOMATOUS HAMARTOMA & LIPOMATOSIS OF NERVE. ARE THEY SIMILAR?**

*Syed Azhariff Syed Yahya, Srijit Das, Abdul Halim Abdul Rashid, Wan Syahira Wan A Kammal, Kamal Jamil*

**TOE TOURNIQUET SYNDROME - A RARE PAEDIATRIC EMERGENCY**

*Priyadarssini Karunakaran, Harmony Tan Chern Yang, Mahazura Mat Lawi, Hishamuddin Salam*

**TRAUMATIC DISLOCATION OF THE HIP IN A CHILD CAUSED BY TRIVIAL FORCE**

*Nur Syahida Mohd Termizi, Sia Ung, Mohd Firdaus Hafni Ahmad, Zulkiflee Osman*

**TRAUMATIC HIP DISLOCATION IN DOWN SYNDROME CHILD - A DILEMMA**

*Nur Aidurra Zainudin, Fadzly Ramidi*

**TRAUMATIC HIP DISLOCATION IN PAEDIATRIC: A RARE CASE**

*Muhammad Syukri Ab Hamid, Nurhanani Abu Bakar, Nur Akmal Ismail Mansor, Mohamad Razip Sirat*

**TRICEPS PRESERVING SURGERY IN A GIRL WITH CHRONIC COMPLICATED ELBOW DISLOCATION: A CASE REPORT**

*Syed Mohd Esmat Hussaini Syed Mohd Ridzuan, Tiw Zhung Shen, Wan Zainuddin Wan Ab Rahman, Mohamad Razip Sirat*

**TRIPLE THREAT SEPTIC ARTHRITIS IN CHILDREN: AN ORTHOPAEDIC EMERGENCY**

*Prevheenraj Naidu Thevaraj, Chan Zhi Yung, Norsaidatul Nadriah Ahmad Shuhiamy, Satriya Sabir Husin Athar*

**WHY IS MY CHILD'S LEG NOT STRAIGHT?: A CASE OF POST TRAUMATIC TIBIA VALGA**

*Sakinah Mohd Razali, Abd Halim Abdul Rashid*

**WRIST FRACTURE IN A NEONATE AT RISK: A CASE REPORT**

*Ku Seng Koon, Norlizam Mohd Nor*

## Spine

**A BACK-BREAKING CONDITION: CASE OF VERTEBRAL PLANAR FRACTURE WITH CORD COMPRESSION***Wan Mohd Hayatuddin Razi Wan Abd Ghani, Muhammad Fawwaz Zamri, Ruben Jaya Kumar***A CASE OF DECOMPRESSION C1 LAMINECTOMY WITHOUT FUSION FOR CRANIOVERTEBRAL JUNCTION STENOSIS WITH MYELOPATHY: A CASE REPORT***Muhammad Ariff Mohd Yunus, Adila Irene Nur Ibrahim, Dzulkarnain Amir, Fazir Mohamad***A CASE OF MULTILEVEL SPINE TUBERCULOSIS***Mohd Fikri Razali, Mohd Shukry Mat Eil @ Ismail, Zakaria Yusoff, Lim Tze Chwen, Ahmad Sabri Omar***A CASE OF NEAR MISS SPINAL TUBERCULOSIS***Patrina Chan Ke Jing***ADOLESCENT LIMBUS VERTEBRA MIMICKING SPONDYLODISCITIS***Adzhar Abdul Latib, Ahmad Faizal Abdullah, Zoran Arif Mat Hussin, Mohd Hazim Mohd Azhar***A LATE ONSET OF HIRAYAMA DISEASE WITH LATE PROGRESSION IN A MALAYSIAN MAN: CASE REPORT***Kishaani Pathamanathan, Logheswaren Suppiah, Nadia Najwa Bakri, Afiqah Md Radzi***AN UNUSUAL PRESENTATION OF ACUTE PARAPARESIS IN A PATIENT WITH ACUTE LYMPHOBLASTIC LEUKAEMIA AND METASTATIC RECTAL ADENOCARCINOMA***Nicholas Aw Shao Jiun, Lim Han Sim, Zairul Anuar Kamarul Bahrin***A PRICKING COMPLICATION***Bryan Teoh Ching Eng, Abdul Muhaimin Aziz, Jeffrey Chong Wei Jin, Kamarul Al Haqq Abdul Ghani***A RARE CASE OF ATRAUMATIC SPONTANEOUS SPINAL CORD INJURY-OWL EYE SIGN***Chong Yee Tong, Lim Han Sim***A RARE CASE OF BERTOLOTTI'S SYNDROME WITH SURGICAL MANAGEMENT IN A YOUNG PATIENT: A CASE REPORT***Selvan Danappal, Azizul Akram Salim, Joehaimy Johari, Mohd Imran Yusof***A RARE CASE OF TOPACEOUS GOUT OF SPINE: INCIDENTAL FINDING FROM CECT AND MRI OF PATIENT WITH CHRONIC UNTREATED GOUT***Irwan Mohamad Ali, Mohamad Zaki Haji Mohd Amin, Nur Aida Faruk Senan***A RARE FRACTURE DISLOCATION OF T7-T8 VERTEBRAE WITH COMPLETE SPINAL CORD TRANSECTION***Mohd Luqman Haji Anuar, Nurhanani Abu Bakar***A RARE INCIDENCE OF TANDEM SPINAL STENOSIS IN YOUNG PATIENT: A CASE REPORT***Weng Vei Chiam Tah Kong, Rosalind Wong Huey Yin, Bong Chin Pei, Mohamed Faizal Abdul Manan, Norisyam Yusoff, Foo Choong Hoon, Wong Chung Chek***A RARE NON-CONTIGUOUS MULTIFOCAL SPINAL TUBERCULOSIS: A CASE REPORT***Muhammad Ariff Mohd Yunus, Dzulkarnain Amir, Fazir Mohamad***A RARE OCCURRENCE: YOUNG GENTLEMAN WITH C2-C6 OSSIFICATION OF POSTERIOR LONGITUDINAL LIGAMENT (OPLL)***Mubsirah Mohd Fadzhil, Hazizul Helmy Hamad@Ahmad, Amalina Muhamad, Azizul Akram Salim***A RARE OPERATIVE APPROACH TO A WORSENING SCOLIOSIS IN A FACIOSCAPULAHUMERAL MUSCULAR DYSTROPHY ADOLESCENT***Syed Nashraf Shah, Mohd Imran Yusof, Joehaimy Johari***A SPINAL EPIDURAL ABSCESS WITH PSEUDOMEMBRANE***Mohd Azwan Ab Aziz, Azizul Akram Salim, Joehaimy Johari, Mohd Imran Yusof***ATYPICAL PRESENTATION OF A RARE ENTITY: SALMONELLA SPONDYLODISCITIS IN AN AFEBRILE PATIENT WITH ULCERATIVE COLITIS AND SWEET'S SYNDROME***Nicholas Aw Shao Jiun, Zairul Anuar Kamarul Baharin, Mohd Hisam Muhamad Ariffin, Azmi Baharuddin, Sabarul Afian Mokhtar*

**BAMBOO FRACTURE: A CASE REPORT**

*Mohamad Norazrin Mohd Abas, Nur Shakinah Ajak, Lee Sing Huat, Thiru Kumaran Moothakumaran*

**BERTOLOTTI'S SYNDROME: AN UNDERDIAGNOSED CAUSE OF LOWER BACK PAIN; CASE REPORT AND MANAGEMENT OPTIONS**

*Ling Lee Siang, Kerry-Anne Shalini Shelton, Seo Soon Teck, Sivapathasundaram C. Nadarajah*

**CASE SERIES: SEVERE ADOLESCENT IDIOPATHIC SCOLIOSIS WITH POSTERIOR CORRECTION AND SPINAL FUSION**

*Mohd Azwan Ab Aziz, Azizul Akram Salim, Joehaimey Johari, Mohd Imran Yusof*

**CERVICAL MYELOPATHY IN AN ELITE BADMINTON PLAYER - A CASE REPORT**

*See Zhi Huang, Mohamad Shariff Ahamid*

**CERVICAL MYELOPATHY SECONDARY TO ATLANTOAXIAL INSTABILITY IN DOWN SYNDROME: A CARE REPORT**

*Shyful Nizam Sumari, Azizul Akram Salim, Joehaimey Johari, Mohd Imran Yusof*

**CHRONIC SPINAL CORD COMPRESSION SECONDARY TO BROWN TUMOUR IN AN END-STAGE RENAL DISEASE PATIENT: A CASE REPORT**

*Ong Kean Loong, Ikhwan Abd Samad, Nor Azlin Zainal Abidin, Thuraikumar Kanniah, Amir Fariz Zakaria, Faizal Manan, Wang Chee Seiang*

**EVALUATION OF ILIOPSOAS ABSCESS TREATED WITH PERCUTANEOUS DRAINAGE**

*Mohd Kamel Mat Jusoh, Joehaimey Johari*

**EWING'S SARCOMA FAMILY OF TUMOUR IN ADULTS: A RARE CASE OF POSTERIOR MEDIASTINAL EWING'S SARCOMA WITH INTRASPINAL EXTENSION CAUSING SPINAL CORD COMPRESSION**

*Tan Joo Boon, Amrik Singh Ranjit Singh, Lim Han Sim, Khoh Phaik San, Normawathy Amir Osman, Zairul Anuar Kamarul Bahrin*

**EXTENSIVE SPINAL EPIDURAL ABSCESS IN ADOLESCENT: A RARE CASE REPORT**

*Che Mohd Hanif Che Mat, Abdul Rahman Nik Mazian, Lim Han Sim, Ahmad Sabri Omar, Mohd Shukry Mat Eil@Ismail*

**FINAL FUSION AFTER GROWING RODS IN EARLY ONSET SCOLIOSIS**

*Tan Yin Ying, Chung Weng Hong, Chiu Chee Kidd, Chris Chan Yin Wei, Kwan Mun Keong*

**HIV RELATED EBV-ASSOCIATED SMOOTH MUSCLE TUMOR OF THORACIC SPINE: A CASE REPORT**

*Elsomond Vick Duin, Mohammad Zaki Haji Mohd Amin, Dayangku Norlida Awang Ojep, Nur Aida Faruk Senan*

**IDIOPATHIC SCOLIOSIS IN MONOZYGOTIC TWIN: CASE REPORT AND REVIEW OF POSSIBLE FACTOR**

*Muhammad Syafiq Hamidan, Hariharan Kumarasamy, Mohammad Anwar Hau Abdullah*

**INJURY TO A RIGID SPINE: A TALE OF THREE SPINES**

*Wang Chen Kang, Ruben Jaya Kumar*

**IS LATE DECOMPRESSION SURGERY VIABLE IN TREATING TRAUMATIC SPINAL CORD INJURY? A CASE OF EXTENSIVE NEUROLOGICAL IMPROVEMENT AFTER LATE DECOMPRESSION SURGERY**

*Leon Hui Ming, Ong Kean Loong, Wang Chee Seiang, Mohamed Faizal Abdul Manan, Thuraikumar Kanniah, Amir Fariz Zakaria, Nor Azlin Zainal Abidin*

**LIMBUS VERTEBRA MASQUERADING AS LUMBAR SPONDYLODISCITIS – A RARE PRESENTATION**

*Ling Lee Siang, Seo Soon Teck, Sivapathasundaram C. Nadarajah*

**MELIOIDOSIS PYOGENIC SPONDYLODISCITIS**

*Kathleen Teo Khai Ling, Mohammed Faizal Abdul Manan, Kamarul Al-Haqq Abdul Ghani, Cheong Yuen Zhi*

**MODIC 1 MRI SIGNAL COULD SIGNIFY THE EARLY SIGN OF SPINAL INFECTION IN CHRONIC LOW BACK PAIN PATIENT - A CASE REPORT**

*Yeo Siang Yew, Chung Weng Hong, Chiu Chee Kidd, Chris Chan Yin Wei, Kwan Mun Keong*

**NON SURGICAL TREATMENT FOR CERVICAL SPONDYLODISCITIS WITH EPIDURAL ABSCESS: OUTCOME OF 2 CASES**

*Amrik Singh Ranjit Singh, Tan Joo Boon, Lim Han Sim, Khoh Phaik San, Normawathy Amir Osman, Zairul Anuar Kamarul Bahrin*

**NONSURGICAL TREATMENT IN RARE PAEDIATRIC UPPER CERVICAL SPINAL TUBERCULOSIS***Chay Guo Qin, Rosalind Wong Huey Yin, Foo Choong Hoon, Bong Chin Pei, Norisyam Yusoff***ODONTOID SYNCHONDROSIS FRACTURE –CASE REPORT ON THE SUCCESSFUL MANAGEMENT OF A RARE INJURY***Belzinder Pal Singh, Marazuki Haji Perwira, Su Yuen***OPERATIVE FIXATION OF THORACIC SPINE FRACTURE - A CASE REPORT***Dinesh Murugaiah, Muhammad Nabil Mohamaddin, Sudhagar Krishinan***PARAPLEGIA AFTER GENERAL ANESTHESIA: A DEBILITATING ADVERSITY***Syed Mohd Esmat Hussaini, Tiw Zhung Shen, Wan Zainuddin Wan Ab Rahman, Mohamad Razip Sirat***PLASMACYTOMA IN CERVICAL SPINE***Muhammad Ariff Mohd Yunus, Hazheem Syazwan Hussin, Dzulkarnain Amir, Fazir Mohamad***POSTERIOR INSTRUMENTATION WITH FUSION IN A C4/C5 BILATERAL FACET DISLOCATION PATIENT WITH SINUS SICK SYNDROME TREATED WITH PACEMAKER***Shyful Nizam Sumari, Azizul Akram Salim, Joehaimey Johari, Mohd Imran Yusof***POTT'S DISEASE OF CERVICAL: A CASE REPORT***Muhammad Hazim Mohd Azhar, Mohd Norfahmi Md Hashim***RARE AXONAL VARIANT OF GUILLAIN-BARRE SYNDROME MIMICKING ACUTE SPINAL CORD INJURY POST TRAUMA: A CASE REPORT***Kishaani Pathamanathan, Noor Sa'adah Kasim***RARE CASE OF EWING SARCOMA OF THE SPINE MIMICKED TUBERCULOUS SPONDYLITIS: A CASE REPORT***Rosalind Wong Huey Yin, Wengvei Chiam Tah Kong, Foo Choong Hoon, Bong Chin Pei, Norisyam Yusoff, Mohamed Faizal Abdul Manan, Wong Chung Chek***RETAINED EPIDURAL CATHETER POST CAESAREAN DELIVERY, TO REMOVE OR NOT TO REMOVE: A CASE REPORT***Mohamed Khaliq Isa, Mohd Norkhairul Hasfanizam Ibrahim, Mohd Fadhil Sulong***SACRAL TUBERCULOSIS: NEVER IGNORE BUTTOCK PAIN***Khairul Abdillah Mohamad, Hazwan Maznon, Lim Han Sim, Ahmad Sabri Omar***SCOLIOSIS OR TRUNK LISTING? A CASE REPORT***She Ann Lee, Weng Hong Chung, Chee Kidd Chiu, Chris Yin Wei Chan, Mun Keong Kwan***SIMPLE SOLUTION FOR A COMPLEX FRACTURE***Ng Yin Teng, Yeoh Ching Wooi, Logheswaren Suppiah, Khoh Phaik Shan, Zairul Anuar Kamarul Bahrin***SPINAL DURAL ARTERIOVENOUS FISTULA (AVF) CAUSING COMPLETE PARALYSIS OF LOWER LIMB: A RARE PRESENTATION OF COMPLETE TREATMENT OF TUBERCULOUS SPONDYLITIS WITH NEUROLOGICAL DEFICIT***Hazheem Syazwan Hussin, Dzulkarnain Amir, Muhammad Ariff Mohd Yunus, Fazir Mohamad***SPINAL EPIDURAL ABSCESS IN PATIENT WITH DIABETES MELLITUS TYPE 2***Kenneth Yap Wei Sheng***SPINAL EPIDURAL HEMATOMA DUE TO ANTICOAGULANT THERAPY IN A POSTOPERATIVE SPINE PATIENT WITH NEW ONSET OF PULMONARY EMBOLISM***Kerryn-Anne Shalini Shelton, Arunjit Singh Sandhu, Azizul Akram Salim, Joehaimey Johari, Mohd Imran Yusof***SPINAL TUBERCULOSIS WITH LOW ERYTHROCYTE SEDIMENTATION RATE (ESR): A CASE REPORT***Tan Weng Liang, Tie Teck Liang, Terence Michael Dass, Kong Yee Sean, Yogeshwarran Nadeson***SPINE CASE SERIES: OCCIPITOCERVICAL FIXATION***Mohd Fikri Razali, Mohd Shukry Mat Eil @ Ismail, Zakaria Yusoff, Lim Tze Chwen, Ahmad Sabri Omar*

**SPINE METASTASES? NO, IT IS SPINE TUBERCULOSIS***Mohd Fikri Razali, Mohd Shukry Mat Eil @ Ismail, Zakaria Yusoff, Lim Tze Chwen, Ahmad Sabri Omar***SPONDYLODISCITIS IN CHILDREN, A 3-YEAR CHRONOLOGICAL EVENT: A CASE REPORT***Normawathy Amir Osman, Ahmad Sabri Omar, Zairul Anuar Kamarul Bahrin***SPONDYLOPTOSIS OF L5/S1 IN A 12 YEAR-OLD CHILD: A CASE REPORT***Tan Yong Lin, Zulkefli Atan***SPONTANEOUS EPIDURAL HEMORRHAGE POST THROMBOLYTIC AGENT***Muhammad Najib Omar, Amrik Singh Ranjit Singh, Normawathy Amir Osman, Zairul Anuar Kamarul Bahrin***SURGICAL SITE INFECTION FOLLOWING LOW MOLECULAR WEIGHT HEPARIN TREATMENT FOR PULMONARY EMBOLISM POST SCOLIOSIS CORRECTIVE SURGERY***Ong Kean Loong, Ikhwan Abd Samad, Nor Azlin Zainal Abidin, Thuraikumar Kanniah, Amir Fariz Zakaria, Faizal Manan, Wang Chee Seiang***TANDEM THORACIC AND LUMBAR SPINAL STENOSIS IN A YOUNG PATIENT: A CASE REPORT***Normawathy Amir Osman, Zairul Anuar Kamarul Bahrin, Ahmad Sabri Omar***THORACIC BUTTERFLY VERTEBRA: A CASE REPORT***Selvan Danappal, Azizul Akram Salim, Joehaimey Johari, Mohd Imran Yusof***THORACIC MYELOPATHY IN THE YOUNG: A CASE REPORT***Yeoh Ching Wooi, Logeshwaran Suppiah, Ong Jin, Leong Jiahour, Zairul Anuar Kamarul Bahrin***THORACOGENIC SCOLIOSIS IN AN ADULT: A CASE REPORT***Normawathy Amir Osman, Zairul Anuar Kamarul Bahrin***TRANSFORAMINAL LUMBAR ENDOSCOPIC DISCECTOMY UNDER LOCAL ANAESTHESIA - HOSPITAL SULTAN ISMAIL EXPERIENCE***Aina Shamira Noor Hisham, Jayamalar Thuraijasingam, Colin Komahen Kamalanathan, Naveen Vijayasingham***TRANSVERSE LIGAMENT HYPERTROPHY OF ATLAS CAUSING CERVICAL MYELOPATHY - AN EXPERIENCE AT HOSPITAL TUANKU JAAFAR, SEREMBAN***Shyamala Sivapragasam, Norshaidi Salim, Abdul Rauf Haji Ahmad***TRAUMATIC CENTRAL CORD SYNDROME WITH CORD LACERATION WITH UNDERLYING CONGENITAL SPINE DEFORMITY: A CASE REPORT***Nasrul Hanif Mohamad, Muhammad Redza Ihsan Rosli, Amrik Singh Ranjit Singh, Normawathy Amir Osman***UNUSUAL MULTIPLE THORACOLUMBAR SPINE FRACTURES: A CASE REPORT***Ong Kean Loong, Mohd Luqman Mazlan, Nor Azlin Zainal Abidin, Thuraikumar Kanniah, Amir Fariz Zakaria, Mohamed Faizal Abdul Manan, Wang Chee Seiang***USAGE OF CT CONTRAST STUDY IN EXTREMELY RARE COMPLICATION OF KNOTTING EPIDURAL CATHETER WITH SUCCESSFUL SURGICAL EXTRACTION - A CASE REPORT***Mohd Hafiz Syazwan, Jamaluddin Shafei, Muhammad Fadhil Mat Salleh***VERTEBRAL OSTEOMYELITIS, A COMPLICATION OF INFECTED EVAR***Mohd Hamdan Mohd Ibrahim, Naadira Faaiza Mazlan, Nur Syahirah Azmi***WHITE CORD SYNDROME: A DISASTER TO KEEP IN MIND***Mohd Rifhan Syahmi Mohd Rusdi, Mohamad Zaki Mohd Amin, Nur Aida Faruk Senan*

## Sports

**A BLIZZARD IN THE KNEE - GOUT CLOUDS THE WAY TO THE OPERATING TABLE***Vikneswaran Govindasamy, Angelyn Wong CC, Kugan Ramachandran, Putra Vatakal, Basir Towil***A CASE OF SUPERIOR CAPSULAR RECONSTRUCTION WITH PECTORALIS MAJOR AND LATISSIMUS DORSI TRANSFER IN PATIENT WITH MASSIVE IRREPARABLE ROTATOR CUFF TEARS***Loo Wen Chern, Che Wan Mohd Shaiful Nizam Che Wan Nik, Siva Thangaraju, Siti Hawa Tahir, Faris Indra Prahasta Didi Indra***A CATASTROPHIC COMPLICATION DURING ARTHROSCOPIC KNEE SURGERY***Prema Sivalingarajah, Shanmugapragash Guraiah, Siti Hawa Tahir, Maizatul Jamny Mahmood***ACJ LOCKDOWN: A NEW DAWN FOR CHRONIC ACJ***Hemraj Kunasekaran, Shukur Ahmad, Yeoh Kian Hua, Chooi Yuo Joe, Mohd Yusof Mahidin, Mohd Sharifudin Said***ACUTE LOCKED KNEE: A ONE-YEAR DEMOGRAPHIC STUDY IN HOSPITAL SELAYANG***Muhammad Luqman Abu Bakar, Muhammad Yasir Ahmad Muslim, Abdul Razak Hussin, Mohd Azrin Shahul Hamid, Satriya Sabir Husin Athar***ACUTE SPONTANEOUS NONTRAUMATIC RUPTURE OF ISOLATED LONG HEAD BICEPS TENDON***Khaw Yam Chuan, Sahran Yahaya, Nor Azman Mat Zin, Wan Faisham Wan Ismail***ADOLESCENT ANTERIOR CRUCIATE LIGAMENT RECONSTRUCTION OF THE KNEE – PROBLEMS / MATTERS WITH THE PHYSEAL PLATE***Mohd Fairudz Mohd Miswan, Muhammad Farhan Izani, Alan Basil Peter, Abdul Razak Hussin***A HOP THAT POP: A CASE OF ACUTE ACHILLES TENDON RUPTURE FOLLOWING SINGLE LEG HOP TEST***Muhammad Nizamuddin Ghazali, Moriffin Mahpis, Abdul Razak Hussin, Thevarayan Somasundaran, Syamsul Rizal Abu Amin, Gurmeet Sing Gurdial Singh***AN UNUSUAL CAUSE OF RECURRENT SHOULDER DISLOCATION***Lim Soo May, Rosalind Wong Huey Yin, Gerry Maxmillan Houjen Pang***A RARE CASE OF ISOLATED LESSER TUBEROSITY FRACTURE OF HUMERUS: A CASE REPORT***Irwan Mohamad Ali, Che Wan Shaiful Nizam Che Wan Nik, Lim Ming Yong, Yap Jun Lin***ARTHROSCOPIC ANCHOR SUTURE FIXATION FOR ISOLATED GREATER TUBEROSITY DISPLACED FRACTURE OF HUMERUS***Abdul Hakim Mohd Hamsari, Abdul Razak Hussin, Satriya Sabir Husin Athar***ARTHROSCOPIC DECOMPRESSION OF SPINOGLEROID CYST WITH SUPRASCAPULAR NERVE ENTRAPMENT***Choo Chin Yin, Sobir Aidit, Sanusi Azni Ab Ghani***BILATERAL QUADRICEPS TENDON RUPTURE IN ESRF PATIENT***Nurhanani Abu Bakar, Mohamad Razip Sirat***BIPLANAR CORRECTIVE OSTEOTOMY IN MALUNION SUPRACONDYLAR FEMUR WITH MULTILIGAMENT INJURY***Nurhanani Abu Bakar, Mohamad Razip Sirat***CASE REPORT: DO WE APPROPRIATELY MANAGE HOFFA FRACTURE?***Mohd Azwan Ab Aziz, Tengku Muzaffar Tengku Shihabudin***CHALLENGES IN MEDIAL PATELLOFEMORAL LIGAMENT RECONSTRUCTION OF MEDIAL BIPARTITE PATELLA IN ADOLESCENT***Mohd Fairudz Mohd Miswan, Mohamed Faizal Sikkandar, Mohd Yusoff Yahaya, Mohd Shukry Mohd Khalid***COMBINED ANTERIOR CRUCIATE LIGAMENT RECONSTRUCTION WITH HIGH TIBIAL OSTEOTOMY USING PATIENT SPECIFIC INSTRUMENTATION***Tan Yin Ying, Teo Seow Hui*

**COMPREHENSIVE ARTHROSCOPIC MANAGEMENT (CAM) PROCEDURE: A JOINT PRESERVING APPROACH FOR A YOUNG ACTIVE PATIENT WITH ADVANCED GLENOHUMERAL ARTHRITIS***Fauziana Abd Jabar, Szali Salleh***DISTAL BICEPS TENDON RUPTURE: A CASE REPORT***Lim Chia Hua, Prema Sivalingarajah, Muhammad Hafiz Daud, Choo Chin Yin, Siva Thangaraju, Che Wan Mohd Shaiful Nizam Che Wan Nik, Siti Hawa Tahir***FAILED REGENERATION OF THE SEMITENDINOSUS TENDON HARVESTED FOR ACL RECONSTRUCTION: A RARE COMPLICATION***Aravind Kumar Murugan, Ruben Jaya Kumar, Abu Ubaidah Amir Norazmi, Raymond Yeak Dieu Kiat, Mohd Zaidi Saleh, Malini Karupaiah, Harrison Danapala***HIGH BMI CAUSING NON-TRAUMATIC PATELLA CHONDRAL LESION***Puravi Ganesh Shanmugam, Mus'ab Norhamidi, Muhammad Dzulkhusni Mohd Dzulkifri, Tan Chen Wee***INNOVATION IN THE FACE OF LIMITATION –A LOCKDOWN STORY (MODIFIED ACJ SLING PROCEDURE 2.0)***Amy Wong Yoke Foong, Leong Wan Hee***LATARJET PROCEDURE FOR SHOULDER INSTABILITY IN ELDERLY***Syed Azhariff Syed Yahya, Badrul Akmal Hisham Md. Yusoff, Ahmad Farihan Mohd. Don, Muhammad Ilyas Muhammed Ali Noor***LATERAL FEMORAL CONDYLE OSTEOCHONDRAL FRACTURE FIXATION WITH BIODEGRADABLE SCREWS AND PINS – A CASE REPORT***Syed Nashraf Shah, Tengku Muzaffar Tengku Mohd Shihabudin, Nor Hamdan Fakhru***LOCALIZED TENOSYNOVIAL GIANT CELL TUMOUR OF THE KNEE, AN INCIDENTAL FINDING FROM DIAGNOSTIC ARTHROSCOPY***Srijan Madusoodanan, Abdul Razak Hussin, Muhammad Nizamuddin Ghazali***MEDIAL TIBIAL STRESS SYNDROME AND TIBIAL DIAPHYSEAL STRESS FRACTURE***Mohd Nazri Nor, Muhammad Ariff Zakaria, Nurul Hidayah Abdullah***OPEN CHONDROPLASTY AND AUTOLOGOUS MATRIX INDUCED CHONDROGENESIS (AMIC) FOR KNEE CHONDRAL INJURY***Muhamad Amir Azfar Sahadun, Tengku Muzaffar Tengku Mohd Shihabudin***OUTCOMES OF MULTILIGAMENT RECONSTRUCTION IN HOSPITAL MUAR USING THE ORIGINAL LARSON TECHNIQUE***Muhammad Syukri Ab Hamid, Nurhanani Abu Bakar, Nur Akmal Ismail Mansor, Mohamad Razip Sirat***POSTERIOR SHOULDER DISLOCATION WITH REVERSE HILL-SACHS LESION : A CASE REPORT***Selvan Danappal, Nor Hamdan Fakhru, Tengku Muzaffar Tengku Md. Shihabudin***PROVOKED PULMONARY EMBOLISM POST ARTHROSCOPIC MENISCUS REPAIR: A CASE REPORT***Layveeniea Ananthan, Prema Sivalingarajah***PULMONARY EMBOLISM POST SHOULDER ARTHROSCOPY – A POTENTIAL SILENT KILLER***Ganesha Devan Kanagarajah, Tengku Muzaffar Tengku Mohamed Shihabudin, Nor Hamdan Fakhru, Mohd Nizlan Mohd Nasir***PULSED RADIOFREQUENCY TREATMENT OF SCAR NEUROMA IN THE SHOULDER – A CASE REPORT***Lim Zhuang Li, Nur Faridah Zulkhaini, Au Yong Pui San, Gandhi Nathan Solayar, Rozaiman Ebrahim***RECONSTRUCTION OF CHRONIC PATELLAR TENDON RUPTURE WITH HAMSTRING AUTOGRAFT IN A PATIENT WITH END STAGE RENAL DISEASE AND TERTIARY HYPERPARATHYROIDISM: A CASE REPORT***Chia Vwrene, Lim Ming Yong, Che Wan Mohd Shaiful Nizam Che Wan Nik, Siva Thangaraju, Siti Hawa Tahir***RELATIVE EFFICACY OF INJECTIONS FOR FUNCTIONAL IMPROVEMENT IN OVERUSE INJURIES: A SYSTEMATIC REVIEW AND NETWORK META-ANALYSIS***Siew Li Goh, Zulkarnain Jaafar, Gan Yan Nee, Alston Choong, Jaspreet Kaur, Burak Kundakci, Samihah Abdul Karim, Muhammad Rahmani Jaafar, Mohamad Shariff A Hamid*



**REVISION SURGERY IN CHRONIC ACROMIOCLAVICULAR JOINT INJURY***Muhamad Amir Azfar Sahadun, Norlizam Mohd Nor***SAFETY, TOLERABILITY AND PRELIMINARY OUTCOME OF PERCUTANEOUSLY INJECTED CHONDROGEN™, A PROPRIETARY CULTURE-EXPANDED WHARTON'S JELLY DERIVED-MESENCHYMAL STEM CELLS IN PATIENTS WITH KNEE OSTEOARTHRITIS***Felix Lau Huey Yih, Badrul Akmal Hisham Md. Yusoff, Ahmad Farihan Mohd Don, Norlelawati Mohamad***SUTURE TAPE WITH KNOTLESS ANCHOR: OVERCOMING THE DILEMMA OF TRADITIONAL METHOD IN QUADRICEPS TENDON REPAIR***Maria Mardi, Mohd Yusoff Yahaya, Satriya Sabir Husin Athar***SYNOVITIS POST ACL RECONSTRUCTION WITH NEOLIGAMENTS SYNTHETIC GRAFT IN 17 YEARS OLD BOY***Kong Ing Hui, Leong Wan Hee***TENOSYNOVIAL GIANT CELL TUMOUR OF THE INFRAPATELLAR FAT PAD MIMICKING AN INTRA-ARTICULAR LOOSE BODY – A CASE REPORT***Lim Zhuang Li, Szali Salleh, Munira Masri, Arfahiza Selimin***THE OUTCOME OF BALANCE EXERCISES AND AGILITY TRAINING FOR POST ANTERIOR CRUCIATE LIGAMENT (ACL) RECONSTRUCTION: CLINICAL ASSESSMENT***Siti Maizatul Akmal Ismail, Saw Aik, Mohamed Razif Mohamed Ali, Mohamad Shariff A. Hamid, Nor Faissal Yasin, Hishamudin Mastar @ Masdar, Sidik Che Kob, Mohd Azrin Shahul Hamid, Mohd Ikraam Ibrahim, Ferdhany Muhamad Effendi, Mohd Fairudz Mohd Miswan, Mohd Fairuz Suhaimi, Anuar Suun***THE RAMPAGE OF GIANT ONE-EYE CREATURE - A RARE PRESENTATION OF INVERTED CYCLOP LESION POST ANTERIOR CRUCIATE LIGAMENT RECONSTRUCTION***Mohd Saperi Zool Kipele, Badrul Akmal Hisham Mohd Yusoff, Ahmad Farihan Mohd. Don***Trauma****A BIOMECHANICAL COMPARTIVE STUDY OF THE EXTERNALIZED LOCKING PLATE***Shaun De Silva, Rizal Abdul Rani, Azlan Mohd Sofian, Wan Kwong Lee, Norhamdan Mohd Yahaya***A CASE OF CONCOMITANT FAT EMBOLISM SYNDROME AND PULMONARY EMBOLISM IN AN ORTHOPAEDIC TRAUMA PATIENT***Wong Jia Yen, Adriel Tiw Wei Jie, Ngo Pei Ern, Navindravadhanam Sockalingam***A CASE OF MIDSHAFT HUMERUS FRACTURE WITH MEDIAN NERVE PALSYP***Kathleen Teo Khai Ling, Felix Lau Huey Yih, Kamarul Al-Haqq Abdul Ghani, Jeffrey Chong Wei Jie, Cheong Yuen Zhi***A CASE REPORT: JOINT SPARING DELTA EXTERNAL FIXATOR WITH TRANS-CONDYLAR SCHANTZ PIN IN SEVERE COMMUNUTED OPEN FRACTURE HUMERUS***Tan Kah Sui, Yeoh Kian Hua, Shukur Ahmad, Mohd Sharifudin Said***A CASE REPORT OF COMBINATION OF PERCUTANEOUS AND INTRAMEDULLARY CANNULATED SCREW FIXATION FOR ANTERIOR AND POSTERIOR PELVIC RING FRACTURE***Chan Zhi Yung, Norsaidatul Nadriah Ahmad Shuhiamy, Kamarul Al Haqq Abdul Ghani, Satriya Sabir Husin Athar***A CASE REPORT -PATHOLOGICAL FRACTURE IN USAGE OF SGLT2 INHIBITOR***Kathiravan Murugan, Yeoh Kian Hua, Shukur Ahmad, Mohd Sharifudin Said***A COMPLEX HIP INJURY WITH BUTTONHOLE EFFECT - A CHALLENGING REDUCTION DILEMMA***Jason Ling Yew Hung, Nurul Aishah Mohamed Zain, Lee Kent Hui, Hishamuddin Salam***A COMPLEX SUBTROCHANTERIC FEMUR FRACTURE – BACK TO DRAWING BOARD***Kavivarma Raj Rajendran, Sa'adon Ibrahim, Naveen Vijayasingam*

**ACUTE COMPARTMENT SYNDROME IN SOFT TISSUE INJURY***Muhammad Shazwan Shahron, Nazri Mohd Nor***ACUTE COMPARTMENT SYNDROME OF LEG SECONDARY TO SOLEUS MUSCLE TEARS IN A LONG JUMP ATHLETE***Norliyana Mazli, Zulkifli Hassan, Ibrahim Ahmad Fuad***ACUTE OSTEOMYELITIS IN A CLOSED INTERTROCHANTERIC FEMUR FRACTURE***Teng Hong Ling, Aw Wai Onn***ADVANTAGE OF PERCUTANEOUS SCREW FIX IN BILATERAL VERTICAL SHEAR: RARE INJURY PATTERN***Muhammad Farhan Md Yusoff, Kamarul Al Haqq Abdul Ghani, Kamarul Arifin Abdul Razak, Muhammad Fadhil Mat Salleh, Mohamad Hafiz Mohamad Zaini, Mohd Fadhil Sulong***AN UNUSUAL CASE OF MOREL-LAVALLÉE LESION OF THE UPPER LIMB***Danial Fa-iz Ibrahim, Ahmad Zubair Anis Ahmad***AN UNUSUAL CASE OF SEGMENTAL CLAVICLE FRACTURE: CASE REPORT***Roshyn Singh Khosa Herjit Singh, Liong Meng Foong, Mohd Firdouse Mohd Zulyadaen, Felix Loong Yew Seng***A PECULIAR CASE OF CENTIPEDE ENVENOMATION CAUSING NEUROLOGICAL DEFICITS: A CASE REPORT***Muhammad Najmi Ab Ghani, Collin Looi Seng Kim***A RARE CASE OF GALEAZZI FRACTURE WITH IPSILATERAL ELBOW DISLOCATION***Wan Afif Hafizi Wan Marzuki, Nurhanani Abu Bakar***A RARE CASE OF RAPID ONSET PULMONARY EMBOLISM POST FEMUR FRACTURE***Teh Ban Heng, Muhammad Dzulhusni Mohd Dzulkifri, Norisyam Yusoff***A RARE CASE PRESENTATION: SIMPLE PUNCTURE WOUND CAUSING UPPER LIMB, CHEST AND NECK EMPHYSEMA***Sharifah Nor Tasnim Alsagoff, Mohd Yusoff Yahya, Satriya Sabir Husin Athar***A RARE CASE REPORT OF TRAUMATIC COMPLETE ACUTE ANTERIOR KNEE DISLOCATION***Magdalen Anthony, Phung Sy Tsong, Esanikarupiah Jagathisen***A RARE LUXATIO ERECTA HUMERI INJURY IN AN ELDERLY: A CASE REPORT***Muhammad Nizamuddin Ghazali, Nik Ahmad Fauzan Nik Wan, Mohd Asrul Che Rahim, Noor Shafika Abd Hamid, Mohd Hafizi Mohd Yusof***A RARE OCCURRENCE: MOREL LAVALLEE LESSION OF KNEE JOINT***Mohamad Hafiz Mohamad Zaini, Muhammad Hilmi Nasir, Khalid Isa, Zamir Hilmi Hamzah, Yang Sofia Ab Rahim, Nur Hafizah Mat Noor***A RARE CASE PRESENTATION OF PLATE BREAKAGE IN DISTAL RADIUS FIXATION POST CORRECTIVE OSTEOTOMY FOR MALUNION***Muhammad Nur Atiq Saharudin, Muhammad Nazirul Mubin Khalid, Muhamad Nurasnol Khamis, Mustaqim Afifi@ Apipi, Sazli Mohd Nor***ARTERI-VEINOS MALFORMATION OF THE HAND, IS LOSING A FINGER AN OPTION?***Mohd Airyshermil Farhan, Mohammad Zufar Shahren, Danial Fa-iz Ibrahim, Nurhanani Abu Bakar***A SILENT BREAK: STRESS NECK OF FEMUR FRACTURE***Sharifah Nor Tasnim Alsagoff, Woo Huey Mey, Shahrul Hisham Sulaiman, Satriya Sabir Husin Athar***A TOOTHY INJURY***Mohd Nazri Noh, Saveen Singh Pasricha, Adibah Samat***ATYPICAL FRACTURE SECONDARY TO PROLONGED BISPHOSPHONATE THERAPY***Kenneth Yap Wei Sheng***ATYPICAL PRESENTATION OF MOREL-LAVALLÉE LESION OF THE MEDIAL SIDE OF THIGH: A CASE REPORT***Lim Kgai Ter, Dinesh Earnest Kunasingh*

**BAIL OUT SURGERY FOR DISTAL FEMUR FRACTURE - A CASE REPORT***Mohd Luqman Mazlan, Azlan Mohd Sofian, Wan Faisham Wan Ismail***BILATERAL QUADRICEPS TENDON RUPTURE IN END STAGE RENAL FAILURE PATIENT***Zuhaili Zahari, Kuhaendra Jeyasingam, Nor Hamdan Fakhru, Tengku Muzaffar Tengku Mohd Shihabudin***BILATERAL TRAUMATIC SCAPHOID FRACTURES: DIVERGENT APPROACH, CONGRUENT RESULT***Jeffrey Chong Wei Jie, Kathleen Teo Khai Ling, Tiew Siew Kern, Kamil Mohd Kassim***B-M INTERVAL APPROACH – CORONOID PROCESS FRACTURE FIXATION***Muhamad Azwan Muhamad Fauzi***BONE SANDWICH TECHNIQUE IN CLOSED HUMERAL PERIPROSTHETIC FRACTURE***Jeffrey Chong Wei Jie, Kathleen Teo Khai Ling, Tiew Siew Kern, Kamil Mohd Kassim***BRACHIORADIALIS MUSCLE FLAP FOR POSTERIOR ELBOW DEFECT: A VIABLE OPTION IN A DISTRICT HOSPITAL SETTING***Tan Shihui, Leon Hui Ming, Shukur Ahmad, Mohd Sharifudin Said***BUDDY SPLINT IS “BUDDY” YET NOT SO FRIENDLY: A CASE REPORT***Leong Jiahour, Nanchappan Selvanathan, Yeoh Ching Wooi, Ng Yin Teng, Yeoh Movinraaj***CASE OF POST TRAUMATIC PATELLA OSTEONECROSIS***Cheong Yuen Zhi, Kathleen Teo Khai Ling, Phung Sy Tsong***CASE REPORT - ARE YOU HOOKED? SIMPLE TECHNIQUE EXTRACTING BROKEN DISTAL INTRAMEDULLARY NAIL***Yap Wei Keing, Mohd Hudzairy Ahmad***CASE SERIES OF DISTRICT EXPERIENCE IN MANAGEMENT OF PIPKIN TYPE IV HIP FRACTURE***Mohd Shaharil Abdul Aziz, Farhan Haripapbilah***CHALLENGES IN EMPOWERMENT OF POST-MENOPAUSAL WOMEN IN PREVENTING FRAGILITY FRACTURES. A MALAYSIAN PERSPECTIVE***Mohd Ariff Sharifudin, Mai Nurul Ashikin Taib, Nik Noor Kaussar Nik Mohd Hatta, Nur Azree Ferdous Kamudin, Nordin Simbak***CHALLENGES IN SUBTROCHANTERIC FEMUR FRACTURE MANAGEMENT: A CASE REPORT OF INAPPROPRIATE IMPLANT CHOICE LEADING TO FIXATION FAILURE AND UPDATE ON MANAGEMENT OPTIONS***Ling Lee Siang, Seo Soon Teck, Sivapathasunduram C. Nadarajah***COMMON PERONEAL NERVE INJURY SECONDARY TO AVULSION FRACTURE HEAD OF FIBULA: A TROUBLESOME FOOT FROP***Mohamed Khaliq Isa, Mohd Norkhairul Hasfanizam Ibrahim, Mohamad Hafiz Mohamad Zaini***COMMUNITED FRACTURE DISTAL HUMERUS IN ADOLESCENCE DILEMMA***Abdullah Aqeel Musa, Kamarulzaman Hj MS kadir***COMPLEX SACRAL FRACTURE WITH DELAY CAUDA EQUINA SYNDROME***Mohamad Faris Md Ariff, Nurul Wahida Mohamad Zaki, Mohd Shukry Mat Eil, Zakaria Yusof***CONCOMITANT FAT EMBOLISM SYNDROME AND PULMONARY EMBOLISM IN IPSILATERAL FRACTURES OF THE FEMORAL AND TIBIAL DIAPHYSES: A CASE REPORT***Fatin Farhana Manas, Mohd Reza Mohd Aridz***CRUSH TMT FRACTURE DISLOCATION: A SINGLE STAGE EXTERNAL FIXATION TECHNIQUE***Thurini Venugopal, Shukur Ahmad, Yeoh Kian Hua, Mohd Yusof Mahidin, Chooi Yuo Joe, Mohd Sharifudin Said***“DECEIVING X-RAY” - A CASE OF CERVICAL FRACTURE DISLOCATION IN NORMAL CERVICAL X-RAY***Muhammad Hazim Mohd Azhar, Mohd Norfahmi Md Hashim***DISTAL MEDIAL FEMUR CONDYLE FRACTURE FIXED WITH SPECIAL CONTOUR PLATE OF TIBIA: A CASE REPORT***Lim Kgai Ter, Dinesh Earnest Kunasingh, Wan Yuhana Wan Md Yusof*

**DODGING THE BULLET WITH THE GANZ TROCHANTERIC OSTEOTOMY: A CASE REPORT**

*Sree Raja Lakshmy Chandra Sekaran, Low Chin Aun, Muhammad Azrin Mohd Asihin, Darshan Krishnan, Shangeetha Tharmalingam, Razin Shah John Mohd, Nur Rahimah Abdul Rahim, Velman Jaya Shri*

**DOES SIZE ACTUALLY MATTER? MOUNTING A LARGE LIMB**

*Thurini Venugopal, Shukur Ahmad, Yeoh Kian Hua, Mohd Yusof Mahidin, Chooi Yuo Joe, Mohd Sharifudin Said*

**DOUBLE TROUBLE IN A FLOATING KNEE: CONCOMITANT PULMONARY EMBOLISM AND FAT EMBOLISM SYNDROME**

*Nur Syahirah Azmi, Ruben Jaya Kumar, Mohd Hamdan Mohd Ibrahim, Naadira Faa'iza Mazlan, Ayuni Khirul Ashar*

**DROWNING IN BLOOD -RARE MANIFESTATION OF FAT EMBOLISM SYNDROME WITH DIFFUSE ALVEOLAR HAEMORRHAGE**

*Mohd Saperi Zool Kipele, Muhammad Kamal Mohd Abdul Jalil, Ahmad Fazly Abd Rasid*

**EMERGING OF NECROTIZING FASCIITIS AS A DEADLY INFECTION IN MALAYSIA**

*Chan Zhi Yung, Richford Anak Jonathan, Danial Faris Hilmi, Satriya Sabir Husin Athar*

**EXTENDED BURKS & SCHAFFER APPROACH FOR POSTEREMEDIAL TIBIAL PLATEAU FRACTURE FIXATION**

*Muhamad Azwan Muhamad Fauzi*

**EXTENSIVE NECROTIZING FASCIITIS – CASE REPORT**

*Anas Yahya, Kashfullah Khalid, Sharil Abdul Rahim*

**EXTRACTION OF INCARCERATED KUNTSCHER NAIL**

*Nadzirah Hairul Anwar, Mohd Fauzlie Yusof*

**FAT EMBOLISM AND THROMBOEMBOLISM: ICEBERG PHENOMENON IN LONG BONE FRACTURES?**

*Muhamad Nazrin Mustafa*

**FEMORAL INTERLOCKING NAIL - AN APPROACH IN OBESITY**

*Thaneshwara Rao Appannan, Shukur Ahmad, Yeoh Kian Hua, Mohd Yusof Mahidin, Chooi Yuo Joe, Mohd Sharifuddin Said*

**FIXATION OF PATHOLOGICAL FRACTURE NECK AND TROCHANTERIC FEMUR WITH INNOVATIVE METHOD: A CASE REPORT**

*Leong Jie Xiang, Ooi Tek Zwee, Asrul Fahmi Azizan, Syed Addi Usmi Syed Othman*

**FIXING AN UNCOMMON COMPLICATION OF A COMMON PROCEDURE: INTRAPELVIC GUIDEWIRE MIGRATION IN FEMORAL NECK OSTEOSYNTHESIS**

*Nicholas Aw Shao Jiun, Noradila Ishak, Mohd Firdaus Hafni Ahmad, Zulkiflee Osman*

**FIXING NECK OF FEMUR FRACTURE IN PATIENT WITH TOTAL KNEE REPLACEMENT AND DISTAL FEMORAL LOCKING PLATE**

*Lee Zhi Cheong, Chuah Jia Peng, Lutfi Rashid, Yohan Khirusman, C. Sankara Kumar Chandrasekaran*

**FORGET THE MISTAKE, REMEMBER THE LESSON -CEMENT AUGMENTATION IN PROXIMAL FEMORAL NAIL**

*Abdul Hadi Mohd Zahari, Mohammed Harris Anwar Ali Khan, Jasvinder Singh Jagindar Singh, Ahmad Munir Hasnim*

**FORGOTTEN TECHNIQUE FOR ANGULATED TIBIA SHAFT FRACTURE IN DISTRICT HOSPITAL – A CASE REPORT**

*Dinesh Murugaiah, Muhammad Nabil Mohamaddin, Yagin Rao Maraiah, Yuwaraja Vijayakumar*

**GASTROCNEMIUS MUSCLE FLAP FOR MIDDLE THIRD LEG DEFECTS: A DISTRICT HOSPITAL EXPERIENCE**

*Wong Kin Chun, Zafirnur Amrin Jasman, Muhammad Nazrinradzuan, Mohd Naim Mohd Nasir, Adam Abdul Razak*

**HEAD IN THE BUTT! A RARE HIP INJURY**

*Sundaresan Soundararajan, Ling Jian Loong*

**IATROGENIC PSEUDOANEURYSM OF LATERAL FEMORAL CIRCUMFLEX ARTERY FOLLOWING ANTEGRADE INTRAMEDULLARY FEMUR NAILING: A CASE REPORT**

*Nur Ayuni Khirul Ashar, Imma Isniza Ismail, Naadira Faa'iza Mazlan, Nur Syahirah Azmi, Rahul Lingam*

**ILIZAROV BONE TRANSPORT AND TREATMENT OF INFECTED CRITICAL-SIZED TIBIAL BONE DEFECT: A CASE REPORT**

*Kee Hoe Teong, Kamarul Izham Kamarudin, Mohd Saifullah Alhany Abdul Halim, S.L Vijaya Kumar Suppan*

**INTRAMEDULLARY NAIL OF HUMERUS: AN EXCELLENT OPTION FOR HUMERUS SHAFT FRACTURE***Mohd Shaharil Abdul Aziz, Farhan Haripapbilah***IPSI LATERAL FEMORAL NECK AND SHAFT FRACTURE; A CASE SERIES OF 3 PATIENTS***Muhammad Najmi Ab Ghani, Johan Abdul Kahar***IPSI LATERAL FEMUR SHAFT FRACTURE IN PRIMARY TRAUMATIC PATELLA DISLOCATION WITHOUT LIGAMENT INJURY: CASE REPORT***Shashindran Nair Kumaran, Lynn Azura, Felix Loong Yew Seng***IPSI LATERAL MIDCLAVICULAR FRACTURE WITH ACROMIOCLAVICULAR JOINT DISRUPTION***George Ezekiel, Rohaman Tasarib***ISOLATED CEREBRAL FAT EMBOLISM SYNDROME POST BICONDYLAR PLATING HUMERUS – A CASE REPORT***Mohamad Hazwan Zulkifli, Mohammed Harris Anwarali Khan, Jasvinder Singh Jagindar Singh***ISOLATED PURE MOTOR MONOPARESIS FOLLOWING CEREBRAL INFARCTION MIMICKING A SPINAL LESION: A CASE REPORT***Nur Ayuni Khirul Ashar, Ruben Jaya Kumar, David See Zhi Huang, Naadira Faa'iza Mazlan, Nur Syahirah Azmi, Rahul Lingam***KNEEDING HELP: A CASE OF PATELLA KNEE AVULSION IN A YOUNG RENAL FAILURE PATIENT***Mohd Zoran Arif Mat Husin, Adzhar Abdul Latib, Mohd Zharif Norasikin, Norlizam Mohd Nor, Amnie Thum Qiu Chin, Mohd Arif Hj Salleh, Muhammad Hazim Mohd Azhar***LESS IS BEST': PERCUTANEOUS SCREW FIXATION OF BILATERAL TRANSVERSE ACETABULAR FRACTURE WITH CONCOMITANT KNEE DISLOCATION***Kamarul Arifin Abdul Razak, Kamarul Al-Haqq Abdul Ghani, Jeffrey Chong Wei Jie, Magdalene Anthony***LUXATIO ERECTA FEMORIS-A RARE INJURY REQUIRING OPEN REDUCTION***Chew Jun Jie, Wagner Loo Cheng Poh, Saadon Ibrahim***MEDIAL CORONAL SHEAR FRACTURE OF THE DISTAL HUMERUS: A CASE REPORT***Timothy Cheng, Mohd Rusdi Draman @ Yusof, Simmrat Singh Jagdish Singh***MID-SHAFT HUMERAL FRACTURE IN OBESE PATIENT: MIPO IS AN OPTION***Ambiggan Supaya, Indrarajah Asokumaran, Kularaj Subramaniam, Syed Addi Usmi Syed Othman***MINIMAL-DISPLACED POSTERIOR ACETABULUM WALL FRACTURE – A CASE REPORT***Dinesh Murugaiah, Muhammad Nabil Mohamaddin, Sudhagar Krishinan***MINIMALLY INVASIVE PLATE OSTEOSYNTHESIS IN HAEMOPHILIA PATIENT : A FIRST IN BORNEO***Faris Indra Prahasta Didi Indra, Nazari Ahmad Tarmuzi, Paul Tan Bong King, Fathin Azizah Mohd Basri***MINIMALLY INVASIVE STABILISATION SURGERY OF UNSTABLE PELVIC RING FRACTURES***Mohd Daniel Djamalludin, Simmrat Singh Jagdis Singh***MINIMALLY INVASIVE SURGERY IN ATYPICAL FRACTURE CONFIGURATION WITH DOUBLE SEGMENTAL FRACTURE OF TIBIA***Ng Lim Hong, Ridhayah Aziha Rosli, Wan Muhamad Amir Abdul Halim, Aida Nurani Sobri, Teo Yu Meng***MINIMIZING A MAJOR PROBLEM; CASE SERIES OF INFECTED MOREL - LAVALLEE LESION***Mohd Saperi Zool Kipele, Azlan Mohd Sofian***MOREL-LAVALLÉE LESION FOLLOWING A LOW ENERGY TRAUMA: A CASE REPORT & LITERATURE REVIEW***Wong Ba Huang, Divenno Anak Jamel, Jasper Lim Tim Chung, Muhammad Shukri Muhammad Safian***MOREL-LAVALLÉE-MISSED AND NEGLECTED LESION***Chan Zhi Yung, Prevheenraj Naidu Thevaraj, Richford Anak Jonathan, Satriya Sabir Husin Athar, Salmi Abdullah, Intan Nurjannah Darwin*

**NECROTISING SOFT TISSUE INFECTION FOLLOWING OPEN FRACTURE RADIUS AND ULNA WITH COMPARTMENT SYNDROME IN A CHILD**

*Ahmad Afiq Fadhli Ramli, Nik Muhammad Shahid Nik Jaffar, Nurul Akma Azmi, Mohammad Faizal Nikman Lee, Atikah Amirah @ Suzanna Abdullah*

**NICE KNOT – USAGE AS REDUCTION TOOL IN CLAVICULAR PLATING**

*Eo Chun Keat, Tharumaraja Thiruselvam*

**NOVEL CONCEPT OF DUAL STAKED PLATING IN SEGMENTAL RADIUS FRACTURE: A CASE REPORT**

*Lee Zhi Cheong, Chuah Jia Peng, Lutfi Rashid, Yohan Khirusman, C. Sankara Kumar Chandrasekaran*

**OBTURATOR DISLOCATION: THERE GOES MY FEMUR HEAD**

*Sassidharen Ponnalagu, Indrarajah Asokumaran, Kularaj Subramaniam, Syed Addi Usmi Syed Othman*

**ONE LIMBED YOUTH: TRAUMATIC HIP DISLOCATION WITH EXTERNAL ILIAC ARTERY THROMBOSIS**

*Nurul Zulaikah Ahmad Arzaai, Mohd Reza Mohd Aridz*

**OPEN BIMALLEOLAR FRACTURE WITH LATERAL MALLEOLUS FRAGMENT BUTTONHOLING TENDON ARCHILLES**

*Muhammad Syafiq Hamidan, Hariharan Kumarasamy, Mohammad Anwar Hau Abdullah*

**OPEN PELVIC INJURY ASSOCIATED WITH SACRAL FRACTURE (TYPE 2) CONCOMITANT OPEN FRACTURE TIBIA/FIBULA: A RARE ENTITY**

*Hazizul Helmy Hamad@Ahmad, Muhammad Munawwir Mohd Hassan, Mohamad Arif Ahmad Dzahiri, Mohd Azahari Ibrahim*

**OPEN REDUCTION AND INTERNAL FIXATION OF NECK OF TALUS: A CASE REPORT**

*Sassidharen Ponnalagu, Indrarajah Asokumaran, Kularaj Subramaniam, Syed Addi Usmi Syed Othman*

**OPEN SEGMENTAL FRACTURE RADIUS (4 PARTS) WITH IPSILATERAL MIDSHAFT ULNA FRACTURE IN ADULT – A RARE CASE REPORT**

*Muhammad Zaidulhair Mohd Reduan, Najib Omar, Eo Chun Keat, Tharumaraja Thiruselvam*

**OVERCOMING SEVERE BOWING OF FEMUR IN ATYPICAL FEMUR FRACTURE. SURGICAL TECHNIQUE; TIPS AND PEARLS**

*Asrul Syamin Hisyam Yong, Thiru Karthikeyan Ramu, Muhammad Fathi Hayyun, Norliyan Mazli, Mohd Yazid Bajuri*

**PELVIC FRACTURE TILE C2 BY CROCODILE ATTACK: DEVASTATING CASE IN LAHAD DATU**

*Jeeva Sivashanumugam, Goh Teik Chiang, Lai Min Chung, Dinesh Rajendran, Hesootheran Govindarajan*

**PELVIC RING INJURY IN DISGUISE: A RARE CASE OF BILATERAL TRANSVERSE ACETABULAR FRACTURES**

*Ku Seng Koon, Mohd Fauzlie Yusoff, Mohd Karim Mohd Isa*

**PELVIC RING OR ACETABULAR FRACTURE WITH IPSILATERAL LOWER LIMB FRACTURE: THE SEREMBAN EXPERIENCE**

*Anis Anwar Zahari, Mohamad Hafiz Mohamad Hassim, Norhaslinda Bahaudin, Abdul Rauf Ahmad*

**PERCUTANEOUS K-WIRE OF ISOLATED RADIAL HEAD FRACTURE IN MASON TYPE II IN ADULT: AN ALTERNATIVE METHOD**

*Muhammad Farhan Md Yusoff, Nik Muhammad Shahid Nik Jaafar, Tuan Fairuz Tuan Ismail*

**PERILS OF REMOVAL OF OLD IMPLANT RADIUS: A CASE REPORT**

*Muhammad Syazwan Md Shalan, Lim Kgai Ter, Kishanraj Hari Kharan, Dinesh Earnest Kunasingh*

**PERIPROSTHETIC ATYPICAL FEMORAL FRACTURES: TIME TO REVISE THE ASBMR DIAGNOSTIC CRITERIA?**

*Neville Lim Shu Huan, Sugesh Raghavan*

**PLASTIC BAND CLOSURE OF A COMPLEX OPEN FRACTURE WOUND: A DISTRICT EXPERIENCE**

*Koh Pei Khen, Fadzly Ramidi*

**POLIOMYELITIS SURVIVOR WITH INTER-TROCHANTERIC FEMUR FRACTURE TREATED WITH INTRAMEDULLARY DEVICES: A CASE REPORT**

*Lim Kgai Ter, Dinesh Earnest Kunasingh*

**POSTERIOR PLATE WITH ANTERIOR COLUMN SCREW FROM A SINGLE APPROACH: MINIMISING COMPLICATIONS***Kamarul Arifin Abdul Razak, Kamarul Al-Haqq Abdul Ghani***POSTEROMEDIAL TIBIAL PLATEAU AVULSION FRACTURE: A CASE REPORT***Thum Ying Ying, Eo Chun Keat, Tharumaraja Thiruselvam***PREVALENCE OF SACRAL SORE IN NURSING HOME AT KUALA KUBU BHARU***Ahmad Baihaqi Abd Rahman, Aishah Fathiyah Abdul Malek, Mohd Basil Sulaiman, Richford Jonathan***PROXIMAL AND DISTAL FEMUR REPLACEMENT FOR PATIENT WITH NON UNION FRACTURE OF INTERTROCHANTERIC AND SUPRACONDYLAR FEMUR***Chin Siang Leon, Muhammad Nizamuddin, Nik Ahmad Fauzan, Mohd Hafizi***PROXIMAL FEMORAL NAIL IN SUPINE POSITION WITHOUT A FRACTURE TABLE ON TREATMENT OF SUBTROCHANTERIC WITH INTERTROCHANTERIC FEMUR FRACTURES AND PELVIC RING INJURY. A CASE REPORT***Anis Anwar Zahari, Mohamad Hafiz Mohamad Hassim, Norhaslinda Bahaudin, Abdul Rauf Ahmad***PULMONARY EMBOLISM IN DELAYED REDUCTION OF HIP DISLOCATION***Maatharasi Balan, Muhindra Rao Gsangaya, Ruben Jaya Kumar***RADIAL HEAD FIXATION VIA WRIGHTINGTON'S APPROACH***Ahmad Syafiq Mohd Zaibidi, Syed Addi Usmi Syed Othman, Kularaj Subramaniam, Indrarajah Asokumaran***RADIAL HEAD REPLACEMENT: A HOSPITAL KEMAMAN EXPERIENCE***Nurul Qisti Ab. Razak, Zareze Abd Rahman, Mohd Hafizi Mohd Yusof, Zaharul Azri Mustapha @ Zakaria***RARE CASE OF BRACHIAL ARTERY INJURY WITH COMPARTMENT SYNDROME, AND OCCULT ELBOW DISLOCATION***Jude Cornelius Savarirajo, Azizul Akram Salim, Syurahbil Abdul Halim, Joehaimy Johari, Mohd Imran Yusof, Wan Faisham Wan Ismail***RARE CASE OF TIBIAL PILON FRACTURE WITH COMPLETE LATERAL COLLATERAL LIGAMENT RUPTURE***Sugesh Raghavan, Karthigaiyan Rajalingam***RETAINING A STABLE IMPLANT IN OSTEOSYNTHESIS-ASSOCIATED INFECTION - A CASE REPORT***Muhammad Fadzil Salleh, Mohammed Harris Anwar Ali Khan, Jasvinder Singh Jagindar Singh, Nizam Shafie***RETRIEVAL OF BROKEN GUIDE WIRE IN NECK OF FEMUR: CASE REPORT***Shashindran Nair Kumaran, Lynn Azura, Felix Loong Yew Seng***RETROGRADE CEPHALOMEDULLARY NAIL REMOVAL TECHNIQUE IN PERIPROSTHETIC DISTAL FEMUR FRACTURE***Kashfullah Khalid, Sharil Abd Rahim, Wan Mohamed Hanif Wan Osman, Anas Yahya, Nurul Iylni Mohamad Noor, Mohamad Hifzhan Arimi, Mohamad Helmi Hamid***REVISION SURGERY WITH CEMENT AUGMENTATION IN PROXIMAL FEMORAL NAIL FAILURE***Abdul Hadi Mohd Zahari, Mohammed Harris Anwar Ali Khan, Jasvinder Singh Jagindar Singh, Nizam Shafie***ROLE OF REVERSE CONTRALATERAL DISTAL FEMUR LOCKING PLATE IN TREATING COMPLEX TROCHANTERIC FRACTURES A CASE SERIES***Leong Jie Xiang, Ooi Tek Zwee, Teh Wai Choon, Asrul Fahmi Azizan, Syed Addi Usmi Syed Othman***RUPTURE OF FLEXOR CARPI RADIALIS TENDON COEXIST WITH CLOSED FRACTURE DISTAL END RADIUS IS A RARE ENTITY***Muhammad Afifi Idris, Narinder Singh Joginder Singh, Muhammad Ammar Nazmi, Izwar Indra***SCHATZKER 6 TIBIAL PLATEAU FRACTURE TREATED WITH MINIMALLY INVASIVE PERCUTANEOUS SCREW FIXATION***Srijan Madusoodanan, Sankar Pillay, Mohd Rusdi Draman, Simmrat Singh Jagdish Singh***SCREW CUT-OUT BLINDED BY INTRAOPERATIVE IMAGING DURING FEMORAL NECK OSTEOSYNTHESIS***Nicholas Aw Shao Jiun, Mohd Hisam Muhamad Ariffin, Zulkiflee Osman*

**SCREW FIXATION IN BILATERAL ANTERIOR COLUMN ACETABULUM FRACTURE AND SYMPHYSIS PUBIC PLATING IN YOUNG REPRODUCTIVE WOMEN. IS THERE STILL HOPE?***Mohd Afiq Muhamed Fuad, Azlan M Sofian***SCREW FIXATION OF FEMORAL HEAD FRACTURE WITH TROCHANTERIC FLIP OSTEOTOMY: A CASE SERIES***Tiw Zhung Shen, Wan Zainuddin Wan Ab Rahman, Syed Mohd Esmat Hussaini Syed Mohd Ridzuan, Mohammad Razip Sirat***SEPTIC ARTHRITIS IN CATHETER RELATED BLOOD STREAM INFECTIONS(CRBSI) IN PATIENTS WITH END STAGE RENAL DISEASE***Nur Syahirah Azmi, Firdati Mohamed Saaid, Muhamad Nazrin Mustafa, Mohd Hamdan Mohd Ibrahim, Naadira Faa'iza Mazlan***SHOULDER DISLOCATION ASSOCIATED WITH RADIAL NERVE INJURY IS RARE ENTITY***Muhammad Afifi Idris, Teo Yu Meng, Muhammad Ammar Azmi, Fitri Asyraf Zahari, Adam Ahmad Zambri***SINGLE INCISION DUAL APPROACHES IN TIBIA PLATEAU FRACTURE***Ku Seng Koon, Norlizam Mohd Nor***SINGLE MODIFIED STOPPA APPROACH FOR THE TREATMENT OF T-TYPE ACETABULAR FRACTURE WITH ACETABULAR PROTRUSIO: A CASE REPORT***Kee Hoe Teong, Kamarul Izham Kamarudin, Mohd Saifullah Alhany Abdul Halim, S.L Vijaya Kumar Suppan***STABILIZATION OF UNSTABLE PELVIC INJURY IN A MORBIDLY OBESE PATIENT USING INFIX: A CASE REPORT***Ng Yin Teng, Khoo Jing Hern, Kamarul Izham Kamarudin, Leong Jiahour, Ahmad Fauzey Kassim***TENSION BAND PLATE: AN OPTION FOR SYMPHYSIS PUBIS DISRUPTIONS***Kamarul Arifin Abdul Razak, Kamarul Al-Haqq Abdul Ghani***THE EFFECTIVENESS OF MODIFIED METAIZEAU TECHNIQUE IN FIXATION OF ADULT RADIAL NECK FRACTURE***Mohamad Imran Hassan, Mohammed Harris Anwarali Khan, Jasvinder Singh Jagindar Singh***THE IRREDUCIBLE TRAUMATIC FLOATING HIPS- A TEST OF SURGEONS JUDGEMENT AND SKILL***Lydia Chiew Ker Minh, Nurul Aishah Muhamed Zain, Hishamudin Salam***THERE IS NO FAILURE, EXCEPT IN NO LONGER TRYING – A REVISION OF PATELLA FIXATION CASE REPORT***Muhammad Fadzil Salleh, Mohammed Harris Anwarali Khan, Jasvinder Singh Jagindar Singh, Nizam Shafie***THIGH COMPARTMENT SYNDROME WITHOUT FRACTURE: KUCHING EXPERIENCE***Mohd Rifhan Syahmi Mohd Rusdi, Mohamad Zaki Haji Mohd Amin, Jeyasilan Karpudewan***TIME HEALS: A CASE OF DELAYED MALUNION OF SUBTROCHANTERIC FEMUR***Muhd Husyaini Hasni, Yohan Khirusman Adnan***TITANIUM PATELLA CLAW PLATE AN ALTERNATIVE FOR FAILED TENSION BAND WIRING IN PATELLA FRACTURES: CASE SERIES***Nasrul Hanif Mohamad, Amrik Singh Ranjit Singh, Tai Ken Meng, Gurmeet Singh Sewa Singh***TRANSILIAC INTERPEDICULAR SCREW ROD WITH SACROILIAC JOINT CANNULATED SCREW FIXATION: A TREATMENT OPTION FOR SACROILIAC JOINT DYSFUNCTION***Khoo Jing Hern, Ng Yin Teng, Kamarul Izham Kamarudin, Leong Jiahour, Ahmad Fauzey Kassim***TRANSOLECRANON FRACTURE DISLOCATION WITH ESSEX-LOPRESTI INJURY – A CASE REPORT***Ammar Abdol Hamid, Mohamad Fauzlie Yusof, Amnie Thum Qiu Chin***TRAUMATIC ACUTE THROMBOSIS OF THE ABDOMINAL AORTA MIMICKING SPINAL CORD COMPRESSION***Priyadarssini Karunakaran, Sim Sze En, Harmony Tan Chern Yang, Hishamuddin Salam***TRAUMATIC HEMIPELVECTOMY: A RARE DEVASTATING PELVIC INJURY***Mohd Fadhil Sulong, Muhammad Fadhil Mat Salleh, Muhammad Farhan Mohd Yusoff, Mohamad Hafiz Mohamad Zaini, Zamir Hilmie Hamzah, Muhammad Hilmi Nasir*



**TRAUMATIC HETEROTOPIC OSSIFICATION IN BILATERAL FEMUR FRACTURE: A CASE REPORT**

*Nurul Qisti Ab. Razak, Zaharul Azri Mustapha @ Zakaria, Mohamad Ros Mohd Ali*

**TRAUMATIC WOUNDS COVERAGE WITH SKIN MIRCO IMPLANTATION**

*Priya Dharsan Subramaniam, Kelvin Chiang Ming Weng, Haravin Rasendren, Mahazura Mat Lawi*

**TREATMENT OF RECALCITRANT ASEPTIC ATROPIC NON UNION HUMERUS: CASE REPORT**

*Mohd Hafizuddin Ahmad Sabri, Mohammed Harris Anwarali Khan, Jasvinder Singh Jagindar Singh*

**TRICORTICAL BONE GRAFT FOR RECONSTRUCTION OF ULNA BONE. A CASE REPORT**

*Mohammad Fittry Safian, Mohd Nazri Nor*

**TRIPLANE SALTER HARRIS TYPE I AND III OF DISTAL FEMUR FRACTURE: A RARE FRACTURE PATTERN TREATED WITH OPEN REDUCTION AND POLY LEVOLACTIC ACID SCREW FIXATION**

*Umar Hakim Mohd Ghani, Rifa Aquidah Subhan*

**USE OF STEINMANN PINS AS POSTERIOR CORTICAL BLOCKADE DURING TIBIAL INTRAMEDULLARY NAILING**

*Kashfullah Khalid, Anas Yahya, Kee Hoe Tiong, Wan Mohamed Hanif Wan Osman, Mohamad Helmi Hamid, Nurul Iylni Mohamad Noor, Mohamad Hifzhan Arimi, Sharil Abd Rahim*

**USE OF ULTRASONOGRAPHY IN DIAGNOSING FOREARM FRACTURES IN A PREGNANT WOMAN**

*Eva Mahirah Zulkifli, Wong Wai Kit, Muhammad Lutfi Abdul Rashid, Yohan Khirusman Adnan, C. Sankara Kumar Chandrasekaran*

**VALIDATION AND RELIABILITY TESTING OF A PROVISIONAL SCALE TO ASSESS MUSLIM TRAUMA PATIENTS' ABILITY TO PERFORM RELIGIOUS DUTIES DURING HOSPITALIZATION**

*Mohd Ariff Sharifudin, Mai Nurul Ashikin Taib, Nazri Mohd Yusof, Al Hafiz Ibrahim, Nordin Simbak*

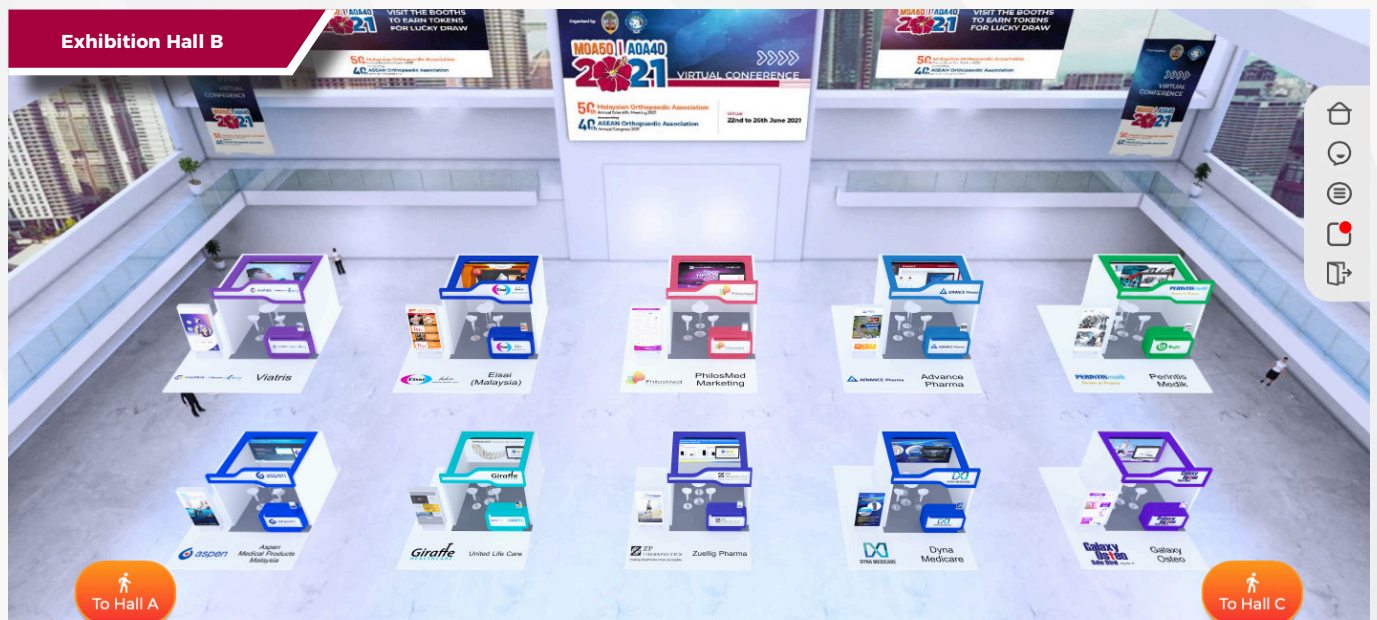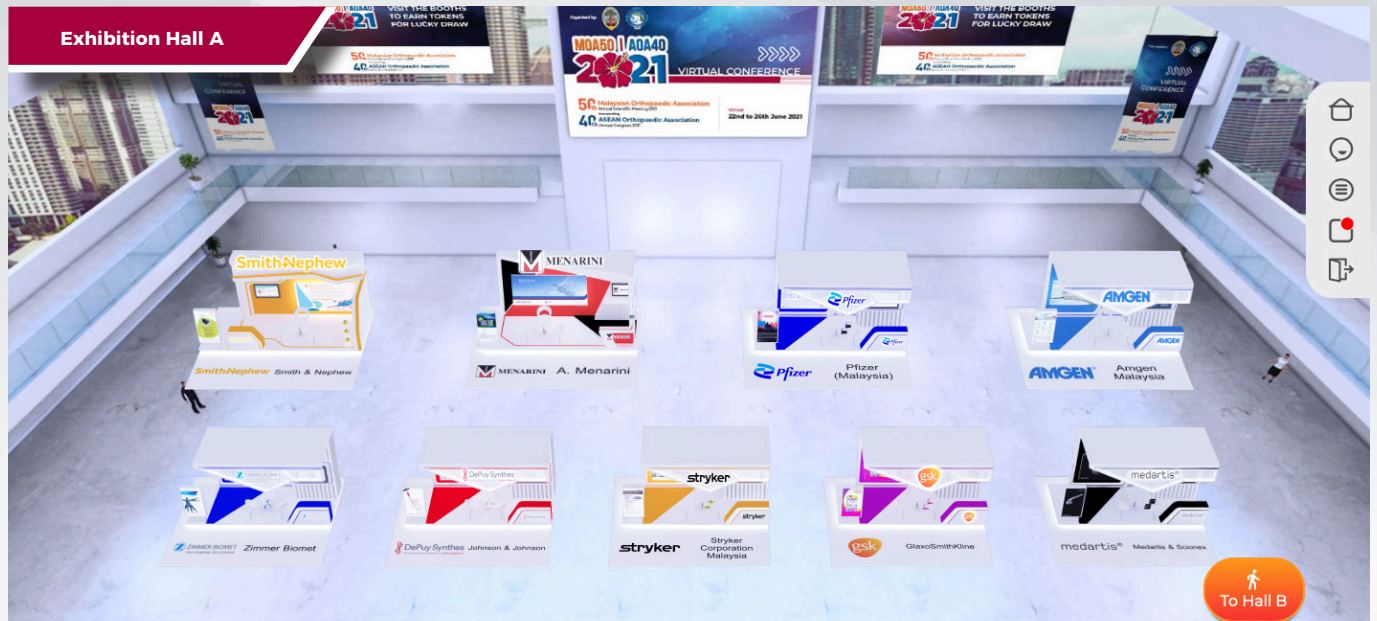
**VERTICAL WIRING TECHNIQUE FOR INFERIOR POLE FRACTURE OF PATELLA**

*Roysten Silvanathan, Muhammad Shukri Muhammad Safian, Wong Bah Huang*

**WHEN YOU CAN'T FIX IT, REPLACE IT: A COMMINUTED SUPRACONDYLAR FRACTURE FEMUR**

*Sharifah Nor Tasnim Alsagoff, Mohd Fairuz Suhaimi, Satriya Sabir Husin Athar*

Exhibition Hall



*MOA would like to acknowledge the following sponsors*

» Platinum Sponsor

**Smith+Nephew**

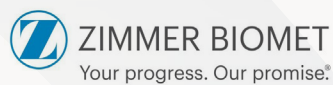
» Gold Sponsor



» Silver Sponsors



**AMGEN**



*Johnson & Johnson*

**stryker®**



**medartis®**

» Single Booth

- BTL Industries
- GE Healthcare
- NexGen Medical
- IQVIA Solutions Malaysia
- Apex Pharmacy
- Profile Technology
- United Life Care
- Zuellig Pharma
- Dyna Medicare

» Other Categories

- Galaxy Osteo
- Hyphens Pharma
- Primo Orthocare
- BBraun Medical
- CiMED Healthcare
- TRB Chemedica
- Sanofi Aventis
- H&A Medical Supply
- Novo Nordisk
- Novartis
- Taisho Pharma



## CONDROSARCOMA OF THE SPINE : A CASE REPORT IN SARAWAK GENERAL HOSPITAL

Hernany Shamsuddin<sup>1</sup>, Chan Wai Hong<sup>1</sup>, Mohamad Zaki Mohd Amin<sup>1</sup>

<sup>1</sup>University Malaysia Sarawak

**Introduction:** Chondrosarcoma represent a heterogenous group of tumors characterized by their ability of cartilage formation. Chondrosarcoma of spine is a rare condition with estimated incidence around 2% to 12% . Most frequently localized in thoracic spine followed by cervical and lumbar region.

**Discussion:** We herein report a case of spinal chondrosarcoma over thoracic spine in 58 years old gentleman. He presented with progressive swelling over the back and incomplete neurological deficit for 3 months. MRI thoracic spine showed T6 to T18 posterior spinal soft tissues, neoplastic mass with lamina arches, spinous process, adjacent posterior ribs bony erosion and spinal cord compression. Core biopsy revealed Chondrosarcoma, Grade 1. Patient underwent excision of thoracic mass, posterior instrumentation and fusion T4 -T10 with removal of pedicle of T6, T7,T8. Intraoperatively, noted tumor measuring 20cm x 20cm extending from T6-T8, involving spinous process, lamina and pedicle. Laminectomy done and tumor was excised in 1 piece together with lamina and spinous process. Postoperatively, muscle power improves to 5 from L3 to S1. Patient was discharge home well with wheelchair ambulation on day 14 post operation.

**Conclusion:** Chondrosarcoma is known to be resistance to both chemotherapy and radiotherapy. So, surgery is critically importance in managing spinal chondrosarcoma. En-block resection of chondrosarcoma with disease free margin reduce recurrence as low as 3-8%. Knowing the facts, the stability will be greatly affected due to extensive involvement to spinal column, we decided to proceed with posterior instrumentation. Surgery should aim at preserving or even improving functionality, relieving pain and controlling local tumor recurrence, promising a prolonged survival.