



European Association of Urology

Nightmares in Urology: Open Science

Nightmares in Salvage Robot-assisted Radical Prostatectomy After Primary Radiation Therapy for Prostate Cancer: A Step by Step Tutorial

Alessandro Marquis^a, Giancarlo Marra^{a,*}, Giorgio Callaris^a, Marco Oderda^a,
Gabriele Montefusco^a, Daniele D'Agate^a, Rene Sotelo^b, Prasanna Sooriakumaran^c,
Jochen Walz^d, Paolo Gontero^a

^a University Hospital S Giovanni Battista, Azienda Ospedaliero Universitaria Citta della Salute e della Scienza di Torino, Turin, Italy; ^b Keck School of Medicine, University of Southern California, Los Angeles, CA, USA; ^c Cleveland Clinic Foundation, Cleveland, OH, USA; ^d Institut Paoli-Calmettes, Marseilles, France

Article info

Article history:

Accepted July 13, 2022

Associate Editor:

Guillaume Ploussard

Keywords:

Salvage radical prostatectomy
Salvage robot-assisted radical
prostatectomy
Nightmares
Complications

Abstract

Salvage radical prostatectomy after primary radiotherapy (sRP) is considered a challenging procedure. We highlight the complications of sRP and detail critical surgical steps to help prevent them. A nonsystematic literature review in PubMed using the term “salvage radical prostatectomy” was performed on December 1, 2021. Salvage robot-assisted RP (sRARP) cases and imaging materials were used to create an [educational video](#) providing practical examples. Owing to radiation-induced changes in the prostate and surrounding tissues after radiotherapy, sRP is typically more challenging than primary RP. Among its critical steps are incision of the endopelvic fascia, bladder neck dissection with attempts at sparing the neck, development of posterior planes between the prostate and rectum, and dissection of the prostatic apex. Complication rates are significant, in particular for bladder neck contracture (0–16%) and anastomotic leakage (10–33%). Rectal injury is now rare (<2%) but still feared; careful adherence to surgical principles is required to avoid this complication. Functional outcomes are nonoptimal, with a high risk of urinary incontinence (severe incontinence in ~25% of men). sRARP is a challenging urological procedure and should be performed by experienced surgeons. Thorough knowledge of the surgical anatomy and a meticulous technique for the most difficult surgical steps are crucial to minimise complications and to improve patient outcomes.

Patient summary: In patients with prostate cancer, removal of the prostate because of cancer recurrence after primary treatment with radiotherapy can be difficult because of radiation-induced tissue damage. This challenging procedure should be performed by experienced surgeons to minimise the risk of complications.

© 2022 The Authors. Published by Elsevier B.V. on behalf of European Association of Urology. This is an open access article under the CC BY-NC-ND license (<http://creativecommons.org/licenses/by-nc-nd/4.0/>).

* Corresponding author. Department of Urology, Azienda Ospedaliero Universitaria Citta della Salute e della Scienza di Torino, Corso Bramante 88–90, 10126 Turin, Italy.
E-mail address: drgiancarlomarra@gmail.com (G. Marra).



1. Introduction

Approximately one in three men with newly diagnosed localised prostate cancer undergoes nonsurgical curative treatments, including external beam radiotherapy (RT) and brachytherapy [1]. Some 30% and 60% of these men experience biochemical recurrence at 5 and 10 yr after RT, respectively [2,3]. However, while approximately half of these recurrences involve micrometastatic disease, the other half are localised to the prostate and thus offer the potential for further radical therapy in order to achieve cancer-free status [4,5].

In the scenario of localised radiorecurrent prostate cancer, different secondary therapeutic strategies for salvage are available, including cryotherapy, high-intensity focused ultrasound, brachytherapy, and salvage radical prostatectomy (sRP). Although these options offer a chance of cure, up to 90% of men undergo long-term palliative androgen deprivation therapy, perhaps owing to the complexity of salvage therapy [6].

Historical results for sRP detail high morbidity rates, with median blood loss of up to 1 l, frequent high-grade complications, a non-negligible risk of rectal lesions and fistulas, and high rates of severe urinary incontinence. These are related to radiation-induced tissue changes that promote fibrosis, necrosis, and neoangiogenesis with consequent alterations in the local pelvic anatomy and surgical planes [7]. Despite recent improvements demonstrated in contemporary sRP series, major complications remain not infrequent and functional outcomes are still far inferior to those after primary RP (pRP) [8]. In fact, some sRP cases can represent a surgeon's worst "nightmare".

Here we detail the main difficulties that can be encountered during sRP and how to prevent them and manage them if they occur.

2. Methods

We performed a nonsystematic literature review using the term "salvage radical prostatectomy" in PubMed on December 1, 2021. Only English language articles were considered. sRP cases from Molinette Hospital (Turin, Italy) were used to create an [educational video](#) and imaging materials were used to provide practical examples of: (1) the most common complications; (2) the rationale for why complications occur more frequently in the salvage setting; and (3) surgical tips and tricks to help prevent complications.

3. Complication events and management

sRP has been related to high surgical morbidity. Historical open sRP series detailed minor (Clavien ≤ 2) and major (Clavien ≥ 3) complications in up to 50% and 33% of cases, respectively [9,10]. Better outcomes have been achieved in salvage robot-assisted RP (sRARP) series, with approximately one in three men experiencing at least one complication and one in ten men at least one high-grade complication [11].

Among major complications, bladder neck contracture (BNC), urinary incontinence, and vesicourethral anastomosis (VUA) leakage are the most frequent, while rectal injury

(RI) and fistulas are rare but highly consequential. Other potential morbidities that have been detailed more frequently than for primary RARP are postoperative haemorrhage, urinary tract infection, sepsis, and delay in wound healing.

3.1. Bladder neck contracture

Historically, BNC is one the most common complications of sRP, described in up to one in two cases [12]. However, with dissemination of the robotic approach in recent years, the BNC rate has dropped to 0–16% [13,14]. While most contractures develop within the first 6 mo, some cases may occur several months after the surgery [8].

Overall, BNC is up to five times higher after sRP than after pRP [12]. The reasons for this difference can be attributed to several radiation-induced changes. It is well known that RT causes vascular atrophy leading to poorly oxygenated tissue and/or collagen deposition [7]. Re-epithelialisation is also impaired, possibly causing a delay in tissue healing with prolonged extravasation of urine through the VUA that then promotes a fibrotic response [7,15]. Together, these processes lead to scar deposition around the bladder neck and surrounding tissues.

Figure 1 shows some examples of tissue fibrosis during bladder neck dissection in sRARP. Figure 2A shows an urethrocytogram demonstrating BNC.

In cases of significant fibrosis, intraoperative wide excision of the bladder neck and remodelling are recommended to minimise the risk of BNC. Sometimes the thick fibrotic layers surrounding the bladder neck can even be excised. Importantly, this has to be balanced against the risk of urinary leakage, as this may lead to persistent inflammatory reaction, compromising the wound healing process and possibly resulting in an anastomotic stricture [12]. Wide resection of the bladder neck can also hamper the achievement of good postoperative urinary continence, especially in the first months after surgery. Achievement of a tension-free anastomosis with buttressing sutures between the bladder and the arcus tendinous, as well as a posterior musculofascial reconstruction (the "Rocco" stitch), may also help. Inadequate or excessive catheterisation time is also a well-known risk factor for stricture formation [16], and we recommend that in most cases the catheter should be removed after a cystogram confirming the absence of leakage. Similarly, rather than at 5–7 d after surgery as in the primary setting, as irradiated tissue generally shows slower healing, catheter removal should be attempted later, at approximately 2 wk after the surgery.

3.2. VUA leakage

VUA leakage is another common complication of sRP. In comparison to pRP, for which its incidence is approximately 2% [17], the VUA leakage rate is much higher in the salvage setting and used to occur in approximately one in three men [9]. Contemporary reports detail better outcomes and lower rates. Nonetheless, approximately one in ten men still encounter prolonged postoperative leakage after sRP [18].

Poor vascularisation of the bladder neck and urethra plays a major role in reducing healing capacity. This

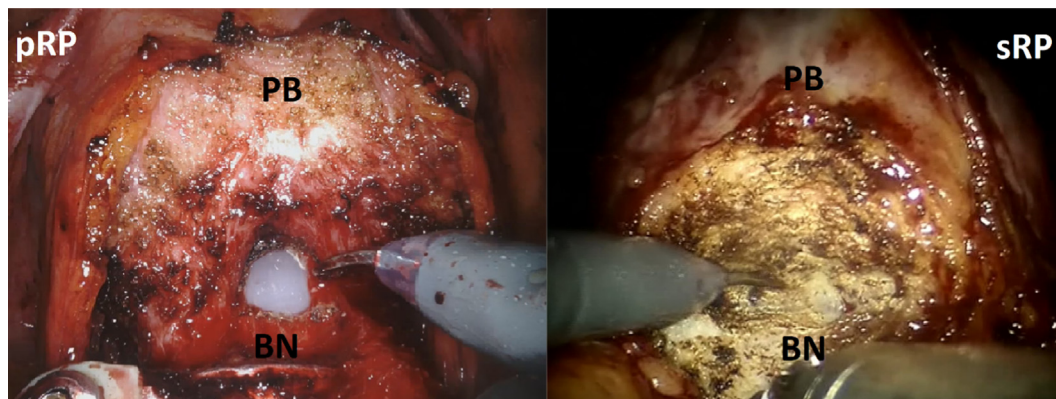


Fig. 1 – Isolation of the bladder neck during primary (pRP) and salvage (sRP) robot-assisted radical prostatectomy. PB = prostate base; BN = bladder neck.

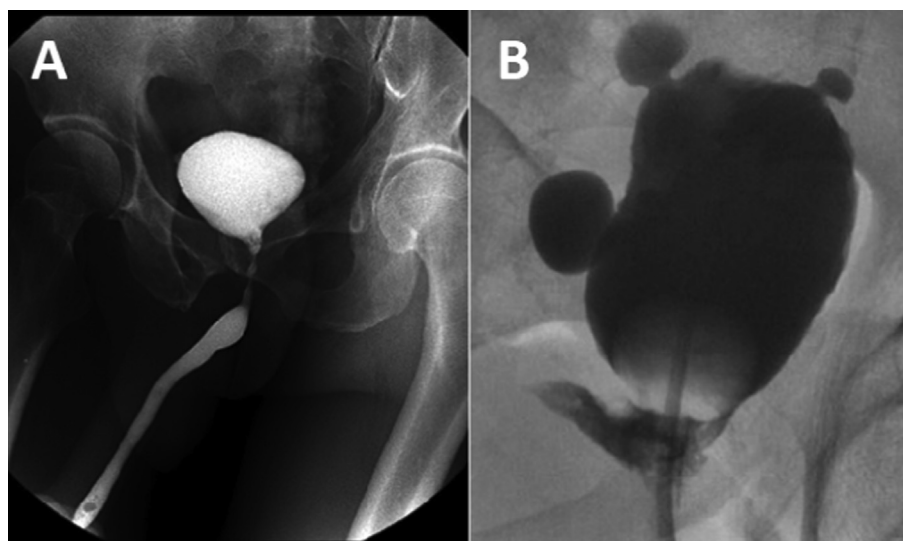


Fig. 2 – Urethrocytograms showing (A) bladder neck contracture and (B) vesicourethral anastomosis leakage.

includes lower vascularisation overall as well as a less organised microvascular supply, as postradiation neoangiogenesis is not as effective as in the treatment-naïve setting [7]. Figure 2B shows an urethrocytogram demonstrating VUA leakage. To minimise the probability of leakage, it is crucial to maximise urethral stump preservation and to avoid excessive opening of the bladder neck. In this light, performing a “tennis racquet” reconstruction, which obviates excessive suturing of bladder tissue to the urethra, can be considered. In general, we would advise a posterior racquet over an anterior racquet, as the former pushes the ureteric orifices away from the VUA, but this is a matter of surgeon preference. In this setting, a posterior reconstruction can help to achieve a tension-free anastomosis and facilitate approximation of the bladder neck and urethral stump. In any case, after completing the VUA, checking for perfect watertightness is mandatory.

Interestingly, a recent multicentre study analysed the use of a scaffold (urinary bladder extracellular matrix) that can be sutured to Denonvilliers’ fascia to wrap the posterior

aspect of the VUA, obtaining a reduction of urinary leakage risk from 35 to 6% after sRARP [19].

3.3. Urinary incontinence

Continence following sRP varies widely by series. The likelihood of continence preservation is >50% according to most recent series [8,11,18]. Nonetheless, one in four men remain severely incontinent (>2 pads/d) [11].

Radiation effects on the periapical area of the prostate favour subversion and loss of the surgical planes between the prostate apex, levator ani muscle, and the external sphincter, which may present as compact and fused as a single structure due to intense fibrotic reactions (Fig. 3). Furthermore, muscle fibres are also frequently atrophic, which decreases their physiological support for continence preservation.

To maximise the chance of preserving continence, patient selection remains crucial. Evaluation of the membranous urethral length using prostatic multiparametric magnetic resonance imaging is a proven independent pre-

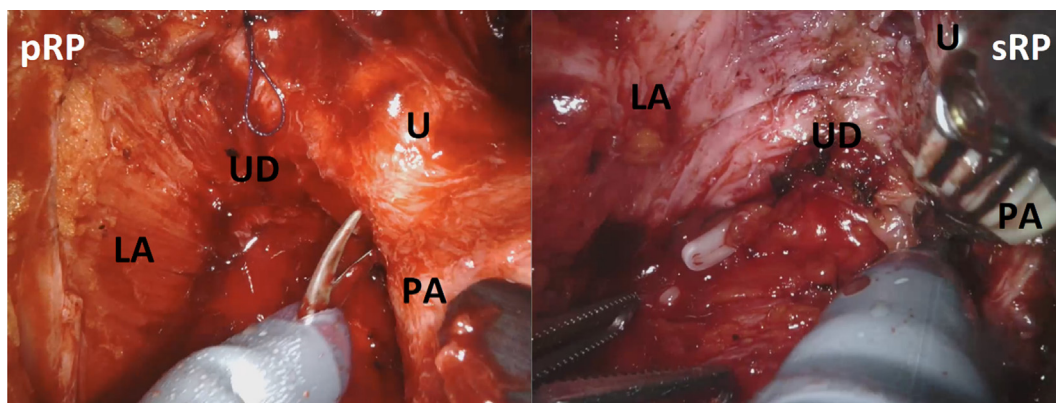


Fig. 3 – Dissection of the prostate apex during primary (pRP) and salvage (sRP) robot-assisted radical prostatectomy. LA = levator ani; UD = urogenital diaphragm; U = urethra; PA = prostate apex.

dictor of continence preservation in pRP and may help in preoperative patient selection and counselling, as those with short urethral stumps may be much more likely to remain incontinent [20]. In addition, the possibility of an underlying overactive bladder as a consequence of prior radiation should also be kept in mind. It has been reported that the robotic approach is a possible factor favouring continence preservation [11], reflecting some potential advantages arising from easier access to the urethral stump and magnified direct three-dimensional vision when aiming to maximise urethral preservation. Furthermore, it has been shown that the Retzius-sparing technique improves continence recovery, even in the sRP setting [21].

However, despite every effort, complete postoperative urinary continence remains difficult to achieve after radiotherapy, and preoperative patient counselling is essential.

3.4. Rectal injury

RI is one of the most feared complications of sRP. In comparison to older series, in which RI was reported in up to one in five cases [22], it is now more rare, reported for <2% of procedures [11,18].

The proinflammatory response and collagen deposition triggered by primary RT promote thickening of Denonvil-

lers' fascia and the formation of adhesions to the prerectal fascia (Fig. 4) [7]. In this scenario, dissection of the posterior plane can be extremely difficult. Sometimes an accurate blunt dissection is crucial to avoid RI and, in some cases, a sharp dissection avoiding the use of thermal energy may be helpful [23].

A check of the rectal wall has been strongly recommended by some authors and may be adopted, depending on the case. Some consider intraoperative digital rectal examination as a simple but effective manoeuvre in cases with suspicion of RI. Others consider the bubble test, in which the pelvic cavity is filled with saline and the rectum with air to ascertain cases of leakage, a check that should be performed in all procedures. Inspection and transillumination using a sigmoidoscope to detect thinning of the rectal wall may be also used [13,23].

In cases of RI, intraoperative conservative repair of the rectal defect is generally not recommended; a temporary diverting colostomy is the first-line choice, since previous prostatic RT is an important risk factor for rectourinary fistula [24]. For this reason, before performing sRARP, robotic colorectal surgeons should be aware of this elective surgery to allow prompt and robotic management of complications in the event that they occur.

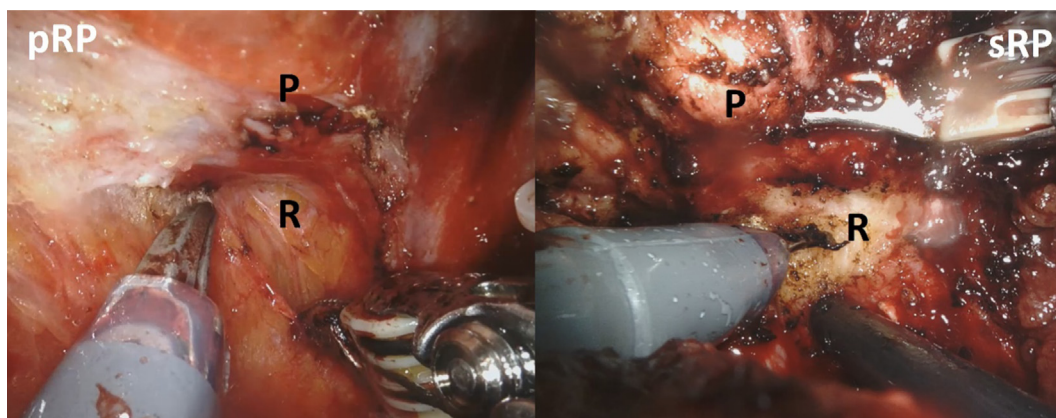


Fig. 4 – Development of posterior planes during primary (pRP) and salvage (sRP) robot-assisted radical prostatectomy. P = prostate; R = rectum.

The robotic approach has probably contributed to the RI reduction thanks to its magnified vision and accuracy of movement.

3.5. Other complications

Among other potential complications, urinary tract infection (4.3–17.9%), gross haematuria (6.3–7.1%), lymphocele (3.5–5.0%), and wound infections (2.3–6.0%) are the most frequent. Except for some cases of lymphocele that require radiology-guided drainage positioning and some cases of haematuria that requires haemostatic endoscopy procedures, the others are all classified as minor (Clavien ≤ 2) complications [9,11,25]. No significant differences between the open and robotic approaches were found [11].

Thanks to the careful haemostatic control and precise dissection allowed by the robotic approach, intraoperative and postoperative bleeding requiring transfusion is a rarer event than in the past [8,22]. To further reduce this risk, use of an intraprostatic transperineal injection of indocyanine green during docking to reveal avascular or low-perfusion tissues may be considered.

Ureteric injury and obturator nerve injury, all common major (Clavien >3) complications of salvage surgery in the past, are now dramatically lower in comparison to older series [22].

4. Discussion

Owing to the radiation-induced effects of primary RT, sRP is one of the most challenging procedures in the field of urology. It is well known that prostatic RT induces a broad spectrum of short- to long-term changes from neoangiogenesis to necrosis that affect the quality of tissues and alter the standard anatomic structures of the pelvis [7].

First, the endopelvic fascia is often thickened and fused to the prostate and levator ani muscles (Fig. 5). Therefore, special attention must be paid during endopelvic fascia incision to avoid entering the incorrect dissection planes. Sometimes it is necessary to use monopolar energy rather than blunt dissection. Second, the bladder neck is frequently surrounded by a thick layer of reactive fibrosis (Fig. 1). As a

consequence, its preservation may be suboptimal and the risk of postoperative incontinence due to inner sphincter weakening, as well as the risk of basal positive surgical margins, must be kept in mind. Third, in some cases the presence of dense fibrosis between Denonvilliers' fascia and the prerectal fascia makes the development of posterior planes extremely complex (Fig. 4). To prevent RI, an accurate blunt dissection is crucial and the robotic approach may represent an advantage over open surgery [11]. Fourth, the prostatic periapical region is often fused with the urogenital diaphragm (Fig. 3). Here, isolation of the prostatomembranous urethra requires particular care, with the aim of preserving a long urethral stump and thus the urinary continence apparatus.

One or more of these difficult steps may be present and frequently coexist during sRP. We describe the major and most common sRARP challenges to maximise awareness among sRP surgeons, who can then use these tips and tricks to reduce the incidence of complications and optimise patient outcomes. Owing to the complexity of these cases, we would advise that nonexpert urologists and those still on their primary RARP learning curve should avoid undertaking sRP procedures.

Currently, the only study to evaluate the learning process in the robotic salvage setting is a prospective single-centre series of 120 sRARP procedures performed by one surgeon; interestingly, increasing surgical experience over time did not lead to improvements in functional outcomes or complication rates, which remained stable [26]. Although extensive surgeon expertise in primary RARP may be an important limiting factor in clearly identifying the learning curve for sRARP, these data underline the challenge of this procedure.

Despite experience and following the techniques described here, complications can still occur not infrequently. Hence, patients considering this procedure must be made aware of these complications and the potential impact on long-term quality of life and a possible need for further intervention. For some patients, alternative treatment approaches such as whole-gland or focal ablation techniques may be preferable, while systemic management without local therapy is the best option for others.

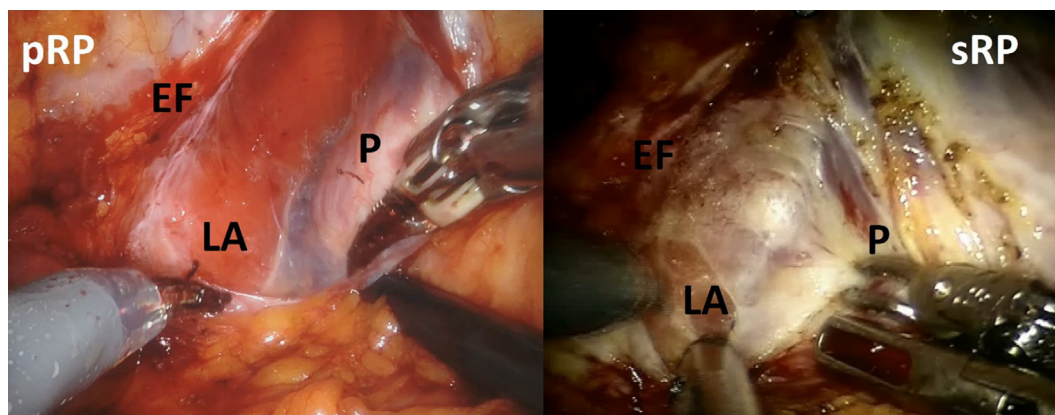


Fig. 5 – Incision of the endopelvic fascia during primary (pRP) and salvage (sRP) robot-assisted radical prostatectomy. EF = endopelvic fascia; LA = levator ani; P = prostate.

Overall, recent sRP series show promising improvements in comparison to historical series. Nevertheless, complication rates and functional results remain suboptimal and the intraoperative and postoperative course can become a “nightmare” for urologists. To minimise this occurrence, surgical experience, thorough knowledge of the procedure, and tips and tricks for dissection are essential. Preoperative patient counselling is also imperative when deciding between different treatment options.

5. Conclusions

sRP is one of the most challenging procedures in the field of urology. The radiation-induced changes caused by primary RT may result in greater surgical complexity, leading to poor functional outcomes and high complication rates. Knowledge of the most difficult steps and the most frequent complications and how to reduce their incidence and manage them if they do occur is vital in order to optimise patient outcomes.

Conflicts of interest: The authors have nothing to disclose.

Appendix A. Supplementary data

Supplementary data to this article can be found online at <https://doi.org/10.1016/j.euros.2022.07.002>.

References

- [1] Cooperberg MR, Broering JM, Carroll PR. Time trends and local variation in primary treatment of localized prostate cancer. *J Clin Oncol* 2010;28:1117–23. <https://doi.org/10.1200/JCO.2009.26.0133>.
- [2] Bolla M, Van Tienhoven G, Warde P, et al. External irradiation with or without long-term androgen suppression for prostate cancer with high metastatic risk: 10-year results of an EORTC randomised study. *Lancet Oncol* 2010;11:1066–73. [https://doi.org/10.1016/S1470-2045\(10\)70223-0](https://doi.org/10.1016/S1470-2045(10)70223-0).
- [3] Zapatero A, Mínguez R, Nieto S, Martín de Vidales C, García-Vicente F. Post-treatment prostate biopsies in the era of three-dimensional conformal radiotherapy: what can they teach us? *Eur Urol* 2009;55:902–10. <https://doi.org/10.1016/j.eururo.2008.04.076>.
- [4] Deger S, Boehmer D, Roigas J, et al. High dose rate (HDR) brachytherapy with conformal radiation therapy for localized prostate cancer. *Eur Urol* 2005;47:441–8. <https://doi.org/10.1016/j.eururo.2004.11.014>.
- [5] Lee WR, Hanks GE, Hanlon A. Increasing prostate-specific antigen profile following definitive radiation therapy for localized prostate cancer: clinical observations. *J Clin Oncol* 1997;15:230–8. <https://doi.org/10.1200/JCO.1997.15.1.230>.
- [6] Marra G, Ploussard G, Ost P, et al. Focal therapy in localised prostate cancer: real-world urological perspective explored in a cross-sectional European survey. *Urol Oncol* 2018;36:529.e11–22. <https://doi.org/10.1016/j.urolonc.2018.08.013>.
- [7] Stone HB, Coleman CN, Anscher MS, McBride WH. Effects of radiation on normal tissue: consequences and mechanisms. *Lancet Oncol* 2003;4:529–36. [https://doi.org/10.1016/S1470-2045\(03\)01191-4](https://doi.org/10.1016/S1470-2045(03)01191-4).
- [8] Callaris G, Marra G, Dalmasso E, et al. Is it worth to perform salvage radical prostatectomy for radio-recurrent prostate cancer? A literature review. *World J Urol* 2019;37:1469–83. <https://doi.org/10.1007/s00345-019-02749-z>.
- [9] Kenney PA, Nawaf CB, Mustafa M, et al. Robotic-assisted laparoscopic versus open salvage radical prostatectomy following radiotherapy. *Physiol Behav* 2017;176:139–48.
- [10] Stephenson AJ, Scardino PT, Bianco FJ, Blasio CJD, Fearn PA, Eastham JA. Morbidity and functional outcomes of salvage radical prostatectomy for locally recurrent prostate cancer after radiation therapy. *J Urol* 2004;172:2239–43. <https://doi.org/10.1097/01.ju.0000140960.63108.39>.
- [11] Gontero P, Marra G, Alessio P, et al. Salvage radical prostatectomy for recurrent prostate cancer: morbidity and functional outcomes from a large multicenter series of open versus robotic approaches. *J Urol* 2019;202:725–31. <https://doi.org/10.1097/JU.00000000000000327>.
- [12] Prasad SM, Gu X, Kowalczyk KJ, Lipsitz SR, Nguyen PL, Hu JC. Morbidity and costs of salvage vs. primary radical prostatectomy in older men. *Urol Oncol* 2013;31:1477–82. <https://doi.org/10.1016/j.urolonc.2012.04.004>.
- [13] Bates AS, Samavedi S, Kumar A, et al. Salvage robot assisted radical prostatectomy: A propensity matched study of perioperative, oncological and functional outcomes. *Eur J Surg Oncol* 2015;41:1540–6. <https://doi.org/10.1016/j.ejso.2015.06.002>.
- [14] Yuh B, Ruel N, Muldrew S, et al. Complications and outcomes of salvage robot-assisted radical prostatectomy: a single-institution experience. *BJU Int* 2014;113:769–76. <https://doi.org/10.1111/bju.12595>.
- [15] Singh M, Blandy JP. The pathology of urethral stricture. *J Urol* 1976;115:673–6. [https://doi.org/10.1016/S0022-5347\(17\)59331-3](https://doi.org/10.1016/S0022-5347(17)59331-3).
- [16] Altinova S, Serefoglu EC, Ozdemir AT, Atmaca AF, Akbulut Z, Balbay MD. Factors affecting urethral stricture development after radical retropubic prostatectomy. *Int Urol Nephrol* 2009;41:881–4. <https://doi.org/10.1007/s11255-008-9519-4>.
- [17] Novara G, Ficarra V, Rosen RC, et al. Systematic review and meta-analysis of perioperative outcomes and complications after robot-assisted radical prostatectomy. *Eur Urol* 2012;62:431–52. <https://doi.org/10.1016/j.eururo.2012.05.044>.
- [18] Marra G, Jeffrey R, Callaris G, et al. Oncological outcomes of salvage radical prostatectomy for recurrent prostate cancer in the contemporary era: a multicenter retrospective study. *Urol Oncol* 2021;39:296.e21–29. <https://doi.org/10.1016/j.urolonc.2020.11.002>.
- [19] Ogaya G, Estefania P, Espinos L, et al. Salvage robotic-assisted radical prostatectomy: oncologic and functional outcomes from two high-volume institutions. *World J Urol* 2019;37:1499–505. <https://doi.org/10.1007/s00345-018-2406-4>.
- [20] Kim LHC, Patel A, Kinsella N, Sharabiani MTA, Ap Dafydd D, Cahill D. Association between preoperative magnetic resonance imaging-based urethral parameters and continence recovery following robot-assisted radical prostatectomy. *Eur Urol Focus* 2020;6:1013–20. <https://doi.org/10.1016/j.euf.2019.01.011>.
- [21] Kowalczyk KJ, Madi RH, Eden CG, et al. Comparative outcomes of salvage Retzius-sparing versus standard robotic prostatectomy: an international, multi-surgeon series. *J Urol* 2021;206:1184–91. <https://doi.org/10.1097/JU.0000000000001939>.
- [22] Chade DC, Eastham J, Graefen M, et al. Cancer control and functional outcomes of salvage radical prostatectomy for radiation-recurrent prostate cancer: a systematic review of the literature. *Eur Urol* 2012;61:961–71. <https://doi.org/10.1016/j.eururo.2012.01.022>.
- [23] Abdul-Muhsin H, Samavedi S, Pereira C, Palmer K, Patel V. Salvage robot-assisted radical prostatectomy. *BJU Int* 2013;111:686–7. <https://doi.org/10.1111/bju.12073>.
- [24] Mandel P, Linnemannstöns A, Chun F, et al. Incidence, risk factors, management, and complications of rectal injuries during radical prostatectomy. *Eur Urol Focus* 2018;4:554–7. <https://doi.org/10.1016/j.euf.2017.01.008>.
- [25] Gotto GT, Yunis LH, Vora K, Eastham JA, Scardino PT, Rabbani F. Impact of prior prostate radiation on complications after radical prostatectomy. *J Urol* 2010;184:136–42. <https://doi.org/10.1016/j.juro.2010.03.031>.
- [26] Bonet X, Moschovas MC, Onof FF, et al. The surgical learning curve for salvage robot-assisted radical prostatectomy: a prospective single-surgeon study. *Minerva Urol Nephrol* 2021;73:600–9. <https://doi.org/10.23736/S2724-6051.20.04077-1>.