



Diagnosis of maternal Hodgkin lymphoma following abnormal findings at noninvasive prenatal screening test (NIPT): Report of two cases

Alessia Castellino¹  | Simona Elba¹ | Roberto Sorasio¹ | Claudia Castellino¹ | Margherita Bonferroni¹ | Mariella Grasso¹ | Enrico Grosso² | Rosalba Giacchello³ | Anna Franca Signorile¹ | Ivana Celeghini¹ | Daniele Mattei¹ | Nicola Mordini¹ | Myriam Foglietta¹ | Bianca Masturzo²  | Roberto Priotto¹ | Andrea Zonta² | Davide Rapezzi¹ | Massimo Massaia¹

¹AO Santa Croce e Carle di Cuneo, Cuneo, Italy

²AOU Citta' della Salute e della Scienza, Torino, Italy

³Ospedale Regina Montis Regalis Mondovì, Mondovì, Italy

Correspondence

Alessia Castellino, Hematology Unit, Santa Croce e Carle Hospital, Via Michele Coppino, 26, 12100, Cuneo, Italy.
Email: castellino.ale@ospedale.cuneo.it

Abstract

Abnormal NIPT results, contrasting with normal fetus development, could disclose maternal malignancy, and this possibility should always be explained during pre-test counseling. In this case, a complete diagnostic assessment is recommended and should be managed by a multidisciplinary team to define the best timing for diagnostic procedures, delivery, and treatment.

KEYWORDS

hematology

1 | INTRODUCTION

Sequencing cell-free DNA in plasma of pregnant women is a noninvasive prenatal screening test (NIPT) for fetal abnormalities. However, cf-DNA could derive from fetus, placenta, or mother and could disclose maternal malignancy. We report two pregnant women, who showed unusual abnormalities at NIPT leading to a Hodgkin lymphoma (HL) diagnosis.

Sequencing cell-free DNA (cf-DNA) circulating in plasma of pregnant women is a noninvasive prenatal screening test (NIPT) for fetal chromosome abnormalities.¹ However, cf-DNA could derive from both fetus, placenta, and maternal bone marrow or apoptotic cells.^{1,2} Since the first use of this screening method, some cases of “false-positive” results were shown: NIPT reported aneuploidy, but the analysis of fetal karyotype was normal. Placental mosaicism was considered

a possible explanation, while maternal malignancies were not initially considered, since their rarity (estimated 1/1000 pregnant women^{3,4}). However, cases of neoplastic diseases were reported during pregnancy: The most common are Hodgkin and non-Hodgkin's lymphomas, leukemias, melanoma, breast, ovarian, cervical, and colon rectal cancers.^{5,6}

Noninvasive prenatal screening test was widely used first to undercover trisomy of chromosome 13, 18, and 21, then also for a genome-wide detection of fetal aneuploidies.

On the same basis, the analysis of cf-DNA has been investigated for diagnosis, monitoring of response, follow-up, and emerging of resistance in many tumors, such as Hodgkin and Non-Hodgkin's lymphomas.⁷

We reported the cases of two pregnant women who showed unusual abnormal findings at NIPT leading to a diagnosis of Hodgkin lymphoma (HL).

This is an open access article under the terms of the Creative Commons Attribution-NonCommercial-NoDerivs License, which permits use and distribution in any medium, provided the original work is properly cited, the use is non-commercial and no modifications or adaptations are made.

© 2021 The Authors. *Clinical Case Reports* published by John Wiley & Sons Ltd.

2 | CASE 1

RJ a 26 years old Caucasian woman performed for her own desire NIPT at week 13 of pregnancy: Abnormal findings, with multiple aneuploidies (trisomy 1,2,3,5,12,15,17, micro-deletion 1p36, fetal sex: male), were found and were possibly in contrast with normal fetus development. For this, a chorionic villus sampling was performed and resulted negative for fetal disease. Many differential diagnostic hypotheses were ruled out, including maternal hematological malignancy. At the same time, no specific symptoms started, such as diffuse itch and asthenia. A lymphopenia and multiple lympho-adenopathies at ultrasound were shown. In the clinical suspicion of maternal cancer, at week 19 of pregnancy, needle biopsy of supraclavicular node was performed, but resulted not diagnostic. At week 24, a surgical biopsy of the same left supraclavicular node showed a diagnosis of classical sclerodular Hodgkin lymphoma (HL). Staging with magnetic resonance imaging (MRI) was II A, with a mediastinal bulky of 9×6.5 cm, no adenopathy at abdomen scan (Figure 1A). Thus, a plan of four courses of chemotherapy, according to ABVD scheme (doxorubicin, bleomycin, vinblastine and dacarbazine), followed by involved-field radiotherapy

(IF-RT) 30 gray (Gy) was done. ABVD chemotherapy was started at week 25 of pregnancy. Normal delivery occurred at week 36, few days after the completion of third ABVD course, without complications neither for newborn nor for mother. A fourth cycle of ABVD was then completed, without significant treatment delay. End of chemotherapy MRI showed residual mass measuring 3.4×1.7 cm negative at the contemporary PET scan according with Deauville score (DS) 3 (Figure 1B,C). Subsequently, the patient received standard consolidation with involved-field radiotherapy. At the end of radiation courses, response evaluation with both PET and MRI was repeated, confirming complete remission. At that point, the patient was proposed to repeat NIPT analysis to assess the reduction or even the disappearance of abnormal ct-DNA, but she refused. She is now in complete remission 24 months after the end of treatment.

3 | CASE 2

F.V is a 29 years old Caucasian woman, who underwent standard prenatal screening at week 13 of pregnancy: Abnormal findings not otherwise specified were found. The test was

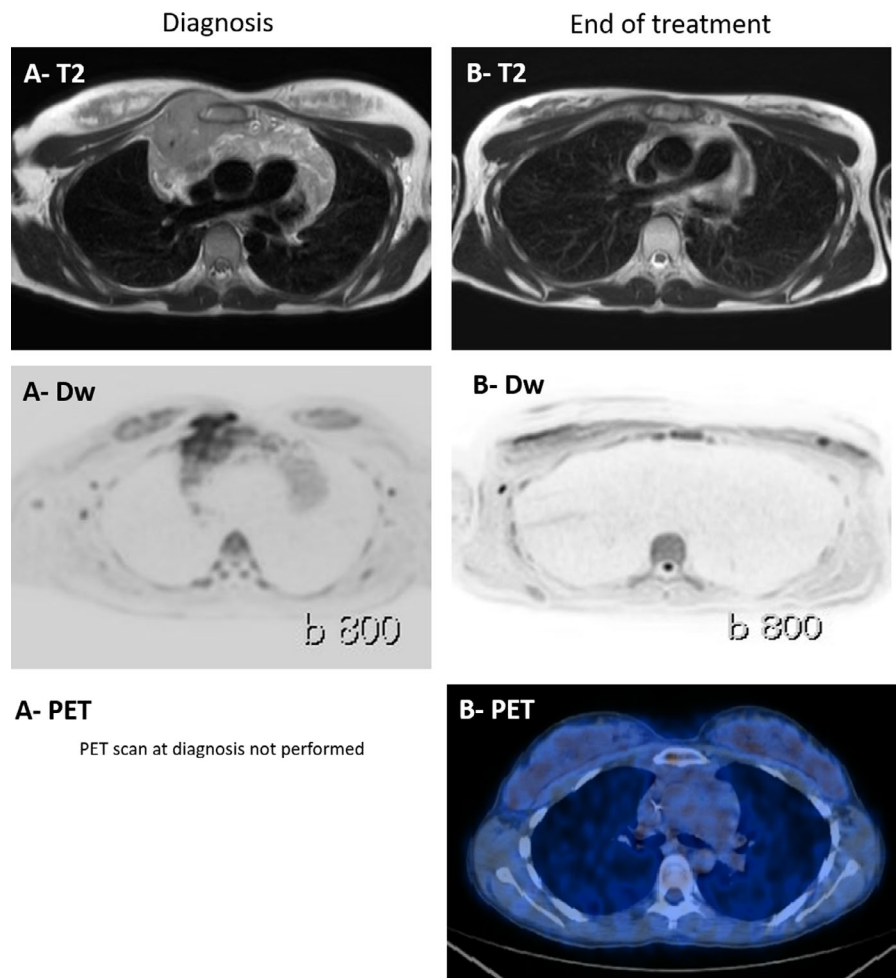


FIGURE 1 Case 1. RJ. A-T2: MRI results at diagnosis, showing mediastinal mass (T2 sequences). A-Dw: MRI results at diagnosis, showing mediastinal mass (Dw sequences). B-T2: MRI at the end of treatment, showing complete regression of mediastinal mass (T2 sequences). B-Dw: MRI at the end of treatment, showing regression of diffusion signal (Dw sequences). B-PET: CT-PET scan at the end of treatment, showing complete remission, Deauville score 3

repeated with the same doubtful results. Subsequently, she performed NIPT, which showed multiple aneuploidies (in 3 autosomal chromosomes and in sexual chromosomes) that, in contrast with normal fetus development, suggested non-fetal origin. In order to definitely rule out fetus abnormality, invasive analysis such as chorionic villus sampling or amniocentesis was proposed, but the patient refused. Maternal malignancies were searched. The patient was completely asymptomatic, no alteration in routine lab examinations was found. Nevertheless, a body MRI showed a mediastinal mass ($5.5 \times 4 \times 7$ cm) and multiple enlarged thoracic nodes (Figure 2A) with no pathological findings in the abdomen. Needle biopsy on mediastinal mass demonstrated a diagnosis of classic scleronodular HL, stage II A. Chemotherapy with four ABVD courses was planned followed by standard 30 Gy involved-field radiotherapy.

ABVD started at week 30 of pregnancy. On day 13 of second ABVD course, natural delivery occurred, without complications neither for new born nor for mother. She completed day 15 of second ABVD in the next days, without significant delay (3 days). After 2 ABVD courses, MRI showed small residual mediastinal mass measuring 1.2×1.7 cm, while contemporary PET scan was not done for clinical decision. The patient thus completed four courses of ABVD treatment, and final MRI and PET scan demonstrated complete remission

of lymphoma with PET Deauville score of 3 (Figure 2B,C). Patient underwent involved-field radiotherapy consolidation. At the end of radiation, response evaluation with both PET and MRI was repeated, confirming complete remission (PET DS 3). In this case, as well as for the other, we proposed to repeat NIPT analysis to assess the disappearance of abnormal ct-DNA, but the patient declined. She is now in complete remission, 6 months after the end of treatment.

4 | DISCUSSION

We reported the cases of two otherwise asymptomatic pregnant women who showed unusual abnormal findings at NIPT leading to a diagnosis of maternal HL. Sequencing cell-free DNA circulating in plasma of pregnant women is the basis of NIPT technique for detecting fetal chromosome abnormalities.¹ However, cf-DNA could have several different origins, such as fetus, placenta, and mother tissues.^{8,9} In the case of “false-positive” NIPT results, with normal fetal karyotype analysis, maternal malignancies should be ruled out, even if rare (estimated 1/1000 pregnant women⁴).

This represents a very uncommon clinical situation, and just few sporadic cases were reported in literature in our knowledge.^{5,10-15} The two largest series came from large

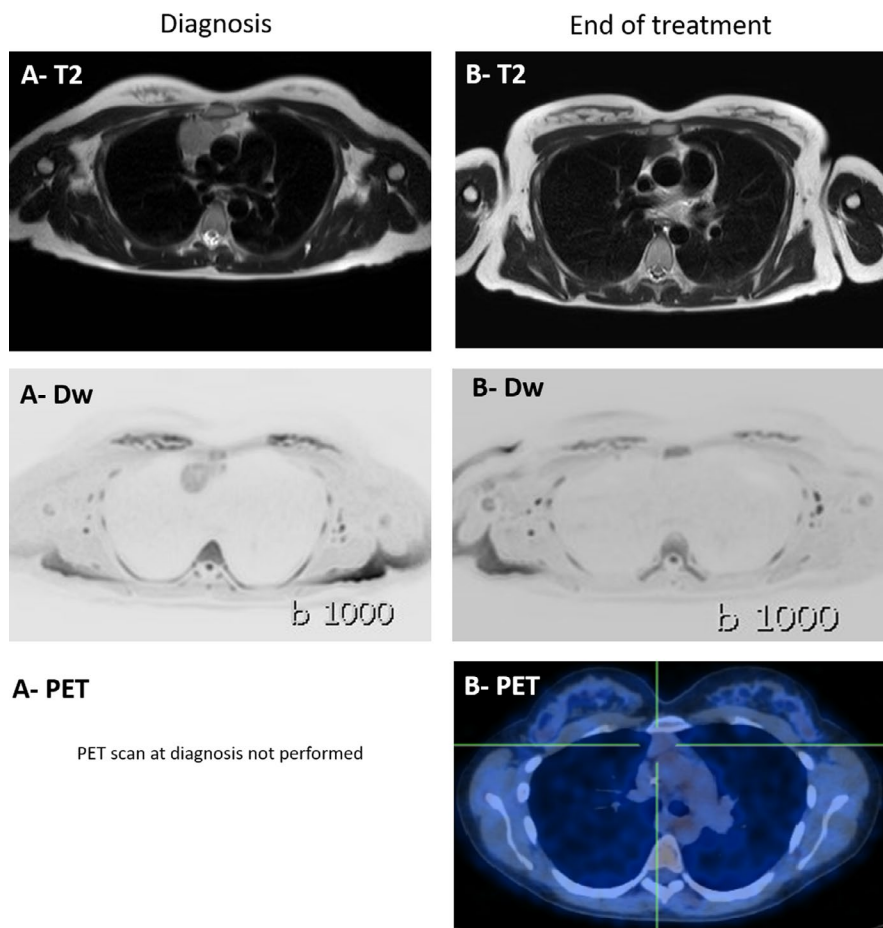


FIGURE 2 Case 2. FV. A-T2: MRI results at diagnosis, showing mediastinal mass (T2 sequences). A-Dw: MRI results at diagnosis, showing mediastinal mass (Dw sequences). B-T2: MRI at the end of treatment, showing complete regression of mediastinal mass (T2 sequences). B-Dw: MRI at the end of treatment, showing regression of diffusion signal (Dw sequences). B-PET: CT-PET scan at the end of treatment, showing complete remission, Deauville score 3

cohort of women who performed NIPT. Table 1 summarizes the principal cases reported in literature until now by our knowledge. Bianchi et al¹⁶ reported a series of 125 426 NIPT results, among which 3757 (3%) were positive for 1 or more aneuploidies involving chromosomes 13, 18, 21, X, or Y. From this set of 3757 samples, 10 cases of maternal cancer were identified. The authors observed that maternal cancers most frequently occurred with the rare NIPT finding of more than 1 aneuploidy detected (7 known cancers among 39 cases of multiple aneuploidies by NIPT, 18%). The 10 maternal malignancies were clinically different and included 3 cases of B-cell lymphoma and 1 case each of T-cell leukemia, Hodgkin lymphoma, unspecified adenocarcinoma, leiomyosarcoma, neuroendocrine, and

colorectal and anal carcinomas. In another large series reported by Dharajiya et al,¹⁷ more than 450 000 pregnant patients submitted samples for clinical laboratory testing. Fifty-five NIPT cases with altered genomic profiles were found and, among these, 40 cases showed a confirmed maternal neoplasm: 18 malignant, 20 benign uterine fibroids, and 2 with radiological confirmation but without pathological classification.

Basing on the results of these studies, the risk of maternal neoplasia when multiple aneuploidies were found could range between 20% and 40%. It is remarkable that in both series and in the two cases we reported the NIPT results preceded or coincided with the onset of symptoms and prompted the diagnosis of malignancy. This eventuality opens more

TABLE 1 Summary of the principal cases reported in literature

Author	Journal/Year	N of cases	Type of tumors	Type of NIPT abnormality
Bianchi et al ¹⁶	Jama 2015	10	3 B cell- NHL 1 T cell AL 1 HL 1 unspecified adenocarcinoma 1 leiomyosarcoma 1 neuroendocrine 1 colorectal carcinomas 1 anal carcinomas	Multiple aneuploidies
Dharajiya et al ¹⁷	Clinical Chemistry 2018	40	18 malignant 4 HL 2 B cell- NHL 1 cutaneous T-cell lymphoma 1 MM 1 CLL 4 breast carcinoma 1 colon carcinoma 1 epithelioid angiosarcoma 1 uterine leiomyosarcoma 1 small-cell vaginal carcinoma 1 esophageal carcinoma 20 benign uterine fibroids 2 unknown	Multiple aneuploidies
Amant et al ⁵	Jama Oncol 2015	3	1 ovarian carcinoma 1 FL 1 HL	Copy number gains
Dharajiya et al ¹⁰	Prenat Diagn 2015	1	1 Uterine leiomyoma	Multiple aneuploies
Osborne et al ¹¹	Prenat Diagn 2013	1	1 metastatic neuroendocrine carcinoma (unknown site of origin)	Multiple aneuploies
Janssens et al ¹²	Prenat Diagn 2016	1	1 CML	t(9;22) breakpoints
Smith et al ¹³	Clinical Case Report 2017	1	1 colon cancer	Multiple aneuploidies
X et al ¹⁴	Taiwan J Obstet Gynecol, 2018	2	1 dysgerminoma 1 cervical cancer	Copy number variations
Vandenbergh et al ¹⁵	Lancet Haematol 2015	1	1 HL	Multiple aneuploies

Abbreviations: AL, acute leukemia; CLL, chronic lymphocytic leukemia; CML, chronic myeloid leukemia; FL, follicular lymphoma; HL, Hodgkin lymphoma; MM, multiple myeloma; NHL, non-Hodgkin lymphoma.

questions than answers and raises important implications for the prenatal counseling and the informed consent process.

Routine analysis of cf-DNA holds considerable potential to shape the way early diagnosis of cancer is made in the near future and opens to great potentiality for follow-up.⁶ In few of the cases of the series reported in literature, NIPT analysis repeated after cancer treatment showed the disappearance of abnormal cf-DNA in mother blood, opening to a great opportunity of molecular follow-up. However, our patients declined to repeat the NIPT test after treatment and we could not report this additional data.

In both our cases, a prompt diagnosis and staging were allowed by MRI scan. During pregnancy, the safest diagnostic modality is represented by ultrasound. However, ultrasound is much less sensible and specific than MRI. Also, MRI (above all diffusion weighted imaging) performed at the end of treatment, combined with PET scan, allowed a more accurate evaluation of response, through a comparison with baseline MRI images. MRI is considered reasonable safe during pregnancy (above all after first trimester), even if some concerns remain for potential teratogenicity, fetal acoustic damage (even if technical measures have been used to reduce noise like “soft tone”), and the potential effect of gadolinium contrast on the developing fetus. Although follow-up studies on infants who had undergone antenatal MRI are reassuring, the patients should be always adequately counseled regarding the potential risks and benefits.¹⁸

Another important task, after maternal cancer diagnosis, is the best timing for starting treatment. Management decisions at any time point require a multidisciplinary team, involving hemato-oncologists, medical obstetricians, nurses, and next of kin. An increasing evidence suggests that ABVD chemotherapy during second and third trimesters of pregnancy can be considered safe and does not result in inferior outcome comparing with deferring treatment.¹⁹ Although there is not a gold standard management during pregnancy, ABVD can be administered without major concerns after the first trimester of pregnancy, above all in patient with advance disease, systemic symptoms or large mediastinal mass that could negatively impact on delivery, as in the cases we reported. However, we are aware that our results and clinical practice do not represent the only possible ones and that are not easily generalizable to different situations and other approaches, such as waiting for delivery before starting treatment, could be considered appropriate as well.

In conclusion, abnormal results of NIPT could disclose maternal malignancy and this eventuality should be explained during prenatal test counseling. In the case of abnormal findings, a complete diagnostic assessment is recommended and, when reasonably safe such as in HL, diagnosis and treatment during pregnancy could be considered without major concern for mothers and babies, even if they should always be defined case by case by a multidisciplinary team.

ACKNOWLEDGMENT

Published with written consent of the patient.

CONFLICT OF INTEREST

Castellino, Elba, Sorasio, Castellino, Bonferroni, Grasso, Grosso, Giacchello, A. F. Signorile, Celeghini, Mattei, Mordini, Foglietta, Masturzo, Priotto, Zonta, Rapezzi, Massaia: nothing to disclose.

AUTHOR CONTRIBUTIONS

AC, SE: wrote the manuscript, reviewed data. RS and DR: supervised the study, and reviewed the manuscript and the contents. RP: collected and edit the figures, reviewed the manuscript. CC, MB, MG, EG, RG, AFS, IC, DM, NM, MF, BM, AZ, DR, MM: reviewed and approved the manuscript.

ORCID

Alessia Castellino  <https://orcid.org/0000-0002-1922-9054>

Bianca Masturzo  <https://orcid.org/0000-0001-5243-0940>

REFERENCES

- Benn P, Plon SE, Bianchi DW. Current controversies in prenatal diagnosis 2: NIPT results suggesting maternal cancer should always be disclosed. *Prenat Diagn*. 2018;39(5):339-343.
- Chiu RW, Chan KC, Gao Y, et al. Non invasive prenatal diagnosis of fetal chromosomal aneuploidy by massively parallel genomic sequencing of DNA in maternal plasma. *Proc Natl Acad Sci USA*. 2008;105(51):20458-20463.
- Hartwig TS, Ambye L, Sørensen S, et al. Discordant non-invasive prenatal testing (NIPT) - a systematic review. *Prenat Diagn*. 2017;37(6):527-539.
- Pavlidis NA. Coexistence of pregnancies and malignancies. *Oncologist*. 2002;7(4):279-287. Review. Erratum. In: *Oncologist* 2002;7(6):585.
- Amant F, Verheevke M, Wlodarska I, et al. Presymptomatic identification of cancers in pregnant women during non invasive prenatal testing. *JAMA Oncol*. 2015;1:814-819.
- Bianchi DW. Cherchez la femme: maternal incidental findings can explain discordant prenatal cell-free DNA sequencing results. *Genet Med Advance*. 2017;20(9):9910-9917.
- Spina V, Rossi D. Liquid biopsy in tissue-born lymphomas. *Swiss Med Wkly*. 2019;149:w14709.
- Samura O, Okamoto A. Causes of aberrant non-invasive prenatal testing for aneuploidy: a systematic review. *Taiwan J Obstet Gynecol*. 2020;59:16-20.
- Carlson LM, Hardisty E, Coombs CC, Vora NL. Maternal malignancy evaluation after discordant cell-free DNA results. *Obstet Gynecol*. 2018;131(3):464e8.
- Dharajiya NG, Namba A, Horiuchi I, et al. Uterine leiomyoma confounding a noninvasive prenatal test result. *Prenat Diagn*. 2013;35:990-993.
- Osborne CM, Hardisty E, Devers P, et al. Discordant noninvasive prenatal testing results in a patient subsequently diagnosed with metastatic disease. *Prenat Diagn*. 2013;33:609-611.
- Janssens K, Deiteren K, Verlinden A, et al. Detection of a case of chronic myeloid leukaemia with deletions at the t(9;22)

- translocation breakpoints by a genome-wide non-invasive prenatal test. *Prenat Diagn.* 2016;36:760-765. 24.
13. Smith J, Kean V, Bianchi DW, et al. Cell-free DNA results lead to unexpected diagnosis. *Clin Case Reports.* 2017;5:1323-1326.
 14. Ji X, Chen F, Zhou Y, et al. Copy number variation profile in non-invasive prenatal testing (NIPT) can identify co-existing maternal malignancies: case reports and a literature review. *Taiwan J Obstet Gynecol.* 2018;57(6):871-877.
 15. Vandenberghe P, Wlodarska I, Tousseyn T, et al. Non-invasive detection of genomic imbalances in Hodgkin/Reed-Sternberg cells in early and advanced stage Hodgkin's lymphoma by sequencing of circulating cell-free DNA: a technical proof-of-principle study. *Lancet Haematol.* 2015;2(2):e55-e65.
 16. Bianchi DW, Chudova D, Sehnert AJ, et al. Noninvasive prenatal testing and incidental detection of occult maternal malignancies. *JAMA.* 2015;314(2):162-169.
 17. Dharajiya NG, Grosu DS, Farkas DH, et al. Incidental detection of maternal neoplasia in noninvasive prenatal testing. *Clin Chem.* 2018;64(2):329-335.
 18. Eyre TA, Lau IJ, Mackillop L, et al. Management and controversies of classical Hodgkin lymphoma in pregnancy. *BJH.* 2015;169:613-630.
 19. Even AM, Advani R, Press OW, et al. Lymphoma occurring during pregnancy: antenatal therapy, complications, and maternal survival in a multicenter analysis. *J Clin Oncol.* 2013;31:4132-4139.

How to cite this article: Castellino A, Elba S, Sorasio R, et al. Diagnosis of maternal Hodgkin lymphoma following abnormal findings at noninvasive prenatal screening test (NIPT): Report of two cases. *Clin Case Rep.* 2021;9:1066–1071. <https://doi.org/10.1002/ccr3.3593>