

## Clinical Study

# Efficacy of Subconjunctival Bevacizumab Injections before and after Surgical Excision in Preventing Pterygium Recurrence

Raffaele Nuzzi and Federico Tridico

Eye Clinic Section and Specialization School in Ophthalmology, Institute of Ophthalmology, Department of Clinical Pathophysiology, University of Turin, Via Juvarra 19, 10100 Turin, Italy

Correspondence should be addressed to Raffaele Nuzzi; [prof.nuzzi\\_raffaele@hotmail.it](mailto:prof.nuzzi_raffaele@hotmail.it)

Received 5 November 2016; Revised 24 March 2017; Accepted 11 April 2017; Published 28 May 2017

Academic Editor: Enrico Peiretti

Copyright © 2017 Raffaele Nuzzi and Federico Tridico. This is an open access article distributed under the Creative Commons Attribution License, which permits unrestricted use, distribution, and reproduction in any medium, provided the original work is properly cited.

**Purpose.** To evaluate the efficacy of subconjunctival bevacizumab injections, before and after surgical excision with bare sclera technique, in preventing postoperative pterygium recurrence. **Material and Methods.** 83 eyes of 83 patients affected with primary pterygia underwent surgical excision. 42 eyes received two subconjunctival bevacizumab injections, at the dosage of 2.5 mg/0.1 ml, one week prior surgery and one week after intervention. Recurrence rate was evaluated among the two groups. Moreover, modifications of pterygium size and grade one week after the first injection were evaluated. **Results.** At 6 months after surgery, the recurrence rate was 7.14% in the bevacizumab group and 24.39% in the control group. Significant changes of pterygium size and grade were reported after the first injection. No important complications related to bevacizumab subconjunctival injections were registered. **Conclusions.** The application of subconjunctival bevacizumab injections, at the dosage of 2.5 mg/0.1 ml, before and after surgical pterygium excision, may be useful in preventing lesion recurrence after bare scleral procedures. Furthermore, bevacizumab subconjunctival administration is well tolerated and may represent a safer alternative if compared with other surgical techniques and adjunctive drugs. This trial is retrospectively registered with ISRCTN Registry on 18 April 2017, TRN: ISRCTN11424742.

## 1. Introduction

Pterygium is a very common conjunctival degenerative condition though the exact cause of this lesion is not completely understood. Risk factors include exposure to ultraviolet and sunlight, wind, dust, trauma, and inflammation. An increased incidence is reported in certain occupations, such as welding, landscaping, farming, and fishing. Its prevalence is also increased in individuals from warmer climates secondary to higher amounts of time spent outdoors and is twice as likely to occur in men than women [1, 2].

Even if it is usually described as a degenerative process, inflammation and fibrovascular proliferation have proven to be very important factors for its pathogenesis. Since pterygia are composed of proliferating fibrovascular tissue, it is clear that neovascularization is involved in its development

and progression. It has been shown that there is angiogenesis during the formation of pterygia [3]. Many growth factors such as vascular endothelial growth factor (VEGF), fibroblast growth factor (FGF), platelet-derived growth factor (PDGF), transforming growth factor beta (TGF- $\beta$ ), and tumor necrosis factor-alpha (TNF- $\alpha$ ) chemically stimulate angiogenesis and have been observed in fibroblastic and inflammatory pterygium cells [4]. Many studies have shown VEGF to be increased in the pathogenesis of pterygia. On immunohistochemistry studies, it has been shown that immunostaining of VEGF is much more intensive in studied pterygial sections if compared to normal conjunctival tissue [5, 6].

There is currently no reliable medical treatment to reduce or even prevent pterygium progression. The definitive treatment is achieved by surgical excision, usually performed if the patient is chronically symptomatic, not responsive to

nonsurgical therapies, or until it becomes vision threatening. However, surgery alone cannot prevent recurrence. Clearly, there is no clear-cut single treatment that is superior to others. In order to reduce the rate of recurrence, various modalities have been proposed. The success of pterygium surgery is dependent on the degree of postoperative wound healing and the amount of scar tissue formation. Recurrence occurs as fibroblasts proliferate and migrate towards the cornea [7–9].

The most common cause of recurrent pterygium is surgical trauma, and the histopathological components include neovascularization and fibroblast proliferation. The majority of medical treatments involve measures that are effective in the inhibition of fibrovascular activities, which play the key role in pterygium recurrence. Preliminary evidence suggests that local bevacizumab may be effective in the treatment of ocular surface neovascularization. Manzano et al. demonstrated that topical bevacizumab, 4 mg/ml, limited corneal neovascularization in a rat model [10]. A recent case report demonstrated the efficacy of 2.5% topical bevacizumab administered four times daily for 3 weeks in inhibiting the recurrence in a patient with impending recurrent pterygium [11]. The aim of this study is to evaluate the efficacy of a protocol based on the application of two 2.5 mg/ml bevacizumab injections, before and after surgery, as adjuvant therapy of surgical pterygium excision.

## 2. Methods

83 eyes of 83 patients affected with primary pterygium have been enrolled in this prospective, comparative, blind, clinical study. Informed consent was obtained from all patients before treatment. All patients underwent full ophthalmological examination before and after surgery. Exclusion criteria were pregnancy, ocular surface disease or infection, autoimmune disorders, and previous limbal surgery.

All 83 patients underwent pterygium excision with bare sclera exposition, performed by a single surgeon. The surgical technique featured

- (1) subconjunctival anesthetic (lidocaine 2%) injection in the area adjacent to the pterygium (5 mm from limbus);
- (2) excision of the pterygium, starting from its head, followed by pterygium body removal;
- (3) exposition of a triangular-shaped bare scleral bed of little dimensions (with the base at the level of the limbus and margins of 1 mm each, as shown in Figure 1);
- (4) conjunctival suture with vicryl 7-0 at the end of the procedure. Suture knot and wire ends were covered by conjunctiva to prevent inflammatory stimuli.

Patients were randomized into two groups. 42 eyes received two subconjunctival bevacizumab injections (2.5 mg/0.1 ml), one 7 days before pterygium excision and the second 15 days after surgery (group A). Bevacizumab injections for subconjunctival use were extracted from

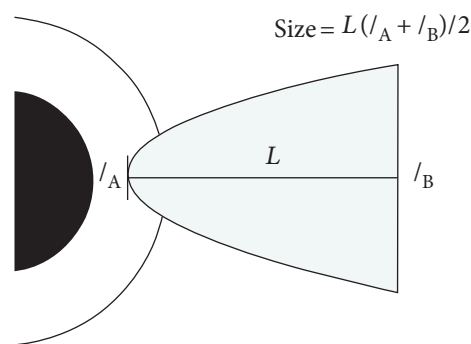


FIGURE 1: Measuring pterygium dimension method. This method, based on measurements performed by Singh et al. in their study (2015), can be considered crude since the pterygium shape is compared to a trapezoid.

100 mg commercially available vials. Preparation of injections has been performed in vertical laminar flow workstation. The first injection was performed at the level of the body of the pterygium, while the second injection was applied at the level of the apex and the margins of the excision triangle. 41 eyes were enrolled in the control group and did not receive subconjunctival injections (group B). Patients were treated with tobramycin and dexamethasone eye drops three times daily for 1 week after surgery.

All patients were followed for 6 months by two independent examiners, in order to assess recurrence frequency of pterygium among the groups under study. After the first injection, changes in vascularization and dimensions of pterygia were evaluated shortly before the surgical excision at the 7th day. Dimensions of the pterygium were measured by calculating the area after taking length in mm (from base, considered at the level of the caruncle, to apex, considered at the most prominent point on the cornea) and width in mm at the base and apical areas (Figure 2). In order to observe modifications of vascularization after the first injection, we compared photos taken at the slit lamp at the registration visit with those taken at 7 days after first subconjunctival bevacizumab administration. Grading of vascularization was done on all photos according to the scheme proposed by Tan et al. [12]:

- (1) Grade I (atrophic): clearly distinguishable episcleral vessel under the body of the pterygium
- (2) Grade II (intermediate): partially visible episcleral vessels under the body of the pterygium
- (3) Grade III (fleshy): totally obscured episcleral vessels under the body of the pterygium.

Follow-up visits were scheduled at 1 day, 1 week, and 1, 3, and 6 months. Recurrence was defined by growth of fibrovascular tissue extending more than 1 mm across the limbus. Examiners were blinded to the treatment protocol. Statistical significance related to the difference in recurrence rate between the two groups has been evaluated with the chi-squared test. Significance of changes of mean pterygia

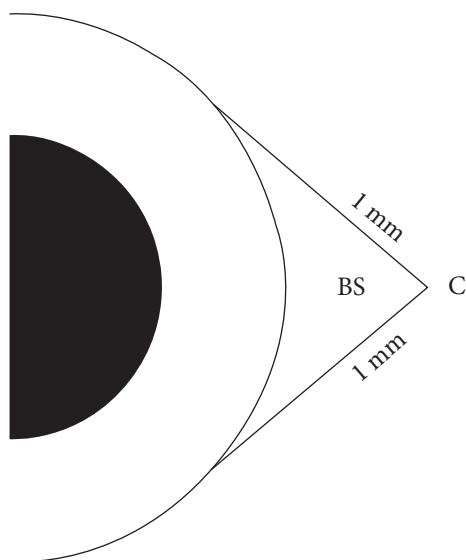


FIGURE 2: Schematic diagram showing the amount of bare sclera remaining after excision. BS = bare sclera; C = conjunctiva.

TABLE 1: Patient characteristics for groups A and B.

	Group A	Group B
Number of patients	42	41
Mean age	52.39 (42–63)	54.02 (46–62)
Male	20	23
Female	22	18

dimensions between the two groups was evaluated with Student’s *t*-test, while changes of grading of pterygia between groups were evaluated using Mann–Whitney test.

### 3. Results

Characteristics of included patients are listed in Table 1. No significant differences regarding sex and age between the two groups were noted. Mean changes of lesion dimensions and vascularization at 1 week after the first injection in group A are shown in Figures 3 and 4, respectively. At 6 months after surgery, the recurrence rate was 7.14% in group A ( $n = 3$ ) and 24.39% in group B ( $n = 10$ ). This difference was statistically significant ( $p = 0.03$ ; CI 0.02–34.14). All cases of pterygium recurrence in group A occurred in subjects with more than 50 years of age while 2 cases in group B occurred in patients with less than 50 years of age. Female patients that suffered from pterygium recurrence were 1 in group A and 2 in group B. All cases of pterygium recurrence in group A were reported at 3 months after the second subconjunctival injection. Regarding group B, 2 cases of recurrence occurred at 1 month after surgery, 6 cases occurred after 3 months, and remaining cases were observed at 6 months follow-up. No complications related to subconjunctival bevacizumab injections were registered during the follow-up period.

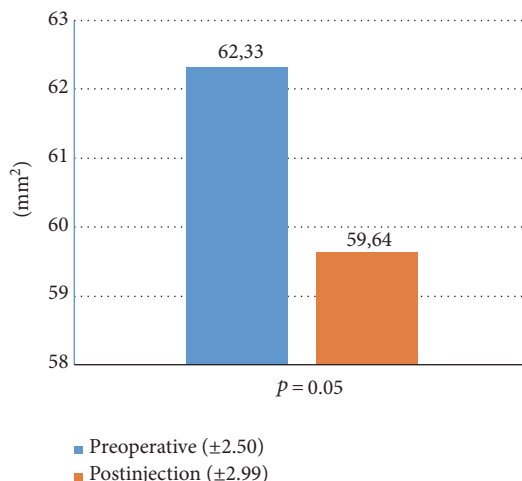


FIGURE 3: Mean changes in pterygium dimensions one week after first subconjunctival bevacizumab injection in group A.

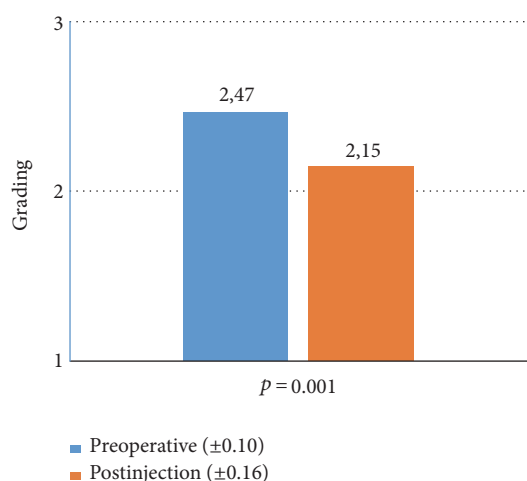


FIGURE 4: Mean changes in pterygium grading 1 week after first subconjunctival bevacizumab injection in group A.

### 4. Discussion

The primary concern in pterygium surgery is recurrence, defined by regrowth of the fibrovascular tissue across the limbus and onto the cornea. In order to reduce the rate of recurrence, various modalities have been proposed. Generally, pterygium recurrences happen during the first 6 months after surgery. A number of factors such as the type of pterygium, age of the patient, environmental agents, and surgical technique may be responsible.

In fact, the bare sclera technique, which involves excising the head and body of the pterygium while allowing the scleral bed to re-epithelialize, is usually associated with high recurrence rates (24–89%) [13]. In this study, it was intended to evaluate the efficacy of 2.5 mg/0.1 ml bevacizumab injections—applied before and after pterygium excision surgery with bare sclera technique—in preventing postoperative recurrence. This is the only study employing this particular

timing for subconjunctival bevacizumab injections, at the present time.

The bare sclera technique has been chosen for this study because it is easy to perform and usually associated with higher recurrence rates, thus proving that surgery alone cannot be sufficient to prevent recurrence. We chose to not administer any kind of injection/placebo prior/after surgery in the control group, since we intended to prevent any inflammatory response, related to the injection itself, that might influence the recurrence rate in this group. Moreover, different excision techniques, even if featured with lower recurrence rate, may be associated with problems such as conjunctival graft edema, graft necrosis, hematoma, Tenon's pyogenic granuloma, corneoscleral dellen, epithelial inclusion cysts, donor site fibrosis (for conjunctival autografting and application of amniotic membrane, as well) [14–16]. In addition, rotational conjunctival autografting cannot be used in cases with large bare scleral area after excision [17]. In regard to amniotic membrane transplantation, the potential risk of amniotic membrane contamination with consequent failure is still present and cannot be overlooked [18]. Furthermore, amniotic membrane application is associated with higher costs and reduced availability.

Adjunctive drugs for pterygium excision involve measures to counter the fibrovascular activities that play key roles in pterygium recurrence. The application of mitomycin C to the scleral bed for 3 minutes proved to be useful in the prevention of pterygium recurrence [19], but, apart from the expensive costs, this procedure can be associated with scleral ulcerations, necrotizing scleritis, perforation (more frequent in myopic eyes, perhaps due to thinner scleral walls) iridocyclitis, cataract, glaucoma, scleral calcification, and eye loss. For this reason, mitomycin C is not fully safe and can be administered with more difficulties [20, 21]. The application of a single pre/intraoperative low dosage of mitomycin C proved over the years to be a safer and effective modality for the management of recurrent pterygium, but side effects like delayed epithelization (>2 weeks) and scleral thinning are still possible [22]. Furthermore, melting of conjunctival or amniotic membrane transplant is still possible if associated with mitomycin C application, thus compromising the success of these techniques [23]. Walkow et al. showed that the bare sclera excision technique in association with phototherapeutic keratectomy and postoperative mitomycin C 0.02% eye drops twice daily for 4 days is a relatively safe method that can reduce pterygium recurrence to 2.9% after 28 months [24]; however, the application of an excimer laser is often associated with an increase in costs and may not be always available for this purpose.

The application of subconjunctival bevacizumab in addition to surgical excision seemed to be well tolerated in previous studies [25]. Even in our study, no complications after multiple subconjunctival bevacizumab injections have been reported. Minor side effects of bevacizumab subconjunctival injections, like conjunctival hemorrhage, have been reported but, due to small number of subjects in previous studies, definitive conclusions on safety and long-term effects are still debated. However, as of today, there is no concordance on which protocol has to be applied. The only other study

evaluating subconjunctival bevacizumab injections after pterygium excision with bare sclera technique has been conducted by Shenasi et al. During those investigations, no significant effects of bevacizumab have been registered; however, in that occasion, a single dose with a lower dosage of bevacizumab was used [26].

Razeghinejad et al. reported that a single intraoperative subconjunctival bevacizumab injection (1.25 mg/0.1 ml) had no effect on recurrence rate [27]. Singh et al. used a single low-dose (1.25 mg/0.5 ml) preoperative subconjunctival injection of bevacizumab with no significant effects on recurrence rate after 3 months, even if there was a significant improvement in grade, color intensity, and size of the pterygium [28]. A single low-dose bevacizumab injection, either preoperative or postoperative, showed no efficacy probably due the transient effects of anti-VEGF drugs, related to their short half-life; therefore, it has been suggested to repeat the injection after the operation and apply a higher dose of bevacizumab.

Nava-Castañeda et al. have studied the efficacy of 2.5 mg/0.1 ml of conjunctival autograft and two subconjunctival bevacizumab (the first one immediately after surgery and the second one after 15 days) in reducing recurrence of the disease, with satisfactory results after a 1-year follow-up [29]. Another study performed by Ozsutcu et al. evaluated the use of an intraoperative bevacizumab injection, with the same dosage, associated with pterygium excision with rotational conjunctival flap followed by another injection after 1 week, reporting significantly less recurrence than rotational flap alone [30]. No side effects related to bevacizumab injection were observed in any previous study [31–33].

In our study, the recurrence rate was significantly lower in the group that underwent pre- and postoperative bevacizumab injection (Figure 5). Moreover, we observed improvements in dimensions and vascularization of pterygium one week after the first subconjunctival injection (Figure 6). Therefore, it is possible that preoperative bevacizumab application may induce several morphological changes that can facilitate the following surgical excision. Even Fallah et al. evaluated the efficacy of intrascleral bevacizumab injection (2.5 mg/0.1 ml) in reducing the size of pterygia and found it to be fairly effective and well tolerated (mean decrease of lesion size was  $3.97 \pm 3.84\%$ ) [34]. However, since bevacizumab effects may be transient, a second injection is required in order to inhibit the acute fibrovascular phase that occurs in the immediate postoperative time and may be responsible of the recurrence onset.

## 5. Conclusion

Even if at the present time there is still no widespread accordance on the modality of administration, timing, and dose, the application of subconjunctival bevacizumab injections, at the dosage of 2.5 mg/0.1 ml, before and after surgical pterygium excision, may be useful in preventing lesion recurrence after bare scleral procedures. No adverse effects were reported among the treated patients, confirming the relative safety of this administration's way and dose. This treatment protocol is easy to perform with possible lower costs and side



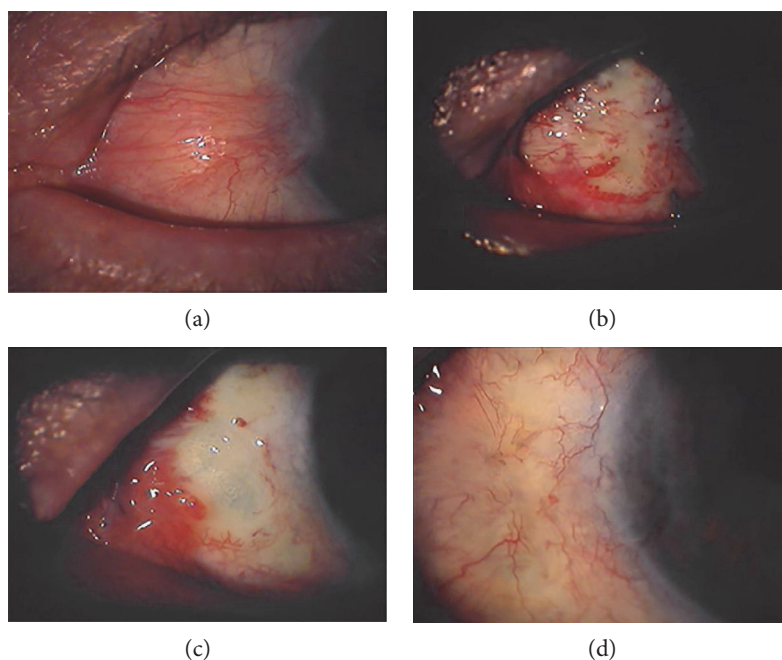


FIGURE 5: Results of application of subconjunctival bevacizumab injections prior and after pterygium surgery with bare sclera technique: (a) preoperative status, (b) 1 day after surgery (1 week after first bevacizumab injection), (c) 1 day after second bevacizumab injection, and (d) 6-month follow-up.

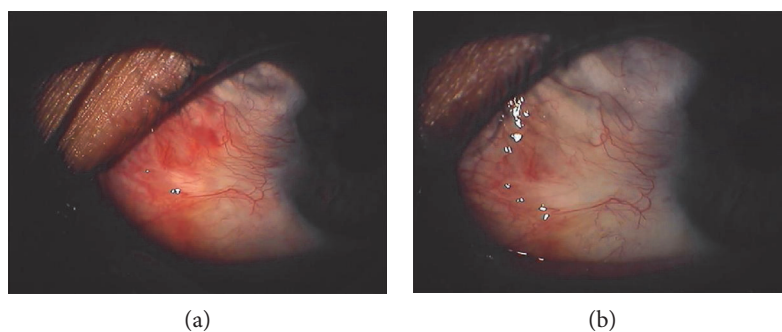


FIGURE 6: Modifications in lesion vascularization after first subconjunctival bevacizumab injection. (a) Preoperative status and (b) one week after bevacizumab injection.

effect rate if compared with the application of mitomycin C. Moreover, the selection of a bare scleral procedure associated with subconjunctival bevacizumab injections as a first-step treatment may prevent the complications associated with other surgical techniques that can still be easily applied, at a later time, in case of failure of the first approach or wide-sized postoperative defects. However, in case of conjunctival autograft or amniotic membrane failure, reintervention may lead to greater technical difficulties.

The mechanism of pterygium recurrence is still not fully clear, but VEGF and neovascularization play a crucial role in its development. The surgeon must take into consideration many factors in order to lower the risk of recurrence as much as possible. Further investigations are needed to comprehend the real efficacy and limits of an adjunctive therapy with subconjunctival bevacizumab injections. In fact, there is still little experience in the application of bevacizumab as adjunctive treatment to surgical pterygium removal; thus,

its recommendation as a first-line therapy is still controversial. Anyhow, repeated subconjunctival bevacizumab injections might prove to be an alternative possibility and effective adjuvant treatment in pterygium excision surgery, expanding the armaments at our disposal, in the management of recurrent episodes. Further surveys on genetic polymorphisms can define the difference in treatment response among different individuals. If novel evidence is found, it would be possible to foretell the efficacy of antiangiogenic therapies and anticipate the results after their administration.

### Ethical Approval

All procedures in this study concerning the authors' conduction and documentation were performed in conformity with the ethical principles set out in the Helsinki Declaration and its revisions. This trial has been approved by the Internal Pharmaceutical Board of San Luigi Gonzaga University

Hospital (University of Turin) on 26 November 2015 (reference no. 7/2015).

## Consent

Consent to participate was obtained in written form and has been registered for all subjects of this study.

## Conflicts of Interest

The authors declare that there is no conflict of interest regarding the publication of this paper.

## References

- [1] W. Tasman and E. A. Jaeger, *Duane's Clinical Ophthalmology*, vol. 6p. 35, Lippincott Williams and Wilkins, Philadelphia, 2002.
- [2] D. J. Moran and F. C. Hollows, "Pterygium and ultraviolet radiation: a positive correlation," *The British Journal of Ophthalmology*, vol. 68, no. 5, pp. 343–346, 1984.
- [3] M. Aspiotis, E. Tsanou, S. Gorezis et al., "Angiogenesis in pterygium: study of microvessel density, vascular endothelial growth factor, and thrombospondin-1," *Eye (London, England)*, vol. 21, no. 8, pp. 1095–1101, 2007.
- [4] L. Kria, A. Ohira, and T. Amemiya, "Immunohistochemical localization of basic fibroblast growth factor, platelet derived growth factor, transforming growth factor-beta and tumor necrosis factor-alpha in pterygium," *Acta Histochemica*, vol. 98, no. 2, pp. 195–201, 1996.
- [5] J. Mauro and C. S. Foster, "Pterygia: pathogenesis and the role of subconjunctival bevacizumab in treatment," *Seminars in Ophthalmology*, vol. 24, no. 3, pp. 130–134, 2009.
- [6] H. Hosseini, M. Nejabat, and M. R. Khalili, "Bevacizumab (Avastin) as a potential novel adjunct in the management of pterygia," *Medical Hypotheses*, vol. 69, no. 4, pp. 925–927, 2007.
- [7] P. Prabhasawat, N. Tesavibul, K. Leelapatranura, and T. Phonjan, "Efficacy of subconjunctival 5-fluorouracil and triamcinolone injection in impending recurrent pterygium," *Ophthalmology*, vol. 113, no. 7, pp. 1102–1109, 2006.
- [8] J. Frucht-Pery, C. S. Siganos, and M. Ilsar, "Intraoperative application of topical mitomycin C for pterygium surgery," *Ophthalmology*, vol. 103, no. 4, pp. 674–677, 1996.
- [9] M. J. Maldonado, J. Cano-Parra, A. Navea-Tejerina, A. L. Cisneros, E. Vila, and J. L. Menezo, "Inefficacy of low-dose intraoperative fluorouracil in the treatment of primary pterygium," *Archives of Ophthalmology*, vol. 113, no. 11, pp. 1356–1357, 1995.
- [10] R. P. Manzano, G. A. Peyman, P. Khan et al., "Inhibition of experimental corneal neovascularisation by bevacizumab (Avastin)," *The British Journal of Ophthalmology*, vol. 91, no. 6, pp. 804–807, 2007.
- [11] P. C. Wu, H. K. Kuo, M. H. Tai, and S. J. Shin, "Topical bevacizumab eyedrops for limbal-conjunctival neovascularization in impending recurrent pterygium," *Cornea*, vol. 28, no. 1, pp. 103–104, 2009.
- [12] D. T. Tan, S. P. Chee, K. B. Dear, and A. S. Lim, "Effect of pterygium morphology on pterygium recurrence in a controlled trial comparing conjunctival autografting with bare sclera excision," *Archives of Ophthalmology*, vol. 115, no. 10, pp. 1235–1240, 1997.
- [13] P. A. Jaros and V. P. DeLuise, "Pingueculae and pterygia," *Survey of Ophthalmology*, vol. 33, no. 1, pp. 41–49, 1988.
- [14] K. R. Kenyon, M. D. Wagoner, and M. E. Hettinger, "Conjunctival autograft transplantation for advanced and recurrent pterygium," *Ophthalmology*, vol. 92, no. 11, pp. 1461–1470, 1985.
- [15] S. Lewallen, "A randomized trial of conjunctival autografting for pterygium in the tropics," *Ophthalmology*, vol. 96, no. 11, pp. 1612–1614, 1988.
- [16] M. Ozdemir, "Conjunctival Z-plasty for pterygium: comparison with conjunctival autografting," *European Journal of General Medicine*, vol. 5, no. 2, pp. 84–89, 2008.
- [17] H. W. Pan, J. X. Zhong, and C. X. Jing, "Comparison of fibrin glue versus suture for conjunctival autografting in pterygium surgery: a meta-analysis," *Ophthalmology*, vol. 118, no. 6, pp. 1049–1054, 2011.
- [18] A. Katbaab, H. R. Anvari Ardekani, H. Khoshniyat, and H. R. Jahadi Hosseini, "Amniotic membrane transplantation for primary pterygium surgery," *J. Ophthalmic Vis. Res.*, vol. 3, no. 1, pp. 23–27, 2008.
- [19] F. Segev, S. Jaeger-Roshu, N. Gefen-Carmi, and E. I. Assia, "Combined mitomycin C application and free flap conjunctival autograft in pterygium surgery," *Cornea*, vol. 22, no. 7, pp. 598–603, 2003.
- [20] J. Frucht-Pery, F. Raiskup, M. Ilsar, D. Landau, F. Orucov, and A. Solomon, "Conjunctival autografting combined with low-dose mitomycin C for prevention of primary pterygium recurrence," *American Journal of Ophthalmology*, vol. 141, no. 6, pp. 1044–1050, 2006.
- [21] Y. A. Katircioğlu, U. E. Altıparmak, and S. Duman, "Comparison of three methods for the treatment of pterygium: amniotic membrane graft, conjunctival autograft and conjunctival autograft plus mitomycin C," *Orbit*, vol. 26, no. 1, pp. 5–13, 2007.
- [22] K. S. Zaky and Y. M. Khalifa, "Efficacy of preoperative injection versus intraoperative application of mitomycin in recurrent pterygium surgery," *Indian Journal of Ophthalmology*, vol. 60, no. 4, pp. 273–276, 2012.
- [23] R. Chen, G. Huang, S. Liu, W. Ma, X. Yin, and S. Zhou, "Limbal conjunctival versus amniotic membrane in the intraoperative application of mitomycin C for recurrent pterygium: a randomized controlled trial," *Graefe's Archive for Clinical and Experimental Ophthalmology*, vol. 255, no. 2, pp. 375–385, 2017.
- [24] T. Walkow, J. Daniel, C. H. Meyer, E. B. Rodrigues, and S. Mennel, "Long-term results after bare sclera pterygium resection with excimer smoothing and local application of mitomycin C," *Cornea*, vol. 24, no. 4, pp. 378–381, 2005.
- [25] Q. Hu, Y. Qiao, X. Nie, X. Cheng, and Y. Ma, "Bevacizumab in the treatment of pterygium: a meta-analysis," *Cornea*, vol. 33, no. 2, pp. 154–160, 2014.
- [26] A. Shenasi, F. Mousavi, S. Shoa-Ahari, B. Rahimi-Ardabili, and R. F. Fouladi, "Subconjunctival bevacizumab immediately after excision of primary pterygium: the first clinical trial," *Cornea*, vol. 30, no. 11, pp. 1219–1222, 2011.
- [27] M. R. Razeghinejad, H. Hosseini, F. Ahmadi, F. Rahat, and H. Eghbal, "Preliminary results of subconjunctival bevacizumab in primary pterygium excision," *Ophthalmic Research*, vol. 43, no. 3, pp. 134–138, 2010.
- [28] P. Singh, L. Sarkar, H. S. Sethi, and V. S. Gupta, "A randomized controlled prospective study to assess the role of

subconjunctival bevacizumab in primary pterygium surgery in Indian patients,” *Indian Journal of Ophthalmology*, vol. 63, no. 10, pp. 779–784, 2015.

- [29] A. Nava-Castañeda, O. Olvera-Morales, C. Ramos-Castellon, L. Garnica-Hayashi, and Y. Garfias, “Randomized, controlled trial of conjunctival autografting combined with subconjunctival bevacizumab for primary pterygium treatment: 1-year follow-up,” *Clinical and Experimental Ophthalmology*, vol. 42, no. 3, pp. 235–241, 2014.
- [30] M. Ozsutcu, E. Ayintap, J. C. Akkan, A. Koytak, and C. Aras, “Repeated bevacizumab injections versus mitomycin C in rotational conjunctival flap for prevention of pterygium recurrence,” *Indian Journal of Ophthalmology*, vol. 62, no. 4, pp. 407–411, 2014.
- [31] S. Grisanti, S. Biester, S. Peters et al., “Intracameral bevacizumab for iris rubeosis,” *American Journal of Ophthalmology*, vol. 142, no. 1, pp. 158–160, 2006.
- [32] T. U. Krohne, N. Eter, F. G. Holz, and C. H. Meyer, “Intraocular pharmacokinetics of bevacizumab after a single intravitreal injection in humans,” *American Journal of Ophthalmology*, vol. 146, no. 4, pp. 508–512, 2008.
- [33] H. M. Marey and A. F. Ellakwa, “Intravitreal bevacizumab with or without mitomycin C trabeculectomy in the treatment of neovascular glaucoma,” *Clinical Ophthalmology*, vol. 5, pp. 841–845, 2011.
- [34] M. R. Fallah Tafti, K. Khosravifard, M. Mohammadpour, M. N. Hashemian, and M. Y. Kiarudi, “Efficacy of intraslesional bevacizumab injection in decreasing pterygium size,” *Cornea*, vol. 30, no. 2, pp. 127–129, 2011.