

AperTO - Archivio Istituzionale Open Access dell'Università di Torino

Transanal endoscopic microsurgery for rectal cancer: T1 and beyond? An evidence-based review

This is the author's manuscript

Original Citation:

Availability:

This version is available <http://hdl.handle.net/2318/1611928> since 2016-11-14T16:04:33Z

Published version:

DOI:10.1007/s00464-016-4818-9

Terms of use:

Open Access

Anyone can freely access the full text of works made available as "Open Access". Works made available under a Creative Commons license can be used according to the terms and conditions of said license. Use of all other works requires consent of the right holder (author or publisher) if not exempted from copyright protection by the applicable law.

(Article begins on next page)

This is the author's final version of the contribution published as:

Allaix, Marco E; Arezzo, Alberto; Morino, Mario. Transanal endoscopic microsurgery for rectal cancer: T1 and beyond? An evidence-based review. SURGICAL ENDOSCOPY. 30 (11) pp: 4841-4852.
DOI: 10.1007/s00464-016-4818-9

The publisher's version is available at:

<http://link.springer.com/10.1007/s00464-016-4818-9>

When citing, please refer to the published version.

Link to this full text:

<http://hdl.handle.net/2318/1611928>

Transanal endoscopic microsurgery for rectal cancer: T1 and beyond? An evidence-based review

- Marco E. Allaix, Alberto Arezzo, Mario Morino
- Department of Surgical Sciences University of Torino Turin Italy

Abstract

Background

The last three decades have witnessed significant improvements in the diagnosis, staging and treatment of rectal cancer leading to a more tailored approach. One of the most clinically relevant advances in this field is represented by transanal endoscopic microsurgery (TEM). Several studies have investigated its role in the treatment of rectal cancer. However, evidence-based recommendations are limited. The aim of this report is to provide an evidence-based review of current indications, controversies and future perspectives of TEM in the management of rectal cancer.

Methods

A review of the literature has been performed in PubMed/Medline electronic databases and the Cochrane Library. Quality of evidence was evaluated according to the GRADE system.

Results

TEM allows to perform a more accurate en bloc full-thickness local excision of rectal tumors than transanal excision. TEM alone seems to provide similar oncologic results in selected T1sm1 N0 rectal cancers to those achieved by rectal resection and total mesorectal excision (TME), without impairing anorectal function. The oncologic outcomes of neoadjuvant therapy followed by TEM for selected T2 N0 rectal cancers are promising, but this approach is still under evaluation. A word of caution comes from the increased rate of suture dehiscence and rectal pain after TEM. TEM is a promising tool for the surgical treatment of locally advanced rectal cancer as a platform for transanal TME.

Conclusions

Selected T1 rectal cancers with favorable features may be effectively treated with TEM without jeopardizing long-term oncologic outcomes. The lack of adequate lymphadenectomy represents the main concern of this approach for the treatment of rectal cancer. Several approaches are under evaluation to overcome this limitation.

Keywords

Evidence based Transanal endoscopic microsurgery Transanal endoscopic operation Transanal minimally invasive surgery Full-thickness excision Rectal cancer Lymph nodes Chemoradiation therapy Total mesorectal excision Natural orifice transluminal endoscopic surgery

The widespread introduction of screening programs has led to a significant increase in the early detection of rectal cancers. In addition, major improvements in diagnosis, staging and treatment modalities of rectal cancer have occurred over the last 20 years. As a consequence, the interest in multimodal organ-preserving strategies in patients with early rectal tumors, including the use of transanal endoscopic microsurgery (TEM) and (chemo)radiation therapy (CRT), is rapidly increasing.

Abdominal rectal resection combined with TME is the current surgical standard of care for the treatment of rectal cancer. However, postoperative morbidity rates are high [1] and functional sequelae are common [2, 3]. During the last 20 years, several studies have challenged the role of local excision for the treatment of T1 rectal cancer. TEM is a minimally invasive procedure that allows to perform a full-thickness *en bloc* local excision of a rectal tumor down to the perirectal fatty tissue and to suture the rectal defect. It is performed under general or spinal anesthesia with very limited postoperative morbidity and mortality [4–6]. The role of TEM for the treatment of rectal cancer is controversial because of the lack of adequate lymphadenectomy. The current evidence supports the use of TEM with a curative intent only in selected T1 rectal cancers [7, 8], while TEM alone for the treatment of more advanced rectal cancers should be considered a compromise [7]. Recently, some reports have been published showing that neoadjuvant CRT followed by TEM in selected T2 N0 rectal cancer patients responding to the neoadjuvant therapy reproduces the results of total mesorectal excision (TME) [9]. In addition, there is increasing research on natural orifice transluminal endoscopic surgery (NOTES) and the potential role of TEM as platform for the treatment of locally advanced rectal cancer through a transanal approach [10].

Even though many studies have addressed the role of TEM in the treatment of rectal cancer, evidence-based recommendations are lacking. This report aims to provide an evidence-based review of indications, controversies and future perspectives of TEM in the management of rectal cancer.

Literature search

The critical appraisal of the literature was performed searching the electronic PubMed/Medline databases and the Cochrane Library for articles published between January 1985 and January 2016 using the following medical subject headings (MeSH) and free-text words alone or in combination: “transanal endoscopic microsurgery”, “transanal excision”, “full thickness excision”, “early rectal cancer” “T1 rectal cancer” “T2 rectal cancer”, “radical resection”, “total mesorectal excision”, “transanal”, “laparoscopic”, “neoadjuvant chemoradiation therapy”, “complications”, “peritoneal perforation”, “function”, “quality of life”, “Natural Orifice Transluminal Endoscopic Surgery”, “Transanal Minimally Invasive Surgery”, “TAMIS”; “Transanal Endoscopic Operations”, “TEO”, “endoscopic posterior mesorectal resection”, “sentinel lymph node”.

Study selection

The literature search was performed independently by two authors (MEA and AA) and was limited to articles published in English language. Reference lists from the included articles were manually checked, and additional studies were included when appropriate. Studies were included if they reported on TEM for the treatment of rectal cancer. When multiple publications on the same data from a single institution were retrieved, the most recent study was considered. The following data were extracted from each publication: year of publication, study design, number of patients

included, postoperative morbidity and mortality, and oncologic outcomes. The series considering both polyp and cancer patients were included in this review only if data regarding cancer patients were reported separately. The study selection process is reported in Fig. 1.

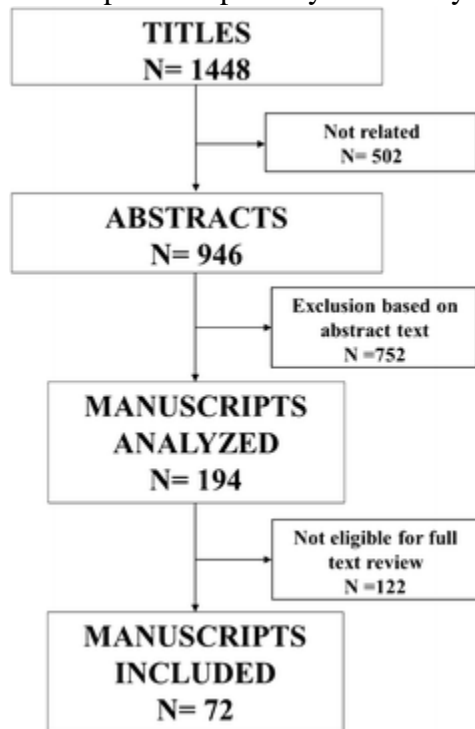


Fig. 1

Flowchart diagram of the study selection

Evaluation of evidence and recommendation

Levels of evidence and grades of recommendation are evaluated according to the GRADE system (<http://www.gradeworkinggroup.org/index.htm>) [11, 12].

TEM for rectal cancer: current indications

Several studies have compared the surgical outcomes of patients undergoing TEM or transanal excision for T1 N0 rectal cancers, showing that local excision by full-thickness TEM is burdened by significantly lower local recurrence rates than transanal local excision performed with retractors, mainly due to lower rates of fragmented resections secondary to accurate dissection of the rectal wall [13]. For instance, Langer et al. [14] retrospectively reviewed the pathological results of 38 T1 rectal cancer patients: 18 patients received a transanal excision while 20 patients underwent a TEM procedure. They found that the rates of positive or indeterminate resection margins were higher after transanal excision than TEM (37 vs. 19 %, positive; 16 vs. 5 %, indeterminate; $P = 0.001$). Similar results were reported by Christoforidis et al. [15]. They compared 42 stage 1 rectal cancer patients who had undergone a TEM procedure and 129 stage 1 rectal cancer patients who were treated by transanal excision. Positive resection margins were more frequently detected after transanal excision than TEM (16 vs. 2 %; $P = 0.017$). An en bloc resection was performed in all patients in the TEM group, while fragmented specimens were obtained in 9 % of patients after transanal excision.

A randomized controlled trial, six comparative non-randomized studies [14, 16–21] and three systematic reviews and meta-analyses [22–24] have assessed short-term and long-term oncologic

outcomes in T1 rectal cancer patients treated by TEM or rectal resection with TME. Significantly lower morbidity (8.2 vs. 47.2 %; $P = 0.01$) and mortality (0 vs. 3.68 %; $P = 0.01$) rates and shorter hospital stay were reported after TEM than TME [22] (Table 1). Overall, TEM was associated with higher local recurrence rates than TME. However, no significant differences in oncologic outcomes were observed in the studies [17, 18] that specifically analyzed patients with “low-risk” T1 carcinoma according to Hermanek criteria [25]. Heintz et al. [17] reported similar local recurrence rates between patients who had a TEM or TME for a T1 “low-risk” cancer (4 vs. 3 %, respectively), while TEM was burdened by higher local recurrence rates than TME in patients with “high-risk” rectal cancer (33 vs. 18 %). Lee et al. [18] reported similar local recurrence rates in 52 patients treated by TEM and in 17 patients who had undergone rectal resection with TME for well or moderately differentiated rectal carcinomas (4 vs. 0 %; $P = 0.95$) (Table 2).

Table 1

Early morbidity and mortality after transanal endoscopic microsurgery for T1 rectal cancer

Reference	Type of study	No. of patients	Postoperative morbidity	Postoperative mortality	Quality of evidence
Winde et al. [16]	RCT	24 TEM	TEM < RR	TEM = RR (0 %)	High
		26 RR			
Heintz et al. [17]	RET	58 TEM	TEM < RR	TEM < RR	Moderate
		45 RR			
Lee et al. [18]	RET	52 TEM	TEM < RR	TEM = RR (0 %)	Moderate
		17 RR			
Langer et al. [14]	RET	20 TEM	TEM < RR	TEM < RR	Low
		18 RR			
Ptok et al. [19]	RET	35 TEM	TEM < RR	TEM = RR (0 %)	Moderate
		359 RR			
de Graaf et al. [20]	PRO	80 TEM	TEM < RR	TEM < RR	High
		75 RR			
Palma et al. [21]	RET	34 TEM	TEM < RR	TEM < RR	Low
		17 RR			
Wu et al. [22]	MET	216 TEM	TEM < RR	TEM < RR	High
		181 RR			

RCT randomized controlled trial, *RET* retrospective, *PRO* prospective, *MET* meta-analysis, *TEM* transanal endoscopic microsurgery, *RR* rectal resection

Table 2

Oncologic outcomes after transanal endoscopic microsurgery (TEM) for T1 rectal cancer: TEM versus rectal resection

Reference	Type of study	No. of patients	5-year LR rate	5-year survival	Quality of evidence
Winde et al. [16]	RCT	24 TEM 26 RR	TEM = RR	TEM = RR	High
Heintz et al. [17] ^a	RET	46 TEM 34 RR	TEM = RR	TEM = RR	Moderate
Heintz et al. [17] ^b	RET	12 TEM 11 RR	TEM > RR	TEM = RR	Low
Lee et al. [18] ^a	RET	52 TEM 17 RR	TEM = RR	TEM = RR	Moderate
Langer et al. [14]	RET	20 TEM 18 RR	TEM > RR	TEM = RR	Low
Ptok et al. [19]	RET	35 TEM 359 RR	TEM > RR	TEM = RR	Moderate
de Graaf et al. [20]	PRO	80 TEM 75 RR	TEM > RR	TEM = RR	Moderate
Palma et al. [21]	RET	34 TEM 17 RR	TEM > RR	TEM = RR	Low
Lu et al. [24]	MET	303 TEM 557 RR	TEM > RR	TEM = RR	Moderate

RCT randomized controlled trial, *RET* retrospective, *PRO* prospective, *TEM* transanal endoscopic microsurgery, *RR* rectal resection, *LR* local recurrence

^aLow-risk T1 rectal cancer

^bHigh-risk T1 rectal cancer

Submucosal tumor invasion, tumor diameter, lymphovascular invasion and resection margin clearance are the strongest prognostic factors for long-term survival in rectal cancer patients with no preoperative evidence of mesorectal lymph node metastases treated by local excision [7, 8]. Bach et al. [7] used prospectively gathered data from 21 centers treating 487 rectal cancer patients by TEM aiming to identify risk factors associated with local recurrence after TEM and to develop a predictive model for risk stratification. A total of 253 patients had a definitive diagnosis of pT1 rectal cancer. T1 rectal cancers with a submucosal tumor invasion <1000 μ (T1sm1) had the lowest risk of recurrence, while similar recurrence rates were observed for sm2–3 T1 and T2 rectal cancers. As the maximum tumor diameter increased by 1 cm, the risk of recurrence increased by 18 %; the presence of lymphovascular invasion increased the risk of recurrence by a factor of 1.86. Local recurrence rate was <5 % for pT1 Sm1 rectal cancer with no lymphovascular invasion and up to 3 cm in diameter.

Even though TEM was initially conceived for the treatment of tumors located in the extraperitoneal rectum, there is increasing evidence that a full-thickness TEM can be offered also to patients with intraperitoneal rectal cancers, with no increased morbidity or mortality [26–31]. The learning curve and the experience of the surgeon are two main factors that influence the treatment strategy to be adopted when the peritoneum is entered [32]. Very few data are available about long-term survival in patients who had a peritoneal entry during TEM. Baatrup et al. [28] reported the oncologic outcomes of 22 patients with a median follow-up of 36 (range 3–164) months: one pT1 patient (7 %) and one pT2 patient (25 %) developed a local recurrence, while three patients developed distant metastases. In our series, all pT1 rectal cancer patients were disease free over a median follow-up period longer than 4 years [29]. Similar results were reported by others [31].

Anorectal function and quality of life are not significantly impaired after TEM. While anal resting and squeeze pressures decrease at 3 months after surgery, they return to baseline values within 6–12 months. Similarly, anorectal manometry performed at 3 months after surgery shows a transient reduction in rectal sensitivity thresholds that might be associated with urgency and slight increase in the Wexner score for fecal continence, which usually returns to preoperative values within 1 year after surgery. At 12 months after TEM, most patients report a high level of satisfaction in terms of quality of life, which is still present at 5-year follow-up [33].

Only a few small retrospective studies have compared quality of life after TEM and TME in T1 rectal cancer patients [34, 35]. Doornebosch et al. [34] compared 31 T1 rectal cancer patients who had undergone TEM with 31 sex- and age-matched 31 T+N0 rectal cancer patients undergoing sphincter saving rectal resection with TME without a diverting ileostomy. Six TME patients underwent neoadjuvant radiation therapy. All patients were disease free at the time of questionnaire mailing. The questionnaires used were the EuroQol EQ-5D, EQ-VAS, EORTC QLQ-C30 and EORTC QLQ-CR38. The median time interval between surgery and the evaluation was 28 months (range 5–91 months). There were no differences in quality of life from the patients' and social perspective between the groups. Defecation problems were reported more frequently after TME than TEM; a trend toward worse sexual function was observed after TME than after TEM, mainly in male patients.

Lezoche et al. [35] evaluated quality of life by using European Organization for Research and Treatment of Cancer (EORTC) QLQ-C30 and QLQ-C38 questionnaires preoperatively and then 1, 6 and 12 months after surgery in 17 patients treated by TEM and in 18 patients who had undergone laparoscopic TME. While TEM adversely impaired quality of life only in the first postoperative month, functional sequelae were reported at 6 months after laparoscopic TME. Further large, prospective studies with longer follow-up are needed to confirm these preliminary findings (Table 3).

Table 3

Functional outcomes after transanal endoscopic microsurgery for T1 rectal cancer

Reference	Type of study	No. of patients	Follow-up	Outcomes	Quality of evidence
Allaix et al. [33]	PRO	100 TEM	Preop, 3, 12, 60 months	Postop = Preop	High
Doornebosch et al. [34]	RET	31 TEM 31 RR	28 (5–91) months ^a	TEM > RR	Moderate

Reference	Type of study	No. of patients	Follow-up	Outcomes	Quality of evidence
Lezoche et al. [35]	PRO	17 TEM 18 RR	Preop, 1, 6, 12 months postop	TEM > RR	Moderate

RE retrospective, *PRO* prospective, *TEM* transanal endoscopic microsurgery, *RR* rectal resection

^aMedian and range

In conclusion, the evidence currently available (Table 4) suggests that:
Table 4

Transanal endoscopic microsurgery for rectal cancer: quality of evidence and strength of recommendations according to the GRADE system

Statement	Quality of evidence	Strength of recommendations
TEM allows to perform a more accurate en bloc full-thickness local excision of rectal tumors than transanal excision	High	Strong
Morbidity and mortality rates are significantly lower after TEM than rectal resection with TME	High	Strong
TEM alone does not impair survival in “low-risk” T1 N0 rectal cancers	Moderate	Weak
TEM does not impair anorectal function and quality of life	High	Strong
The oncologic outcomes of neoadjuvant (chemo)radiation therapy followed by TEM for selected T2 N0 rectal cancers are promising, but this approach is still under evaluation and should be proposed only in the setting of clinical trials until these results are confirmed by further large prospective randomized trials	Moderate	Weak
The use of neoadjuvant (chemo)radiation therapy is associated with increased rate of suture dehiscence and rectal pain after TEM	Moderate	Strong
Patients with unfavorable pathological features in the TEM specimen who undergo rectal resection with TME are at higher risk of abdominoperineal resection	Moderate	Weak

TEM transanal endoscopic microsurgery, *TME* total mesorectal excision

1. (a)

TEM is the procedure of choice for local excision of selected rectal cancers (*quality of evidence: HIGH; strength of recommendation: STRONG*)

2. (b)

morbidity and mortality rates are significantly lower after TEM than rectal resection with TME (*quality of evidence: HIGH; strength of recommendation: STRONG*);

3. (c)

local excision by TEM alone in selected “low-risk” T1 rectal cancer patients achieves long-term survival that is similar to that achieved after TME (*quality of evidence: MODERATE; strength of recommendation: WEAK*);

4. (d)

“high-risk” T1 rectal cancer should undergo rectal resection and TME (*quality of evidence: HIGH; strength of recommendation: STRONG*);

5. (e)

anorectal function and quality of life after TEM are not impaired (*quality of evidence: HIGH; strength of recommendation: STRONG*).

TEM for rectal cancer: controversies

The main challenge of TEM as surgical procedure for the treatment of rectal cancer is the inadequacy in the assessment of perirectal lymph node involvement. The risk of lymph node metastases varies according to the staging of the tumor, being 0–3 % for T1 sm1, 15 % for T1 sm2–3 and about 25 % for T2 rectal cancers [36, 37]. Therefore, the preoperative staging by endoscopic ultrasound (EUS) and magnetic resonance imaging (MRI) is key for the proper selection of patients for a TEM procedure. EUS and MRI should be considered complementary imaging modalities for the preoperative staging of rectal cancer [38]. EUS is the most accurate imaging modality for the assessment of early tumor invasion of the rectal wall (T1 vs. T2 rectal cancers). However, EUS is highly operator dependent and has low accuracy in differentiating between T1 sm1, sm2 and sm3 substages, with a risk of under staging in 15–20 % of patients [39–41].

When poor prognostic features are found at the pathologic evaluation of the TEM specimen, abdominal rectal resection with TME is recommended to reduce the risk of recurrence [42–47]. While “low-risk” T1 rectal cancer patients treated by TEM have excellent oncologic outcomes, “high-risk” T1 and T2 rectal cancer patients have a significantly higher risk of recurrence after TEM alone than after rectal resection and TME. For instance, Borschitz et al. [44] studied recurrence rates and 10-year cancer-free survival in 105 pT1 cancer patients treated by TEM. Patients were grouped into two groups: “low-risk” cancers and “high-risk.” The TEM procedure was followed by reoperation for the presence of unfavorable histologic features (R_1 , R_x , $R \leq 1$ mm, high-risk situation) after TEM in 21 patients. Local recurrence rates were 6 % after R_0 TEM in the low-risk cancer patients and 39 % in the high-risk group of patients. The recurrence rate was significantly reduced to 6 % in those high-risk patients who underwent an immediate reoperation ($P = 0.015$).

Even though a previous TEM does not affect long-term survival of these patients, the risk of abdominoperineal resection (APR) after full thickness transanal excision is increased. For instance, Levic et al. [48] compared in a case-matched study the short-term outcomes of 25 patients who had undergone TME following TEM and 25 patients who were treated by primary TME for early rectal cancer. No significant differences were reported in terms of intraoperative outcomes. The APR rate was 44 % in both groups. In 2013, we compared the perioperative outcomes in 17 patients treated by laparoscopic TME following a full-thickness TEM with 34 well matched patients who underwent primary laparoscopic TME for extraperitoneal rectal cancer [49]. The results of this study showed that laparoscopic TME after TEM is safe and has similar intraoperative and postoperative morbidity when compared to primary laparoscopic TME. However, we observed a significant increase in APR (41.2 vs. 11.7 %; $P = 0.028$) after a TEM procedure. TEM was the only independent predictor ($P = 0.046$). Indeed, the pelvic dissection during a TME is much more challenging due to the fibrotic scar in the rectal wall and inside the perirectal fatty tissue secondary to mesorectal inflammation following the TEM procedure [50], and a low colorectal or a coloanal anastomosis is sometimes technically not feasible. Currently, there are no data regarding the best timing for a TME after a full-thickness TEM.

To reduce postoperative morbidity and mortality associated with rectal resection and TME without jeopardizing long-term survival, a multimodal organ-preserving approach including TEM and neoadjuvant CRT has been recently proposed in selected rectal cancer patients. Neoadjuvant CRT induces reduction in tumor size and sterilizes mesorectal lymph nodes, leading to a pathological complete response (pCR) in up to 30 % of patients [51]. Local recurrence is strictly related to the pathologic response to neoadjuvant treatment, with the best local control achieved in patients with pCR and ypT1 [51, 52]. Unfortunately, there are no clinical methods to reliably identify before surgery those patients who have achieved a pCR [53–55]. Local excision has been proposed as an option for an accurate assessment of the pathological response. However, main concern of this strategy is that only the rectal wall is excised while mesorectal lymph nodes are not removed, and mesorectal lymph node metastases are found in up to 27 % of ypT0 rectal cancers undergoing TME [56].

During the last 10 years, several studies have been conducted aiming to select rectal cancer patients for neoadjuvant treatment followed by local excision, thus avoiding an “unnecessary” abdominal rectal resection with the related morbidity [57–60]. For instance, Bhangu et al. [58] have reported cancer-specific outcomes of 7378 patients undergoing local excision and 36,116 patients undergoing major rectal resection for T0-2N0M0 rectal cancer included in the SEER (Surveillance, Epidemiology, and End Results) database. They showed that local excision was equivalent to abdominal surgery for the treatment of T0–1 rectal cancers, while the results were disappointing in T2 rectal cancer patients. The subgroup analysis of T2 patients who had undergone preoperative therapy showed similar oncologic outcomes when compared with those who had abdominal surgery. To date, a few studies have compared the outcomes after TEM and TME for T2 N0 rectal cancers [9, 18, 61, 62]. For instance, Lezoche et al. [9] have randomized 100 patients with a rectal cancer preoperatively staged as T2 N0 M0, G1–2, smaller than 3 cm and located within 6 cm of the anal verge, to TEM or rectal resection and TME after long-course neoadjuvant CRT. Overall, the median duration of follow-up was 9.6 years (range 5.5–12.4 years in the TEM group, and 4.7–12.3 years in the TME group). In both groups, all local recurrence or distant metastases occurred in poor or non-responder patients to neoadjuvant CRT. The cancer-related and overall survival rates were similar between TEM and TME patients: 89 vs. 94 % ($P = 0.687$) and 72 vs. 80 % ($P = 0.609$).

Several studies have reported morbidity rates related to the rectal wound in patients undergoing neoadjuvant treatment followed by TEM up to 70 % [63–66]. Marks et al. [63] included in a

retrospective study 62 rectal cancer patients: 43 underwent neoadjuvant radiation therapy and 19 were treated with TEM alone. There was no mortality. The overall morbidity rate was significantly higher in the radiation therapy group than in the TEM group (33 vs. 5.3 %; $P < 0.05$). A total of 11 patients experienced a rectal wound complication (25.6 vs. 0 %; $P = 0.015$). Only one patient required a diverting stoma, while the other 10 patients were treated conservatively.

Perez et al. [64] reported the 30-day outcomes in 36 consecutive patients undergoing TEM with closure of the rectal wall defect at a single institution: 23 patients underwent neoadjuvant CRT followed by TEM, while 13 patients underwent TEM alone. Overall 30-day morbidity rate was 44 % for grade 2/3 complications, that occurred more frequently in patients treated by neoadjuvant therapy followed by TEM (56 vs. 23 %; $P = 0.05$). This group of patients had a higher rate of rectal suture dehiscence (70 vs. 23 %; $P = 0.03$), and risk of readmission (43 vs. 7 %; $P = 0.02$). Similarly, Coco et al. [65] compared 22 patients treated by neoadjuvant CRT followed by TEM and 25 patients who had undergone TEM alone for rectal tumors. They reported a trend toward a higher rate of overall morbidity after neoadjuvant CRT followed by TEM than TEM alone (36.4 vs. 16 %; $P = 0.114$), and suture dehiscence (22.7 vs. 4 %; $P = 0.068$).

One of the factors that may lead to rectal wall dehiscence in patients undergoing TEM after neoadjuvant radiation therapy is the suture of two irradiated tissues. However, there are no studies comparing the outcomes of closed and unclosed rectal wounds in this subgroup of patients. Further studies are needed to assess the optimal management of the rectal wall defect during TEM following neoadjuvant radiation therapy.

Some recent studies have reported poor functional outcomes after local excision following neoadjuvant radiotherapy which are similar to those observed after anterior resection and TME [65, 67, 68]. For instance, Gornicki et al. [67] retrospectively compared the functional outcomes in 44 patients undergoing neoadjuvant radiation therapy followed by full-thickness local excision for cT1 N0, cT2 N0 and borderline cT2–3 N0 G1–2 rectal cancer smaller than 3 cm with 38 patients who had undergone anterior resection alone for cT2 N0 rectal cancer. A self-administered non-validated questionnaire was sent to the patients 1 year after treatment and returned to the trial office by regular post. There were no differences in the mean number of bowel movements, occurrence of gas and fecal incontinence, clustering of bowel movements and urgency between the 2 groups of patients. Quality of life was affected by anorectal dysfunction in 38 % of patients, while sexual life was impaired in 19 % of men and 20 % of women.

Even though oncologic preliminary results are promising, this treatment strategy should be proposed only in the setting of clinical trials until long-term results of large randomized controlled trials will be available [38]. An European multicenter prospective study, Transanal Endoscopic Microsurgery After Radiochemotherapy for Rectal Cancer (CARTS), investigates the outcomes of TEM performed 8–10 weeks after preoperative long-course CRT [69]. The TREC (transanal endoscopic microsurgery and radiotherapy in early rectal cancer) [70] is an ongoing phase II open, multicenter randomized controlled trial that compares abdominal rectal resection combined with TME and short-course radiotherapy followed by delayed (8–10 weeks) TEM for early rectal cancer patients. The TREC and CARTS groups have combined their phase II protocols (STAR-TREC) to produce a single-phase III trial that will randomize patients to one of three treatments: (a) standard radical surgery, (b) short-course radiotherapy + TEM, (c) CRT and TEM.

In conclusion, the evidence currently available (Table 4) suggests that:

1. (a)

neoadjuvant chemoradiation therapy followed by TEM achieves satisfactory oncologic results in highly selected T2 N0 rectal cancers; however, it should be proposed only in the setting of clinical trials until these results are confirmed by further large prospective randomized trials (*quality of evidence: MODERATE; strength of recommendation: WEAK*);

2. (b)

neoadjuvant treatment is associated with increased rate of suture dehiscence and rectal pain after TEM (*quality of evidence: MODERATE; strength of recommendation: STRONG*);

3. (c)

radiotherapy followed by TEM might be associated with worse functional outcomes (*quality of evidence: MODERATE; strength of recommendation: WEAK*).

Transanal endoscopic microsurgery: the platforms

The transanal endoscopic operation (TEO) platform is gaining wide acceptance as a valid alternative to TEM platform. Both follow the same principles and many Authors do not differentiate between them or present series including patients operated on with both systems. A RCT comparing the results in 34 patients undergoing TEM or TEO for rectal tumors showed no significant differences in intraoperative and postoperative outcomes. TEO platform costs were significantly lower than TEM platform [71].

Another option is TAMIS (TransAnal Minimally Invasive Surgery), first developed in 2009 as an alternative to TEM for local excision of early rectal cancers to overcome the considerable cost of the TEM instrumentation and the steep learning curve of the TEM technique [72]. It seems to be gaining support in many centers. Martin-Perez et al. [73] recently reviewed the evidence about the use of TAMIS for the local excision of rectal tumors. They found 33 retrospective case series and case reports, and 3 abstracts, representing 390 TAMIS procedures. Main indications were adenomas (39 %) and cancers (53.5 %). The overall positive margins rate is 4.4 %, while specimen fragmentation rate is 4.1 %. Overall postoperative morbidity is 7.4 %. These results show the feasibility and safety of this platform in the treatment of early rectal tumors (*quality of evidence: LOW; strength of recommendation: WEAK*). However, the interpretation of these data is limited by the retrospective nature and the small sample size of the studies. To date, there are no clinical prospective studies comparing TEM and TAMIS. Only one small comparative experimental study showed a significantly faster completion of both dissection and suturing during the TEM procedure; the two approaches did not differ in accuracy in the tissue dissection [74]. The largest clinical retrospective series was published in 2013 by Albert et al. [75]: 50 patients were treated with TAMIS for adenomas ($n = 25$), carcinomas ($n = 23$) and neuroendocrine tumors ($n = 2$). The authors reported a specimen fragmentation rate of 4 % ($n = 2$) and positive margin rate of 6 % ($n = 3$). Early complication rate was 6 %; no further complications occurred after a median follow-up of 20 months.

In conclusions, TEM and TEO platforms are considered equivalent for the local treatment of rectal tumors, while clinical prospective studies comparing TEM and TAMIS are needed to evaluate the real benefits of TAMIS.

TEM for rectal cancer: new perspectives

Current research aims to increase the organ-preserving strategies and to further reduce the invasiveness of laparoscopic TME for rectal cancer. Two major fields of interest are (a) perirectal lymph node sampling in patients undergoing a TEM procedure and (b) transanal TME.

The preoperative evaluation of perirectal lymph nodes by EUS and MRI is challenging. Several approaches that combine local excision and perirectal lymph node sampling have been described, aiming to increase the accuracy in perirectal lymph node detection, and therefore overcoming the lack of lymphadenectomy during TEM.

Endoscopic posterior mesorectal excision (EPMR) performed after transanal excision for “high-risk” T1 rectal cancer is a safe procedure that allows the resection of the posterior part of the mesorectum [76]. The severity of postoperative complications after EPMR is significantly lower than transabdominal TME, the number of lymph nodes harvested is similar and no significant differences in terms of survival have been reported between the two approaches (*quality of evidence: MODERATE; strength of recommendation: WEAK*). Tarantino et al. [77] have compared morbidity and mortality in 18 consecutive patients undergoing EPMR 6 weeks after transanal excision with those in 17 patients treated by low anterior resection for T1 rectal cancer. Minor complications occurred in 3 (16.7 %) patients after EPMR and in 4 (23.5 %) patients after low anterior resection ($P = 0.691$). Major complications occurred in 2 (11.1 %) patients after EPMR and in 4 (23.5 %) patients after low anterior resection ($P = 0.402$). No significant differences were observed in the median number of lymph nodes removed: 7 (range 1–22) after EPMR and 11 (range 2–36) after low anterior resection ($P = 0.132$). Median follow-up was 23.1 (range 4–95) months after local excision and EPMR, and 58.1 (range 5–145.6) months after low anterior resection ($P = 0.199$). No patient experienced local recurrence.

EPMR in combination with TEM does not seem to affect anorectal function in the long-term period (*quality of evidence: LOW; strength of recommendation: WEAK*). Walega et al. [78] evaluated the impact of TEM followed by EPMR on the anorectal functions in 10 T1 rectal cancer patients. There were no significant differences in manometric findings and fecal continence by using the Fecal Incontinence Severity Index before and after TEM, and 1, 3, 6, 12 and 36 months after EPMR. However, further large studies with longer follow-up are needed to confirm the oncologic adequacy of this approach to rectal cancer and the impact on quality of life.

Several authors are now proposing the sentinel lymph node biopsy in patients with rectal cancer at early stages without clinical evidence of lymph node involvement or distant metastases [79]. The intraoperative detection of the sentinel lymph node may avoid more extensive surgery and the related postoperative morbidity. However, the sensitivity and specificity of the sentinel lymph node biopsy vary greatly across the several studies published in the literature, due to the tremendous diversity in patient selection, sentinel lymph node procedures, pathological techniques and heterogeneity across institutions and surgeons (*quality of evidence: LOW; strength of recommendation: WEAK*). Very recently, some new approaches to the perirectal lymph nodes have been proposed, including the nucleotide-guided mesorectal excision combined with TEM by using 99-m-technetium-marked nanocolloid injection into the peritumoral submucosa [80], and the transrectal sentinel lymph node biopsy during TEM by using indocyanine green solution and a near-

infrared camera [81]. Large studies are awaited to better clarify the indications and the oncologic implications of these procedures in combination with TEM in the treatment of rectal cancer.

The detection of predictive biomarkers of lymph node metastases might help identify rectal cancer patients who are unlikely to develop lymph node metastases and therefore may safely be offered an organ preservation approach. To date, promising results have been reported in locally advanced rectal cancer patients undergoing neoadjuvant CRT [82, 83]. Further studies are necessary to identify predictive biomarkers in the setting of earlier tumors.

In the NOTES era, transanal rectal resections (the so-called down-to-up approach) by using the rigid TEM platform or a flexible system (TAMIS) with [84] and without laparoscopic assistance [85] have been described to overcome technical limitations of the laparoscopic approach in patients with distal and bulky tumors in narrow pelvis [86]. To date, only a few small studies with short follow-up have been published [87]. The largest series comparing transanal and laparoscopic TME is that by Fernández-Hevia et al. [88]. They included into a prospective cohort 37 consecutive patients with middle or low rectal cancer treated by transanal TME assisted by laparoscopy. These patients were compared with a retrospective cohort of consecutive 37 patients of identical characteristics undergoing laparoscopic TME in the immediate chronological period. Operative time was significantly longer in the laparoscopic TME group (252 ± 50 min) than in the transanal TME group (215 ± 60 min) ($P < 0.01$), due to the fact that two surgical teams worked simultaneously during the transanal TME. Distal margin clearance was lower (1.8 ± 1.2 vs. 2.7 ± 1.7 mm; $P = 0.05$) after the laparoscopic TME than the transanal TME. The 30-day postoperative morbidity rate was slightly higher after laparoscopic TME than transanal TME even though the difference was not statistically significant (51 vs. 32 %; $P = 0.16$). Early readmission was more frequent after laparoscopic TME than transanal TME (22 vs. 6 %; $P = 0.03$).

The correct placement of the stapler distal to the rectal tumor during a laparoscopic TME can be challenging, and it might result in inadequate oncologic resection. A recent matched case-control study comparing 25 transanal TME and 25 laparoscopic TME has shown a significantly higher rate of complete mesorectum in the transanal TME group (96 vs. 72 %, $P < 0.05$). No differences were observed in the other pathological findings, including circumferential resection margin status [89].

The first case of pure NOTES procedure for mid-rectal cancer was published by Leroy et al. in 2013 [85]. They used a transanal endoscopic operation device as a surgical platform to create a viscerotomy distal to an endoluminal purse-string suture and to subsequently perform a TME using a “bottom-up” approach. The surgeon mobilized the sigmoid colon by a posterior, retroperitoneal approach, divided the colon intraperitoneally, and performed a hand-sewn, side-to-end, coloanal anastomosis. They called this approach perirectal oncologic gateway for retroperitoneal endoscopic single site surgery (PROGRESSS).

Based on the data available in the literature, transanal TME by using the TEM platform seems to be a novel promising approach to rectal cancer patients with limited access to the pelvis by laparoscopy (*quality of evidence: LOW; strength of recommendation: WEAK*). However, the clinical series published in the literature are at present too limited to draw any conclusions. Further studies are necessary to validate the feasibility and the oncologic safety of this approach. Lastly, there are few small studies assessing the potential of the application of the robotic technology to transanal endoscopic surgery [90] and TME [91], showing its safety and feasibility. More robust data are awaited before drawing any recommendation.

Conclusions

TEM is the most effective surgical option for the local excision of selected T1 rectal cancers, without jeopardizing long-term oncologic outcomes. The lack of lymphadenectomy represents the main issue of this approach. Several approaches are under evaluation to overcome this limitation. TEM is also a promising tool for the surgical treatment of locally advanced rectal cancer as a platform for transanal TME. Further studies with long-term follow-up are needed to confirm the preliminary data.

References

1. 1.

van der Pas MH, Haglind E, Cuesta MA, Fürst A, Lacy AM, Hop WC, Bonjer HJ, COLOrectal cancer Laparoscopic or Open Resection II (COLOR II) Study Group (2013) Laparoscopic versus open surgery for rectal cancer (COLOR II): short-term outcomes of a randomised, phase 3 trial. *Lancet Oncol* 14:210–218

2. 2.

Bryant CL, Lunniss PJ, Knowles CH, Thaha MA, Chan CL (2012) Anterior resection syndrome. *Lancet Oncol* 13(9):e403–e408

3. 3.

Andersson J, Abis G, Gellerstedt M, Angenete E, Angerås U, Cuesta MA, Jess P, Rosenberg J, Bonjer HJ, Haglind E (2014) Patient-reported genitourinary dysfunction after laparoscopic and open rectal cancer surgery in a randomized trial (COLOR II). *Br J Surg* 101:1272–1279

4. 4.

Allaix ME, Arezzo A, Arolfo S, Caldart M, Rebecchi F, Morino M (2013) Transanal endoscopic microsurgery for rectal neoplasms. How I do it. *J Gastrointest Surg* 17:586–592

5. 5.

Lee TG, Lee SJ (2014) Transanal single-port microsurgery for rectal tumors: minimal invasive surgery under spinal anesthesia. *Surg Endosc* 28:271–280

6. 6.

Suppiah A, Maslekar S, Alabi A, Hartley JE, Monson JR (2008) Transanal endoscopic microsurgery in early rectal cancer: time for a trial? *Colorectal Dis* 10:314–327

7. 7.

Bach SP, Hill J, Monson JR, Lane L, Merrie A, Warren B, Mortensen NJ, Association of Coloproctology of Great Britain and Ireland Transanal Endoscopic Microsurgery (TEM) Collaboration (2009) A predictive model for local recurrence after transanal endoscopic microsurgery for rectal cancer. *Br J Surg* 96:280–290

8. 8.

Morino M, Allaix ME, Caldart M, Scozzari G, Arezzo A (2011) Risk factors for recurrence after transanal endoscopic microsurgery for rectal malignant neoplasm. *Surg Endosc* 25:3683–3690

9. 9.

Lezoche E, Baldarelli M, Lezoche G, Paganini AM, Gesuita R, Guerrieri M (2012) Randomized clinical trial of endoluminal locoregional resection versus laparoscopic total mesorectal excision for T2 rectal cancer after neoadjuvant therapy. *Br J Surg* 99:1211–1218

10. 10.

Hall DJ, Farmer KC, Roth HS, Warriar SK (2014) Transanal endoscopic microsurgery colorectal anastomosis: a critical step to natural orifice colorectal surgery in humans. *Dis Colon Rectum* 57:549–552

11. 11.

Brozek JL, Akl EA, Alonso-Coello P, Lang D, Jaeschke R, Williams JW, Phillips B, Lelgemann M, Lethaby A, Bousquet J, Guyatt GH, Schünemann HJ, GRADE Working Group (2009) Grading quality of evidence and strength of recommendations in clinical practice guidelines. Part 1 of 3. An overview of the GRADE approach and grading quality of evidence about interventions. *Allergy* 64:669–677

12. 12.

Brozek JL, Akl EA, Compalati E, Kreis J, Terracciano L, Fiocchi A, Ueffing E, Andrews J, Alonso-Coello P, Meerpohl JJ, Lang DM, Jaeschke R, Williams JW Jr, Phillips B, Lethaby A, Bossuyt P, Glasziou P, Helfand M, Watine J, Afilalo M, Welch V, Montedori A, Abraha I, Horvath AR, Bousquet J, Guyatt GH, Schünemann HJ, GRADE Working Group (2011) Grading quality of evidence and strength of recommendations in clinical practice guidelines. Part 3 of 3. The GRADE approach to developing recommendations. *Allergy* 66:588–595

13. 13.

Clancy C, Burke JP, Albert M, O’Connell PR, Winter D (2015) Transanal endoscopic microsurgery versus standard transanal excision for the removal of rectal neoplasms: a systematic review and meta-analysis. *Dis Colon Rectum* 58:254–261

14. 14.

Langer C, Liersch T, Süß M, Siemer A, Markus P, Ghadimi BM, Füzesi L, Becker H (2003) Surgical cure for early rectal carcinoma and large adenoma: transanal endoscopic microsurgery (using ultrasound or electrosurgery) compared to conventional local and radical resection. *Int J Colorectal Dis* 18:222–229

15. 15.

Christoforidis D, Cho HM, Dixon MR, Mellgren AF, Madoff RD, Finne CO (2009) Transanal endoscopic microsurgery versus conventional transanal excision for patients with early rectal cancer. *Ann Surg* 249:776–782

16. 16.

Winde G, Nottberg H, Keller R, Schmid KW, Bünte H (1996) Surgical cure for early rectal carcinomas (T1). Transanal endoscopic microsurgery vs. anterior resection. *Dis Colon Rectum* 39:969–976

17. 17.

Heintz A, Mörschel M, Junginger T (1998) Comparison of results after transanal endoscopic microsurgery and radical resection for T1 carcinoma of the rectum. *Surg Endosc* 12:1145–1148

18. 18.

Lee W, Lee D, Choi S, Chun H (2003) Transanal endoscopic microsurgery and radical surgery for T1 and T2 rectal cancer. *Surg Endosc* 17:1283–1287

19. 19.

Ptok H, Marusch F, Meyer F, Koeckerling F, Gastinger I, Lippert H, Colon/Rectal Cancer (Primary Tumor) Study Group (2007) Oncological outcome of local vs radical resection of low-risk pT1 rectal cancer. *Arch Surg* 142:649–656

20. 20.

de Graaf EJ, Doornebosch PG, Tollenaar RA, Kranenburg EM-K, de Boer AC, Bekkering FC, van de Velde CJ (2009) Transanal endoscopic microsurgery versus total mesorectal excision of T1 rectal adenocarcinomas with curative intention. *Eur J Surg Oncol* 35:1280–1285

21. 21.

Palma P, Horisberger K, Joos A, Rothenhoefer S, Willeke F, Post S (2009) Local excision of early rectal cancer: is transanal endoscopic microsurgery an alternative to radical surgery? *Rev Esp Enferm Dig* 101:172–178

22. 22.

Wu Y, Wu YY, Zhu BS, Zhao K, Yang XD, Xing CG (2011) TEM and conventional rectal surgery for T1 rectal cancer: a meta-analysis. *Hepatogastroenterology* 58(106):364–368

23. 23.

Kidane B, Chadi SA, Kanters S, Colquhoun PH, Ott MC (2015) Local resection compared with radical resection in the treatment of T1N0M0 rectal adenocarcinoma: a systematic review and meta-analysis. *Dis Colon Rectum* 58:122–140

24. 24.

Lu JY, Lin GL, Qiu HZ, Xiao Y, Wu B, Zhou JL (2015) Comparison of Transanal Endoscopic Microsurgery and Total Mesorectal Excision in the treatment of T1 rectal cancer: a meta-analysis. *PLoS One* 10:e0141427. doi:10.1371/journal.pone.0141427

25. 25.

Hermanek P, Gall FP (1986) Early (microinvasive) colorectal carcinoma. Pathology, diagnosis, surgical treatment. *Int J Colorectal Dis* 1:79–84

26. 26.

Gavagan JA, Whiteford MH, Swanstrom LL (2004) Full-thickness intraperitoneal excision by transanal endoscopic microsurgery does not increase short-term complications. *Am J Surg* 187:630–634

27. 27.

Ramwell A, Evans J, Bignell M, Mathias J, Simson J (2009) The creation of a peritoneal defect in transanal endoscopic microsurgery does not increase complications. *Colorectal Dis* 11:964–966

28. 28.

Baatrup G, Borschitz T, Cunningham C, Qvist N (2009) Perforation into the peritoneal cavity during transanal endoscopic microsurgery for rectal cancer is not associated with major complications or oncological compromise. *Surg Endosc* 23:2680–2683

29. 29.

Morino M, Allaix ME, Famiglietti F, Caldart M, Arezzo A (2013) Does peritoneal perforation affect short- and long-term outcomes after transanal endoscopic microsurgery? *Surg Endosc* 27:181–188

30. 30.

Eyvazzadeh DJ, Lee JT, Madoff RD, Mellgren AF, Finne CO (2014) Outcomes after transanal endoscopic microsurgery with intraperitoneal anastomosis. *Dis Colon Rectum* 57:438–441

31. 31.

Marks JH, Frenkel JL, Greenleaf CE, D'Andrea AP (2014) Transanal endoscopic microsurgery with entrance into the peritoneal cavity: is it safe? *Dis Colon Rectum* 57:1176–1182

32. 32.

Salm R, Lampe H, Bustos A, Matern U (1994) Experience with TEM in Germany. *Endosc Surg Allied Technol* 2:251–254

33. 33.

Allaix ME, Rebecchi F, Giaccone C, Mistrangelo M, Morino M (2011) Long-term functional results and quality of life after transanal endoscopic microsurgery. *Br J Surg* 98:1635–1643

34. 34.

Doornebosch PG, Tollenaar RA, Gosselink MP, Stassen LP, Dijkhuis CM, Schouten WR, van de Velde CJ, de Graaf EJ (2007) Quality of life after transanal endoscopic microsurgery and total mesorectal excision in early rectal cancer. *Colorectal Dis* 9:553–558

35. 35.

Lezoche E, Paganini AM, Fabiani B, Balla A, Vestri A, Pescatori L, Scoglio D, D'Ambrosio G, Lezoche G (2014) Quality-of-life impairment after endoluminal locoregional resection and laparoscopic total mesorectal excision. *Surg Endosc* 28:227–234

36. 36.

Yamamoto S, Watanabe M, Hasegawa H, Baba H, Yoshinore K, Shiraishi J, Kitajima M (2004) The risk of lymph node metastasis in T1 colorectal carcinoma. *Hepatogastroenterology* 51:998–1000

37. 37.

Saraste D, Gunnarsson U, Janson M (2013) Predicting lymph node metastases in early rectal cancer. *Eur J Cancer* 49:1104–1108

38. 38.

Morino M, Risio M, Bach S, Beets-Tan R, Bujko K, Panis Y, Quirke P, Rembacken B, Rullier E, Saito Y, Young-Fadok T, Allaix ME (2015) Early rectal cancer: the European Association for Endoscopic Surgery (EAES) clinical consensus conference. *Surg Endosc* 29:755–773

39. 39.

Marusch F, Ptok H, Sahm M, Schmidt U, Ridwelski K, Gastinger I, Lippert H (2011) Endorectal ultrasound in rectal carcinoma—do the literature results really correspond to the realities of routine clinical care? *Endoscopy* 43:425–431

40. 40.

Ashraf S, Hompes R, Slater A, Lindsey I, Bach S, Mortensen NJ, Cunningham C, Association of Coloproctology of Great Britain and Ireland Transanal Endoscopic

Microsurgery (TEM) Collaboration (2012) A critical appraisal of endorectal ultrasound and transanal endoscopic microsurgery and decision-making in early rectal cancer. *Colorectal Dis* 14:821–826

41. 41.

Puli SR, Bechtold ML, Reddy JB, Choudhary A, Antillon MR, Brugge WR (2009) How good is endoscopic ultrasound in differentiating various T stages of rectal cancer? Meta-analysis and systematic review. *Ann Surg Oncol* 16:254–265

42. 42.

Baron PL, Enker WE, Zakowski MF, Urmacher C (1995) Immediate vs. salvage resection after local treatment for early rectal cancer. *Dis Colon Rectum* 38:177–181

43. 43.

Hahnloser D, Wolff BG, Larson DW, Ping J, Nivatvongs S (2005) Immediate radical resection after local excision of rectal cancer: an oncologic compromise? *Dis Colon Rectum* 48:429–437

44. 44.

Borschitz T, Heintz A, Junginger T (2006) The influence of histopathologic criteria on the long-term prognosis of locally excised pT1 rectal carcinomas: results of local excision (transanal endoscopic microsurgery) and immediate reoperation. *Dis Colon Rectum* 49:1492–1506

45. 45.

Lee WY, Lee WS, Yun SH, Shin SH, Chun HK (2007) Decision for salvage treatment after transanal endoscopic microsurgery. *Surg Endosc* 21(6):975–979

46. 46.

Borschitz T, Heintz A, Junginger T (2007) Transanal endoscopic microsurgical excision of pT2 rectal cancer: results and possible indications. *Dis Colon Rectum* 50:292–301

47. 47.

Junginger T, Goenner U, Hitzler M, Trinh TT, Heintz A, Wollschlaeger D, Brettner M (2016) Long-term oncologic outcome after transanal endoscopic microsurgery for rectal carcinoma. *Dis Colon Rectum* 59:8–15

48. 48.

Levic K, Bulut O, Hesselfeldt P, Bülow S (2013) The outcome of rectal cancer after early salvage TME following TEM compared with primary TME: a case-matched study. *Tech Coloproctol* 17:397–403

49. 49.

Morino M, Allaix ME, Arolfo S, Arezzo A (2013) Previous transanal endoscopic microsurgery for rectal cancer represents a risk factor for an increased abdominoperineal resection rate. *Surg Endosc* 27:3315–3321

50. 50.

Smart CJ, Cunningham C, Bach SP (2014) Transanal endoscopic microsurgery. *Best Pract Res Clin Gastroenterol* 28:143–157

51. 51.

O'Neill BD, Brown G, Heald RJ, Cunningham D, Tait DM (2007) Non-operative treatment after neoadjuvant chemoradiotherapy for rectal cancer. *Lancet Oncol* 8:625–633

52. 52.

Borschitz T, Wachtlin D, Möhler M, Schmidberger H, Junginger T (2008) Neoadjuvant chemoradiation and local excision for T2-3 rectal cancer. *Ann Surg Oncol* 15:712–720

53. 53.

Smith FM, Chang KH, Sheahan K, Hyland J, O'Connell PR, Winter DC (2012) The surgical significance of residual mucosal abnormalities in rectal cancer following neoadjuvant chemoradiotherapy. *Br J Surg* 99:993–1001

54. 54.

Hiotis SP, Weber SM, Cohen AM, Minsky BD, Paty PB, Guillem JG, Wagman R, Saltz LB, Wong WD (2002) Assessing the predictive value of clinical complete response to neoadjuvant therapy for rectal cancer: analysis of 488 patients. *J Am Coll Surg* 194:131–135

55. 55.

Glynn-Jones R, Hughes R (2012) Critical appraisal of the “wait and see” approach in rectal cancer for clinical complete responders after chemoradiation. *Br J Surg* 99:897–909

56. 56.

Martin ST, Heneghan HM, Winter DC (2012) Systematic review and meta-analysis of outcomes following pathological complete response to neoadjuvant chemoradiotherapy for rectal cancer. *Br J Surg* 99:918–928

57. 57.

Garcia-Aguilar J, Shi Q, Thomas CR Jr, Chan E, Cataldo P, Marcet J, Medich D, Pigazzi A, Oommen S, Posner MC (2012) A Phase II trial of neoadjuvant chemoradiation and local excision for T2N0 rectal cancer: preliminary results of the ACOSOG Z6041 trial. *Ann Surg Oncol* 19:384–391

58. 58.

Bhangu A, Brown G, Nicholls RJ, Wong J, Darzi A, Tekkis P (2013) Survival outcome of local excision versus radical resection of colon or rectal carcinoma: a Surveillance, Epidemiology, and End Results (SEER) population-based study. *Ann Surg* 258:563–569

59. 59.

Pucciarelli S, De Paoli A, Guerrieri M, La Torre G, Maretto I, De Marchi F, Mantello G, Gambacorta MA, Canzonieri V, Nitti D, Valentini V, Coco C (2013) Local excision after preoperative chemoradiotherapy for rectal cancer: results of a multicenter phase II clinical trial. *Dis Colon Rectum* 56:1349–1356

60. 60.

Shaikh I, Askari A, Ourû S, Warusavitarne J, Athanasiou T, Faiz O (2015) Oncological outcomes of local excision compared with radical surgery after neoadjuvant chemoradiotherapy for rectal cancer: a systematic review and meta-analysis. *Int J Colorectal Dis* 30:19–29

61. 61.

Allaix ME, Arezzo A, Giraudo G, Morino M (2012) Transanal endoscopic microsurgery vs. laparoscopic total mesorectal excision for T2N0 rectal cancer. *J Gastrointest Surg* 16:2280–2287

62. 62.

Sajid MS, Farag S, Leung P, Sains P, Miles WFA, Baig MK (2013) Systematic review and meta-analysis of published trials comparing the effectiveness of transanal endoscopic microsurgery and radical resection in the management of early rectal cancer. *Colorectal Dis* 16:2–16

63. 63.

Marks JH, Valsdottir EB, DeNittis A, Yarandi SS, Newman DA, Nweze I, Mohiuddin M, Marks GJ (2009) Transanal endoscopic microsurgery for the treatment of rectal cancer: comparison of wound complication rates with and without neoadjuvant radiation therapy. *Surg Endosc* 23:1081–1087

64. 64.

Perez RO, Habr-Gama A, São Julião GP, Proscurshim I, Scanavini Neto A, Gama-Rodrigues J (2011) Transanal endoscopic microsurgery for residual rectal cancer after neoadjuvant chemoradiation therapy is associated with significant immediate pain and hospital readmission rates. *Dis Colon Rectum* 54:545–551

65. 65.

Coco C, Rizzo G, Mattana C, Gambacorta MA, Verbo A, Barbaro B, Vecchio FM, Pafundi DP, Mastromarino MG, Valentini V (2013) Transanal endoscopic microsurgery after neoadjuvant radiochemotherapy for locally advanced extraperitoneal rectal cancer: short-term morbidity and functional outcome. *Surg Endosc* 27:2860–2867

66. 66.

Arezzo A, Arolfo S, Allaix ME, Munoz F, Cassoni P, Monagheddu C, Ricardi U, Ciccone G, Morino M (2015) Results of neoadjuvant short-course radiation therapy followed by transanal endoscopic microsurgery for T1-T2 N0 extraperitoneal rectal cancer. *Int J Radiat Oncol Biol Phys* 92:299–306

67. 67.

Gornicki A, Richter P, Polkowski W, Szczepkowski M, Pietrzak K, Kepka L, Rutkowski A, Bujko K (2014) Anorectal and sexual functions after preoperative radiotherapy and full-thickness local excision of rectal cancer. *Eur J Surg Oncol* 40:723–730

68. 68.

Restivo A, Zorcolo L, D'Alia G, Cocco F, Cossu A, Scintu F, Casula G (2016) Risk of complications and long-term functional alterations after local excision of rectal tumors with transanal endoscopic microsurgery (TEM). *Int J Colorectal Dis* 31(2):257–266

69. 69.

Verseveld M, de Graaf EJ, Verhoef C, van Meerten E, Punt CJ, de Hingh IH, Nagtegaal ID, Nuyttens JJ, Marijnen CA, de Wilt JH, CARTS Study Group (2015) Chemoradiation therapy for rectal cancer in the distal rectum followed by organ-sparing transanal endoscopic microsurgery (CARTS study). *Brit J Surg* 102:853–860

70. 70.

TREC study. <http://www.controlled-trials.com/ISRCTN14422743?q=trec&filters=&sort=&offset=2&totalResults=5&page=1&pageSize=10&searchType=basic-search>. Accessed 25 Sep 2012

71. 71.

Serra-Aracil X, Mora-Lopez L, Alcantara-Moral M, Caro-Tarrago A, Navarro-Soto S (2014) Transanal endoscopic microsurgery with 3-D (TEM) or high-definition 2-D transanal endoscopic operation (TEO) for rectal tumors. A prospective, randomized clinical trial. *Int J Colorectal Dis* 29:605–610

72. 72.

Atallah S, Albert M, Larach S (2010) Transanal minimally invasive surgery: a giant leap forward. *Surg Endosc* 24:2200–2205

73. 73.

Martin-Perez B, Andrade-Ribeiro GD, Hunter L, Atallah S (2014) A systematic review of transanal minimally invasive surgery (TAMIS) from 2010 to 2013. *Tech Coloproctol* 18:775–788

74. 74.

Rimonda R, Arezzo A, Arolfo S, Salvai A, Morino M (2013) TransAnal Minimally Invasive Surgery (TAMIS) with SILS™ port versus Transanal Endoscopic Microsurgery (TEM): a comparative experimental study. *Surg Endosc* 27:3762–3768

75. 75.

Albert M, Atallah S, deBeche-Adams TC, Izfar S, Larach SW (2013) Transanal minimally invasive surgery (TAMIS) for local excision of benign neoplasms and early-stage rectal cancer: efficacy and outcomes in the first 50 patients. *Dis Colon Rectum* 56:301–307

76. 76.

Zerz A, Muller-Stich BP, Beck J, Linke GR, Tarantino I, Lange J (2006) Endoscopic posterior mesorectal resection after transanal local excision of T1 carcinomas of the lower third of the rectum. *Dis Colon Rectum* 49(6):919–924

77. 77.

Tarantino I, Hetzer FH, Warschkow R, Zünd M, Stein HJ, Zerz A (2008) Local excision and endoscopic posterior mesorectal resection versus low anterior resection in T1 rectal cancer. *Br J Surg* 95(3):375–380

78. 78.

Walega P, Kenig J, Richter P (2014) Transanal endoscopic microsurgery combined with endoscopic posterior mesorectum resection in the treatment of patients with T1 rectal cancer—3-year results. *Wideochir Inne Tech Malo Inwazyjne* 9:40–45

79. 79.

van der Pas MH, Meijer S, Hoekstra OS, Riphagen II, de Vet HC, Knol DL, van Grieken NC, Meijerink WJ (2011) Sentinel-lymph-node procedure in colon and rectal cancer: a systematic review and meta-analysis. *Lancet Oncol* 12:540–550

80. 80.

Lezoche E, Fabiani B, D'Ambrosio G, Ursi P, Balla A, Lezoche G, Monteleone F, Paganini AM (2013) Nucleotide-guided mesorectal excision combined with endoluminal locoregional resection by transanal endoscopic microsurgery in the treatment of rectal tumors: technique and preliminary results. *Surg Endosc* 27:4136–4141

81. 81.

Arezzo A, Arolfo S, Mistrangelo M, Mussa B, Cassoni P, Morino M (2014) Transrectal sentinel lymph node biopsy for early rectal cancer during transanal endoscopic microsurgery. *Minim Invasive Ther Appl Technol* 23:17–20

82. 82.

Ghadimi BM, Grade M, Liersch T, Langer C, Siemer A, Füzesi L, Becker H (2003) Gain of chromosome 8q23-24 is a predictive marker for lymph node positivity in colorectal cancer. *Clin Cancer Res* 9:1808–1814

83. 83.

Chen Z, Liu Z, Deng X, Warden C, Li W, Garcia-Aguilar J (2012) Chromosomal copy number alterations are associated with persistent lymph node metastasis after chemoradiation in locally advanced rectal cancer. *Dis Colon Rectum* 55:677–685

84. 84.

Sylla P, Rattner DW, Delgado S, Lacy AM (2010) NOTES transanal rectal cancer resection using transanal endoscopic microsurgery and laparoscopic assistance. *Surg Endosc* 24:1205–1210

85. 85.

Leroy J, Barry BD, Melani A, Mutter D, Marescaux J (2013) No-scar transanal total mesorectal excision: the last step to pure NOTES for colorectal surgery. *JAMA Surg* 148:226–230

86. 86.

Velthuis S, van den Boezem PB, van der Peet DL, Cuesta MA, Sietses C (2013) Feasibility study of transanal total mesorectal excision. *Br J Surg* 100:828–831

87. 87.

Araujo SE, Crawshaw B, Mendes CR, Delaney CP (2015) Transanal total mesorectal excision: a systematic review of experimental and clinical evidence. *Tech Coloproctol* 19:69–82

88. 88.

Fernández-Hevia M, Delgado S, Castells A, Tasende M, Momblan D, Díaz Del Gobbo G, DeLacy B, Balust J, Lacy AM (2015) Transanal total mesorectal excision in rectal cancer: short-term outcomes in comparison with laparoscopic surgery. *Ann Surg* 261:221–227

89. 89.

Velthuis S, Nieuwenhuis DH, Ruijter TE, Cuesta MA, Bonjer HJ, Sietses C (2014) Transanal versus traditional laparoscopic total mesorectal excision for rectal carcinoma. *Surg Endosc* 28:3494–3499

90. 90.

Hompes R, Rauh SM, Ris F, Tuynman JB, Mortensen NJ (2014) Robotic transanal minimally invasive surgery for local excision of rectal neoplasms. *Br J Surg* 101:578–581

91. 91.

Gómez Ruiz M, Parra IM, Palazuelos CM, Martín JA, Fernández CC, Diego JC, Fleitas MG (2015) Robotic-assisted laparoscopic transanal total mesorectal excision for rectal cancer: a prospective pilot study. *Dis Colon Rectum* 58:145–153