

AperTO - Archivio Istituzionale Open Access dell'Università di Torino

Delayed onset of fatal encephalitis in a COVID-19 positive patient

This is the author's manuscript

Original Citation:

Availability:

This version is available <http://hdl.handle.net/2318/1780915> since 2021-03-17T22:30:03Z

Published version:


DOI:10.1080/00207454.2021.1886095

Terms of use:

Open Access

Anyone can freely access the full text of works made available as "Open Access". Works made available under a Creative Commons license can be used according to the terms and conditions of said license. Use of all other works requires consent of the right holder (author or publisher) if not exempted from copyright protection by the applicable law.

(Article begins on next page)



Delayed onset of fatal encephalitis in a COVID-19 positive patient

Luca Zanin , Giorgio Saraceno , Giulia Renisi , Liana Signorini , Luigi Battaglia , Marco Ferrara , Francesco Antonio Rasulo , Pier Paolo Panciani & Marco Maria Fontanella

To cite this article: Luca Zanin , Giorgio Saraceno , Giulia Renisi , Liana Signorini , Luigi Battaglia , Marco Ferrara , Francesco Antonio Rasulo , Pier Paolo Panciani & Marco Maria Fontanella (2021): Delayed onset of fatal encephalitis in a COVID-19 positive patient, International Journal of Neuroscience, DOI: [10.1080/00207454.2021.1886095](https://doi.org/10.1080/00207454.2021.1886095)

To link to this article: <https://doi.org/10.1080/00207454.2021.1886095>



Accepted author version posted online: 03 Feb 2021.



Submit your article to this journal [↗](#)



View related articles [↗](#)



View Crossmark data [↗](#)

Delayed onset of fatal encephalitis in a COVID-19 positive patient

Luca Zanin, MD¹, Giorgio Saraceno, MD², Giulia Renisi, MD³, Liana Signorini, MD³, Luigi Battaglia, MD, PhD⁴, Marco Ferrara, MD⁵, Francesco Antonio Rasulo, MD⁶, Pier Paolo Panciani, MD, PhD², Marco Maria Fontanella, MD⁷

¹Unit of Neurosurgery, Department of Surgical Specialties, Radiological Sciences, and Public Health, University of Brescia, 25123 Brescia, Italy

²Neurosurgery, Department of Medical and Surgical Specialties, Radiological Sciences and Public Health, University of Brescia, Brescia, Italy

³Department of Infection and Tropical Disease, University of Brescia, Brescia, Italy.

⁴Dipartimento di Scienza e Tecnologia del Farmaco, Università degli Studi di Torino, Via Pietro Giuria 9, Turin, Italy

⁵Azienda Ospedaliera Spedali Civili di Brescia, Neuroradiology, Department of Medical and Surgical Specialties, Radiological Sciences and Public Health, University of Brescia, Brescia, Italy.

⁶University of Brescia, Intensive Care and Anesthesiology, Department of Surgical Specialties, Radiological Sciences and Public Health, University of Brescia and Spedali Civili Hospital, Brescia, Italy.

⁷University of Brescia, Neurosurgery, Department of Medical and Surgical Specialties, Radiological Sciences and Public Health, P.le Spedali Civili, 1, Brescia, Italy

Corresponding author: Luca Zanin, MD Unit of Neurosurgery, Department of Surgical Specialties, Radiological Sciences, and Public Health, University of Brescia, Piazzale Spedali Civili 1, 25123 Brescia, Italy. Telephone number: +39 0303995587 Fax number: +39 0303995008 E-mail address: lucazanin00@gmail.com

Abstract

Background:

The SARS-nCoV-2019 epidemic has spread since December 2019, quickly gaining worldwide attention. Symptoms consist of fever, cough and breathing difficulties. An increasing number of studies are focusing on neurological manifestations. In addition to the typical ageusia and anosmia, up to 30% of cases can present headache, nausea and vomiting. More serious neurological manifestations, such as encephalitis, thrombosis and cerebral haemorrhage have been reported.

Case description:

We described the case of a 47-year-old man who tested positive for COVID-19 virus in early March 2020. After two negative nasopharyngeal swabs, 41 days after the diagnosis of COVID-19 infection,

he developed intense headache with fever, and he was hospitalized. He had subsequent generalized epileptic seizures and intubation was necessary. Contrast Head MRI was negative for brain abscesses or tumours but detected severe vasogenic oedema of the white matter with 10 mm shift of the midline and compression of the right lateral ventricle. Massive cortisone support therapy was ineffective. We diagnosed brain death on day 43 from the infection diagnosis.

Discussion:

COVID-19 virus can reach the brain, penetrating into the neuronal cells through the interaction between the spike protein S1 and the host ACE-2 receptor, expressed in the capillary endothelium. We believe that in this infection, the pro-inflammatory state induced by the cytokine storm can cause a cerebral cell-mediated response, with subsequent vasodilatation and brain oedema.

Conclusion:

To our knowledge, this is the first description of a delayed onset cell-mediated encephalitis caused by COVID-19 virus after more than 40 days from the diagnosis.

Keywords: encephalitis; COVID-19; infection; fatal

Introduction:

The novel coronavirus pandemic (SARS-CoV-2) produces a respiratory and systemic illness which progresses to a severe interstitial pneumonia in 10-15% of patients¹. It was recently documented that, in addition to respiratory symptoms, about 30% of patients with SARS-CoV-2 show neurological manifestations².

Currently, many studies are focusing on Central Nervous System involvement in COVID-19^{3,4}. Headache, nausea and vomiting are the main potential neuroinvasive neurologic symptoms caused by the SARS-CoV-2, after anosmia and ageusia². It has already been proven that this virus can also cause severe neurological manifestations such as brain haemorrhages, cerebral thrombosis and encephalitis⁴⁻⁶.

Encephalitis is described as an acute onset, and common signs include headache, high fever, vomiting, seizures, and consciousness disorders⁷. Early diagnosis of encephalitis can be difficult and there is often a diagnostic delay.

We reported a possible case of a delayed onset encephalitis in a COVID-19 patient.

Case presentation

The patient was a 47-year-old man. Medical history did not reveal anything meaningful. In early March 2020 he developed fever, dry cough and respiratory fatigue. For this reason, he was hospitalized in the emergency room and subjected to real-time polymerase chain reaction (RT-PCR) for SARS-CoV-2 obtained by nasopharyngeal swab (day 1). The test resulted positive and he remained in home isolation for 15 days. In the following days he took paracetamol for fever and no other specific antiviral therapy. Oxygen saturation remained above 98%.

On day 20 the first nasopharyngeal swab control was performed which resulted negative, as did the second nasopharyngeal swab control also. The patient had no relevant symptoms in the following days.

On day 41 the fever reappeared, associated with nausea, vomiting and severe headache (NRS 7). He was immediately transferred to the emergency room and a CT head scan was performed. Right temporo-fronto-parietal vasogenic edema with extension to the capsular region was evident (Figure 1a). The patient was awake and fully oriented, with a Glasgow Coma Scale (GCS) of E4-V5-M6.

In the suspicion of brain abscess the patient was hospitalized, and echocardiography exam and orthopantomography, were performed, which resulted both negative.

Blood investigation revealed an increased C-reactive protein (27.4), increased White Blood Cell count (28.12), neutrophil dominant (90.6), extremely reduced lymphocytes (1.6). Antibiotic therapy with metronidazole and ceftriaxone was started.

On day 42 the patient deteriorated neurologically, with a GCS which dropped to E3-V4-M5. A second CT head scan was urgently performed which showed a worsening of brain oedema and midline shift (Figure 1b). While awaiting a contrast brain MRI the patient developed subsequent generalized epileptic seizures, which did not resolve with the administration of benzodiazepines iv (lorazepam). The seizures therefore progressed to Status epilepticus which led to the necessity to intubate the patient and administer continuous intravenous benzodiazepines (diazepam) for seizure control.

With the patient intubated, a contrast Head MRI scan was performed and resulted negative for abscesses or tumours, but confirmed vasogenic oedema of the white matter with 10mm shift of the midline and compression of the right lateral ventricle (Figure 2). The radiological findings seem to be characteristic in the first hypothesis for an encephalitic process. Diffusion weighted imaging shows extensive cortical marked restriction of the interested regions in right emisphere without images of hyperperfusion on qualitative parametric maps (Figure 3).

Dexamethasone support therapy was commenced but resulted ineffective. When sedation was stopped on day 43, the patient's neurological evaluation showed a GCS of E1-V1-M1, fixed dilated pupils, and corneal reflex.

Brain death was diagnosed on the night of day 43.

Discussion

Encephalitis is defined as inflammation of the brain. The severity can be variable with symptoms including headache, fever, and vomiting. An increasing number of COVID-19 patients with neurological manifestations are described and more studies are focusing on neuroinvasive mechanisms of SARS-CoV-2^{3,4}. In fact, neurotropism may possibly occur via the bloodstream and/or trans-cribrial route, which in theory may enable the COVID-19 virus to reach the brain, penetrating into the neuronal cells through the interaction between the spike protein S1 and the host ACE-2 receptor, expressed in the capillary endothelium^{8,9}. Subsequent budding of the viral particles leads to inflammation and demyelination. In addition to that, nervous system damage caused by viral infection may also be mediated by the immune system. As demonstrated by previous studies¹⁰, the pathogenesis of severe viral infections is closely linked to the development of virus induced systemic inflammatory response syndrome (SIRS) or SIRS-like immune disorders¹¹. For SARS-CoV-2 infection, the pro-inflammatory state induced by the cytokine storm, (especially IL1, IL6 and TNF α), may be responsible of cerebral cell-mediated response, with subsequent vasodilatation and brain oedema. Although the definitive diagnosis of viral encephalitis is based on virus isolation, the transient dissemination of SARS-CoV-2019 in cerebrospinal fluid as well as the phenomenon of viral clearance and delayed performance of lumbar puncture, make its isolation difficult in the cerebrospinal fluid. Certainly, for the differential diagnosis regarding this case it would be necessary to consider other pathogens that can cause encephalitis, such as Herpes Simplex Virus 1 and 2,

Epstein-Barr Virus, Varicella Zoster Virus, or even bacteria, like *Mycoplasma pneumoniae* and *Borrelia burgdorferi*, and often the causative agent of viral encephalitis remains unknown¹². However, the presence of the virus, even if searched for during autopsy, may not be detected and therefore uncertain. This is due mostly to the pathogenic action carried out by the immune system itself and not by the virus. We decided not to perform a lumbar puncture because of the high risk represented by intracranial hypertension. Unfortunately, despite the steroid therapy, it was not possible to control the ongoing cerebral edema and the clinical condition rapidly worsened until the patient expired.

Conclusion

We believe that this case is important because it may represent a possible case of encephalitis caused by SARS-CoV-2 after more than 40 days from the diagnosis and after two negative nasopharyngeal swabs. We speculate that patients with a medical history, positive for COVID-19 and with acute typical neurological manifestations should be immediately investigated for viral encephalitis, as a delayed onset may be possible.

References

1. Guan, W.-J. *et al.* Clinical Characteristics of Coronavirus Disease 2019 in China. *N. Engl. J. Med.* (2020) doi:10.1056/NEJMoa2002032.
2. Mao, L. *et al.* Neurological Manifestations of Hospitalized Patients with COVID-19 in Wuhan, China: a retrospective case series study. *Lancet Neurol.* 2020.02.22.20026500 (2020) doi:10.1101/2020.02.22.20026500.
3. Baig, A. M., Khaleeq, A., Ali, U. & Syeda, H. Evidence of the COVID-19 Virus Targeting the CNS: Tissue Distribution, Host-Virus Interaction, and Proposed Neurotropic Mechanisms. *ACS Chemical Neuroscience* vol. 11 995–998 (2020).
4. Wu, Y. *et al.* Nervous system involvement after infection with COVID-19 and other coronaviruses. *Brain. Behav. Immun.* (2020) doi:10.1016/j.bbi.2020.03.031.
5. Ye, M., Ren, Y. & Lv, T. Encephalitis as a clinical manifestation of COVID-19. *Brain, Behavior, and Immunity* vol. 88 945–946 (2020).
6. Moriguchi, T. *et al.* A first Case of Meningitis/Encephalitis associated with SARS-Coronavirus-2. *Int. J. Infect. Dis.* (2020) doi:10.1016/j.ijid.2020.03.062.
7. Ellul, M. & Solomon, T. Acute encephalitis - diagnosis and management. *Clinical Medicine, Journal of the Royal College of Physicians of London* vol. 18 155–159 (2018).
8. Netland, J., Meyerholz, D. K., Moore, S., Cassell, M. & Perlman, S. Severe Acute Respiratory Syndrome Coronavirus Infection Causes Neuronal Death in the Absence of Encephalitis in Mice Transgenic for Human ACE2. *J. Virol.* **82**, 7264–7275 (2008).
9. Wrapp, D. *et al.* Cryo-EM Structure of the 2019-nCoV Spike in the Prefusion Conformation. *bioRxiv Prepr. Serv. Biol.* (2020) doi:10.1101/2020.02.11.944462.
10. Mehta, P. *et al.* COVID-19: consider cytokine storm syndromes and immunosuppression. *Lancet (London, England)* (2020) doi:10.1016/S0140-6736(20)30628-0.

11. Chen, C., Zhang, X. R., Ju, Z. Y. & He, W. F. [Advances in the research of cytokine storm mechanism induced by Corona Virus Disease 2019 and the corresponding immunotherapies]. *Zhonghua Shao Shang Za Zhi* **36**, E005 (2020).
12. Sigfrid, L. *et al.* A systematic review of clinical guidelines on the management of acute, community-acquired CNS infections. *BMC Med.* **17**, 170 (2019).

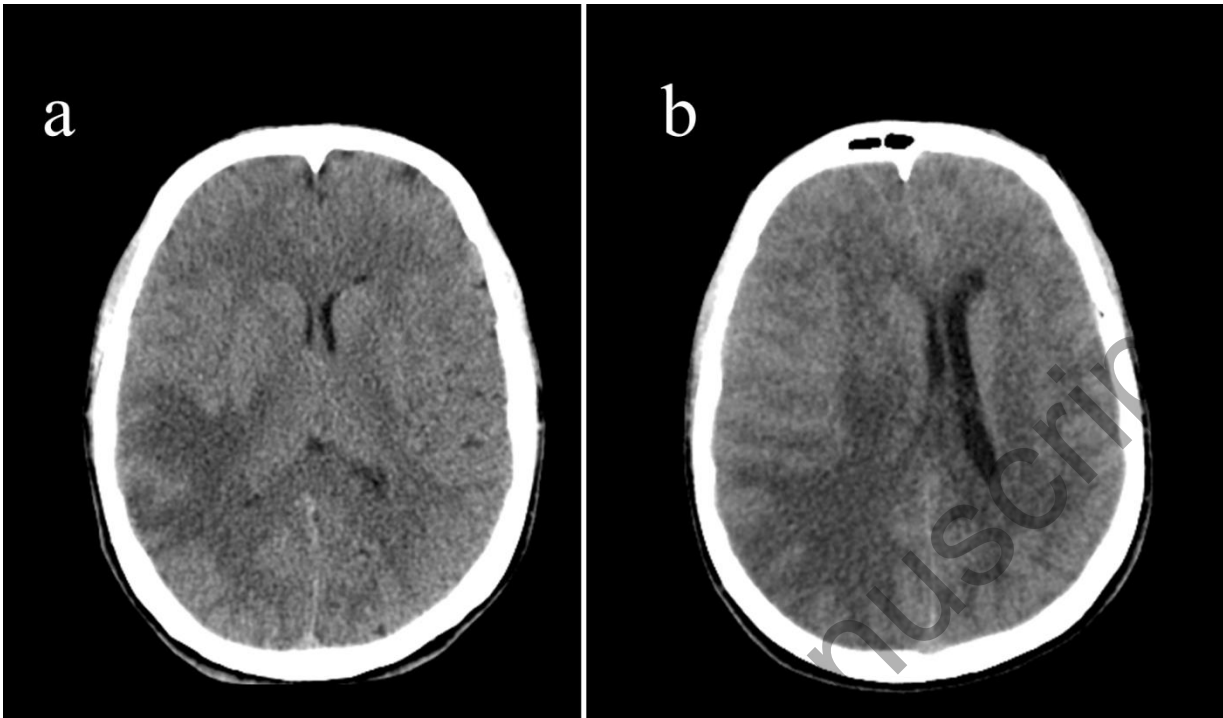


Figure 1. Head CT scan, axial view: a) first CT head scan performed on day 41 showing moderate vasogenic edema in the right temporo-fronto-parietal region and modest midline shift b) second CT scan performed on day 42 shows increasing vasogenic oedema in the right temporo-fronto-parietal region with extension to the capsular region, to the cerebral peduncle and in the ipsilateral mesencephalic region. Severe compressive effect on the right lateral ventricle.

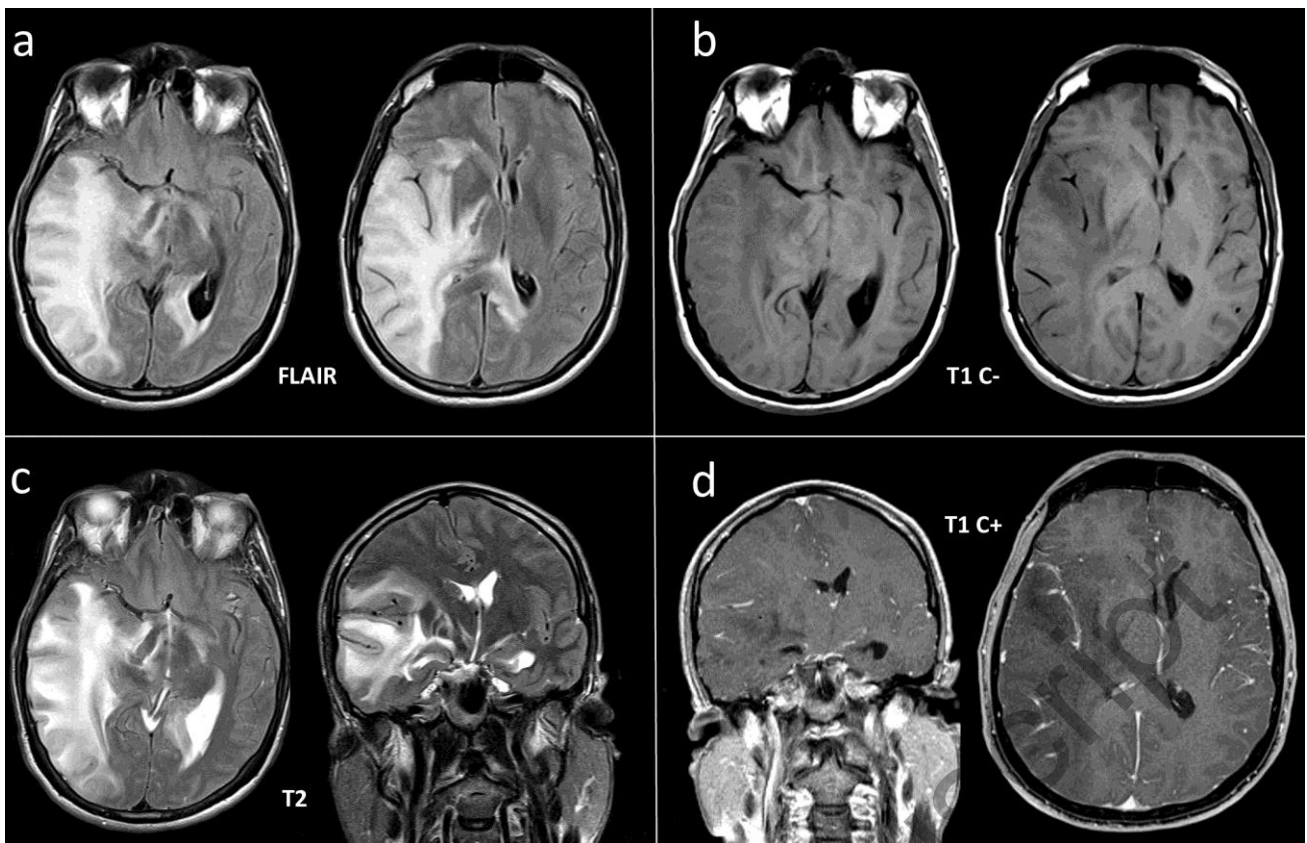


Figure 2. Head MRI, axial and coronal view: extensive vasogenic edema of the white matter in the right hemisphere, involving the isthmus and splenium of the corpus callosum bilaterally and, through the cerebral peduncles in correspondence of the cortico-spinal bundles, in subtentorial region. Marked diffusion restriction of the parieto - insulo - temporal and occipital cortical area on the right was associated. Hyperintense T2-signal is also observed in the right optic tract and in the bulbar pyramids. The extensive edema determines a marked compressive effect on the right lateral ventricle with associated compensatory dilatation of the left lateral ventricle and posterior interstitial edema. After contrast medium, a nuanced and inhomogeneous impregnation is observed at the margins of the vasogenic edema.

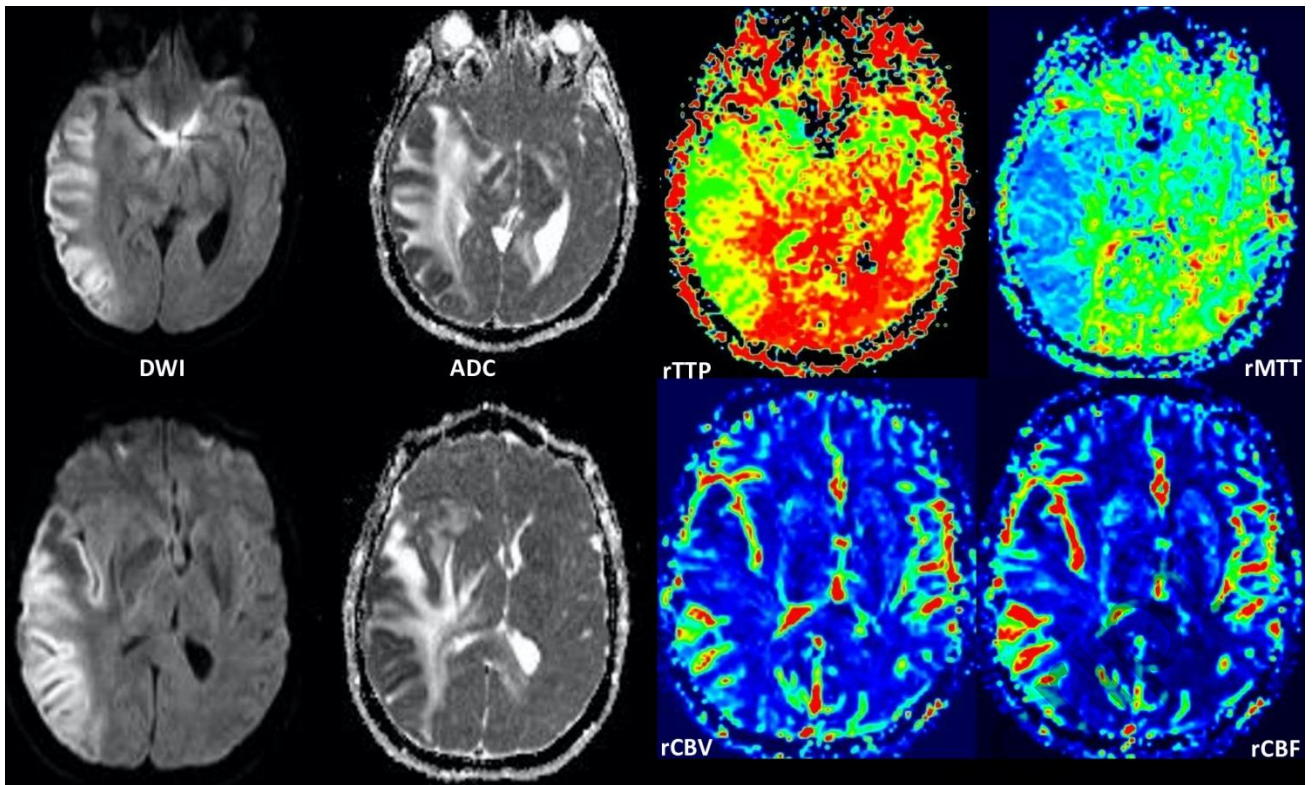


Figure 3. Head MRI, DWI and Perfusion Study, axial view: diffusion weighted imaging (on the left) shows extensive cortical marked restriction of the interested regions in right emisphere without images of hyperperfusion on qualitative parametric maps (on the right).