

AperTO - Archivio Istituzionale Open Access dell'Università di Torino

Combined liver kidney transplantation for primary hyperoxaluria type 1: Will there still be a future? Current transplantation strategies and monocentric experience

This is the author's manuscript

Original Citation:

Availability:

This version is available <http://hdl.handle.net/2318/1788007> since 2021-10-01T00:49:51Z

Published version:

DOI:10.1111/petr.14003

Terms of use:

Open Access

Anyone can freely access the full text of works made available as "Open Access". Works made available under a Creative Commons license can be used according to the terms and conditions of said license. Use of all other works requires consent of the right holder (author or publisher) if not exempted from copyright protection by the applicable law.

(Article begins on next page)

**TRANSPLANTATION STRATEGIES FOR PRIMARY HYPEROXALURIA TYPE-1 IN CHILDREN:
SHOULD WE CONSIDER THE “LIVER FIRST” OPTION?**

Brief communication: 3,000 words with 30 references; ABSTRACT 250 words

→ ABSTRACT 250 words

→ TEXT 2,891 words

→ References 22

Tandoi F ^{1#} MD, PhD, FEBS. ORCID# 0000-0003-3166-6684

Cussa D ^{1#} MD. ORCID#

Peruzzi L ² MD. ORCID#

Catalano S ¹ MD. ORCID#

Camilla R ² MD. ORCID#

Mandrile G ³

Calvo PL ⁴ MD, ORCID#

Dell’Olio D ⁵ MD, PhD, ORCID# [0000-0002-4448-4559](https://orcid.org/0000-0002-4448-4559)

Salizzoni M ¹ MD, ORCID#

Amoroso A ⁵ MD, ORCID#

Romagnoli R ¹ MD, ORCID#

These Authors contributed equally to this work

¹ Liver Transplant Center, General Surgery Unit – Department of Surgical Sciences – A.O.U. Città della Salute e della Scienza – University of Torino, Torino, Italy

² Paediatric Nephrology – Department of Paediatrics – A.O.U. Città della Salute e della Scienza – University of Torino, Torino, Italy

³ Medical Genetics Unit – University of Torino – AOU San Luigi, Orbassano, Italy

⁴ Paediatric Gastroenterology – Department of Paediatrics – A.O.U. Città della Salute e della Scienza – University of Torino, Torino, Italy

⁵ Regional Transplant Centre – A.O.U. Città della Salute e della Scienza – University of Torino, Torino, Italy

Running title: “TRANSPLANTATION STRATEGIES FOR PH-1 IN CHILDREN”

Address for reprints and correspondence:

Renato Romagnoli, MD, FEBS

Professor of Surgery at the University of Turin

Chirurgia Generale 2 U – Centro Trapianto di Fegato

A. O. U. Città della Salute e della Scienza di Torino – Presidio Molinette

Corso Bramante 88, 10126, Turin, Italy

email: renato.romagnoli@unito.it

ABBREVIATIONS:

Aza: Azathioprine

BSA: Body Surface Area

CIT: Cold Ischemia Time

CLKT: Combined Liver-Kidney Transplantation

CMV: Cytomegalovirus

CsA: Cyclosporine A

EBV: Epstein-Barr Virus

ESRD: End-Stage Renal Disease

GRBWR: Graft to Recipient Body Weight Ratio

HLA: Human Leukocyte Antigens

HPLC: high-pressure liquid chromatography

ICU: intensive care unit

MMF: Mycophenolate mofetil

PELD: Paediatric End-stage Liver Disease

PH1: primary hyperoxaluria type 1

RRT: Renal Replacement Therapy

St: Steroids

Tac: Tacrolimus

WIT: Warm Ischemia Time

ABSTRACT

Background: Combined liver–kidney transplantation is the preferred therapeutic option for children affected by type 1 primary hyperoxaluria. However, persistently high serum oxalate levels may lead to kidney graft failure. It is debated in which cases pre-emptive liver transplantation, followed by kidney transplantation, might be a better strategy to reduce kidney graft loss.

Methods: Our experience of 6 Paediatric combined liver–kidney transplants for primary hyperoxaluria type 1 in pediatric recipients was retrospectively analysed. Serum oxalate levels were monitored before and after transplantation.

Results: All the recipients were on hemodialysis at transplantation. Four were male (67%). Median (IQR) recipients' age at transplantation was 11 [4.4-12.6] years; in all cases a compatible graft from a pediatric brain-death donor aged 8.1 [3.3-12.6] years was used. In a median follow-up of 6.5 [2-10] years after combined liver–kidney transplantation, no child died and no liver graft failure was observed. By contrast three (50%) kidney grafts were lost, due to chronic rejection, to primary non-function, the last due to early renal oxalate accumulation. Liver and kidney graft survival remained stable at 1, 3, and 5 years, at 100% and 85% respectively

Conclusions: Kidney graft loss was the major complication after combined liver–kidney transplantation in our series. This risk is much higher in very young, low weight donors. Pre-emptive liver transplantation with sequential kidney transplantation or delayed kidney transplantation in a combined transplant setting, with recourse to hypothermic perfusion techniques, might be better therapeutic strategies to reduce kidney loss due to high serum oxalate.

INTRODUCTION

Primary hyperoxaluria type 1 (PH1, OMIM #259900) is a rare inborn error of metabolism, caused by deficiency of the hepatic enzyme alanine-glyoxylate-aminotransferase(1).

The absent or reduced enzyme activity leads to an excessive oxalate production, with diffuse interstitial renal accumulation as nephrocalcinosis or relapsing kidney stones, possibly evolving into end-stage renal disease (ESRD). In its severe expression, extra-renal oxalate accumulation can be observed in the retina, bone, arteries and soft tissues, as systemic oxalosis (2).

Although a rare disorder, it acquires considerable clinical importance as it accounts for approximately 2% of children needing renal replacement treatment in Western countries, whilst in populations where the frequency of parental consanguinity is high it may account for up to 17% of ESRD in pediatric age (3).

Despite promising innovative therapies, including gene therapy and stem cell therapy (4),(5), supportive treatment is still based on hyper-hydration, vitamin B6, and potassium citrate supplementation. Liver transplantation, with or without kidney transplantation, still remains the definitive treatment for primary hyperoxaluria type 1 (6),(7),(8), at least until, in a hopefully near future, the defective enzyme activity will be pharmacologically or biologically restored.

What the best surgical strategy may be, and particularly the timing and type of transplantation, still remains controversial. In the last decade, the debate has focused on choosing the right approach between simultaneous combined liver-kidney transplantation (CLKT) (9) and sequential surgical procedures (10),(11).

It is well recognized that kidney transplantation alone may result in a dramatic disease recurrence and graft failure (12), therefore kidney substitutive therapy through transplantation is usually planned once the enzyme defect has been obviated, previously or simultaneously, thanks to a liver transplant. Even following this approach, kidney graft loss due to massive oxalate accumulation is a major complication of CLKT (6),(7),(9), in up to 50% of the cases, despite the adoption of an aggressive post-transplant hemodialysis protocol (10),(13).

In an era of donor shortage, avoiding organ wasting and preventable graft failure is becoming more and more important, forcing transplantation centres to explore new solutions.

AIM OF THE STUDY:

This study aimed to assess the outcomes of CLKT in paediatric PH1 patients with ESRD transplanted in our Centre, and to suggest improvement in the management strategies of this rare condition through serum oxalate levels monitoring before and after CLKT.

PATIENTS AND METHODS

We performed a retrospective observational study on 6 children with PH1 who received a simultaneous CLKT in our centre between 2001 and 2018.

This study was approved by our institutional review board and carried out according to good clinical practices. Written informed consent was obtained from all parents and patient consent was obtained, where appropriate.

Patients

Between January 2001 and December 2018, 2459 liver transplantation (LT) were performed in our institution, 2309 in adult and 150 in pediatric recipients. CLKT were 70 (2.8%) and 13/70 (18.6%) were performed for PH1, 7 in adult and 6 in pediatric recipients.

All children were referred by the Pediatric Nephrology Unit with a confirmed diagnosis of PH1, and were on renal replacement therapy. None was diagnosed in an early phase of the disease on a familiar or clinical basis, and in all cases the diagnostic suspicion was raised because of advanced nephrocalcinosis or recurrent urinary stones with chronic renal disease. PH1 diagnosis was based on elevated serum oxalate levels and elevated urinary oxalate if a diuresis was still present, followed by *AGXT* gene mutation analysis confirmation. Upon diagnosis, all children received intensive hemodialysis treatment or combined hemodialysis and peritoneal dialysis, aimed at maintaining serum oxalate levels assessed by HPLC (14) lower than 70 $\mu\text{mol/L}$. Intensive nutritional support and accurate screening of oxalate accumulation in the target organs were concomitantly carried out. Indications and optimal timing for transplantation were discussed by a multidisciplinary team.

Surgical technique

All the patients underwent orthotopic liver transplantation from a deceased pediatric donor, in all cases with preservation of the inferior retrohepatic vein. The portal vein was reconstructed with an end-to-end anastomosis without vein graft interposition or a porto-plasty. The artery was reconstructed with an end-to-end anastomosis on the recipient common hepatic artery or directly onto the aorta with an end-to-side anastomosis with an iliac artery graft interposition. The bile duct was reconstructed with an end-to-end anastomosis or with a Roux-en-Y hepatico-jejunostomy.

At the end of liver transplantation surgery, a heterotopic kidney transplantation was performed on the iliac axes; an end-to-side anastomosis between the donor renal artery and recipient iliac artery was performed. The donor ureter was implanted onto the recipient bladder on J-J stent.

Immunosuppression and post-transplant clinical course

Standard immunosuppression was based on induction with intraoperative basiliximab (20 or 40 mg according to weight <20kg or >20 kg) associated with steroid pulses (methylprednisolone 10 mg/kg intraoperative followed by tapering doses in the following days to 4 mg/kg on day 1 and 2 mg/kg on day 2). Immunosuppressive maintenance was based on calcineurin inhibitors [cyclosporine (2h peak of 1200-1400 ng/ml in the first month) or tacrolimus (through level 7-9 ng/ml in the first month then gradual tapering)], mycophenolate (1200 mg/m²), and steroids (0.75 mg/kg with progressive tapering until discontinuation within 24 months)]. Liver biopsies were performed if liver enzyme increased and by protocol at 12 months. Donor-specific antibody (DSA) were routinely monitored.

Plasma oxalate levels were measured by HPLC (14) at the time of listing for CLKT transplantation and on day 2 after transplantation.

In the first week after transplantation, vital parameters were monitored in Intensive Care Unit (ICU) where urine output, renal function tests, serum bilirubin, liver enzymes, coagulation parameters, and acid-base balance were 8 hourly recorded. All recipients underwent daily Doppler ultrasonography monitoring of the transplanted liver and kidney.

Statistical analysis

Qualitative variables are presented as numbers and percentages and analysed by chi-square test; quantitative variables are presented as median and quartiles and analysed by Mann-

Whitney test. Wilcoxon signed-rank test was used to compare pre- and post-CLKT measurements. A logistic regression was performed to evaluate variables related to kidney loss after CLKT. Graft survivals were evaluated with Kaplan-Meier analysis for comparisons with the log-rank test. The level of significance was set at $P < 0.05$. Statistical analyses were carried out with StatView (SAS Institute INC).

RESULTS

Clinical data of the 6 patients are summarized in Table 1.

Four children (67%) were boys; the median age at time of transplantation was 11 [4.4-12.6] years and the body surface area (BSA) 1.11 [0.65-1.16] m².

All patients underwent CLKT from brain death deceased compatible pediatric donors; median donor age was 8.1 [3.3-12.6] years and BSA 0.87 [0.64-1.26] m².

Median graft-to-recipient body weight ratio for liver allograft was 3.1 [2.0-3.8]%. Median cold ischemia time was 554 [460-563] minutes for livers, 911 [863-919] minutes for kidneys.

All children were on intensive hemodialysis at the time of transplantation; 5 out of 6 children resumed adequate urine output immediately after transplantation but three needed also supportive renal replacement therapy in the first days after transplantation.

Haplotype and mutations in the *AGXT* gene that encodes for the peroxisomal alanine-glyoxylate aminotransferase (AGT) enzyme are shown in Table 2.

The trend of serum oxalate (Figure 1) was characterized by a quick reduction within 48 hours from renal graft reperfusion as well as after a hemodialysis procedure, with plasma oxalate significantly lower than its pre-transplantation levels ($p=0.027$): median pre-CLKT plasma oxalate was 142 [127-198] $\mu\text{mol/L}$ while on day 2 post-CLKT was 43 [37-50] $\mu\text{mol/L}$.

Aspartate transaminase, alanine transaminase and total bilirubin levels progressively returned to normal values in the first 10 days after transplantation. Also serum creatinine decreased after CLKT in all cases in the first 7 days after transplantation, even if in three patients (patient 1, 3 and 6) the reduction was slower and strictly dependant from hemodialysis.

In a median follow-up of 6.5 [2-10] years after transplantation, no child died and no liver graft failure was observed. Two kidney grafts (33%) were lost early in the follow up, respectively after 11 days due to primary non-function possibly caused by the long ischemia time, and after 21 days due to early renal oxalate accumulation, despite a very aggressive hemodialysis protocol started immediately after transplantation. Another kidney graft was lost due to chronic rejection for therapy non-adherence, 10 years after CLKT, without histological signs of oxalate deposition.

None of the studied variables achieved statistical significance for predicting early kidney graft loss at logistic regression. Liver and kidney graft survival remained stable at 1, 3, and 5 years, at 100% and 85% respectively.

Case series

Patient 1 was a ten year old boy, transplanted in September 2001. Post-operative course was complicated by intra-abdominal bleeding which required an emergency re-laparotomy. The Kidney graft was lost 10 years later in 2011 due to chronic rejection, related to non adherence to immunosuppressive therapy. No oxalate deposition was evidenced at kidney biopsy.

Patient 2 was a thirteen year old boy, transplanted in March 2010. The follow-up was complicated by late intrahepatic biliary strictures with recurrent cholangitis related to changes in intrahepatic arterial flow, successfully treated by percutaneous bilioplasty. He experienced recurrent lower urinary tract infections requiring antibiotic treatment in the first three years after transplantation and no other complications afterwards.

Patient 3 was a 2.6 year old boy, transplanted in April 2010. The patient was anuric on the first day after CLKT and required haemodialysis. On day 11 after transplantation, a renal scintigraphy showed no arterial flow in the kidney graft, which was eventually lost as primary non function possibly due to the protracted ischemia time (CIT kidney = 1000 min). Early post-operative course was also complicated by changes in intrahepatic arterial flow with tardus-parvus waveforms at Doppler ultrasonography. The patient received a second successful kidney transplantation in February 2012; the follow up of the second kidney graft was complicated by humoral kidney rejection with de-novo DSA without liver involvement.

Patient 4 was a 12 year old girl; in addition to ESRD, the girl suffered from oxalosis-related retinopathy. The post-transplant course and follow up have been uneventful with early restoration of liver and kidney function and normal urine output.

Patient 5 was a 13 year old girl who had undergone a laparoscopic left nephrectomy for infected urinary stones ; she was listed for CLKT and transplanted in July 2018. The early post-transplantation course was uneventful. Three months later, the girl developed a ventral incisional hernia, surgically corrected 1 year after transplant. Liver and kidney graft are showing normal function and follow up is uneventful.

Patient 6 was 3 year old boy with early onset of severe oxalosis and ESRD, diagnosed with PH1 at 2 months. The child was anuric and had very high plasma oxalate levels with severe nephrocalcinosis with, and oxalate-related retinopathy. He received intensive daily hemodialysis and nutritional support and was waitlisted when he reached a pre-dialysis plasma oxalate of 70 $\mu\text{mol/L}$ with efficient dialysis removal. He was transplanted in July 2018

from a deceased 3-years old donor. To avoid recurrence, he was treated immediately after transplantation with 24 hours continuous renal replacement treatment for 6 days in adjunction to forced diuresis. Kidney function loss occurred after three weeks concomitant with lung infection with respiratory failure and fluid overload which required assisted respiratory support: rapid fluid removal caused a dramatic diuresis reduction and irreversible oxalate accumulation, ascertained at kidney graft biopsy. Ten months after CLKT, the kidney graft and the native left kidney were explanted due the difficulty in reducing plasma oxalate in spite of intensive hemodialysis treatment; at histological examination, tubular oxalate accumulation and interstitial fibrosis were observed. Twenty months after transplantation, liver function is normal. This child is still on dialysis awaiting for kidney re-transplantation.

DISCUSSION

The ideal strategy for medical and surgical treatment for PH1 still remains controversial. Due to the rarity of the disease most reported series are limited in numbers, the timing of transplant is variable, and patients differ by clinical presentation and probably by genetic make-up.

In our experience, albeit limited to 6 pediatric recipients, CLKT is a safe and feasible approach, but despite the satisfactory outcome in patient quality of life and liver graft survival, kidney graft loss represents a severe complication possibly leading to continuation of hemodialysis or re-transplantation.

Our data suggest a relationship between recipients' age and the risk for kidney graft loss for more than one reason.

Small children with early end-stage renal failure due to massive nephrocalcinosis were offsprings of consanguineous marriages, bearing homozygous or compound heterozygous genetic defects causing complete loss of enzyme activity, with no response to vitamin B6 and high oxalate production even on intensive hemodialysis.

The significant correlation between a lower donor's age and weight and risk of graft loss, might also be due to rapid oxalate dismission from previous massive tissue accumulation that has to be handed by a small size kidney graft. Forced diuresis and supportive renal replacement treatment notwithstanding, such severe cases of PH1 may experience a rapid recurrence of the diseases in a kidney graft of compatible size, but too small to cope with a massive oxalate discharge.

Plasma oxalate levels can be still significantly raised months or even years after a functioning liver transplantation to replace ATG enzyme activity (10), eventually causing renal impairment and kidney graft failure.

For this reasons, Ozer and coll. decided to perform (6) a sequential transplantation in patients who have signs of systemic oxalosis or high levels of plasma oxalate. They also suggested the possibility to utilize different organs from the same living donor in different times to treat the disease (6).

A Stanford University group (10) recently argued on the two possible alternative approaches of two sequential transplants versus one simultaneous transplant and tried to elucidate which might be the better option: they concluded that, based on the published series and the limited pediatric experience in this rare disease, data supporting sequential versus combined transplantation are not sufficiently strong to indicate one or the other strategy.

They suggest that many donor and recipients' variables should be taken into account when deciding on transplant timing and strategy and that none of the two options can be at the moment recommended. Hence, while waiting for gene therapy (5), the choice of the best transplant strategy to cure PH1 still remains a challenge. The main limit of our reported experience is the small sample size, due to the rarity of the disease (less than three cases per million), but, our experience can contribute to the ongoing discussion (9) with some "lessons learned":

- 1) many children with PH1 are late referrals, already with ESRD and on haemodialysis. We rarely had the opportunity of considering an early CLKT on a PH1 patient with an eGFR below 30 ml/min/1.73 m², and never in a child.
- 2) Even if it is controversial as a primary approach, simultaneous CLKT has always been our first choice. Sequential liver-kidney transplantation was considered only in case of failing kidney graft.
- 3) Sequential liver-kidney transplantation could be fruitfully considered if the diagnosis is made early, in a phase of CKD stage 3 with a eGFR >30 ml/min/1.73 m², when progression to renal failure is deemed unavoidable. In our experience we could never considered this option in infants < 2 year, since tolerance to intensive hemodialysis was always difficult to maintain.
- 4) CLKT may be an issue especially in small infants. When PH1 is diagnosed before 6 months of age it usually presents as a very severe disease with systemic oxalate accumulation, bone disease and risk of retinal degeneration. In this context, any medical or surgical treatment can be difficult and with a high risk of complications. In these severe cases, who rapidly lead to native kidneys loss due to nephrocalcinosis in spite of intensive hemodialysis, oxalate net removal is scarce due to the kinetic of new oxalate generation. There is therefore often an urgency to perform a transplant to correct the metabolic defect and stop the irreversible systemic deposition in the eyes, brain, arteries and bone. Performing an isolated liver transplant first can rapidly correct the enzyme defect but continuation on hemodialysis may be hampered by serious complications in a small child. In any single case, the choice between the two options is bound to be always very challenging. We suggest a "case by case" discussion considering donor's and recipient's characteristics before choosing CLKT versus sequential transplantation. CLKT remains our first choice in children older than 2 year, and we consider this option safe and feasible (15).

- 5) Sequential transplantation could be a good option in infants to reduce the risk of kidney graft loss, and living donor liver transplantation represents probably the best option for the logistic and timing issues, followed by a cadaveric kidney transplantation (16).

Monitoring of the serum oxalate levels before and after transplantation can provide useful information on the best strategies to be pursued for management of CLKT in PH1.

A promising option in this context, despite the little experience in the paediatric field, might be represented by machine perfusion (17),(18). The advent of machine perfusion could profoundly change the way we envision combined transplantation. Thanks to machine perfusion it is now possible to recover a donated organ during complex surgical procedures like total hepatectomy, thus reducing the cold ischemia time (19),(20). If one considers that the oxalate levels decreases during the first 48 hours after liver transplantation (Figure 1), one could recover the kidney during this time interval, while the recipient is on an aggressive haemodialysis protocol. Kidney transplantation could thus be delayed by 24-48 hours, and the graft protected from oxalate accumulation (21),(22).

REFERENCES

1. Hoppe B. An update on primary hyperoxaluria. *Nat Rev Nephrol.* 2012;8(8):467–75.
2. Milliner DS, McGregor TL, Thompson A, Dehmel B, Knight J, Roskamp R, et al. End Points for Clinical Trials in Primary Hyperoxaluria. *Clin J Am Soc Nephrol* 2020;15(7):1056–65.
3. Hulton S-A. The primary hyperoxalurias: A practical approach to diagnosis and treatment. *Int J Surg* 2016;36(Pt D):649–54.
4. Jiang J, Salido EC, Guha C, Wang X, Moitra R, Liu L, et al. Correction of hyperoxaluria by liver repopulation with hepatocytes in a mouse model of primary hyperoxaluria type-1. *Transplantation.* 2008;85(9):1253–60.
5. Estève J, Blouin J-M, Lalanne M, Azzi-Martin L, Dubus P, Bidet A, et al. Generation of induced pluripotent stem cells-derived hepatocyte-like cells for ex vivo gene therapy of primary hyperoxaluria type 1. *Stem Cell Res.* 2019;38:101467.
6. Ozer A, Aktas H, Bulum B, Emiroglu R. The experience of combined and sequential liver and kidney transplantation from a single living donor in patients with primary hyperoxaluria type 1. *Pediatr Transplant.* 2019;23(4):e13406.
7. Büscher R, Büscher AK, Cetiner M, Treckmann JW, Paul A, Vester U, et al. Combined liver and kidney transplantation and kidney after liver transplantation in children: Indication, postoperative outcome, and long-term results. *Pediatr Transplant.* 2015;19(8):858–65.
8. Kavukçu S, Türkmen M, Soylu A, Kasap B, Oztürk Y, Karademir S, et al. Combined liver-kidney transplantation and follow-up in primary hyperoxaluria treatment: report of three cases. *Transplant Proc.* 2008;40(1):316–9.
9. Kotb MA, Hamza AF, Abd El Kader H, El Monayeri M, Mosallam DS, Ali N, et al. Combined liver-kidney transplantation for primary hyperoxaluria type I in children: Single Center Experience. *Pediatr Transplant.* 2019;23(1):e13313.
10. Pham TA, Esquivel C. Are two operations better than one? The debate over combined versus sequential liver-kidney transplantation from a single live donor in the treatment of primary hyperoxaluria 1. *Pediatr Transplant.* 2019;23(4):e13457.
11. Brinkert F, Ganschow R, Helmke K, Harps E, Fischer L, Nashan B, et al. Transplantation procedures in children with primary hyperoxaluria type 1: outcome and longitudinal growth. *Transplantation.* 2009;87(9):1415–21.
12. Jayasinghe K, Haber A, Wyburn K, Gracey D, Chadban S. Recurrent oxalosis in a combined liver-kidney transplant patient with primary hyperoxaluria type 1 resulting in graft failure. *Nephrol* 2018;23(10):962.
13. Bacchetta J, Mekahli D, Rivet C, Demède D, Leclerc A-L. Pediatric combined liver-kidney transplantation: a 2015 update. *Curr Opin Organ Transplant.* 2015;20(5):543–9.
14. Cochat P, Hulton S-A, Acquaviva C, Danpure CJ, Daudon M, De Marchi M, et al. Primary hyperoxaluria Type 1: indications for screening and guidance for diagnosis and treatment. *Nephrol Dial Transplant* 2012;27(5):1729–36.
15. Xiang J, Chen Z, Xu F, Mei S, Li Z, Zhou J, et al. Outcomes of liver-kidney transplantation in patients with primary hyperoxaluria: an analysis of the scientific registry of transplant recipients database. *BMC Gastroenterol.* 2020;20(1):208.

16. Angelico R, Guzzo I, Pellicciaro M, Saffioti MC, Grimaldi C, Mourani C, et al. Same Donor Laparoscopic Liver and Kidney Procurement for Sequential Living Donor Liver-Kidney Transplantation in Primary Hyperoxaluria Type I. *J Laparoendosc Adv Surg Tech A*. 2019;29(12):1616–22.
17. Werner MJM, van Leeuwen OB, de Jong IEM, Bodewes FAJA, Fujiyoshi M, Luhker OC, et al. First report of successful transplantation of a pediatric donor liver graft after hypothermic machine perfusion. *Pediatr Transplant*. 2019;23(3):e13362.
18. Cussa D, Patrono D, Catalano G, Rizza G, Catalano S, Gambella A, et al. Use of Dual Hypothermic Oxygenated Machine Perfusion to Recover Extended Criteria Pediatric Liver Grafts. *Liver Transplant* 2020;26(6):835–9.
19. Lauterio A, De Carlis R, Di Sandro S, Buscemi V, Andorno E, De Carlis L. Delayed kidney transplantation in combined liver-kidney transplantation for polycystic liver and kidney disease. *Transpl Int* 2019;32(12):1336–8.
20. Patrono D, Surra A, Catalano G, Rizza G, Berchiolla P, Martini S, et al. Hypothermic Oxygenated Machine Perfusion of Liver Grafts from Brain-Dead Donors. *Sci Rep*. 2019;9(1):9337.
21. Lunsford KE, Agopian VG, Yi SG, Nguyen DTM, Graviss EA, Harlander-Locke MP, et al. Delayed Implantation of Pumped Kidneys Decreases Renal Allograft Futility in Combined Liver-Kidney Transplantation. *Transplantation*. 2020;104(8):1591–603.
22. Hamar M, Selzner M. Ex-vivo machine perfusion for kidney preservation. *Curr Opin Organ Transplant*. 2018;23(3):369–74.

Patient N.	1	2	3	4	5	6
Year of transplantation	2001	2010	2010	2017	2018	2018
Donor						
Age (years)	4.1	1,8	2.0	16.0	12.0	3.0
Gender	Female	Female	Male	Male	Male	Male
Blood type	0	A	0	B	0	0
Body Surface Area (m ²)	0.71	1.33	0.53	1.81	1.04	0.62
Cause of brain death	Trauma	Anoxia	Trauma	Trauma	Trauma	Anoxia
HLA-A1	2	3	2	2	2	2
HLA-A2	30(19)	32(19)	11	3	24(9)	3
HLA-B1	18	7	41	38(16)	18	7
HLA-B2		35	51(5)	49(21)	35	39(16)
HLA-DR1	1	3	4	11(5)	17(3)	1
HLA-DR2	3	7	15(2)	13(6)	13(6)	15(2)
Recipient						
Age (years)	9.8	13.5	2.6	12.2	12.7	1.3
Gender	Male	Male	Male	Female	Female	Male
Blood type	0	A	0	B	B	A
Body Surface Area (m ²)	1.09	1.17	0.50	1.14	1,27	0,40
Waiting list time (days)	142	9	71	193	204	82
PELD	-1	29	-8	20	21	2
HLA-A1	23(9)	2	1	26(10)	1	2
HLA-A2	29(19)			29(19)	32(19)	26(10)
HLA-B1	44(12)	18	51(5)	7	27	7
HLA-B2			57(17)	38(16)	35	44(12)
HLA-DR1	11(5)	11(5)	3	10	11(5)	4
HLA-DR2	7		11(5)	13(6)	16(2)	15(2)
Transplant operation						
GRBWR (liver)	1.6%	2.6%	3.5%	3.9%	1.8%	4.5%
CIT Liver (minutes)	551	565	584	430	332	556
WIT Liver (minutes)	21	42	29	37	19	38
CIT Kidney (minutes)	905	955	1000	849	545	916
WIT Kidney (minutes)	95	29	30	25	24	25
Donor/Recipient Match						
Donor/Recipient CMV	Neg/Pos	Pos/Pos	Pos/Pos	Pos/Pos	Neg/Neg	Neg/Pos
Donor/Recipient EBV	Neg/Neg	Neg/Pos	Neg/Neg	Neg/Pos	Neg/Pos	Neg/Neg
Crossmatch	Negative	Negative	Negative	Negative	Positive	Negative
Post-Transplant Course						
Immunosuppression	CsA+Aza+St	TAC+MMF+St	TAC+MMF+St	TAC+MMF+St	TAC+MMF+St	TAC+MMF+St
Induction	Basiliximab	Basiliximab	Basiliximab	Basiliximab	Basiliximab	Basiliximab
RRT post CLKT	Yes	No	Yes	No	No	Yes
ICU Stay days	27	14	12	6	7	7
Rejection - Liver	No	No	No	No	No	No
Rejection - Kidney	Chronic	No	No	No	No	No
Serum oxalate (µmol/L)						
Pre-CLKT	86	214	124	135	148	248

Table 1: Clinical features of the six PH1 patients undergoing CLKT. (Aza: Azathioprine; BSA: Body Surface Area; CIT: Cold Ischemia Time; CLKT: Combined Liver-Kidney Transplantation; CMV: Cytomegalovirus; CsA: Cyclosporine A; EBV: Epstein-Barr Virus; GRBWR: Graft to Recipient Body Weight Ratio; HLA: Human Leukocyte Antigens; ICU: intensive care unit; MMF: Mycophenolate mofetil; PELD: Paediatric End-stage Liver Disease; PH1: primary hyperoxaluria type 1; RRT: Renal Replacement Therapy; St: Steroids; Tac: Tacrolimus; WIT: Warm Ischemia Time).

Patient N.	1	2	3	4	5	6
<i>Year of transplantation</i>	2001	2010	2010	2017	2018	2018
Haplotype	mm	mm	MM	MM	MM	mm
Mutation allele 1	c.943-1G>T	c.943-1G>T	p.Asp201Glu	c.33dupC	p.Gly156Arg	p.Ile244Thr
Mutation allele 2	c.943-1G>T	c.943-1G>T	p.Asp201Glu	c.33dupC	c.33dupC	p.Ile244Thr

Table 2: Haplotype and mutations in the AGXT gene in the six PH1 patients undergoing CLKT. (CLKT: Combined Liver-Kidney Transplantation; PH1: primary hyperoxaluria type 1).

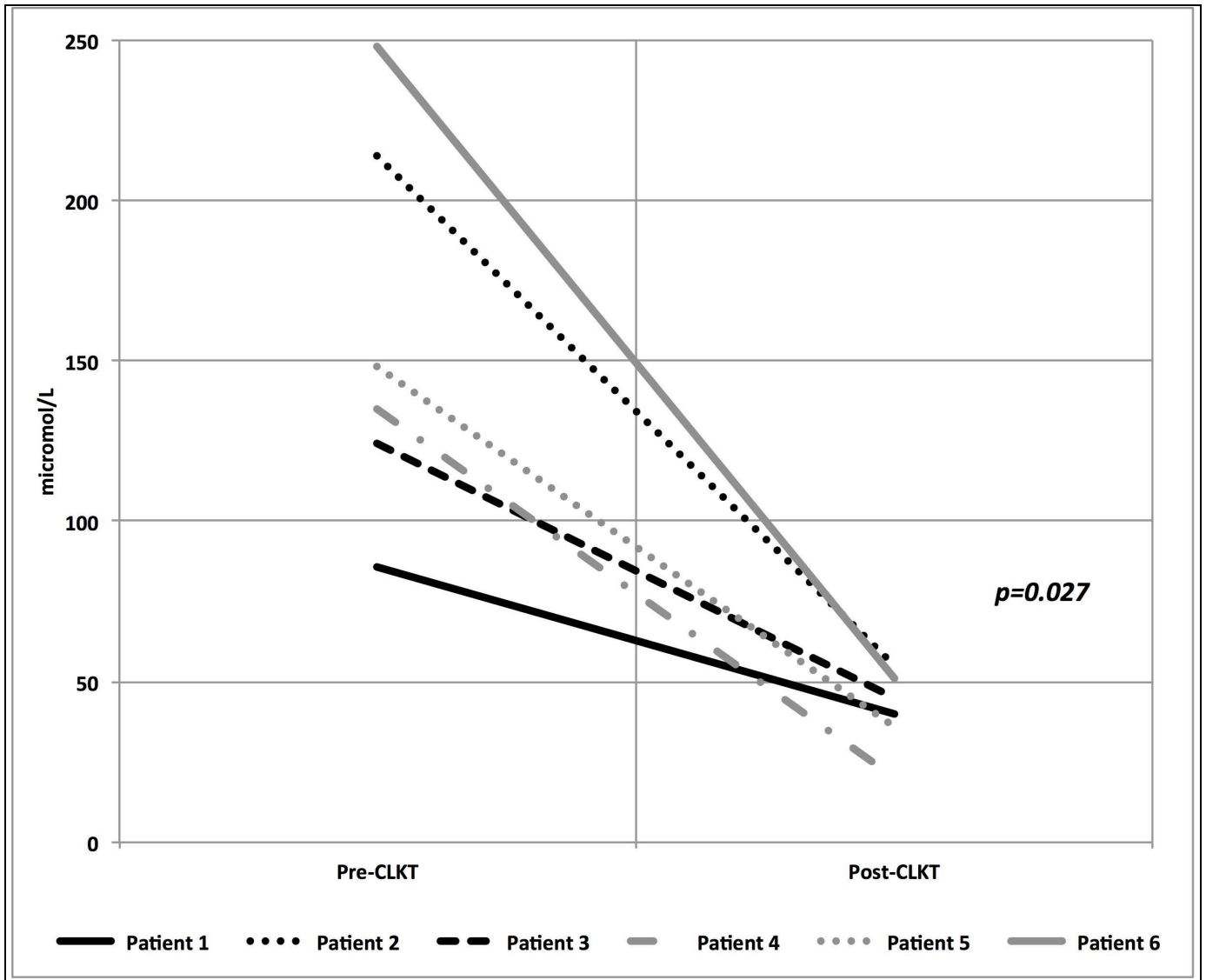


Figure 1: Pre- and post-CLKT (day 2) levels of serum oxalate in the six patients in study (CLKT: Combined liver and kidney transplantation). Patient 1, 3 and 6 underwent renal replacement therapy immediately after CLKT.