

AperTO - Archivio Istituzionale Open Access dell'Università di Torino

## Recovering two languages with the right hemisphere

### **This is the author's manuscript**

*Original Citation:*

*Availability:*

This version is available <http://hdl.handle.net/2318/1597953> since 2016-10-04T12:11:30Z

*Published version:*

DOI:10.1016/j.bandl.2016.05.014

*Terms of use:*

Open Access

Anyone can freely access the full text of works made available as "Open Access". Works made available under a Creative Commons license can be used according to the terms and conditions of said license. Use of all other works requires consent of the right holder (author or publisher) if not exempted from copyright protection by the applicable law.

(Article begins on next page)

# Recovering two languages with the right hemisphere

Andrea Marini <sup>a,b,c,†</sup>, Valentina Galetto <sup>d,e</sup>, Karina Tatu <sup>f,g</sup>, Sergio Duca <sup>g</sup>, Giuliano Geminiani <sup>e,f,g,h</sup>,  
Katuscia Sacco <sup>e,f,g,h</sup>, Marina Zettin <sup>d,e,f,†</sup>

<sup>a</sup> Dipartimento di Lingue e Letterature, Comunicazione, Formazione e Società, University of Udine, Udine, Italy

<sup>b</sup> Scientific Institute, IRCCS Eugenio Medea, San Vito al Tagliamento, Pordenone, Italy

<sup>c</sup> Claudiana – Landesfachhochschule für Gesundheitsberufe, Bolzano, Italy

<sup>d</sup> Centro Puzzle, Torino, Italy

<sup>e</sup> Center for Cognitive Science, Università degli Studi di Torino, Italy

<sup>f</sup> Dipartimento di Psicologia, Università di Torino, Italy

<sup>g</sup> Koelliker Hospital, Turin, Italy

<sup>h</sup> Neuroscience Institute of Turin, Italy

---

## abstract

---

### Keywords:

Traumatic brain injury  
Right hemisphere  
Aphasia recovery  
Ventricular dilation  
Bilingualism

Converging evidence suggests that the right hemisphere (RH) plays an important role in language recovery from aphasia after a left hemisphere (LH) lesion. In this longitudinal study we describe the neurological, cognitive, and linguistic profile of A.C., a bilingual who, after a severe traumatic brain injury, developed a form of fluent aphasia that affected his two languages (i.e., Romanian and Italian). The trauma-induced parenchymal atrophy led to an exceptional ventricular dilation that, gradually, affected the whole left hemisphere. A.C. is now recovering both languages relying only on his right hemisphere. An fMRI experiment employing a bilingual covert verb generation task documented the involvement of the right middle temporal gyrus in processes of lexical selection and access. This case supports the hypothesis that the RH plays a role in language recovery from aphasia when the LH has suffered massive lesions.

---

## 1. Introduction

Language is a complex cognitive function implemented in an extensive array of neural networks (Indefrey, 2014; Vigneau et al., 2006). For long time, the only way to study the neural organization of language relied on the observation of patients with linguistic impairments after focal lesions to the left hemisphere (LH). This approach allowed clinicians to identify areas potentially involved in lexical production and comprehension in the cortical layer of the LH (e.g., Broca, 1865; Geschwind, 1970). Over the past 20 years, converging evidence from both neuropsychological studies on patients with brain lesions and investigations of linguistic processing in healthy individuals suggests that also the right hemisphere (RH), far from being “mute”, plays an important role in selective aspects of language processing (Joanette, Goulet, & Hannequin, 1990; Myers, 1993). For example, persons with right

hemisphere damage may exhibit difficulties involving prosodic, pragmatic, and even narrative abilities (Ferré, Ska, Lajoie, Bleau, & Joanette, 2011; Lehman Blake, 2006; Marini, 2012; Marini et al., 2005). A recent meta-analysis of 128 studies involving right-handed healthy participants found that the involvement of the RH was marginal in phonological and semantic processing but significant in sentence and discourse processing (Vigneau et al., 2011).

A critical issue regards the role potentially played by the RH in aphasia recovery. Generally speaking, the plastic reorganization of the linguistic networks after a lesion requires a complex interplay between the recruitment of neurons in perilesional areas (Heiss & Graf, 1994), the modulation of existing synaptic connections, and the generation of new synapses (Tecchio et al., 2006). As highlighted in a recent critical survey on this topic (Gainotti, 2015), the role of the RH in linguistic recovery after a lesion to the LH is still controversial. Two major hypotheses have been formulated so far: the “interhemispheric inhibition hypothesis” and the “right hemisphere involvement hypothesis”. According to the former, a lesion of the language epicenters in the LH (e.g., in the left inferior frontal gyrus) might hypothetically release a transcallosal inhibition on homologue areas in the RH. This might interfere with

---

† Corresponding authors at: Università di Udine, Dipartimento di Lingue e Letterature, Comunicazione, Formazione e Società, Via Margreth, 3, 33100 Udine, Italy (A. Marini). Centro Puzzle, Via Cimabue 2 – CAP, 10137 Torino, Italy (M. Zettin).

E-mail addresses: [andrea.marini@uniud.it](mailto:andrea.marini@uniud.it) (A. Marini), [marina.zettin@unito.it](mailto:marina.zettin@unito.it) (M. Zettin).

the perilesional reorganization in the LH hampering the process of recovery from aphasia (Turkeltaub, 2015). If this were the case, the inhibition of the RH homologues of language areas in the LH should enhance language recovery in patients with aphasia after lesions to the LH. Over the past 10 years a growing number of studies have tested this hypothesis by applying inhibitory stimulation (i.e., low frequency Transcranial Magnetic Stimulation, TMS or cathodic transcranial direct current stimulation, tDCS) over RH homologues of language areas in such patients. For example, two seminal investigations by Martin et al. (2004) and Naeser et al. (2005) showed that low frequency rTMS over the right pars triangularis improved picture naming in persons with chronic non-fluent aphasia (see also two recent meta-analyses by Ren et al. (2014) and Ota, Olma, Floel, and Wellwood (2015) showing positive effects of RH inhibition on a number of linguistic functions). Critically, most of these studies have focused on the inhibition of a specific region of the RH (i.e., the right inferior frontal gyrus) leaving open the possibility that other areas of the same hemisphere, under specific circumstances, might play an active role in language recovery after a lesion to the LH (“right hemisphere involvement hypothesis”). These circumstances include: (1) the extension of the lesion in the LH, with large lesions more likely to recruit homologue areas in the RH (Anglade, Thiel, & Ansaldo, 2014; Heiss & Thiel, 2006);

(2) the time elapsed since the onset of aphasia, with a recruitment of areas in the RH more likely to occur in the acute phase after the lesion and a gradual decrease of such recruitment with time (e.g., Ansaldo, Arguin, & Roch Lecours, 2002; Saur et al., 2006); (3) the speed of the development of the lesion in the LH, with slowly pro-ceeding lesions rather than faster ones more likely to trigger a shift of linguistic functions to the RH (Thiel et al., 2006); (4) the specific linguistic function to be recovered, with a good level of semantic and lexical recovery but a much lower level of phonological and syntactic recovery after reorganization of language areas in the RH (Abel, Weiller, Huber, & Willmes, 2014; Wright, Stamatakis, & Tyler, 2012). The possibility of a right hemispheric involvement in language recovery has been supported by a study by Flöel et al. (2011) where anodal tDCS over the right temporo-parietal cortex improved naming in a cohort of twelve chronic persons with aphasia. Furthermore, this hypothesis is also in line with available evidence suggesting that the right hemisphere might play an active role in language recovery from aphasia (e.g., Barlow, 1877; Basso, Gardelli, Grassi, & Mariotti, 1989; Turkeltaub et al., 2012). For example, Barlow (1877) described the case of a boy with non-fluent aphasia after a stroke in the left inferior frontal gyrus who recovered his linguistic skills over time, but then worsened again after a symmetric stroke in the right hemisphere. This case was taken as evidence that the right hemisphere might assume functions of the left hemisphere in aphasic individuals. More recently, Turkeltaub et al. (2012) described the case of a 72-year-old woman who suffered from chronic non-fluent aphasia following left mid-dle cerebral artery ischemic stroke. In this patient, 10 daily inhibitory TMS sessions over the right pars triangularis improved naming skills. An fMRI scan confirmed the reduction in activity in the target area of the RH (but failed to show any increase in activity in the homologue areas of the LH). This apparently confirmed the “interhemispheric inhibition hypothesis”. However, three months after the TMS sessions, the patient suffered a right hemisphere stroke that significantly worsened her linguistic impairments. This supports the possibility that at least some areas of the RH might play a key role in language recovery.

Overall, these findings provide both indirect and direct evidence of the role played by the right hemisphere in language recovery from aphasia. In the current study we provide an accurate description of the neurological, cognitive and linguistic profile of A.C., a bilingual with parallel aphasia after severe traumatic brain injury. Most importantly, a large ventricular dilation affecting left

fronto-temporo-parietal regions has devastated his left hemi-sphere over a period of four months in which the left lateral ventricle kept dilating (from April until August 2009). Since then no further ventricular dilation was observable and only three months later (since November 2009) the patient initiated a gradual and very slow linguistic recovery of his two languages relying only on his RH. We believe that this case provides an opportunity to significantly contribute to the ongoing debate on the role played by the RH on language recovery.

## 2. Materials and methods

### 2.1. Case history

A.C. is a 24 years old right-handed male who was born in Romania. His limb dominance was determined according to the Edinburgh Handedness Inventory (Oldfield, 1971). At the age of 7 he moved with his family to Italy where he completed his instruction and was hired as mechanic. Before the insult, A.C. was a sequential bilingual with comparable levels of exposure to his two languages (L1 at home with family and relatives; L2 at work and with friends) and similar levels of proficiency in both Romanian (L1) and Italian (L2). His bilingual history was explored by administering the questionnaire contained in the first section of the Bilingual Aphasia Test (BAT; Paradis, 1987; see Table S1).

In April 2009, at age 19, A.C. was involved in a car accident and reported a severe traumatic brain injury (Glasgow Coma Scale = 4; post-traumatic amnesia > 1 month) resulting in a coma (20 days). Immediately after the accident, a first CT scan showed cerebral edema, subarachnoid hemorrhage (SAH), and a compression of the lateral ventricle in the left cerebral hemisphere (see Fig. 1a). A.C. received frontal-temporal craniotomy, followed by removal of necrotic brain tissue. After three months (July 2009), a second CT scan showed malacia in the left hemisphere, global dilation of the entire left ventricular system, and focal dilation ex vacuo of the left lateral ventricle. The global dilation was likely the consequence of the SAH, whereas the focal dilation of the lateral ventricle was determined by the left hemisphere malacia (see Fig. 1b). A third scan (August 2009) showed a further dilation of the left lateral ventricle that was particularly evident in the frontal, parietal and occipital lobes (see Fig. 1c). After this period, no further ventricular dilation was observable (see Fig. 1d). Immediately after the coma, A.C. was diagnosed with spastic tetraparesis, mostly right lateralized. In September 2009 his motoric impairment was still characterized by marked right hemiparesis that forced him to the use of a wheelchair. A.C. had been hospitalized for 18 months at the “Santa Croce” Hospital in Cuneo (Italy). During the hospitalization, he was mostly exposed to Italian, the language used by the medical staff. In October 2009 it was still not possible to perform a neuropsychological assessment and his linguistic skills were severely affected. He could not speak because of massive orofacial apraxia. In November 2009, A.C. could understand simple requests in Italian and in the same language could name colors but still not verbs and objects. His speech contained semantic paraphasias and perseverations. A first, still incomplete, neuropsychological assessment performed in May 2010 in Italian showed major difficulties as attested by his inability to complete several tests and the low scores obtained on the Mini-Mental State Examination (MMSE: 23/30) and on tests assessing attention (trail making A z-scores: 3.52; trail making B z-scores: 14; visual search test: z-scores: 3.33). In October 2010, A.C. eventually left the Hospital and began an intensive rehabilitation program at the Rehabilitation Center “Puzzle” in Turin, where his cognitive and linguistic skills were thoroughly assessed in different periods (see Table 1) and where he is still receiving cognitive and linguistic rehabilitation in Italian (his L2) twice a week in sessions of

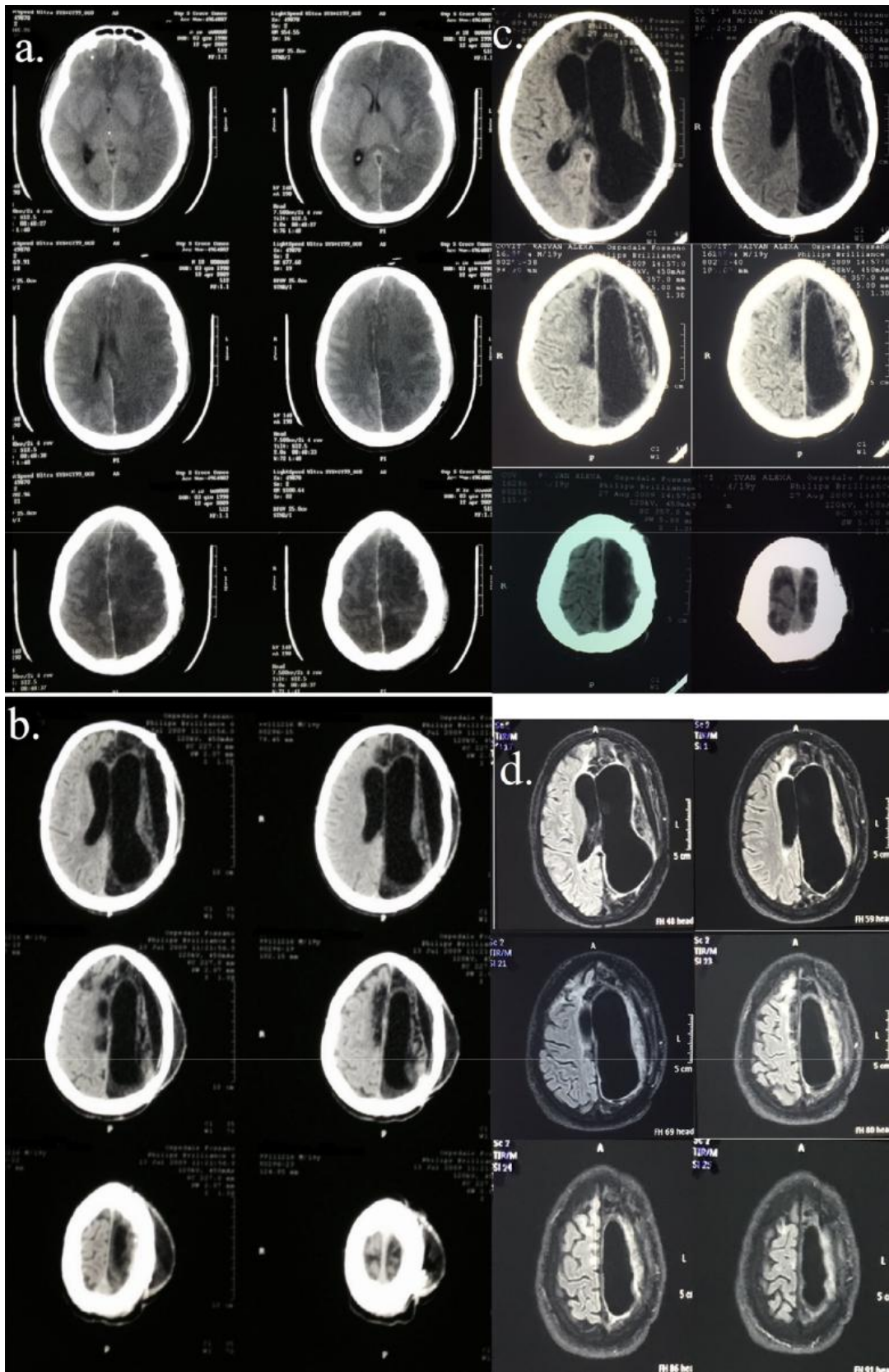


Fig. 1. Axial and sagittal scans showing the marked progression of ventricular dilation in A.C.: (a) first CT scan (April 2009) on the day of injury; (b) second CT scan (July 2009); (c) third CT scan (August 2009); (d) MRI scan (October 2013). Images are in radiological perspective with left on the viewer's right.

**Table 1**  
A.C.'s neuropsychological, linguistic, and narrative profile in L2 in October 2010 and August 2012. Asterisks indicate when the performance on neuropsychological testing was below the cut-off for normality. For AAT scores, the absence/entity of impairment is shown.

	1st Neuropsychological assessment (October, 2010)	2nd Neuropsychological assessment (August, 2012)
<b>Attention</b>		
TM-A (seconds, cutoff <93)	78.2	89
TM-B (seconds, cutoff <282)	268.2	182
<b>Memory</b>		
Rey's word immediate recall (recalled items, cutoff >28.5)	26.5*	27.9*
Rey's word delayed recall (recalled items, cutoff >4.7)	1.2	2.2
Verbal Span Forward (recalled digits, cutoff >3)	2.3	3.5
Spatial Span Forward (recalled spatial configurations, cutoff >3.8)	3.5	3.5
Spatial Learning Task (learned items, cutoff > 5.8)	4.9	5.0
<b>Logical reasoning</b>		
Raven's Test (correct answers, cutoff > 14.8)	19.3	24.5
<b>Executive functions</b>		
Tower of London (seconds, cutoff > 24.9)	18*	24*
Phonemic fluency (words produced, cutoff > 16)	0	15
<b>Language – AAT (Italian, L2)</b>		
Token Test	8/50 (errors) - Mild impairment	7/50 (errors) - Mild impairment
Repetition	146/150 - Absence of impairment	150/150 - Absence of impairment
Written language	90/90 - Absence of impairment	90/90 - Absence of impairment
Naming	82/120 - Moderate impairment	81/120 - Moderate impairment
Comprehension	78/120 - Moderate impairment	92/120 - Mild impairment
<b>Narrative language – (Italian, L2)*</b>		
Words	51.00 (12.73) – z-scores: 1.20	39.00 (22.63) – z-scores: 1.44
Speech Rate	58.29 (11.35) – z-scores: 3.10	43.38 (6.31) – z-scores: 3.62
MLU	2.68 (0.82) – z-scores: 2.99	3.00 (0.61) – z-scores: 2.79
% Phonological Errors	5.91 (3.94) – z-scores: 10.86	2.42 (3.42) – z-scores: 4.15
% Semantic Paraphasias	16.99 (7.39) – z-scores: 10.60	9.73 (2.88) – z-scores: 5.80
% Syntactic completeness	25.79 (8.19) – z-scores: 2.69	18.01 (5.27) – z-scores: 3.15
% Local Coherence Errors	40.92 (5.77) – z-scores: 14.72	15.22 (21.52) – z-scores: 4.92
% Global Coherence Errors	48.55 (9.12) – z-scores: 3.81	22.36 (11.42) – z-scores: 1.32
% Lexical Informativeness	36.44 (7.77) – z-scores: 5.62	67.55 (16.43) – z-scores: 1.95

Legend: AAT: Aachener Aphasia Test.

\*The second narrative assessment took place in April 2013.

one hour. The speech therapy program focuses on recovering communicative, semantic, morphosyntactic, and syntactic skills through a variety of tasks: from picture naming, semantic fluency, and sentence completion tasks to oral and written picture descriptions. Furthermore, A.C. has received also tasks for enhancing his verbal planning and sentence transformation skills. In order to enhance also his communicative efficacy, A.C. has received also the Promoting Aphasics' Communicative Exchange (PACE; Carlomagno, 1994) protocol.

## 2.2. Neuropsychological assessment

The neuropsychological assessment, performed in two separate sessions in October 2010 and August 2012, included tests aimed at quantifying his sustained and selective attention (Trail Making Test, A and B (Reitan, 1992)), visuo-spatial memory (Spatial Span Test [short-term memory: Spinnler & Tognoli, 1987]; Spatial Learning Task [long-term memory: Capitani, Grossi, Lucca, Orsini, & Spinnler, 1980]), short and long term verbal memory (Verbal Span Test (Spinnler & Tognoli, 1987); Rey's 15-word Immediate and Delayed Recall (Rey, 1958)), logical reasoning (Raven's Progressive Matrices (Raven, 1938)), executive functions (Tower of London (Shallice, 1982); phonemic fluency (Novelli et al., 1986)) and linguistic skills in Italian (Italian version of the Aachener Aphasia Test; Luzzatti, Illmes, & DeBleser, 1991). Finally, in order to obtain additional information about his linguistic and communicative skills in Italian, A.C. received also a narrative-picture description task. Namely, he was asked to describe the stories depicted in two cartoon stories with six pictures each, presented on the same page (the stories of the "Flower Pot" by Huber and Gleber (1982) and

the "Quarrel" story by Nicholas and Brookshire (1993)). Each story-telling was tape-recorded and transcribed verbatim by two authors (AM and VG). The transcripts underwent a comprehensive multi-level analysis of discourse production, which focused on both micro- and macrolinguistic aspects of narrative production (Marini, Andreatta, del Tin, & Carlomagno, 2011). Microlinguistic measures included the analysis of productivity (in terms of words, speech rate [i.e., words per minute] and Mean Length of Utterance [MLU; words per utterance]), production of lexical errors (% of phonological errors and % of semantic errors produced during the description), production of grammatically well-formed sentences (% of Complete Sentences to utterances), production of errors in establishing the correct relations between contiguous utterances (% Local Coherence Errors), production of tangential, filler, repetitive or conceptually incongruent utterances (% Global Coherence Errors), and production of informative words (% Lexical Informativeness) and of complete stories (% Thematic Selection). For an exhaustive description of these procedures please refer to Marini et al. (2011) and to the Supplementary Materials to this article. The scoring procedure was performed independently by two of the authors (AM and VG) and then compared. Acceptable inter-rater reliability was set at Cohen's  $k$  P 0.80, a level of interrater reliability reached also in preceding studies (e.g., Marini & Urgesi, 2012).

## 2.3. Assessment of A.C.'s bilingual profile

In order to have an accurate estimation of his linguistic profile in both L1 (Romanian) and L2 (Italian), in 2013 A.C.'s bilingual history was explored by administering the questionnaire contained in



the first section (Part A) of the Bilingual Aphasia Test (BAT; [Paradis, 1987](#)). A.C.'s bilingual profile was further explored by administering in 2013 and 2014 the Italian and Romanian versions of the Western Aphasia Battery (WAB; [Kory Calomfirescu, 1996](#); [Villardita, Quattropiani, Lomeo, & Gruppo Italiano WAB, 1994](#)).

## 2.4. fMRI experiment: verb generation tasks in Italian and Romanian

### 2.4.1. Tasks

A.C. underwent fMRI scanning at the Ospedale Koelliker in Turin (Italy) during the execution of a covert verb-generation task originally developed by [Petersen, Fox, Posner, Mintun, and Raichle \(1988\)](#) and adapted for fMRI by [Benson et al. \(1999\)](#). We used a covert version of the verb generation task because overt speech causes both poorly correctable movements and susceptibility image artefacts. Furthermore, this is a well-established fMRI task generally used to assess language lateralization in clinical populations with reliable results. It has been demonstrated to strongly activate brain areas involved in language production and comprehension in both healthy and clinical populations ([Eaton et al., 2008](#); [Szaflarski, Holland, Schmithorst, & Byars, 2006](#)).

Before the scanning session, A.C.'s comprehension of the task was assessed. Namely, he received a training session with new stimuli (concrete nouns) not previously used in the fMRI session. A.C. was asked to overtly respond to each heard noun by generating an associated verb. For example, after hearing the noun 'food', he would be expected to generate a verb such as cook or eat. The patient rehearsed the task until satisfactory performance was achieved (i.e., the patient produced the target verb for each heard noun). After this overt verb generation training, the patient rehearsed the task silently in order to ensure he would perform it correctly during the scan. Before entering the scanner, the patient rehearsed the task, first with verbal responses to check his comprehension, and then silently to assure he would perform it correctly during the scan. During the fMRI session A.C. listened to a list of concrete nouns and was asked to covertly generate the corresponding verbs. The words were randomly presented with no repeated items. The patient was instructed to think the verbs silently, and not to say them aloud. In the control condition, the patient was asked to count forward, from one to ten and again, following his own pace; this control task was specifically designed to distract the patient from verb generation during the control period. Immediately after the scanning session, the patient received questions about his performance in order to ensure that the task was accurately carried out. Namely, we asked the patient about the words he had heard during the scanning session and about the covertly generated responses. We have previously used this same version of the paradigm in a series of clinical cases, with reliable results ([Spena et al., 2010](#)). The task was presented in two versions: Italian (first run) and Romanian (second run). We used a block design with 9 blocks of active condition (i.e. verb generation) alternating with 10 blocks of control condition (i.e. self-paced forward counting), for a total of 19 blocks per run with 21 s of the verb generation condition alternating with 15 s of the control condition. The counting condition was used to ensure that at the end of an active block, the patient was not continuing to covertly generate or think to verbs related to the nouns presented during the active block. This control task was specifically designed to distract the patient from verb generation during the blocks of control condition. Each verb generation block comprised 6 words, for a total of 54 words per run. Each run, comprising a total of 19 blocks (9 active conditions, 10 control conditions), lasted 5.65 min. All tasks were generated using E-Prime software (Psychology Software Tools, Inc. Pittsburgh, PA, USA). The stimuli were presented by IFIS-SA™ (MRI Device Corporation, Waukesha, WI, USA), which also synchronized the presentation of stimuli with the fMRI scanner.

### 2.4.2. Image acquisition

Data acquisition was performed with a 1.5 T Intera scanner (Philips Medical Systems). Functional T<sub>2</sub>-weighted images were acquired using echoplanar (EPI) sequences, with a repetition time (TR) of 3000 ms, an echo time (TE) of 60 ms, and a 90L flip angle. The acquisition matrix was 64 64; the field of view (FoV) was 256 mm. For each task (Italian; Romanian), a total of 113 volumes were acquired. Each volume consisted of 20 axial slices, parallel to the anterior-posterior (AC-PC) commissure line and covering the whole brain; the slice thickness was 5 mm without gap. Two volumes were imaged (but not collected) at the beginning of each run to reach a steady-state magnetization, before subsequent acquisition of the experimental data.

In the same session, a set of three-dimensional high-resolution T<sub>1</sub>-weighted structural images was acquired for the patient. This data set was acquired using a Fast Field Echo (FFE) sequence, with a repetition time (TR) of 25 ms, the shortest echo time (TE), and a 30L flip angle. The acquisition matrix was 256 256; the field of view (FoV) was 256 mm square. The data set consisted of 160 contiguous sagittal images covering the whole brain, with a voxel size of 1 mm 1 mm 1 mm.

### 2.4.3. Data analysis

We analyzed imaging data using Brain Voyager QX 2.3 (Brain Innovation, Maastricht, Holland). The functional data underwent the following preprocessing steps: mean intensity adjustment, slice scan time correction with cubic spline interpolation, 3D motion correction with trilinear/sinc interpolation, spatial smoothing with a 3D Gaussian filter (FWHM = 4 mm), temporal filtering with high-pass 2 sines/cosines. After pre-processing, the fMRI data of the patient were co-registered to the associated 3D high resolution structural scan, which was transformed into Talairach space ([Talairach & Tournoux, 1988](#)). The pre-processed fMRI data were subsequently transformed into Talairach space using the anatomical-functional coregistration matrix and manually-determined Talairach reference points.

For each version of the task (i.e., Italian and Romanian), a single-subject study design matrix was specified and the box-car was convolved with a predefined hemodynamic response function (HRF) ([Boynton, Engel, Glover, & Heeger, 1996](#)) to account for the hemodynamic delay. The design matrix was constructed using a single predictor (i.e. verb generation condition) and a constant (baseline). The statistical analyses based on the general linear model (GLM) were performed separately for the Italian and Romanian versions of the task to yield functional activation maps for each version. The specified model consisting in a single predictor (verb generation) was fitted to the time course of each voxel and t-statistical maps were obtained. The results were thresholded at  $p < 0.05$  corrected for multiple comparisons using the Bonferroni correction method. In order to generate volumes of interests and compute their peaks of activation, a default cluster threshold of 300 anatomical sized voxels has been used. To label anatomical structures we used the Talairach Daemon ([Lancaster et al., 2000](#)), a digitalized version of the Talairach atlas.

## 3. Results

### 3.1. Neuropsychological assessment

[Table 1](#) shows the cognitive profile of A.C. in 2010 and 2012. On the first neuropsychological assessment, a general improvement was clearly observable in his performance. However, A.C. had still significant difficulties on some tasks assessing executive functions, memory, and language. Even if normal on the two tests of attention (TM-A and TM-B), his performance was below the cut-off for

normality on tests assessing verbal and nonverbal learning (Rey's word immediate and delayed recall, Spatial Learning Task), verbal and spatial short-term memory (Verbal Span Test and Spatial Span Test), and executive functions (Tower of London and Phonemic Fluency). As shown in Table 1, the linguistic assessment, limited to Italian, was performed by administering the Italian version of the AAT leading to a diagnosis of moderate fluent aphasia. His writing skills were surprisingly unaffected. However, his naming and comprehension skills were still moderately affected and mild difficulties characterized his performance at the Token test confirming the impairment also in verbal working memory. Interestingly, the multilevel procedure for discourse analysis revealed the patient's productivity in Italian was indeed moderately affected. For this analysis, we recruited a cohort of 16 healthy individuals aged 20 through 30. They were asked to produce samples of narrative discourse by describing the same cartoon-picture stories as A. C. Their performance is detailed in Table S2. These data were used to calculate z-scores in order to determine the quality of the narrative performance of A.C. The results confirmed that in October 2010 A.C. had still relevant difficulties in linguistic production (see Table 1). Namely, his speech rate and MLU were far below normal level as he produced several phonological and semantic errors and only 25.79% of his utterances were grammatically well-formed sentences. He still produced several errors of local (mainly words without clear referents) and global coherence. As a result, his lexical informativeness was severely impaired.

As shown in Table 1, the cognitive profile emerging from the second neuropsychological assessment performed in August 2012 and April 2013 for what concerns the analysis of his narrative production skills, showed a further improvement. This improvement, however, was not homogeneously distributed across the different cognitive domains. Indeed, it was marginal for tests assessing memory with the notable exception of the performance on the Verbal Span Test, and significant for tests assessing executive functions. However, his linguistic profile was still characterized by a moderate aphasic disorder with persisting difficulties in naming with some improvement in lexical comprehension. Noteworthy, in spite of the entity of the cerebral damage, A.C.'s communicative ability had improved. As reported by his family, his peers and by the speech therapist, he was able to suitably interact with other

people. This was confirmed by the gradual increase in his narrative performance. Indeed, the multilevel procedure of narrative assessment revealed that the production of phonological and semantic errors (although still relevant) had significantly decreased. Furthermore, at the time of this assessment A.C. produced fewer errors of local and global coherence and his lexical informativeness raised from a mere 36% of all uttered words to 67.55% of informative words.

### 3.2. Assessment of A.C.'s bilingual profile

In September 2013 and August 2014 A.C. received a thorough linguistic assessment in his two languages with the Romanian and Italian versions of the WAB (see Table 2). This assessment showed that the mild fluent aphasia still observable in 2013 further evolved in 2014. The Aphasia Quotient was comparable across the two languages (77.2 and 77.6 in 2013 and 86.2 and 86.4 in 2014 for Romanian and Italian, respectively). A qualitative inspection of the linguistic performance of A.C. on these tests confirmed the absence of articulatory deficits (the performance on Repetition was at ceiling in both languages) but highlighted the presence of comparable difficulties in lexical production in both languages (Naming Total: 51/100 and 48/100 in 2013 and 63/100 and 61/100 in 2014 for L1 and L2, respectively). Mild difficulties in Reading and Writing across the two languages were still observable (Reading: 81/100 and 72/100 in 2013 and 97/100 and 82/100 in 2014 in L1 and L2, respectively; Writing: 82/100 in both languages in 2013 and 69/100 and 82/100 in 2014 for L1 and L2, respectively). As for Comprehension, both languages were mildly affected but with different levels of gravity and showed a remarkable improvement at the last assessment (Comprehension Total: 152/200 and 120/200 in 2013 and 178/200 and 182/200 for L1 and L2, respectively).

### 3.3. Results on the verb generation task

In both languages during the verb generation task a cluster of activation was found in the right middle temporal gyrus (rMTG; BA 22) (Italian:  $t = 6.69$ , peak of activation in Talairach coordinates  $x = 54$ ;  $y = 32$ ;  $z = 3$ ; Romanian:  $t = 6.52$ , peak  $x = 56$ ;  $y = 35$ ;

Table 2  
Linguistic profile of A.C. in L1 and L2 in September 2013 and August 2014.

Western Aphasia Battery	Romanian (L1) (2013)	Italian (L2) (2013)	Romanian (L1) (2014)	Italian (L2) (2014)
Aphasia quotient	77.2/100	77.6/100	86.2/100	86.4/100
Spontaneous language				
Informative content	8/10	9/10	9/10	9/10
Fluency	8/10	9/10	9/10	9/10
Total	16/20	18/20	18/20	18/20
Comprehension				
Yes/No questions	54/60	54/60	54/60	57/60
Words	50/60	44/60	57/60	53/60
Sequential Orders	48/80	22/80	67/80	72/80
Total	152/200	120/200	178/200	182/200
Repetition	99/100	100/100	99/100	100/100
Naming				
Object naming	31/60	29/60	40/60	36/60
Verbal fluency	6/20	7/20	9/20	9/20
Sentence Completion	6/10	4/10	6/10	10/10
Questions/answers	8/10	8/10	8/10	6/10
Total	51/100	48/100	63/100	61/100
Reading & writing				
Reading	81/100	72/100	97/100	82/100
Writing	82/100	82/100	69/100	82/100
Total	163/200	153.5/200	166.2/200	164/200

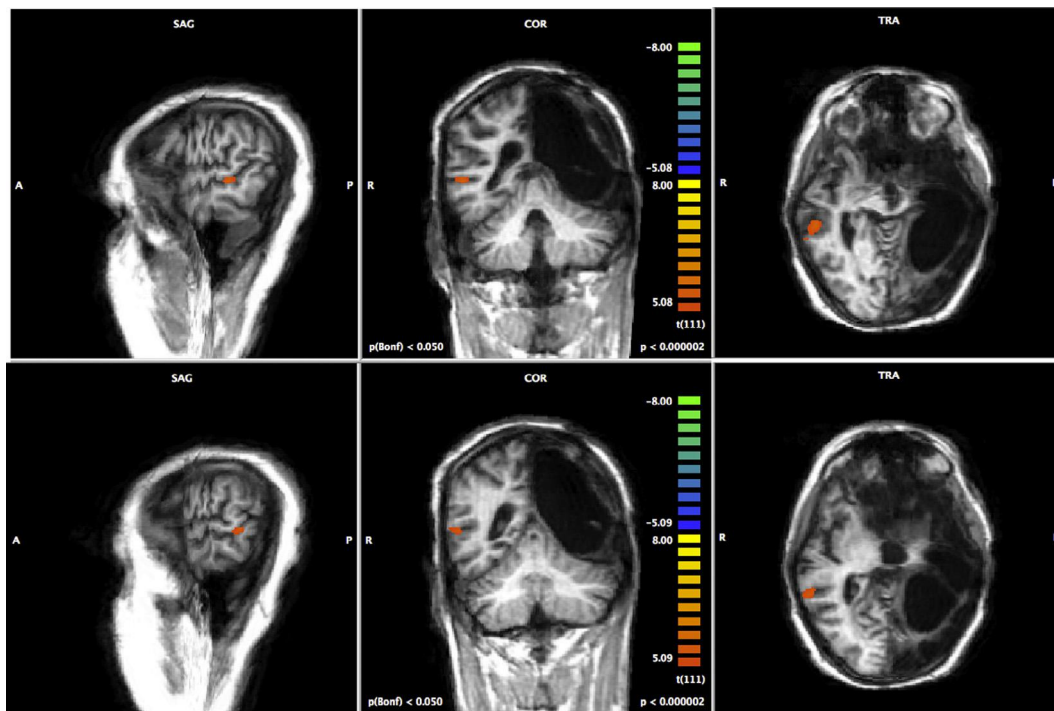


Fig. 2. Verb generation activation maps for the Italian (first row) and the Romanian (second row) versions of the task.

$z = 5$ ). Fig. 2 shows the map of activations for Italian (first row) and Romanian (second row), respectively.

#### 4. Discussion

This study focused on the longitudinal analysis of the neural, cognitive, and linguistic features of a bilingual person with high proficiency in L1 and L2 and high levels of exposure to both languages who had sustained a severe TBI. His cognitive and linguistic performance was compared to normative data available for Italian language for the AAT, the WAB and the Neuropsychological tests. As for Romanian, WAB normative data for that language were used. The trauma-induced parenchymal atrophy led to an exceptional ventricular dilation that, over a period of three months, affected the whole left hemisphere. After a long period in which he was not testable, in spite of the severity of the lesion A.C. showed a still incomplete but absolutely remarkable parallel recovery of his two languages. These findings (1) provide evidence of linguistic recovery after an exceptional ventricular dilation triggered by a severe TBI; (2) suggest that sites in the RH might support language recovery when the LH has suffered massive lesions; (3) support the hypothesis that some linguistic functions cannot be easily recovered at an optimal level using only the RH.

The first issue concerns the exceptional ventricular dilation observed in A.C. After TBI, patients usually experience massive fronto-temporal lesions (Bigler, 2007). The damaged axons may suffer a retraction and degenerate to the cellular body, producing neuronal death, or degenerate distally (Verger et al., 2001). The diffuse axonal injury induced by the trauma evolves gradually (e.g., Bendlin et al., 2008; Warner et al., 2010), leading to progressive sulcal enlargement, damage to callosal fibers with consequent deformation of the corpus callosum (Viano et al., 2005), and passive expansion of the ventricular system (e.g., Poca et al., 2005). This ventricular enlargement has been correlated with coma duration, memory skills, cognitive status, and even prognosis for independent living (Levin, Handel, & Goldman, 1985; Levin et al., 1990;

Reider-Groswasser, Cohen, Costeff, & Grosswasser, 1993). That said, to the best of our knowledge, a massive ventricular enlargement such as the one observed in A.C. has never been reported before. As shown in Fig. 1a–c, the ventriculomegaly evolved quite rapidly, affecting frontal, temporal and parietal lobes of the left hemisphere. This is coherent with the symptomatology experienced by A.C. after the accident. Five months after the injury it was still not possible to perform a neuropsychological assessment and he could not use either of his two languages. One and a half year after the insult, A.C.'s attentive skills and non-verbal logical reasoning had eventually normalized even if he was still experiencing significant disturbances of memory, language, and executive functions. This general picture showed a slight improvement when his cognitive skills had been further assessed almost 2 years later (3 years after the accident).

A second issue concerns the still incomplete but absolutely remarkable parallel recovery of the two languages mastered by A.C. before the insult. Because of the massive neural damage, his linguistic profile changed with an extremely slow pace over time. During the first year after the insult, he suffered from a form of parallel global aphasia: both L1 and L2 were severely affected in all modalities. However, as shown in Table 1, during the second year after the trauma the patient's linguistic profile ameliorated and he was finally testable. At this stage, the first assessment in his L2 showed the presence of moderate fluent aphasia. A.C. had still moderate difficulties in both naming and comprehension. The multilevel procedure for discourse analysis confirmed that his speech rate was significantly affected and his utterances were much shorter than normal (see Table S2 for the performance of the control participants). His lexical production was characterized by several phonological and semantic errors. Relevant difficulties were also found in the production of grammatically well-formed sentences as well as in his macrolinguistic skills: A.C. still produced a high number of errors of local and global coherence and all these problems significantly lowered his levels of lexical informativeness. Interestingly, his linguistic profile significantly improved over the following two years leading to a diagnosis of mild fluent



aphasia. Indeed, In August 2012 A.C. improved in comprehension but still experienced moderate difficulties in naming. The narrative assessment performed in April 2013 allowed us to better describe the features of this linguistic improvement. A.C. had still significant difficulties in speech rate and produced shorter utterances with respect to the group of healthy individuals. However, his phono-logical and semantic skills, still significantly impaired, showed an improvement from 10.9 and 10.6 to 4.2 and 5.8 z-scores, respectively. His syntactic skills were still impaired but his macrolinguis-tic skills improved leading to the production of a sensibly higher number of informative words. This confirms the possibility that the RH alone can lead to a significant but still incomplete language recovery. Interestingly, the linguistic assessment with the Western Aphasia Battery in Romanian and Italian confirmed the diagnosis of mild-to-moderate fluent aphasia in both languages with a parallel recovery of his two languages in 2013 and showed a further improvement in 2014 which led to two comparable aphasia quo-tients of 86.2 and 86.4 for Romanian (L1) and Italian (L2). Overall, these findings suggest that the RH can play a role in linguistic recovery in patients with aphasia following the almost complete loss of the LH.

This consideration leads us to the third relevant issue concern-ing the neural (re)organization of the linguistic networks of A.C. Unfortunately, we do not have any neuroradiological data attesting the organization of such neural networks before the insult. We know that the patient was fully right-handed. This doesn't allow us to completely rule out the possibility that A.C. might have been among the <2% of right-handed individuals with right hemisphere language dominance; that is indeed the incidence of crossed aphasia, i.e. aphasia in right-handed patients after right hemisphere injury (Gloning, Gloning, Haub, & Quatember, 1969; Zangwill, 1967). Nonetheless, the fact that A.C. was right-handed supports the possibility of a left-hemispheric functional lateralization of his lexical and grammatical skills. This hypothesis is also supported by the severe aphasic deficits experienced by the patient during the hospitalization. Indeed, the slow linguistic recovery supports the possibility of a massive reorganization of the linguistic system in the RH (e.g., Krieg et al., 2013; Szaflarski et al., 2006). The still incomplete but absolutely remarkable parallel recovery of both languages lends direct evidence in support of the hypothesis of a right hemispheric involvement in the reorganization of the neural networks implicated in language after a left hemispheric lesion (e.g., Saur et al., 2006). The role of the right hemisphere in this recovery has been further demonstrated by the functional activa-tions in right middle temporal gyrus during the covert verb gener-ation task. This finding is particularly interesting. In healthy individuals, this task usually elicits activations in left fronto-temporo-parietal areas as well as in the right cerebellum (Allendorfer, Kissela, Holland, & Szaflarski, 2012; Fiez, Raichle, Balota, Tallal, & Petersen, 1996; Szaflarski et al., 2006). For exam-ple, in a group of 32 healthy adult participants, Allendorfer et al. (2012) reported activations in an articulated neural network which comprised areas in the LH (left middle frontal gyrus, left middle temporal gyrus, left inferior parietal lobule), RH (right superior temporal gyrus) and in both hemispheres (bilateral insula and superior temporal, inferior frontal and cingulate gyri) as well as the right cerebellar hemisphere. In the same study, 16 chronic aphasic participants with lesions in the LH showed a partially dif-ferent pattern of activations in the LH (left parahippocampal, mid-dle and superior temporal gyri, and left middle frontal gyrus), RH (right middle and superior temporal gyri), bilaterally (bilateral superior and inferior frontal gyri) with the involvement of the basal ganglia (left caudate). In A.C. the LH could not contribute to such a network and we found a cluster of activation only in the right middle temporal gyrus for both languages (see Fig. 1). This suggests that in this patient the reorganization of the neural

network that subserves the process of lexical selection has recruited an epicenter (the right middle temporal gyrus) which mirrors the activation in the left middle temporal gyrus observed in the group of healthy participants in the study by Allendorfer et al. (2012).

As shown in the Introduction, some previous single case studies supported the hypothesis that the RH plays a role in language recovery (Barlow, 1877; Basso et al., 1989; Turkeltaub et al., 2012). Furthermore, a number of investigations have shown right hemispheric activations during the execution of linguistic tasks in right-handed patients with lesions to the left hemisphere. For example, such activations have been reported in the right superior temporal gyrus (Weiller et al., 1995) as well as in the right inferior frontal gyrus (Schlosser et al., 2002) also in aphasic patients after stroke (e.g., Basso et al., 1989; Heiss, Kessler, Thiel, Ghaemi, & Karbe, 1999; Ohyama et al., 1996; Raboyeau et al., 2008; Saur et al., 2006; Winhuisen et al., 2005). A few investigations have ana-lyzed the patterns of linguistic recovery and plastic reorganization in persons with slowly progressive lesions such as those with brain tumors (e.g., Thiel et al., 2001, 2006). For example, Thiel et al. (2001) showed that a significant linguistic-related activation was observable in the right inferior frontal lobe in 60% of a cohort of right-handed patients with tumors in the left hemisphere. This is striking when one considers that in healthy right-handed individ-uals these percentages are much lower, with barely 7.5% showing right-hemispheric lateralization for the same functions (e.g., Knecht et al., 2000). Interestingly, Thiel et al. (2006) further showed that the probability of a right hemispheric involvement in the linguistic reorganization after a brain injury correlates with the time elapsed after the lesion. The authors investigated linguis-tic processing in right-handed patients with tumors in the left hemisphere. They could not find any right-sided lateralization of language functions in those patients who presented rapidly pro-gressive lesions. Instead, in those with slowly progressive lesions linguistic processing was found lateralized in the right hemisphere. This suggests that the time elapsed after a lesion might be a key factor in shaping the reorganization of linguistic processing in this hemisphere. In this sense, A.C. provides an opportunity to observe the progressive recovery of linguistic functions through the shift-ing of linguistic functions in the right hemisphere. However, his linguistic recovery is still not complete. Indeed, persons with apha-sia who use the right frontal lobe to complete language tasks might perform worse than patients relying on their left hemispheric per-ilesional tissue (Winhuisen et al., 2005). According to Krieg et al. (2013), the process of language reorganization in the right hemi-sphere might not always fully compensate for the loss of brain tis-sue in the left one. Therefore, the former alone might not provide a perfect mastery for complex linguistic processes still relatively inefficient in A.C.'s both languages such as those involved in lexical selection and access (Boatman et al., 1998) and grammatical struc-turing (Stark, Bleile, Brandt, Freeman, & Vining, 1995).

## 5. Conclusion

In conclusion, the results of this case study are coherent with previous observations (e.g., Turkeltaub et al., 2012) where LH lesions induced compensatory reorganization in the RH. This sup-ports the hypothesis that the RH plays a role in language recovery from aphasia when the LH has suffered massive lesions. Further-more, it documents the role of the right middle temporal gyrus in processes of lexical selection (i.e., in a task of bilingual covert verb generation). Some clinical implications can be derived by these findings. First of all, in case of massive lesions to the LH lan-guage therapy protocols should target functions that induce the recruitment of the RH in language processing. As suggested by

investigations by Schlaug, Marchina, and Norton (2009) and Crosson et al. (2005), at least one of these protocols (i.e., Melodic Intonation Therapy) might induce a remodeling of language functions in the RH. Overall, in line with a few previous investigations (e.g., Vines, Norton, & Schlaug, 2011) these findings highlight the need for future studies targeting the effects of high-frequency rTMS or anodal tDCS over RH areas in aphasia recovery after large lesions in the LH.

## Acknowledgments

This work was partially supported by a grant from IRCCS “E. Medea” (Progetto 5x1000, Italian Ministry of Health) to A.M.

## Appendix A. Supplementary data

## References

- Abel, S., Weiller, C., Huber, W., & Willmes, K. (2014). Neural underpinnings for model-oriented therapy of aphasic word production. *Neuropsychologia*, 57, 154–165.
- Allendorfer, J. B., Kissela, B. M., Holland, S. K., & Szaflarski, J. P. (2012). Different patterns of language activation in post-stroke aphasia are detected by overt and covert version of the verb generation fMRI task. *Medical Science Monitor*, 18(3), CR135–CR147.
- Anglade, C., Thiel, A., & Ansaldo, A. I. (2014). The complementary role of the cerebral hemispheres in recovery from aphasia after stroke: A critical review of literature. *Brain Injury*, 28, 138–145.
- Ansaldo, A. I., Arguin, M., & Roch Lecours, A. (2002). The contribution of the right cerebral hemisphere to the recovery from aphasia: A single longitudinal case study. *Brain and Language*, 82, 206–222.
- Barlow, T. (1877). On a case of double cerebral hemiplegia, with cerebral symmetrical lesions. *British Medical Journal*, 2, 103–104.
- Basso, A., Gardelli, M., Grassi, M. P., & Mariotti, M. (1989). The role of the right hemisphere in recovery from aphasia. Two case studies. *Cortex*, 25, 555–566.
- Bendlin, B. B., Ries, M. L., Lazar, M., Alexander, A. L., Dempsey, R. J., Rowley, H. A., ... Johnson, S. C. (2008). Longitudinal changes in patients with traumatic brain injury assessed with diffusion tensor and volumetric imaging. *Neuroimage*, 42, 503–514.
- Benson, R. R., FitzGerald, D. B., LeSueur, L. L., Kennedy, D. N., Kwong, K. K., Buchbinder, B. R., ... Rosen, B. R. (1999). Language dominance determined by whole brain functional MRI in patients with brain lesions. *Neurology*, 52, 798–809.
- Bigler, E. D. (2007). Anterior and middle cranial fossa in traumatic brain injury: Relevant neuroanatomy and neuropathology in the study of neuropsychological outcome. *Neuropsychology*, 21, 515–531.
- Boatman, D., Hart, J., Lesser, R., Honeycutt, N., Anderson, N., Miglioretti, D., & Gordon, B. (1998). Right hemisphere speech perception as revealed by amobarbital injection and electrical interference. *Neurology*, 51, 458–464.
- Boynton, G. M., Engel, S. A., Glover, G. H., & Heeger, D. J. (1996). Linear systems analysis of functional magnetic resonance imaging in human V1. *The Journal of Neuroscience*, 16(13), 4207–4221.
- Broca, P. (1865). Sur le siège de la faculté du langage articulé. *Bulletins de la Société d'Anthropologie*, 6, 377–393.
- Capitani, E., Grossi, D., Lucca, M., Orsini, A., & Spinnler, H. (1980). Spatial and color-cues in a spatial learning task. *Acta Neurologica*, 35, 305–314.
- Carlomagnò, S. (1994). Pragmatic approaches to aphasia therapy. London: Whurr.
- Crosson, B., Moore, A. B., Gopinath, K., White, K. D., Wierenga, C. E., Gaiefsky, M. E., ... Rothi, L. J. G. (2005). Role of the right and left hemispheres in recovery of function during treatment of intention in aphasia. *Journal of Cognitive Neuroscience*, 17(3), 392–406.
- Eaton, K. P., Szaflarski, J. P., Altaye, M., Ball, A. L., Kissela, B. M., Banks, C., & Holland, S. K. (2008). Reliability of fMRI for studies of language in post-stroke aphasia subjects. *Neuroimage*, 41(2), 311–322.
- Ferré, P., Ska, B., Lajoie, C., Bleau, A., & Joannette, Y. (2011). Clinical focus on prosodic, discursive and pragmatic treatment for right hemisphere damaged adults: What's right? *Rehabilitation Research and Practice*, 2011, 1–10.
- Fiez, J. A., Raichle, M. E., Balota, D. A., Tallal, P., & Petersen, S. E. (1996). PET activation of posterior temporal regions during auditory word presentation and verb generation. *Cerebral Cortex*, 6, 1–10.
- Flöel, A., Meinzer, M., Kirtstein, R., Nijhof, S., Deppe, M., Knecht, S., & Breitenstein, C. (2011). Short-term anomia training and electrical brain stimulation. *Stroke*, 42 (7), 2065–2067.
- Gainotti, G. (2015). Contrasting opinions on the role of the right hemisphere in the recovery of language. A critical survey. *Aphasiology*, 29, 1020–1037.
- Geschwind, N. (1970). The organization of language and the brain. *Science*, 170, 940–944.
- Gloning, I., Gloning, K., Haub, G., & Quatember, R. (1969). Comparison of verbal behavior in right-handed and non right-handed patients with anatomically verified lesion of one hemisphere. *Cortex: A Journal Devoted to the Study of the Nervous System and Behavior*.
- Heiss, W. D., & Graf, R. (1994). The ischemic penumbra. *Current Opinion in Neurology*, 7, 11–19.
- Heiss, W. D., Kessler, J., Thiel, A., Ghaemi, M., & Karbe, H. (1999). Differential capacity of left and right hemispheric areas for compensation of poststroke aphasia. *Annals of Neurology*, 45, 430–438.
- Heiss, W. D., & Thiel, A. (2006). A proposed regional hierarchy in recovery of post-stroke aphasia. *Brain and Language*, 98, 118–123.
- Huber, W., & Gleber, J. (1982). Linguistic and nonlinguistic processing of narratives in aphasia. *Brain and Language*, 16, 1–18.
- Indefrey, P. (2014). Time course of word production does not support a parallel input architecture. *Language, Cognition and Neuroscience*, 29, 33–34.
- Joannette, Y., Goulet, P., & Hannequin, D. (1990). Right hemisphere and verbal communication. New York: Springer Verlag.
- Knecht, S., Deppe, M., Dräger, B., Bobe, L., Lohmann, H., Ringelstein, E. B., & Henningsen, H. (2000). Language lateralization in healthy right-handers. *Brain*, 123, 74–81.
- Kory Calomfirescu, S. (1996). Romanian version of Western Aphasia Battery % in Afazia in accidenteale vasculare cerebrale (pp. 74–95). Cluj Napoca: Casa Cartii de Stiinta.
- Krieg, S. M., Sollmann, N., Hauck, T., Ille, S., Foerschler, A., Meyer, B., & Ringel, F. (2013). Functional language shift to the right hemisphere in patients with language-eloquent brain tumors. *PLoS ONE*, 8, e75403.
- Lancaster, J. L., Woldorff, M. G., Parsons, L. M., Liotti, M., Freitas, C. S., Rainey, L., ... Fox, P. T. (2000). Automated Talairach atlas labels for functional brain mapping. *Human Brain Mapping*, 10(3), 120–131.
- Lehman Blake, M. (2006). Clinical relevance of discourse characteristics after right hemisphere brain damage. *American Journal of Speech Language Pathology*, 15, 255–267.
- Levin, H. S., Handel, S. F., & Goldman, A. M. (1985). Magnetic resonance imaging after diffuse nonmissile head injury. *Archives of Neurology*, 42, 963–968.
- Levin, H. S., Williams, D. H., Valastro, M., Eisenberg, H. M., Crofford, M. J., & Handel, S. F. (1990). Corpus callosal atrophy following closed head injury: Detection with magnetic resonance imaging. *Journal of Neurosurgery*, 73, 77–81.
- Luzzatti, G. W., Illmes, K., & DeBleser, R. (1991). A.A.T. versione italiana. Firenze: Organizzazioni Speciali.
- Marini, A. (2012). Characteristics of narrative discourse processing after damage to the right hemisphere. *Seminars in Speech and Language*, 33, 68–78.
- Marini, A., Andreatta, S., del Tin, S., & Carlomagno, S. (2011). A multi-level approach to the analysis of narrative language in Aphasia. *Aphasiology*, 25, 1372–1392.
- Marini, A., Carlomagno, S., Caltagirone, C., & Nocentini, U. (2005). The role played by the right hemisphere in the organization of complex textual structures. *Brain and Language*, 93, 46–54.
- Marini, A., & Urgesi, C. (2012). Please, get to the point! A cortical correlate of linguistic informativeness. *Journal of Cognitive Neuroscience*, 24, 2211–2222.
- Martin, P. I., Naeser, M. A., Theoret, H., Tormos, J. M., Nicholas, M., Kurland, J., ... Pascual-Leone, A. (2004). Transcranial magnetic stimulation as a complementary treatment for aphasia. *Seminars in Speech and Language*, 25(2), 181–191.
- Myers, P. S. (1993). Narrative expressive deficits associated with right-hemisphere damage. In H. Brownell & Y. Joannette (Eds.), *Narrative discourse in neurologically impaired and normal aging adults* (pp. 279–296). San Diego: Singular.
- Naeser, M. A., Martin, P. I., Nicholas, M., Baker, E. H., Seekins, H., Kobayashi, M., ... Pascual-Leone, A. (2005). Improved picture naming in chronic aphasia after TMS to part of right Broca's area: An open-protocol study. *Brain and Language*, 93(1), 95–105.
- Nicholas, L. E., & Brookshire, R. H. (1993). A system for quantifying the informativeness and efficiency of the connected speech of adults with aphasia. *Journal of Speech and Hearing Research*, 36, 338–350.
- Novelli, G., Papagno, C., Capitani, E., Laiacò, N., Vallar, G., & Cappa, S. F. (1986). Tre test clinici di ricerca e produzione lessicale. Taratura su soggetti normali. *Archivio di Psicologia, Neurologia e Psichiatria*, 47, 477–506.
- Ohyama, M., Senda, M., Kitamura, S., Ishii, K., Mishina, M., & Terashi, A. (1996). Role of the nondominant hemisphere and undamaged area during word repetition in poststroke aphasics. A PET activation study. *Stroke*, 27, 897–903.
- Oldfield, R. C. (1971). The assessment and analysis of handedness: The Edinburgh inventory. *Neuropsychologia*, 9(1), 97–113.
- Otal, B., Olma, M. C., Floel, A., & Wellwood, I. (2015). Inhibitory non-invasive brain stimulation to homologous language regions as an adjunct to speech and language therapy in post-stroke aphasia: A meta-analysis. *Frontiers in Human Neuroscience*, 9, 236.
- Paradis, C. (1987). On constraints and repair strategies. *The Linguistic Review*, 6, 71–97.
- Petersen, S. E., Fox, P. T., Posner, M. I., Mintun, M., & Raichle, M. E. (1988). Positron emission tomographic studies of the cortical anatomy of single-word processing. *Nature*, 331(6157), 585–589.
- Poca, M. A., Sahuquillo, J., Mataró, M., Benejam, B., Arikian, F., & Bágüena, M. (2005). Ventricular enlargement after moderate or severe head injury: A frequent and neglected problem. *Journal of Neurotrauma*, 22, 1303–1310.
- Raboyeau, G., De Boissezon, X., Marie, N., Balduyck, S., Puel, M., Bézy, C., ... Cardebat, D. (2008). Right hemisphere activation in recovery from aphasia: Lesion effect or function recruitment? *Neurology*, 70, 290–298.

- Raven, J. C. (1938). Standard progressive matrices: Sets A, B, C, D, and E. H.K. Lewis (London).
- Reider-Groswasser, I., Cohen, M., Costeff, H., & Grosswasser, Z. (1993). Late CT findings in brain trauma: Relationship to cognitive and behavioral sequelae and to vocational outcome. *American Journal of Radiology*, 160, 147–152.
- Reitan, R. M. (1992). Trail making test: Manual for administration and scoring. Tucson AZ: Reitan Neuropsychological Laboratory.
- Ren, C. L., Zhang, G. F., Xia, N., Jin, C. H., Zhang, X. H., Hao, J. F., ... Cai, D. L. (2014). Effect of low-frequency rTMS on aphasia in stroke patients: A meta-analysis of randomized controlled trials. *PLoS ONE*, 9(7), e102557.
- Rey, A. (1958). Memorisation d'une serie de 15 mots en 5 repetitions. In A. Rey (Ed.), *L'examen clinique en psychologie* (pp. 139–193). Paris: Presses Universitaires de France.
- Saur, D., Lange, R., Baumgaertner, A., Shraknepper, V., Willmes, K., Rijntjes, M., & Weiller, C. (2006). Dynamics of language reorganization after stroke. *Brain*, 129, 1371–1384.
- Schlaug, G., Marchina, S., & Norton, A. (2009). Evidence for plasticity in white matter tracts of patients with chronic Broca's aphasia undergoing intense intonation-based speech therapy. *Annals of the New York Academy of Sciences*, 1169, 385–394.
- Schlosser, R., Hunsche, S., Gawehn, J., Grunert, P., Vucurevic, G., Gesierich, T., ... Stoeter, P. (2002). Characterization of BOLD-fMRI signal during a verbal fluency paradigm in patients with intracerebral tumors affecting the frontal lobe. *Magnetic Resonance Imaging*, 20, 7–16.
- Shallice, T. (1982). Specific impairment of planning. *Philosophical Transactions of the Royal Society*, 298, 199–209.
- Spena, G., Nava, A., Cassini, F., Pepoli, A., Bruno, M., D'Agata, F., ... Versari, P. (2010). Preoperative and intraoperative brain mapping for the resection of eloquent-area tumors. A prospective analysis of methodology, correlation, and usefulness based on clinical outcomes. *Acta Neurochirurgica*, 152(11), 1835–1846.
- Spinnler, H., & Tognoli, G. (1987). Standardizzazione e taratura italiana di test neuropsicologici. *The Italian Journal of Neurological Sciences*, 8, 1–113.
- Stark, R. E., Bleile, K., Brandt, J., Freeman, J., & Vining, E. P. G. (1995). Speech-language outcomes of hemispherectomy in children and young adults. *Brain and Language*, 51, 406–421.
- Szafarski, J. P., Holland, S. K., Schmithorst, V. J., & Byars, A. W. (2006). fMRI study of language lateralization in children and adults. *Human Brain Mapping*, 27(3), 202–212.
- Talairach, J., & Tournoux, P. (1988). Co-planar stereotaxic atlas of the human brain. New York: Thieme Medical Publishers.
- Tecchio, F., Zappasodi, F., Tombini, M., Oliviero, A., Pasqualetti, P., Vernieri, F., ... Rossini, P. M. (2006). Brain plasticity in recovery from stroke: An MEG assessment. *NeuroImage*, 32, 1326–1334.
- Thiel, A., Habedank, B., Herholz, K., Kessler, J., Winhuisen, L., Haupt, W. F., & Heiss, W. D. (2006). From the left to the right: How the brain compensates progressive loss of language function. *Brain and Language*, 98, 57–65.
- Thiel, A., Herholz, K., Koyuncu, A., Ghaemi, M., Kracht, L. W., Habedank, B., & Heiss, W. D. (2001). Plasticity of language networks in patients with brain tumors: A positron emission tomography activation study. *Annals of Neurology*, 50, 620–629.
- Turkeltaub, P. E. (2015). Brain stimulation and the role of the right hemisphere in aphasia recovery. *Current Neurology and Neuroscience Reports*, 15(72), 1–9.
- Turkeltaub, P. E., Coslett, H. B., Thomas, A. L., Faseyitan, O., Benson, J., Norise, C., & Hamilton, R. H. (2012). The right hemisphere is not unitary in its role in aphasia recovery. *Cortex*, 48(9), 1179–1186.
- Verger, K., Junqué, C., Levin, H. S., Jurado, M. A., Perze-Gomez, M., Bartres-Faz, D., ... Mercader, J. M. (2001). Correlation of atrophy measures on MRI with neuropsychological sequelae in children and adolescents with traumatic brain injury. *Brain Injury*, 15(3), 211–221.
- Viano, D. C., Casson, I. R., Pellman, E. J., Zhang, E. J., King, A. I., & Yang, K. H. (2005). Concussion in professional football: Brain responses by finite element analysis: Part 9. *Neurosurgery*, 57, 891–916.
- Vigneau, M., Beaucousin, V., Hervé, P. Y., Duffau, H., Crivello, F., Houdé, O., ... Tzourio-Mazoyer, N. (2006). Meta-analyzing left hemisphere language areas: Phonology, semantics, and sentence processing. *NeuroImage*, 30, 1414–1432.
- Vigneau, M., Beaucousin, V., Hervé, P. Y., Jobard, G., Petit, L., Crivello, F., ... Tzourio-Mazoyer, N. (2011). What is right-hemisphere contribution to phonological, lexico-semantic, and sentence processing? Insights from a meta-analysis. *NeuroImage*, 54, 577–593.
- Villardita, C., Quattropiani, M., & Lomeo, C. Gruppo Italiano WAB. (1994). La Western Aphasia Battery Italiana (WABIT). Traduzione e adattamento – parte I. *Phoenix*, 4, 379–398.
- Vines, B. W., Norton, A. C., & Schlaug, G. (2011). Non-invasive brain stimulation enhances the effects of melodic intonation therapy. *Frontiers in Psychology*, 2, 230.
- Warner, M. A., Marquez de la Plata, C., Spence, J., Wang, J. Y., Harper, C., Moore, C., ... Diaz-Arrastia, R. (2010). Assessing spatial relationships between axonal integrity, regional brain volumes, and neuropsychological outcomes after traumatic axonal injury. *Journal of Neurotrauma*, 27, 2121–2130.
- Warner, M. A., Youn, T. S., Davis, T., Chandra, A., Marquez de la Plata, C., Moore, C., ... Arrastia, R. D. (2010). Regionally selective atrophy after traumatic axonal injury. *Archives in Neurology*, 67, 1336–1344.
- Weiller, C., Isensee, C., Rijntjes, M., Huber, W., Muller, S., Bier, D., ... Diener, H. C. (1995). Recovery from Wernicke's aphasia: A positron emission tomographic study. *Annals of Neurology*, 37, 723–732.
- Winhuisen, L., Thiel, A., Schumacher, B., Kessler, J., Rudolf, J., Haupt, W. F., & Heiss, W. D. (2005). Role of the contralateral inferior frontal gyrus in recovery of language function in poststroke aphasia: A combined repetitive transcranial magnetic stimulation and positron emission tomography study. *Stroke*, 36, 1759–1763.
- Wright, P., Stamatakis, E. A., & Tyler, L. K. (2012). Differentiating hemispheric contributions to syntax and semantics in patients with left-hemisphere lesions. *Journal of Neurosciences*, 32, 8149–8157.
- Zangwill, O. L. (1967). Speech and the minor hemisphere. *Acta neurologica et psychiatrica Belgica*, 67, 1013–1020.