

Ectopic breast tissue mimicking Bartholin's Abscess: a case report

Solaja OT^{1,2}[ID](#), Nwadiokwu JI^{1,2}[ID](#), OkebalamaVC¹[ID](#), Imaralu JO^{1,3}[ID](#), Ehioghae O⁴[ID](#)

¹Department of Histopathology, Babcock University Teaching Hospital, Ilishan-Remo, Ogun State, Nigeria

²Benjamin Carson (Snr.) College of Health and Medical Sciences, Babcock University, Ilishan-Remo, Ogun State, Nigeria

³Department of Obstetrics and Gynecology, Babcock University Teaching Hospital, Ilishan-Remo, Ogun State, Nigeria

⁴Department of Surgery, Babcock University Teaching Hospital, Ilishan-Remo, Ogun State, Nigeria

Submitted: 11th March 2022

Accepted: 23rd June 2022

Published: 31st December 2022

[ID](#): Orcid ID

Abstract

Background: Ectopic breast tissue (EBT) is an uncommon occurrence in which the breast tissue can be found at any point along the milk line. Although it is most commonly found on the axilla, it can also present on the thighs, perineum, vulva, inframammary region, and groin. EBT mimicking a Bartholin's abscess is extremely rare.

Case presentation: Here, we report the case of a 31-year-old nulliparous woman who presented to our gynecology clinic with a complaint of right-sided vulvar swelling. An initial diagnosis of Bartholin's abscess was made after clinical examination. This was surgically removed using marsupialization. However, following histopathological & immuno-histochemical evaluation, a confirmatory diagnosis of ectopic breast tissue was made.

Conclusion: Indeed, our case re-emphasizes the absolute need for histopathological examination of every tumor notwithstanding the nature of the presentation, site of occurrence, and/or initial diagnosis. Furthermore, although rare, EBT should be considered an important differential in tumors of the vulva.

Keywords: Ectopic breast tissue, Bartholin's abscess, Vulva

Background

Ectopic breast is breast tissue found outside the normal location of the breast on the anterior chest wall overlying the 2nd to the 6th rib and anterior axillary line to the midline of the chest on either side. The shape and extent of the breast vary among individuals. Ectopic breasts have been found along the milk line which extends from the axillar to the groin. However, it has also been reported in the vulvar among other places. It is not a commonplace occurrence, albeit, quite a number have been reported with incidence ranging from 0.6-6% (1, 2).

Although very rare, EBT can mimic a Bartholin's abscess. We herein present the case of a 31-year-old who presented with a right-sided vulvar swelling, initially diagnosed as a

Bartholin's abscess but was later confirmed, histopathologically, to be an ectopic breast tissue.

Case presentation

Miss RO was a 31-year-old nullipara who presented to the gynecology clinic with a right-sided vulvar swelling which she noticed three weeks earlier while having her bath. The swelling had increased progressively in size and was initially painless. She however developed pain in the third week, which was aggravated by sexual intercourse, but became persistent after three days, making walking difficult. She had no vaginal discharge or dysuria. She had one first trimester pregnancy termination by dilatation and curettage, ten years earlier and no complications occurred.

Correspondence:

Solaja, Oluwafemi T

Department of Histopathology,

Babcock University Teaching Hospital, Ilishan-Remo, Ogun State, Nigeria

+2348033744005, solajataiowo@gmail.com

She had a myomectomy three years earlier on account of menorrhagia and a huge uterine fibroid mass.

Examination revealed an anxious-looking woman, who was febrile to touch and had a temperature of 37.9°C. There was a non-tender 16-week-sized abdominal mass. Vaginal examination revealed a tender, firm, cystic, but non-fluctuant swelling on the inner aspect of the right labium minus. It extended from the mid-portion of the right labium minus to the fourchette posteriorly. It was fairly spherical with a diameter of 5cm and was exquisitely tender. The rest of the external genitalia were normal. An impression of a right Bartholin's abscess was made

She was then counseled for marsupialization and written consent was obtained for the procedure. She was commenced on an intravenous infusion of 5% Dextrose in Saline, and intramuscular Pentazocine 30mg was given to relieve her pain. She also administered, statum doses of intravenous Ampicillin cloxacillin 1 gram, and Metronidazole 500mg while awaiting surgery. Additionally, she was administered intramuscular acetaminophen, 600mg, and Diclofenac 75mg, for further relief of pain and fever.

Requested investigations showed that her packed cell volume was 35%, her hemoglobin genotype was AA, and her white blood cell count was 11,600/mm³ with differentials of (Neutrophils 76%, Lymphocytes 22%, and Eosinophils of 2%). Her blood group was O Rhesus positive, Urinalysis, was normal and both urine microscopy and urethral and rectal swab cultures were negative for any bacterial growth.

Furthermore, a pelvic ultrasound scanning showed a bulky uterus with multiple intramural and subserosal masses, the largest measuring 95mm x 70mm. The endometrial echoplate was intact.

Marsupialization of the right Bartholin's gland abscess was done in the theatre the next day. A sub-arachnoid block that was saddled to block the pelvic and perineal areas was administered to the patient. She was then

placed in the Lithotomy position, the perineum and vagina were cleansed with Chlorhexidine solution and sterile drapes were applied. The urinary bladder was emptied with a metal catheter. An endocervical swab was obtained during inspection of the cervix through a Cusco's speculum. Thereafter, a bimanual pelvic examination was done. A vertical incision about 2cm long was then made over the convexity of the mass just lateral to the hymenal remnants. The edges of the incision were held medially and laterally with size number 1 artery forceps and the following findings were noted; an encapsulated soft, 5cm by 4cm non-fluctuant, solid swelling, with cream color and well-delineated borders were noted within the right labium majus. The left labia, cervix, and adnexa looked and felt grossly normal. The swelling was dissected off with minimal bleeding and the lining of the cavity was sutured to the nearby skin laterally and vaginal mucosa medially with a series of interrupted sutures of 3/0 polyglycolic acid sutures. A sterile perineal pad was applied. She was administered postoperative antibiotics, and analgesics and had supportive care. She was discharged home on the second postoperative day when her general condition was satisfactory. She was seen in the gynecology clinic one week later and she had no complaints. The histology report, however, revealed that she had vulvar ectopic breast tissue.

Pathological and immuno-histochemical findings

A nodular fragment of greyish white tissue was received. It weighed 6.0grams and measured 7.0 x 2.0 x 1.0cm. Serial sections showed nodular greyish white tissue.

Microscopic sections showed tissue reminiscent of the breast. It was composed of numerous glandular structures disposed of in a dense fibro-collagenous stroma. Most of the glands were dilated. They were lined by layers of benign epithelial cells with abundant pink cytoplasm. Also seen were several vascular channels (Figure 1).

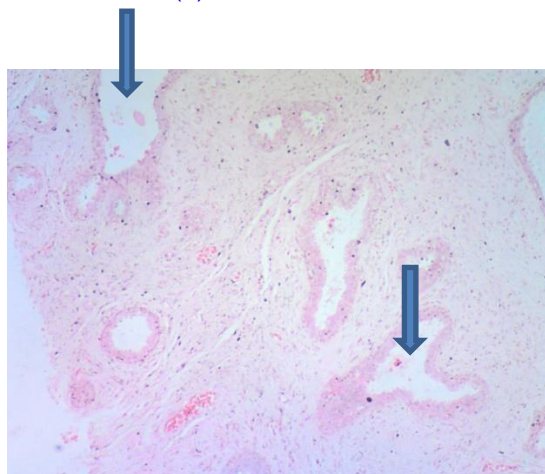


Figure 1: H & E x 100 showing dilated glandular structures lined by benign epithelial cells reminiscent of dilated breast ducts (arrows)

A diagnosis of an ectopic breast with fibrocystic disease was made. Immunohistochemistry was

positive for estrogen and progesterone receptors (Figures 2 and 3).

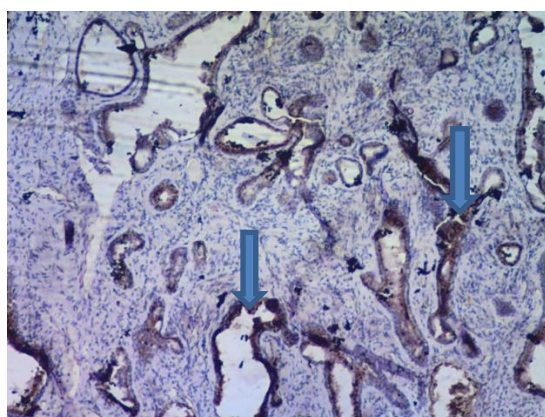


Figure 2: Progesterone receptor (PR) Immuno-histochemical marker x100 showing moderate nuclear membrane staining consistent with breast ductal epithelium (arrows)

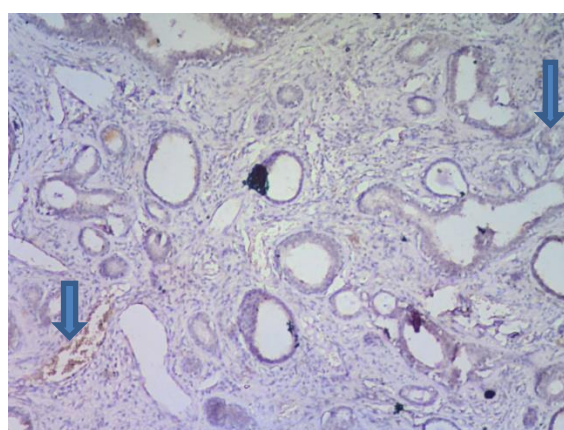


Figure 3: Estrogen receptor (ER) Immuno-histochemical marker x100 showing moderate focal nuclear membrane staining consistent with breast ductal epithelium (arrows)

Discussion

Polymastia refers to the presence of more than two breasts. This term is considered synonymous with supernumerary breast, accessory breast, and ectopic breast tissue. During embryogenesis, two ectodermal thickenings, extending from the axilla to the groin develop, representing the milk lines.

Failure of regression of these ridges, save for two located at the embryo's pectoral region, which eventually becomes the normal breasts, results in ectopic breast tissue; this could exist with a nipple-areolar complex (polythelia) or without the complex (polymastia) (1). The axilla remains the most common site of occurrence of EBT, with other observed sites including the

sternum, the infraclavicular region, epigastrium, and vulva (2, 3, 4).

Although most cases of ectopic breast tissue are sporadic, hereditary patterns have been reported (2). Overall, the incidence of EBT differs among various ethnicities, ranging from 0.6% to 6% (2, 5). Owing to the rather rare nature of the pathology, there is currently a paucity of similar case reports in Nigeria. It occurs in both sexes (6).

Kajava, in 1915 propounded a classification system for supernumerary breast tissue which comprises Classes I through VIII. Class I represents a complete breast with nipple-areolar complex and glandular tissue. Class II consists of the nipple and glandular tissue, but no areolar. Class III consists of areolar and glandular tissue but no nipple. Class IV consists of glandular tissue only. Class V consists of the nipple and areolar but no glandular tissue (pseudomamma). Class VI represents a nipple only (polythelia). Class VII consists of an areolar only (polythelia areolaris). Class VIII consists of a patch of hair only (polythelia pilosa) (7). Our case falls under class IV.

EBT usually presents asymptotically, with the major concern being cosmetic displeasure. The clinical significance, however, is that the pathological conditions which occur in normally situated breasts could occur in EBTs, causing significant morbidity, such as in our case. Pain and discomfort may occur due to hormonal changes at various stages of a female's reproductive cycle (menstruation, pregnancy, and lactation) (1). Furthermore, inflammation, fibrosis, fibroadenoma and fibrocystic changes (as in our case), and even carcinoma may occur as well, accounting for about 0.3% of all breast carcinomas (1, 8, 9, 10). Such carcinomas arising from EBT present late and carry a poorer prognosis as there is a delay in diagnosis due to a wide gamut of differential diagnoses (11). EBTs have also been reported to be associated with abnormalities of the urinary system such as renal agenesis, supernumerary kidneys, hydronephrosis, renal adenocarcinoma, polycystic kidney disease, duplicate renal arteries, and ureteric stenosis. This may be explained by the close relationship between the development of the mammary structure and the genitourinary system during embryogenesis (12, 13).

Conclusion

In conclusion, the importance of a strong clinical acumen in the evaluation of an individual presenting with abnormalities along the milk line cannot be emphasized. Additionally, EBT presenting a Bartholin's abscess is extremely rare. Further

investigations, including a biopsy, should be done to make a diagnosis. It is also important to look out for other associations to avert complications. Treatment options depend on the severity of symptoms and the presence of associated breast pathologies. In our case, excision was done with follow-up. Furthermore, our case buttresses the absolute need for histopathological evaluation of every tumor notwithstanding the nature of the presentation, site of occurrence, and/or initial diagnosis. In addition, EBT should be considered an important differential in tumors of the vulva even though it's a rare pathological entity.

List of abbreviations

EBT: Ectopic Breast Tissue

Declarations

Ethics consideration

Written informed consent for publication was obtained from the patient whose management is being reported.

Consent for publication

The authors hereby give consent for the publication of this work under the Creative Commons CC Attribution. Non-commercial 4.0 license.

Availability of data and materials

All data generated or analyzed in this study are included in this article and are available on request.

Competing interests

The authors declare no competing interest in the publication of this case report.

Funding

The authors did not receive any financial support for this publication.

Acknowledgments

Nil

References

1. Shin SJ, Sheikh FS, Allenby PA, Rosen PP. Invasive secretory (juvenile) carcinoma arising in ectopic breast tissue of the axilla. Archives of pathology & laboratory medicine. 2001 Oct;125(10):1372-4. <https://doi.org/10.5858/2001-125-1372-ISJCAI>
2. Marshall MB, Moynihan JJ, Frost A, Evans SR. Ectopic breast cancer: case report and literature review. Surgical oncology. 1994 Oct 1;3(5):295-304. <https://doi.org/10.1016/0960->

- [7404\(94\)90032-9](https://doi.org/10.17659/01.2012.0013)
3. Amsler E, Sigal-Zafrani B, Marinho E, Aractingi S. Ectopic breast cancer of the axilla. In *Annales de dermatologie et de venerologie* 2002 Dec 1 (Vol. 129, No. 12, pp. 1389-1391).
 4. Routiot T, Marchal C, Verhaeghe JL, Depardieu C, Netter E, Weber B, Carolus JM. Breast carcinoma located in ectopic breast tissue: a case report and review of the literature. *Oncology reports*. 1998 Mar 1;5(2):413-20.
<https://doi.org/10.3892/or.5.2.413>
 5. Aubert JP, Paulhe P, Magalon G. Glande mammaire surnuméraire: un cas inhabituel. In *Annales de chirurgie plastique et esthétique* 1991 (Vol. 36, No. 5, pp. 457-459).
 6. Önel S, Karateke F, Kuvvetli A, Özyazıcı S, Özdoğan M. Ectopic breast cancer: A case report. *Turkish Journal of Surgery/Ulusal cerrahi dergisi*. 2013;29(2):96.
<https://doi.org/10.5152/UCD.2013.23>
 7. Kajava Y. The proportion of supernumerary nipples in the Finnish population. *Duodecim*. 1915;31:143-51.
 8. Rizvi G, Pandey H, Gupta MK. Fibroadenoma of ectopic breast tissue in axilla. *Journal of case reports*. 2012 Aug 8;2(2):36-8.
<https://doi.org/10.17659/01.2012.0013>
 9. Evans DM, Guyton DP. Carcinoma of the axillary breast. *Journal of surgical oncology*. 1995 Jul;59(3):190-5.
<https://doi.org/10.1002/jso.2930590311>
 10. Avilés Izquierdo J, Martínez Sánchez D, Suárez Fernández R, Lázaro Ochaita P, Isabel Longo-Imedio M. Pigmented axillary nodule: carcinoma of an ectopic axillary breast. *Dermatologic surgery*. 2005 Feb;31(2):237-9.
<https://doi.org/10.1097/00042728-200502000-00022>
 11. Ciralik H, Bulbuloglu E, Arican O, Citil R. Fibroadenoma of the ectopic breast of the axilla—a case report. *Pol J Pathol*. 2006 Jan 1;57(4):209-11.
 12. Grossl NA. Supernumerary breast tissue: historical perspectives and clinical features. *Southern medical journal*. 2000 Jan 1;93(1):29-32.
<https://doi.org/10.1097/00007611-200093010-00005>
 13. Dixon JM, Mansel RE. Congenital problems and aberrations of normal breast development and involution. *British Medical Journal*. 1994 Sep 24;309(6957):797-801.
<https://doi.org/10.1136/bmj.309.6957.797>