

# Changes of optic nerve head microcirculation in high myopia

Wen-Quan Tang<sup>1</sup>, Yu-Lin Luo<sup>1</sup>, Xi-Lang Wang<sup>1</sup>, Xuan-Chu Duan<sup>2,3</sup>

<sup>1</sup>Department of Ophthalmology, Hunan Children's Hospital, Changsha 410007, Hunan Province, China

<sup>2</sup>Changsha Aier Eye Hospital, Changsha 410011, Hunan Province, China

<sup>3</sup>Aier School of Ophthalmology, Central South University, Changsha 410011, Hunan Province, China

**Correspondence to:** Xuan-Chu Duan. Changsha Aier Eye Hospital, Changsha 410011, Hunan Province, China. duanxchu@126.com

Received: 2022-06-12 Accepted: 2022-07-21

## Abstract

• **AIM:** To analyze the correlation of age, spherical equivalent (SE), and axial length (AL) with the microcirculation of optic nerve head (ONH) in high myopia (HM).

• **METHODS:** In this cross-sectional clinical study, 164 right eyes were included. Optical coherence tomography angiography (OCTA) was used to detect ONH vessel density. Eyes were classified based on age, SE, and AL. Groups of Age1, Age2, and Age3 were denoted for age classification (Age1<20y, 20y≤Age2<30y, Age3≥30y); Groups SE1, SE2, and SE3 for the SE classification (-9≤SE1<-6 D, -12≤SE2<-9 D, SE3<-12 D); Groups AL1, AL2, AL3, and AL4 for the AL classification (AL1<26 mm, 26≤AL2<27 mm, 27≤AL3<28 mm, AL4≥28 mm).

• **RESULTS:** No significant difference was observed in vessel density among the Age1, Age2, and Age3 groups (all  $P>0.05$ ) and the SE1, SE2, and SE3 groups (all  $P>0.05$ ). No significant difference was observed in the intrapapillary vascular density (IVD) among AL1, AL2, AL3, and AL4 groups ( $P>0.05$ ). However, a significant decrease was found in the peripapillary vascular density (PVD) in the AL1, AL2, AL3, and AL4 groups ( $F=3.605$ ,  $P=0.015$ ), especially in the inferotemporal (IT;  $F=6.25$ ,  $P<0.001$ ), temporoinferior (TI;  $F=2.865$ ,  $P=0.038$ ), and temporosuperior (TS;  $F=6.812$ ,  $P<0.001$ ) sectors. The IVD was correlated with age ( $r=0.190$ ,  $P<0.05$ ) but not with SE or AL ( $P>0.05$ ). The PVD was correlated with AL ( $r=-0.236$ ,  $P<0.01$ ) but not with age or SE ( $P>0.05$ ).

• **CONCLUSION:** With the increase of AL, the IVD remains stable while the PVD decreases, especially in the three

directions of temporal (IT, TI, and TS). The main cause of microcirculation reduction may be related to AL elongation rather than an increase in age or SE.

• **KEYWORDS:** high myopia; optic nerve head; optical coherence tomography angiography; vascular density; axial length

**DOI:10.18240/ijo.2023.01.15**

**Citation:** Tang WQ, Luo YL, Wang XL, Duan XC. Changes of optic nerve head microcirculation in high myopia. *Int J Ophthalmol* 2023;16(1):102-107

## INTRODUCTION

Myopia is the most prevalent correctable visual impairment worldwide. The prevalence of myopia and high myopia (HM) is continuously increasing, especially in Asian populations<sup>[1-2]</sup>. HM is characterized by progressive extension of the axial length (AL) and degenerative structural changes in the fundus<sup>[3]</sup>. Increasing evidence suggests that chorioretinal vascular dysfunction may be an associated complication or factor of HM<sup>[4-5]</sup>. Of note, previous studies have reported a decrease in the retinal vessels perfusion in HM<sup>[5-6]</sup>. Besides stenosis of retinal arterioles, and decrease in retinal blood flow is also associated with AL elongation<sup>[7-9]</sup>. Thus, impaired retinal blood flow can play a crucial role in developing HM-associated degenerative changes. Therefore, it is important to study optic disc microcirculation changes in HM. In this study, we used optical coherence tomography angiography (OCTA) to detect changes in the optic nerve head (ONH) microcirculation in HM. We compared microcirculatory parameters at different ages, spherical equivalent (SE), and AL. Further, we assessed the correlation between microcirculatory parameters with these factors to screen out the related and predictable indicators of HM related degenerative changes.

## SUBJECTS AND METHODS

**Ethical Approval** The study adhered to the principles of the Declaration of Helsinki. The study protocol was approved by the Ethics Committee of Changsha Aier Eye Hospital, Central South University, Changsha, China. Written informed consents were obtained from all cases.

**Subjects** From May 2020 to June 2021, the medical records

of 167 consecutive patients with myopia in the Refractive Department were reviewed. Comprehensive examinations including slit-lamp biomicroscope, mydriatic indirect ophthalmoscopy, intraocular pressure (IOP), AL (IOL Master 700; Carl Zeiss Meditec, Germany), ultra-widefield fundus imaging (Optos; Daytona P200T, Nikon, Japan), OCTA (RTVue-XR Avanti; Optovue, Fremont, CA, USA), visual acuity and refractive error were assessed.

Inclusion criteria: 1)  $SE < -6.00$  D; 2)  $IOP \leq 21$  mm Hg; 3) OCTA signal strength index  $\geq 50$ . Exclusion criteria: Patients with hypertension, diabetes, systemic connective tissue disorder, or any other ophthalmic disease (such as cataract, glaucoma, macular hole, retinal hole, or retinal hemorrhage), history of ophthalmic trauma, or surgery.

**Parameters from Optical Coherence Tomography Angiography** OCTA system automatically measured the peripapillary vascular density (PVD) and intrapapillary vascular density (IVD). A  $6 \times 6$  mm<sup>2</sup> cube and a  $4.5 \times 4.5$  mm<sup>2</sup> cube scan centered were obtained on the fovea and ONH, respectively. ONH was divided into 8 sectors (superanasal, SN; nasosuperior, NS; nasoinferior, NI; inferonasal, IN; inferotemporal, IT; temporoinferior, TI; temporosuperior, TS; superotemporal, ST; Figure 1).

**Statistical Analysis** SPSS22.0 software was used for the statistical analysis. The data were presented as mean±standard deviation (SD). Analysis of variance (ANOVA) and least significant difference (LSD) was applied for different analyses between groups. With the *P*-value of  $< 0.05$ , the difference was considered to be statistically significant.

## RESULTS

**Demographic Data** In total, 164 right eyes met the inclusion and exclusion criteria. Among them, 36 males and 128 females were included, with a mean age of  $25.11 \pm 5.69$ . The SE was  $-9.25 \pm 2.10$  D. AL was  $26.99 \pm 1.11$  mm. IVD was  $54.04\% \pm 4.94\%$ , and PVD was  $49.81\% \pm 3.24\%$  (Table 1).

**Microcirculation Changes of Optic Nerve Head in Different Age Groups** No significant difference was observed in the IVD or PVD among the Age1, Age2, and Age3 groups ( $P > 0.05$ ). However, with the increase of age, the IVD and PVD decreased (Table 2).

**Microcirculation Changes of Optic Nerve Head in Different Spherical Equivalent Groups** No significant difference was observed in the IVD or PVD among the SE1, SE2, and SE3 groups ( $P > 0.05$ ; Table 3).

**Microcirculation Changes of Optic Nerve Head in Different Axial Length Groups** No significant difference was observed in the IVD among AL1, AL2, AL3, and AL4 groups ( $P > 0.05$ ). In contrast, PVD in AL1, AL2, and AL3 groups was higher than in the AL4 group ( $P < 0.05$ ). Among 8 regions of PVD, the NI, IT, TI, and TS regions were significantly different ( $P < 0.05$ ).

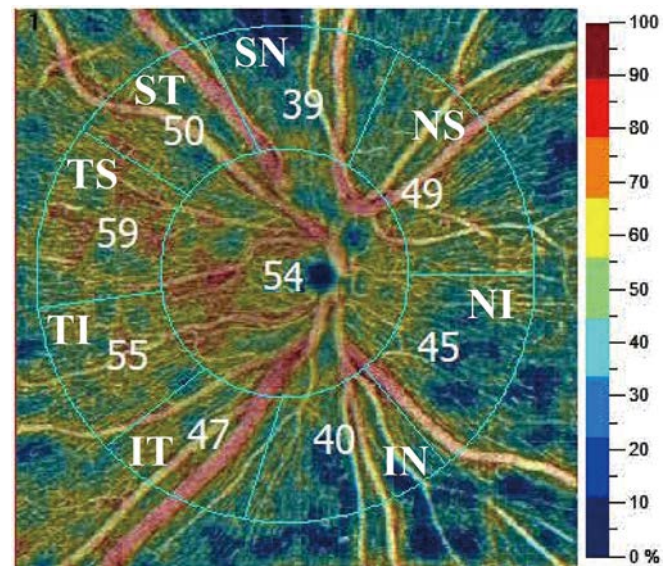


Figure 1 Parameters by optical coherence tomography angiography.

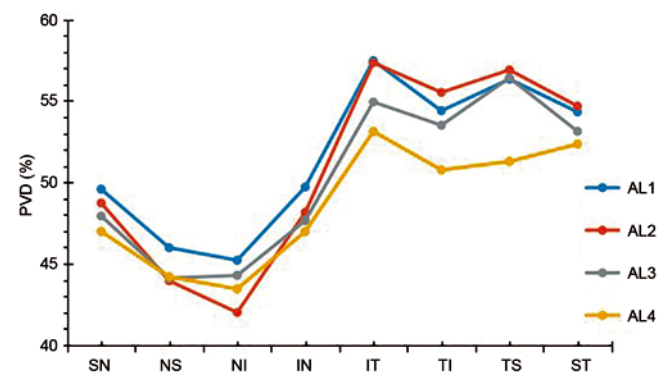


Figure 2 Peripapillary vascular density in eight sectors of different axial length groups.

Parameters	Data	Min	Max	mean±SD
Gender (male/female)	36/128	NA	NA	
Age (y)	$25.11 \pm 5.69$	18	39	
Axial length (mm)	$26.99 \pm 1.11$	23.75	30.85	
Spherical equivalent (D)	$-9.25 \pm 2.10$	-6.125	-19.625	
Intrapapillary vascular density (%)	$54.04 \pm 4.94$	42.03	67.71	
Peripapillary vascular density (%)	$49.81 \pm 3.24$	39.93	59.10	

The temporal direction was higher than that of the nasal direction. However, IVD did not change significantly with AL growth (Table 4, Figure 2).

**Correlation Analysis** IVD was negatively correlated with age ( $r = -0.190$ ,  $P = 0.042$ ) but was not correlated with AL ( $r = 0.145$ ,  $P = 0.063$ ) or SE ( $r = 0.088$ ,  $P = 0.263$ ). PVD had a significant negative correlation with AL ( $r = -0.236$ ,  $P = 0.002$ ; Figure 3) but was not correlated with age ( $r = 0.042$ ,  $P = 0.597$ ) or SE ( $r = -0.047$ ,  $P = 0.550$ ).

## DISCUSSION

In this study, we analyzed the vessel density parameters of ONH in HM, and found that the PVD decreased with AL elongation, while the IVD remained stable.

**Table 2 Microcirculation changes of optic nerve head in different age groups** mean±SD

Parameters	Age1 (n=29)	Age2 (n=94)	Age3 (n=41)	F	P
IVD (%)	55.18±5.17	54.09±4.71	53.12±5.24	1.503	0.226
PVD (%)	49.88±3.43	49.81±3.17	49.74±3.35	0.016	0.984
SN	43.97±6.27	44.76±5.66	43.69±5.89	0.557	0.574
NS	42.52±4.98	44.02±5.66	42.41±7.17	1.384	0.254
NI	48.33±5.77	47.43±5.83	49.05±4.70	1.268	0.284
IN	56.47±4.31	55.80±4.37	55.80±6.15	0.225	0.799
IT	54.69±6.1	53.82±7.37	53.85±6.58	0.181	0.835
TI	56.57±3.81	55.50±5.93	56.46±6.07	0.642	0.527
TS	52.90±4.84	53.71±4.96	54.31±4.59	0.718	0.489
ST	48.98±4.63	48.61±4.71	47.72±3.81	0.802	0.450

PVD: Peripapillary vascular density; IVD: Intrapapillary vascular density; SN: Superanasal; NS: Nasosuperior; NI: Nasoinferior; IN: Inferonasal; IT: Inferotemporal; TI: Temporoinferior; TS: Temporosuperior; ST: Superotemporal.

**Table 3 Microcirculation changes of optic nerve head in different SE groups** mean±SD

Parameters	SE1 (n=80)	SE2 (n=73)	SE3 (n=11)	F	P
IVD (%)	53.61±4.57	54.45±5.06	54.48±6.77	0.597	0.552
PVD (%)	49.95±3.01	49.81±3.32	48.74±4.40	0.666	0.515
SN	44.50±5.03	44.20±6.84	44.36±3.71	0.049	0.952
NS	43.20±6.09	43.27±5.66	44.99±7.46	0.445	0.642
NI	48.05±5.24	47.69±5.79	49.59±6.62	0.560	0.572
IN	56.34±5.03	55.73±4.41	54.20±6.11	1.049	0.353
IT	53.64±6.17	54.97±7.17	49.94±9.34	2.764	0.066
TI	56.71±4.02	55.47±6.41	53.29±9.00	2.235	0.110
TS	53.66±4.06	54.33±5.23	50.02±6.12	3.955	0.021
ST	48.58±4.63	48.53±4.16	47.06±5.56	0.569	0.567

SE: Spherical equivalent; PVD: Peripapillary vascular density; IVD: Intrapapillary vascular density; SN: Superanasal; NS: Nasosuperior; NI: Nasoinferior; IN: Inferonasal; IT: Inferotemporal; TI: Temporoinferior; TS: Temporosuperior; ST: Superotemporal.

**Table 4 Microcirculation changes of optic nerve head in different AL groups** mean±SD

Parameters	AL1 (n=24)	AL2 (n=56)	AL3 (n=61)	AL4 (n=23)	F	P
IVD (%)	52.27±4.71	54.61±4.59	53.55±4.43	55.81±6.61	2.527	0.059
PVD (%)	51.07±2.08	50.03±3.30	49.75±3.21	48.09±3.65 <sup>a,b,c</sup>	3.605	0.015
SN	49.92±3.43	48.80±4.47	48.11±4.30	46.98±5.55	1.945	0.124
NS	46.53±2.95	43.59±6.62	44.26±5.07	44.19±7.41	1.470	0.225
NI	45.05±5.02	41.46±6.59 <sup>a</sup>	44.38±5.40 <sup>b</sup>	43.45±5.92	3.248	0.023
IN	49.20±4.24	48.02±5.79	47.88±5.39	46.98±6.73	0.632	0.595
IT	57.14±3.69	57.50±3.51	55.05±5.46 <sup>b</sup>	53.12±5.40 <sup>a,b</sup>	6.250	0.000
TI	53.98±4.29	55.65±4.48	53.68±7.69	50.76±10.36 <sup>b</sup>	2.865	0.038
TS	56.41±3.79	57.01±3.87	56.50±5.69	51.28±8.26 <sup>a,b,c</sup>	6.812	0.000
ST	54.38±3.10	54.60±4.75	53.16±4.96	52.34±5.89	1.667	0.176

<sup>a</sup>P<0.05 compared with AL1 group; <sup>b</sup>P<0.05 compared with AL2 group; <sup>c</sup>P<0.05 compared with AL3 group. AL: Axial length; PVD: Peripapillary vascular density; IVD: Intrapapillary vascular density; SN: Superanasal; NS: Nasosuperior; NI: Nasoinferior; IN: Inferonasal; IT: Inferotemporal; TI: Temporoinferior; TS: Temporosuperior; ST: Superotemporal.

The ONH is a conspicuous structure with optic nerve and retinal vessels entering or exiting the eyeball. In concurrence with previous reports, this study also observed that the PVD decreases with the growth of the AL<sup>[10-12]</sup>. Importantly, two mechanisms may lead to a decrease in perfusion in the peripapillary region of the HM. First, the growth of the eyeball leads to the expansion and thinning of the retina, especially

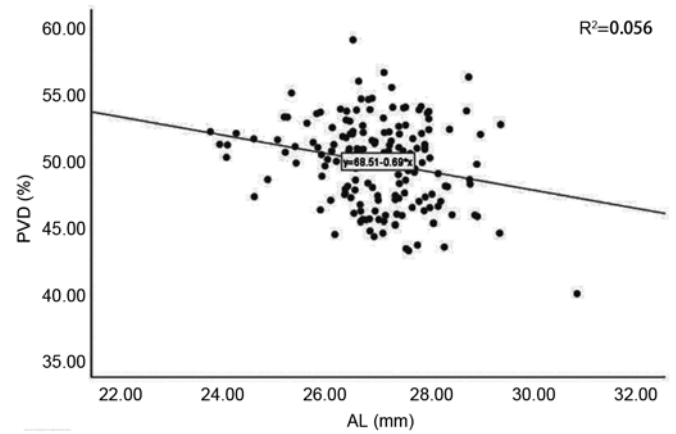
around the optic disc<sup>[13]</sup>, resulting in a decrease in the vascular tissue per unit area. Al-Sheikh *et al*<sup>[14]</sup> and Milani *et al*<sup>[15]</sup> reported that the retinal vessel density in the macular area of myopia patients was significantly decreased. Moreover, the excessive axial elongation resulted in straightening and stenosis of blood vessels, causing an overall decrease in vessel density. Second, the possible mechanism of thinning

in the peridiscal retinal tissue decreases the oxygen demand, which further causes a decrease in blood circulation<sup>[16-17]</sup>. To a certain extent, the supply-demand relationship explains that the decrease in vessel density in HM is a physiological rather than a pathological phenomenon. Further, previous studies have reported thinning of the retinal nerve fiber layer in HM<sup>[18-20]</sup>, which may reduce oxygen and blood flow demand. In this study, the PVD on the temporal side (IT, TI, TS, and ST) was higher than on the nasal side (SN, NS, NI, and IN). Of note, when AL was greater than 28 mm, the three regions of temporal PVD (IT, TI, and TS) were significantly reduced. These findings are in coherence with our morphological studies on the ONH. Thus, as AL elongates, the morphological changes on the temporal side of the ONH significantly increase compared to the nasal side. This observation indicates that there may be a relation between the morphological structure of the peripapillary area and PVD in HM, which needs to be explored further.

Our study revealed that the IVD (54.04%±4.94%) was greater than the PVD (49.81%±3.24%) in HM. In contrast to PVD, with the increase of AL, IVD remained stable. To date, no relevant research has been performed on this topic. The blood supplied to the optic disc is complex, mainly provided by retinal and choroidal circulations. The Zinn-Haller arterial ring provides the main blood supply to the optic disc at the level of the lamina. However, as AL increases, the distance between the Zinn-Haller and the optic disc boundary increases significantly<sup>[21-22]</sup>. Therefore, the different changes in IVD and PVD might occur due to the inside and peripapillary blood supply provided by different blood circulations.

Additionally, in another possible mechanism, changes in the ONH are mainly focused on the peripapillary area. Thus, blood perfusion is compensated by increasing the disc area while the IVD remains stable for preserving the optic nerve tissue. This mechanism may explain why not all high myopia eyes undergo optic nerve degenerative pathological changes.

Previous studies have shown that SE was significantly correlated with changes in retinal microvessels<sup>[23]</sup>. On the contrary, our results suggest that the SE does not correlate with ONH vessel density. The SE is mainly determined by various components of the anterior and posterior segments, including the eyeball's corneal curvature, lens, and AL. Axial elongation is generally the result of structural changes in the posterior segment. Nonetheless, the mechanical stretching caused by axial elongation is usually accompanied by a reduction in oxygen consumption, eventually affecting the structure of the posterior segment<sup>[24-25]</sup>, such as the retina<sup>[26]</sup>. Although not completely equivalent, AL and SE changes occur almost simultaneously during the development of HM<sup>[27]</sup>. In this study, we found that the relationship between vessel



**Figure 3** The correlation between peripapillary vascular density and axial length.

density and AL was more profound than between vessel density and SE. Therefore, in clinical diagnosis and treatment, ophthalmologists and myopia patients should pay more attention to axial elongation and not just refractive changes.

In addition, we found that the ONH vessel density did not show a significant change with the increase in age, which was in agreement with the previous findings of Liu *et al*<sup>[23]</sup>. They reported that in the age of 18-45y, the vessel density in the macular region was relatively unaffected by age. However, this finding was inconsistent with the conclusion of Wei *et al*<sup>[28]</sup>, who studied people between 18 and 82 years of age. They found that only those aged 65y or older had a significant decrease in vessel density. Leng *et al*<sup>[29]</sup> found that with the increase in age, the vessel density of macula decreased significantly, while the vessel density of macula did not correlate with sex, race, SE, or AL. The findings of these studies were contrary to our conclusions. The reasons could be the differences in the clinical characteristics of the study population, inclusion, and image analysis criteria. Yu *et al*<sup>[30]</sup> reported that in a healthy Chinese population, the blood flow index and vessel density of the superficial macular parafoveal decreases with age with constant decreases of 0.6% (blood flow index) and 0.4% (vessel density) each year. Therefore, it is critical to conduct future studies in larger cohorts to clarify and validate the potential impact of age on retinal perfusion in HM.

The study had certain limitations. First, this was a retrospective study; hence, longitudinal data were unavailable. Thus, the causality of the conclusion cannot be confirmed. Second, an OCTA scan requires the subjects to maintain a stable position and fixation; however, elderly patients with refractive interstitial opacity or poor fixation can't receive accurate measurements. The subjects were young to middle-aged; thus, we could obtain satisfactory image quality under full guidance with the credibility of the results. Further, a sample selection bias also occurred to some extent. Third, the magnification effect of the images may affect the results of OCT measurements (*e.g.*,

vessel density, and area). The range of 4.5×4.5 mm<sup>2</sup> scans used in this study was small, so the effect of the amplification effect was not significant.

In conclusion, in HM, IVD, and PVD did not change significantly with an increase in age or SE. However, with the increase in AL, the IVD remained stable, but the PVD decreased, especially in the three temporal regions (IT, TI, and TS). The PVD was negatively correlated with AL. In young patients, the SE and age were not significantly correlated with ONH vessel density. Therefore, ophthalmologists and myopia patients should pay attention to AL elongation, not merely to refractive changes. The asymmetric changes in IVD and PVD may explain why not all HM patients undergo optic nerve degenerative pathological changes.

#### ACKNOWLEDGEMENTS

**Authors' contributions:** Tang WQ and Duan XC designed the research study; Tang WQ wrote the paper; Tang WQ, Luo YL, and Wang XL analyzed and interpreted the data; Duan XC, Luo YL and Wang XL contributed to critical revision of the article; Duan XC and Luo YL obtained and provided administrative, technical, or logistic support. All authors approved the manuscript.

**Foundations:** Supported by National Natural Science Foundation of China (No.81970801); Health Commission of Hunan Province (No.202107020468; No.202107021955).

**Conflicts of Interest:** Tang WQ, None; Luo YL, None; Wang XL, None; Duan XC, None.

#### REFERENCES

- 1 Wong YL, Saw SM. Epidemiology of pathologic myopia in Asia and worldwide. *Asia Pac J Ophthalmol (Phila)* 2016;5(6):394-402.
- 2 Russo A, Boldini A, Romano D, Mazza G, Bignotti S, Morescalchi F, Semeraro F. Myopia: mechanisms and strategies to slow down its progression. *J Ophthalmol* 2022;2022:1004977.
- 3 Haarman AEG, Tedja MS, Brussee C, Enthoven CA, van Rijn GA, Vingerling JR, Keunen JEE, Boon CJF, Geerards AJM, Luyten GPM, Verhoeven VJM, Klaver CCW. Prevalence of myopic macular features in Dutch individuals of European ancestry with high myopia. *JAMA Ophthalmol* 2022;140(2):115-123.
- 4 Wu Q, Chen Q, Lin B, Huang S, Wang Y, Zhang L, Lin H, Wang J, Lu F, Shen M. Relationships among retinal/choroidal thickness, retinal microvascular network and visual field in high myopia. *Acta Ophthalmol* 2020;98(6):e709-e714.
- 5 Shimada N, Ohno-Matsui K, Harino S, Yoshida T, Yasuzumi K, Kojima A, Kobayashi K, Futagami S, Tokoro T, Mochizuki M. Reduction of retinal blood flow in high myopia. *Graefes Arch Clin Exp Ophthalmol* 2004;42(4):284-288.
- 6 Azemin MZ, Daud NM, Ab Hamid F, Zahari I, Sapuan AH. Influence of refractive condition on retinal vasculature complexity in younger subjects. *Sci World J* 2014;2014:783525.
- 7 Li H, Mitchell P, Rohtchina E, Burlutsky G, Wong TY, Wang JJ.

- Retinal vessel caliber and myopic retinopathy: the blue mountains eye study. *Ophthalmic Epidemiol* 2011;18(6):275-280.
- 8 Tai EL, Li LJ, Wan-Hazabbah WH, Wong TY, Shatriah I. Effect of axial eye length on retinal vessel parameters in 6 to 12-year-old Malay girls. *PLoS One* 2017;12(1):e0170014.
- 9 Liu X, Zhang F, Wang Y, Xie Z, Wu W, Wang Q, Zheng M, Lu F, Mao X. Associations between optic disc characteristics and macular choroidal microvasculature in young patients with high myopia. *Clin Exp Ophthalmol* 2021;49(6):560-569.
- 10 Yaprak AC, Yaprak L. Retinal microvasculature and optic disc alterations in non-pathological high myopia with optical coherence tomography angiography. *Graefes Arch Clin Exp Ophthalmol* 2021; 259(11):3221-3227.
- 11 Wang X, Kong X, Jiang C, Li M, Yu J, Sun X. Is the peripapillary retinal perfusion related to myopia in healthy eyes? A prospective comparative study. *BMJ Open* 2016;6(3):e010791.
- 12 He J, Chen Q, Yin Y, Zhou H, Fan Y, Zhu J, Zou H, Xu X. Association between retinal microvasculature and optic disc alterations in high myopia. *Eye (Lond)* 2019;33(9):1494-1503.
- 13 Pan T, Su Y, Yuan ST, Lu HC, Hu ZZ, Liu QH. Optic disc and peripapillary changes by optic coherence tomography in high myopia. *Int J Ophthalmol* 2018;11(5):874-880.
- 14 Wang XQ, Zeng LZ, Chen M, Liu LQ. A meta-analysis of alterations in the retina and choroid in high myopia assessed by optical coherence tomography angiography. *Ophthalmic Res* 2021;64(6):928-937.
- 15 Milani P, Montesano G, Rossetti L, Bergamini F, Pece A. Vessel density, retinal thickness, and choriocapillaris vascular flow in myopic eyes on OCT angiography. *Graefes Arch Clin Exp Ophthalmol* 2018; 256(8):1419-1427.
- 16 Kur J, Newman EA, Chan-Ling T. Cellular and physiological mechanisms underlying blood flow regulation in the retina and choroid in health and disease. *Prog Retin Eye Res* 2012;31(5):377-406.
- 17 Fan H, Chen HY, Ma HJ, Chang Z, Yin HQ, Ng DS, Cheung CY, Hu S, Xiang X, Tang SB, Li SN. Reduced macular vascular density in myopic eyes. *Chin Med J (Engl)* 2017;130(4):445-451.
- 18 Hwang YH, Yoo C, Kim YY. Myopic optic disc tilt and the characteristics of peripapillary retinal nerve fiber layer thickness measured by spectral-domain optical coherence tomography. *J Glaucoma* 2012;21(4):260-265.
- 19 Sezgin Akcay BI, Gunay BO, Kardes E, Unlu C, Ergin A. Evaluation of the ganglion cell complex and retinal nerve fiber layer in low, moderate, and high myopia: a study by RTVue spectral domain optical coherence tomography. *Semin Ophthalmol* 2017;32(6):682-688.
- 20 Chang PY, Wang JY, Wang JK, Huang TL, Hsu YR. Optical coherence tomography angiography compared with optical coherence tomography for detection of early glaucoma with high myopia. *Front Med (Lausanne)* 2021;8:793786.
- 21 Ishida T, Jonas JB, Ishii M, Shinohara K, Ikegaya Y, Ohno-Matsui K. Peripapillary arterial ring of zinn-haller in highly myopic eyes as detected by optical coherence tomography angiography. *Retina*

- 2017;37(2):299-304.
- 22 Jonas JB, Wang YX, Dong L, Panda-Jonas S. High myopia and glaucoma-like optic neuropathy. *Asia Pac J Ophthalmol (Phila)* 2020; 9(3):234-238.
- 23 Liu M, Wang P, Hu X, Zhu C, Yuan Y, Ke B. Myopia-related stepwise and quadrant retinal microvascular alteration and its correlation with axial length. *Eye (Lond)* 2021;35(8):2196-2205.
- 24 Kim HK, Kim SS. Factors associated with axial length elongation in high myopia in adults. *Int J Ophthalmol* 2021;14(8):1231-1236.
- 25 Jagadeesh D, Philip K, Fedtke C, Jong M, Ly A, Sankaridurg P. Posterior segment conditions associated with myopia and high myopia. *Clin Exp Optom* 2020;103(6):756-765.
- 26 Meng LH, Yuan MZ, Zhao XY, Chen YX. Macular Bruch's membrane defects and other myopic lesions in high myopia. *Int J Ophthalmol* 2022;15(3):466-473.
- 27 Deng L, Gwiazda J, Manny RE, Scheiman M, Weissberg E, Fern KD, Weise K, COMET Study Group. Limited change in anisometropia and aniso-axial length over 13 years in myopic children enrolled in the Correction of Myopia Evaluation Trial. *Invest Ophthalmol Vis Sci* 2014;55(4):2097-2105.
- 28 Wei Y, Jiang H, Shi Y, Qu D, Gregori G, Zheng F, Rundek T, Wang J. Age-related alterations in the retinal microvasculature, microcirculation, and microstructure. *Invest Ophthalmol Vis Sci* 2017; 58(9):3804-3817.
- 29 Leng Y, Tam EK, Falavarjani KG, Tsui I. Effect of age and myopia on retinal microvasculature. *Ophthalmic Surg Lasers Imaging Retina* 2018;49(12):925-931.
- 30 Yu J, Jiang C, Wang X, Zhu L, Gu R, Xu H, Jia Y, Huang D, Sun X. Macular perfusion in healthy Chinese: an optical coherence tomography angiogram study. *Invest Ophthalmol Vis Sci* 2015;56(5):3212-3217.