

Bilateral hip heterotopic ossification with sciatic nerve compression on a paediatric patient—An individualized surgical approach: A case report

João Pedro Gouveia Nóbrega, Pedro Jordão, Joana Arcângelo

Specialty type: Orthopedics

Provenance and peer review:

Unsolicited article; Externally peer reviewed.

Peer-review model: Single blind

Peer-review report's scientific quality classification

Grade A (Excellent): 0

Grade B (Very good): 0

Grade C (Good): C

Grade D (Fair): 0

Grade E (Poor): 0

P-Reviewer: Greco T, Italy

Received: September 5, 2021

Peer-review started: September 5, 2021

First decision: December 2, 2021

Revised: December 15, 2021

Accepted: July 18, 2022

Article in press: July 18, 2022

Published online: August 18, 2022



João Pedro Gouveia Nóbrega, Department of Orthopaedics, Hospital Dr. Nélio Mendonça, Funchal 9000-243, Portugal

Pedro Jordão, Joana Arcângelo, Department of Orthopaedics, Hospital Dona Estefânia, Lisboa 1169-045, Portugal

Corresponding author: João Pedro Gouveia Nóbrega, MD, Surgeon, Department of Orthopaedics, Hospital Dr. Nélio Mendonça, Caminho do Arieiro nº46, Funchal 9000-243, Portugal. joaonobrega@campus.ul.pt

Abstract

BACKGROUND

Neurogenic heterotopic ossification is an acquired serious complication described in patients with central nervous system disorders and defined by bone formation in non-osseous tissue.

CASE SUMMARY

We present an unusual case of a 13-yr-old boy presenting with hip pain and severe gait impairment 5 mo after the diagnosis of hemiplegia following a spontaneous intracerebral haemorrhage. Computed tomography revealed bilateral heterotopic ossification of both the paretic and the non-paretic limbs, with entrapment of the sciatic nerve. The choice of surgical or nonsurgical management of such patients depends on the timing of diagnosis, the symptoms, and the extent of maturation of the ossified lesions. Surgical resection remains the only treatment with proven, evidence-based effectiveness. The choice of surgical approach largely depends on the location of the ossified lesions.

CONCLUSION

We believe the plane of dissection presented is a satisfactory option for resection of a posteromedial mass and sciatic nerve release.

Key Words: Hip; Heterotopic ossification; Pediatrics; Orthopedics; Resection surgery; Case report

©The Author(s) 2022. Published by Baishideng Publishing Group Inc. All rights reserved.

Core Tip: Rare case of a post-stroke bilateral neurogenic heterotopic ossification of the hip with sciatic nerve entrapment in a paediatric patient with an individualised surgical approach for resection and release of the sciatic nerve.

Citation: Nóbrega JPG, Jordão P, Arcângelo J. Bilateral hip heterotopic ossification with sciatic nerve compression on a paediatric patient—An individualized surgical approach: A case report. *World J Orthop* 2022; 13(8): 768-774

URL: <https://www.wjgnet.com/2218-5836/full/v13/i8/768.htm>

DOI: <https://dx.doi.org/10.5312/wjo.v13.i8.768>

INTRODUCTION

Neurogenic heterotopic ossification (NHO) is a process of ectopic bone deposition in non-skeletal tissue in the setting of an event involving the central nervous system, such as a stroke, cerebral anoxia, or cranial or medullary injury. Its severity and clinical presentation vary depending on the extension of the ossified lesion and the compromise of adjacent neurovascular structures. The etiopathogenesis of NHO is unclear, but existing evidence supports the involvement of neuronal control mechanisms[1] and conversion of mesenchymal progenitor cells to osteoblast lineages[2] with the participation of prostaglandin E2 and osteoblast stimulating factors[3]. In this report, we introduce a case of a paediatric patient who, following a haemorrhagic stroke, developed bilateral hip NHO with entrapment of the sciatic nerve and with the unusual involvement of both the paretic and nonparetic limbs. We describe our surgical approach and resection strategy.

CASE PRESENTATION

Chief complaints

A 13-yr-old boy with sickle cell trait presented with hip pain and limited range of motion.

History of present illness

The patient had a 5-mo history of painful bilateral hip stiffness that progressively impaired his gait. Extensive bilateral heterotopic ossification was seen on pelvic radiographs (Figure 1).

History of past illness

The patient had an history of right fronto-temporal haemorrhagic stroke because of an arteriovenous malformation, complicated with a right chronic subdural haemorrhage resulting in right facial nerve palsy with dyspraxia and left hemiplegia that has persisted since then.

Personal and family history

There is no personal and family history.

Physical examination

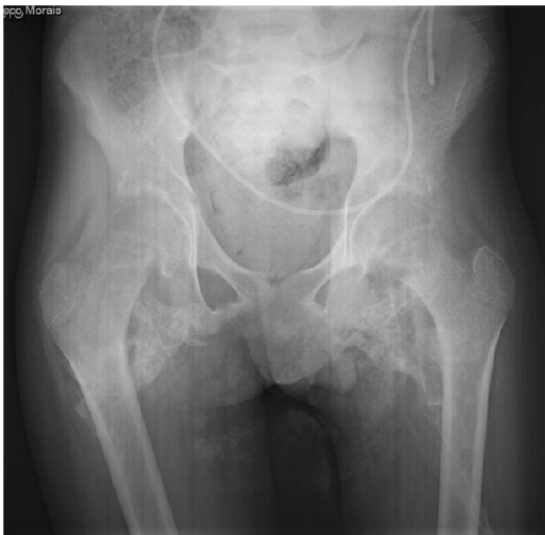Motor examination revealed left spastic hemiparesis (0/5) with hyperreflexia and right side upper limb motor function of 4+/5 and 3/5 on the ipsilateral lower limb. The patient presented with painful, generalized and progressive limited passive range of motion of both hips, and soon was completely bedridden.

Laboratory examinations

There is no laboratory examinations.

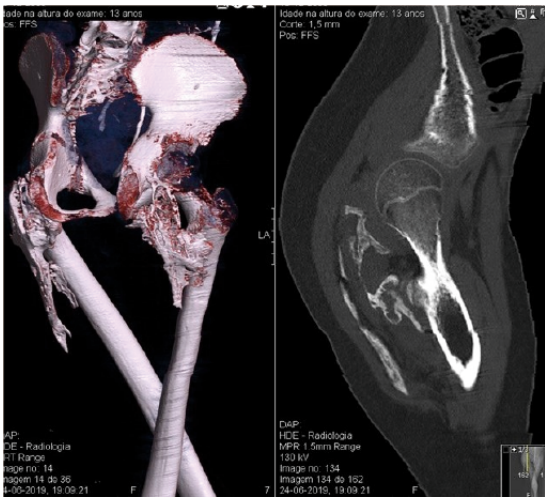
Imaging examinations

A computed tomography (CT) scan documented extensive calcification occupying the ischial-femoral space, with bilateral involvement of the posterior muscles of the thigh, mainly the external obturator, gemellus inferior and the proximal aspect of the biceps femoris. A 2.5 cm extension and oedema resulted in osseous incarceration of the proximal aspect of the sciatic nerve that was more evident on the right side (Figures 2 and 3).



DOI: 10.5312/wjo.v13.i8.768 Copyright ©The Author(s) 2022.

Figure 1 Antero-posterior pelvic radiograph showing extensive bilateral heterotopic ossification.



DOI: 10.5312/wjo.v13.i8.768 Copyright ©The Author(s) 2022.

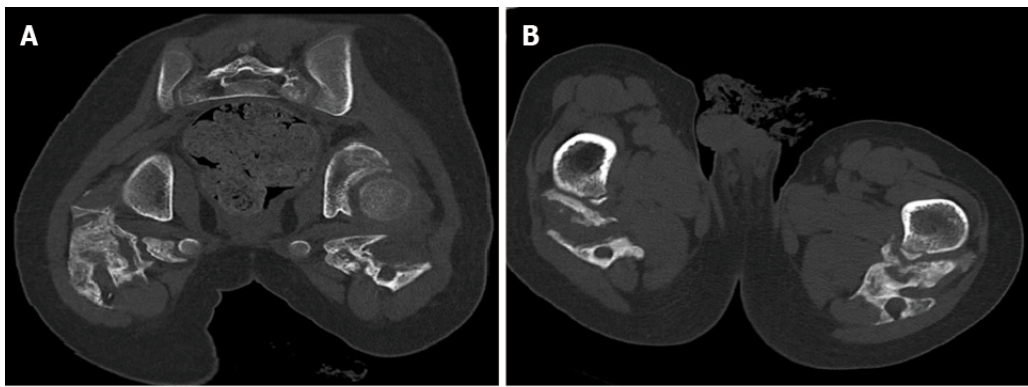
Figure 2 Computed tomography showing a bilateral bony bridge between the ischium and postero-medial proximal femur that limits hip range of motion.

FINAL DIAGNOSIS

The patient was diagnosed with posteromedial bilateral heterotopic ossification with entrapment of both proximal aspects of the sciatic nerve.

TREATMENT

Surgical resection of the ossified lesion and release of the sciatic nerve were performed, starting with the right hip. A modified posterior thigh approach that was developed by the senior author was used for both hips. The procedure was performed with the patient in a ventral position and began with a “lazy S” incision made in the centre of the gluteal region (Figure 4A). The gluteus maximus was detached from its distal insertion point on the proximal femur and retracted proximally, a manoeuvre intended to preserve gluteus vascularization from the superior gluteal artery. The sciatic nerve was then identified at both extremities of the ossification and subsequently released (Figure 4B and C). Note that a fibrous capsule that had formed between the nerve and the bone facilitated the dissection, which was performed with Kerrison forceps and meticulous haemostasis.



DOI: 10.5312/wjo.v13.i8.768 Copyright ©The Author(s) 2022.

Figure 3 Computed tomography and axial view. A: A proximal section showing ossification of the gluteal and posterior thigh musculature; B: A distal section showing ossification around the sciatic nerve.

OUTCOME AND FOLLOW-UP

Resection was performed on the left hip 6 wk later, and radiographic evaluation revealed a limited NHO relapse on the right hip (Figure 5A). Postoperatively, the patient began partial weight-bearing walking and participation in a rehabilitation program. After 1-yr of follow-up, there was no further development of the NHO lesions on radiographic evaluations and the patient had experienced a significant clinical improvement, being able to resume walking (Figure 5B).

DISCUSSION

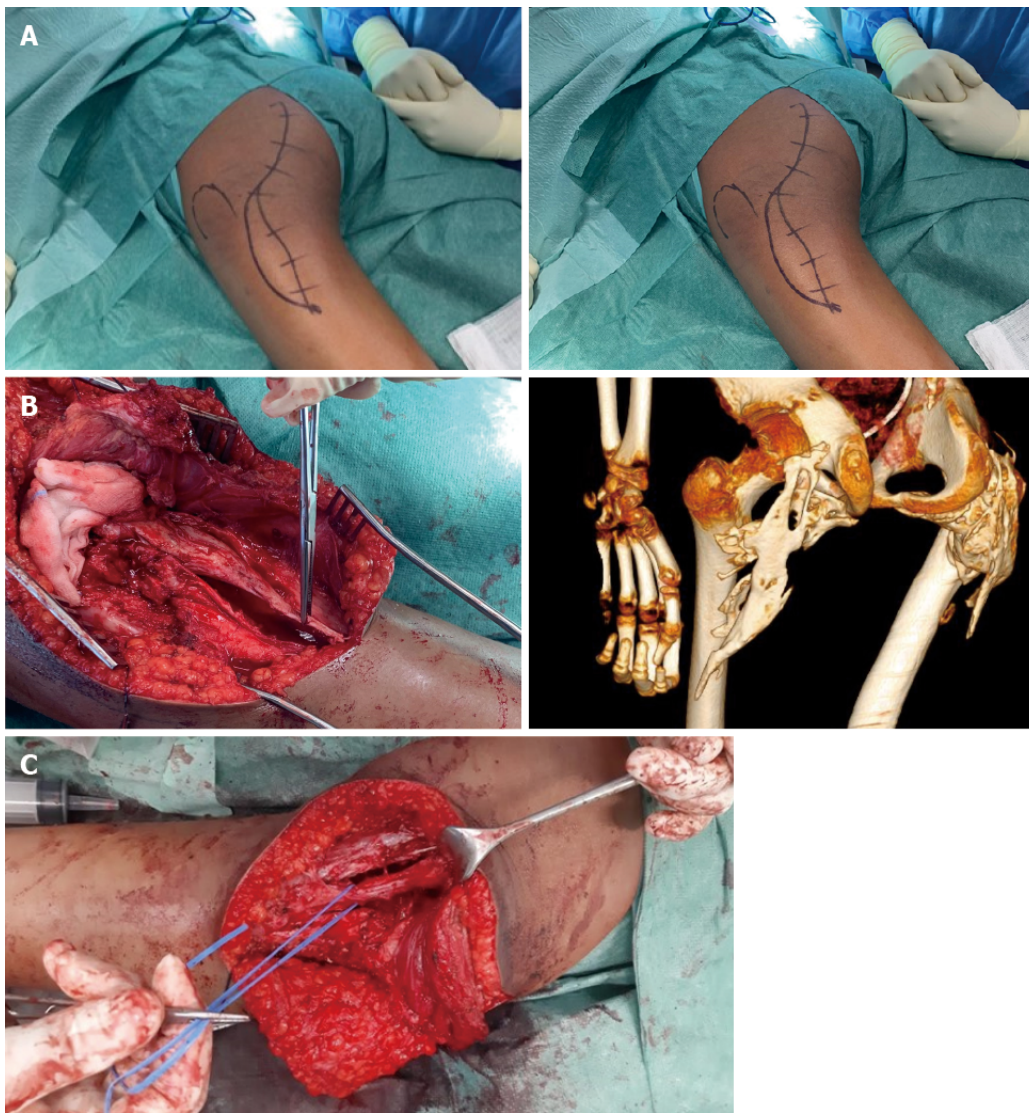
NHO is not often encountered in the paediatric population, and that has resulted in the use of diagnostic and treatment methods based on experience and evidence obtained in adults. To our knowledge, this is the first published case of a post-stroke bilateral NHO of the hip with sciatic nerve entrapment in a paediatric patient. Management of these patients is complex and requires multidisciplinary intervention. Even though there is a lack of evidence to support their effectiveness, and there are some conflicting viewpoints, conservative measures remain the first approach in the early stages of NHO. Pharmacological therapy with bisphosphonates and indomethacin has demonstrated efficacy in the early inflammatory phase of NHO, reducing disease progression. Non-steroidal anti-inflammatory drugs, particularly indomethacin, reduce the incidence of NHO in patients with spinal cord injury[4] but increase the risk of haemorrhagic complications that could be serious in patients with sickle cell trait, such as ours.

Furthermore, peri-articular radiation is considered another valid early-stage therapeutic modality that has been found to be more effective than non-steroidal anti-inflammatory drugs[5]. It is considered useful for inactivating the high mitotic rate of the pluripotent osteoprogenitor cells recruited by the inflammatory cascade and their differentiation into osteoblasts and chondrocytes[6]. Low-dose radiation therapy administered preoperatively or less than 72 h postoperatively represents an effective treatment [7], not only in reducing the size of NHO lesions[8] but also the risk of recurrence[9], with minimal side effects[10].

Another conservative treatment applied is physical therapy, but whether it plays a significant role in the mitigation of NHO lesions remains unclear. It has been suggested that forced manipulation of the extremity can induce HO formation by increasing inflammation[11], whereas lack of movement can cause HO formation and progression to ankylosis. Cautious use of a gentle range of motion is considered the best approach. In this case, we believe that recurrence of the HO on the right hip was promoted by the immobilization incurred while the patient waited for surgery of his left hip. It was only after both hips were operated and freed of ossification, and mobilization was resumed that the HO on the right side stopped progressing. Besides that, postoperative low-dose radiation therapy could have also contributed to minimization of the high risk for recurrence of HO lesions after resection on the right hip.

For this particular case, the patient presented with severe pain, gait impairment and the presence of signs of neurological compromise. It is generally agreed in the orthopaedic community[12] that fully matured hip HO limits the use and efficacy of conservative treatment modalities as curative options. Therefore, surgical intervention remains the mainstay for treatment of mature HO lesions.

First of all, surgical intervention should not aim for a complete resection, as this could incur an increased risk of haemorrhage and infection. A “functional” resection that increases mobility and alleviates pain is preferable. Furthermore, the location of the heterotopic ossification on the hip, which



DOI: 10.5312/wjo.v13.i8.768 Copyright ©The Author(s) 2022.

Figure 4 Intraoperative views. A: Lazy “S” incision in the gluteal region; B: Resection of ossified lesions; C: Release of the sciatic nerve path.

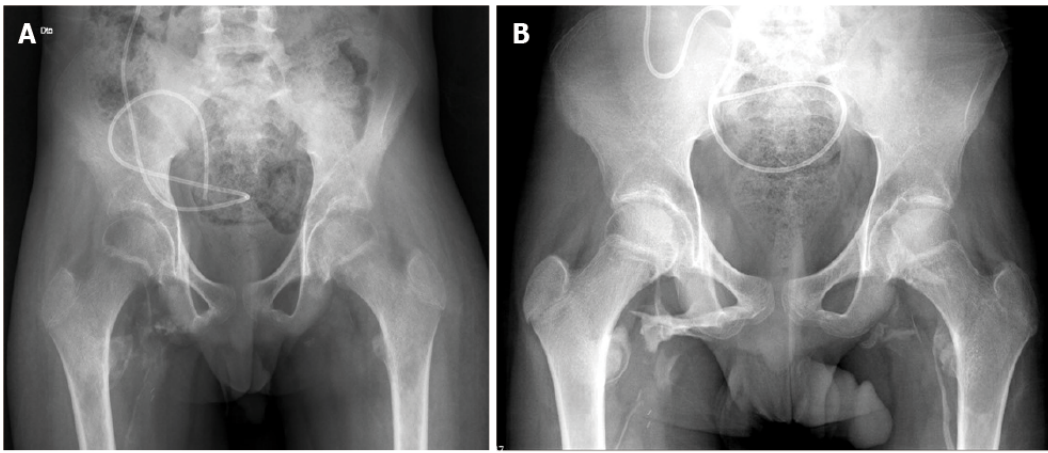
will guide the choice of surgical approach, is largely determined by certain aetiologies; for example, posterior lesions, like in our case, are typically associated with cerebral anoxia.

In our case, the heterotopic calcification had an extension below the plane of the greater gluteus muscle, from the trochanteric region to the ischiatic region. Traditional approaches (such as the posterolateral Gibson approach) do not allow for a clear exposition of this space. The transgluteal approach has the disadvantage of muscle denervation, and proximal disinsertion of the greater gluteus muscle may jeopardize its vascularization (gluteal artery, branch of the internal iliac artery). Thus, through an S-shaped incision that allows a wide area of exposure, the distal tendinous release of the greater gluteus muscle and the progressive disinsertion of this muscle exposes the entire plane of the rotators and hamstrings (where the major HO lesion lies) without compromising innervation and vascularization.

Controversy persists in the timing of surgery. It is accepted that HO lesions should not be surgically treated until bone maturation is complete with presence of defined cortical margins, which often appear around 6 mo after the beginning of ossification. Some authors suggest waiting 18 mo[8,13]. A recent study suggests that the risk of recurrence is independent of the time to surgery. Early surgery was found to prevent the development of joint ankylosis, and subsequent induction of epiphyseal osteoporosis, progressive cartilage loss, loss of function, joint stiffness, and bone demineralization with increased risk of fracture.

CONCLUSION

A posterior approach of the gluteal region with gluteus maximus distal disinsertion from proximal



DOI: 10.5312/wjo.v13.i8.768 Copyright ©The Author(s) 2022.

Figure 5 Radiograph. A: Radiograph obtained immediately after left hip resection, note the regrowth of ossification on the right hip, which was treated first; B: Radiograph at 1 yr after surgery shows limited regrowth of heterotopic ossification on the right hip with signs of cortical maturation.

femur and proximal retraction with a meticulous sciatic nerve release are favorable therapeutic options for severe posterior heterotopic ossifications. This case illustrates the practical difficulties of managing such patients and reinforces the need for specific guidelines not only for treatment and timing but also for the use of adjuvant therapy in the paediatric population, for which the literature is sparse.

FOOTNOTES

Author contributions: In terms of the revision, the first author Nóbrega JPG has complemented the text with the reviewers' requests and the other authors corrected and complemented the text.

Informed consent statement: The informed consent was signed and explained to the mother of this patient in portuguese language.

Conflict-of-interest statement: All authors report no relevant conflict of interest for this article.

CARE Checklist (2016) statement: The authors have read the CARE Checklist (2016), and the manuscript was prepared and revised according to the CARE Checklist (2016).

Open-Access: This article is an open-access article that was selected by an in-house editor and fully peer-reviewed by external reviewers. It is distributed in accordance with the Creative Commons Attribution NonCommercial (CC BY-NC 4.0) license, which permits others to distribute, remix, adapt, build upon this work non-commercially, and license their derivative works on different terms, provided the original work is properly cited and the use is non-commercial. See: <https://creativecommons.org/licenses/by-nc/4.0/>

Country/Territory of origin: Portugal

ORCID number: João Pedro Gouveia Nóbrega 0000-0002-1866-5575; Pedro Jordão 0000-0002-1659-9586; Joana Arcângelo 0000-0001-9722-2547.

S-Editor: Wu YXJ

L-Editor: A

P-Editor: Wu YXJ

REFERENCES

- 1 O'Brien MM, Murray T, Keeling F, Williams D. Intracerebral haemorrhage and hemiplegia with heterotopic ossification of the affected hip. *BMJ Case Rep* 2015; **2015** [PMID: 26243751 DOI: 10.1136/bcr-2015-211467]
- 2 Urist MR, Nakagawa M, Nakata N, Nogami H. Experimental myositis ossificans: cartilage and bone formation in muscle in response to a diffusible bone matrix-derived morphogen. *Arch Pathol Lab Med* 1978; **102**: 312-316 [PMID: 580725]
- 3 Shehab D, Elgazzar AH, Collier BD. Heterotopic ossification. *J Nucl Med* 2002; **43**: 346-353 [PMID: 11884494]
- 4 Banovac K, Williams JM, Patrick LD, Haniff YM. Prevention of heterotopic ossification after spinal cord injury with indomethacin. *Spinal Cord* 2001; **39**: 370-374 [PMID: 11464310 DOI: 10.1038/sj.sc.3101166]

- 5 **Cai L**, Wang Z, Luo X, She W, Zhang H. Optimal strategies for the prevention of heterotopic ossification after total hip arthroplasty: A network meta-analysis. *Int J Surg* 2019; **62**: 74-85 [PMID: 30615954 DOI: 10.1016/j.ijso.2018.12.011]
- 6 **Meiers C**, Lisiecki J, Miller S, Levin A, Fayad L, Ding C, Sono T, McCarthy E, Levi B, James AW. Heterotopic Ossification: A Comprehensive Review. *JBMR Plus* 2019; **3**: e10172 [PMID: 31044187 DOI: 10.1002/jbm4.10172]
- 7 **Milakovic M**, Popovic M, Raman S, Tsao M, Lam H, Chow E. Radiotherapy for the prophylaxis of heterotopic ossification: A systematic review and meta-analysis of randomized controlled trials. *Radiother Oncol* 2015; **116**: 4-9 [PMID: 26163090 DOI: 10.1016/j.radonc.2015.05.022]
- 8 **Davis E**, Williams K, Matheney TH, Snyder B, Marcus KJ, Shore BJ. Radiation Prophylaxis for Hip Salvage Surgery in Cerebral Palsy: Can We Reduce the Incidence of Heterotopic Ossification? *J Pediatr Orthop* 2019; **39**: e386-e391 [PMID: 30543561 DOI: 10.1097/BPO.0000000000001314]
- 9 **Cipriano C**, Pill SG, Rosenstock J, Keenan MA. Radiation therapy for preventing recurrence of neurogenic heterotopic ossification. *Orthopedics* 2009; **32** [PMID: 19750999 DOI: 10.3928/01477447-20090728-33]
- 10 **Georhakopoulos I**, Kouloulas V, Kougiountzopoulou A, Platoni K, Antypas C, Liakouli Z, Nikoloudi S, Kelekis N, Mouloupoulou LE, Zygogianni A. Radiation therapy for the prevention of heterotopic ossification: Efficacy and toxicity of single fraction radiotherapy. *Orthop Rev (Pavia)* 2020; **12**: 8577 [PMID: 32922703 DOI: 10.4081/or.2020.8577]
- 11 **Michelsson JE**, Rauschnig W. Pathogenesis of experimental heterotopic bone formation following temporary forcible exercising of immobilized limbs. *Clin Orthop Relat Res* 1983; 265-272 [PMID: 6406124 DOI: 10.1097/00003086-198306000-00039]
- 12 **Winkler S**, Wagner F, Weber M, Matussek J, Craiovan B, Heers G, Springorum HR, Grifka J, Renkawitz T. Current therapeutic strategies of heterotopic ossification--a survey amongst orthopaedic and trauma departments in Germany. *BMC Musculoskelet Disord* 2015; **16**: 313 [PMID: 26494270 DOI: 10.1186/s12891-015-0764-2]
- 13 **Denormandie P**, de l'Escalopier N, Gatin L, Grelier A, Genêt F. Resection of neurogenic heterotopic ossification (NHO) of the hip. *Orthop Traumatol Surg Res* 2018; **104**: S121-S127 [PMID: 29174871 DOI: 10.1016/j.otsr.2017.04.015]



Published by **Baishideng Publishing Group Inc**
7041 Koll Center Parkway, Suite 160, Pleasanton, CA 94566, USA

Telephone: +1-925-3991568

E-mail: bpgoffice@wjgnet.com

Help Desk: <https://www.f6publishing.com/helpdesk>

<https://www.wjgnet.com>

