

Massive trapezial metastasis from gastric adenocarcinoma resected and reconstructed with a vascularized scapular bone graft

A case report

Masanori Okamoto, MD, PhD^{a,*}, Hiroshi Yamazaki, MD, PhD^{a,b}, Yasuo Yoshimura, MD, PhD^{a,c}, Kaoru Aoki, MD, PhD^{a,d}, Atsushi Tanaka, MD^a, Hiroyuki Kato, MD, PhD^a

Abstract

Rationale: Isolated metastasis to the hand bones is very rare. Only seven cases of metastasis to the trapezium have been reported. To the best of our knowledge, this is the first report of a single metastasis to the trapezium from a gastric adenocarcinoma.

Patient concerns: A 62-year-old man presented with pain and massive swelling in the right carpometacarpal joint of the thumb.

Diagnoses: The patient was diagnosed with trapezial metastasis of advanced gastric adenocarcinoma.

Interventions: The patient underwent systemic chemotherapy with cisplatin and S-1, radiotherapy to the metastatic bone, and treatment with denosumab. One year later, the huge metastatic tumor was resected, and the hand was reconstructed using vascularized scapular bone.

Outcomes: Eighteen months postoperatively, the patient was satisfied with the appearance of the reconstructed hand and was able to use his right thumb in activities of daily living.

Lessons: Although rare, metastasis to the trapezium should be considered in patients with persistent and progressive thumb CMC joint pain.

Abbreviations: APL = abductor pollicis longus, CMC = carpometacarpal, DASH = disabilities of the arm, shoulder and hand, EPL = extensor pollicis longus, F = female, L = left, M = male, N/A = not assessed, R = right, RT = radiotherapy.

Keywords: gastric neoplasm, metastasis, scapular flap, trapezium

1. Introduction

Isolated metastasis to the hand bones is very rare, with an incidence as low as 0.1%.^[1] The primary tumor site is most commonly the lung, kidney, breast, or colon. The distal phalanx is the most frequently involved bone, and the thumb is the most frequently involved digit.^[2] Only 7 cases of metastasis to the trapezium have been reported.^[3–9] We herein report an extremely rare case of massive metastasis from a gastric adenocarcinoma to

the trapezium. The lesion was resected successfully, and the hand was reconstructed using vascularized scapular bone without damaging the function of the hand. A satisfactory appearance was achieved.

2. Case report

A 62-year-old man presented with pain and massive swelling in the right carpometacarpal (CMC) joint of the thumb (Fig. 1). He had been treated conservatively for thumb CMC osteoarthritis for 3 months. X-ray and computed tomography examinations revealed an osteolytic lesion in the trapezium with resorption of almost the whole trapezium (Fig. 2). Adenocarcinoma was identified by histopathological examination of the needle biopsy sample. Based on the results of positron emission tomography/computed tomography and gastrointestinal endoscopy, the patient was diagnosed with advanced gastric adenocarcinoma (cT3N2M1 for metastases of bone, Stage IV). No other distant metastases were found. He underwent systemic chemotherapy with cisplatin and S-1 (tegafur, gimeracil, and oteracil potassium combination), radiotherapy (30 Gy) to the metastatic bone, and treatment with denosumab (a fully human monoclonal antibody that inhibits receptor activator of nuclear factor-kappa B ligand).

One year later, the metastatic lesion to the trapezium had increased in size, formed new bone resembling a birdcage, and become involved in the first metacarpal bone (Figs. 3 and 4). Magnetic resonance imaging revealed that the lesion was limited to the bone and that there was no invasion to the soft tissue around the bone. Gastrointestinal endoscopy and positron emission tomography/computed tomography revealed that the

Editor: Shizhang Ling.

The study was approved by the institutional review board of our hospital, and the patient provided informed consent prior to study enrollment.

The authors have no conflicts of interest to disclose.

^a Department of Orthopaedic Surgery, Shinshu University School of Medicine,

^b Department of Orthopaedic Surgery, Aizawa Hospital, ^c Department of Rehabilitation Medicine, Shinshu University School of Medicine, ^d Department of Applied Physical Therapy, Shinshu University School of Health Sciences, Matsumoto, Nagano, Japan.

* Correspondence: Masanori Okamoto, Department of Orthopaedic Surgery, Shinshu University School of Medicine, 3-1-1 Asahi, Matsumoto, Nagano 390-8621, Japan (e-mail: ryoyuma@shinshu-u.ac.jp).

Copyright © 2017 the Author(s). Published by Wolters Kluwer Health, Inc. This is an open access article distributed under the terms of the Creative Commons Attribution-NonCommercial-ShareAlike 4.0 License, which allows others to remix, tweak, and build upon the work non-commercially, as long as the author is credited and the new creations are licensed under the identical terms.

Medicine (2017) 96:50(e9294)

Received: 7 June 2017 / Received in final form: 24 November 2017 / Accepted: 27 November 2017

<http://dx.doi.org/10.1097/MD.0000000000009294>

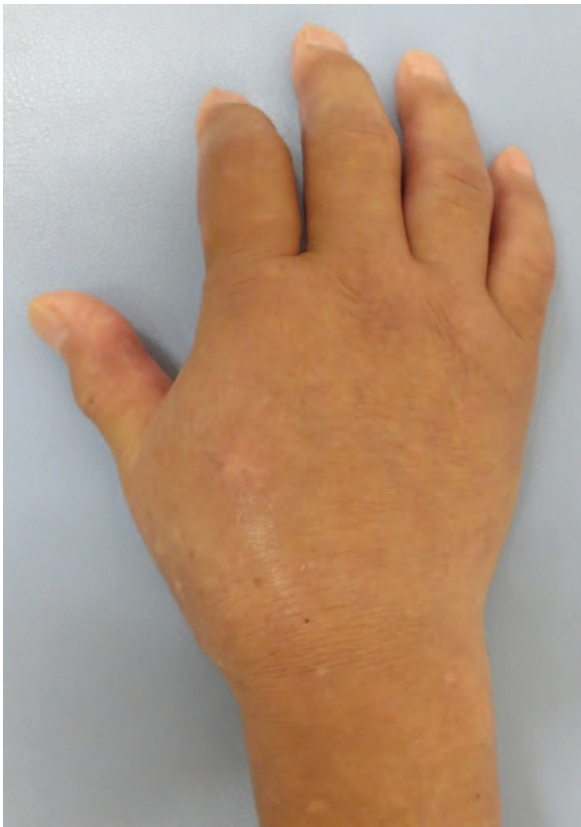


Figure 1. Photograph of the right hand at the initial visit. The patient's right carpometacarpal joint was swollen.

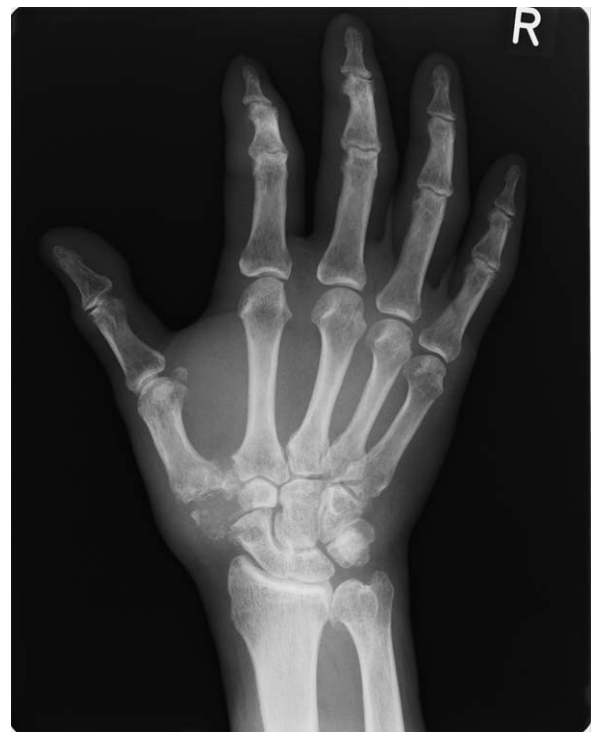

Figure 2. X-ray image of the right hand at the initial visit. The patient had an osteolytic lesion in the trapezium.

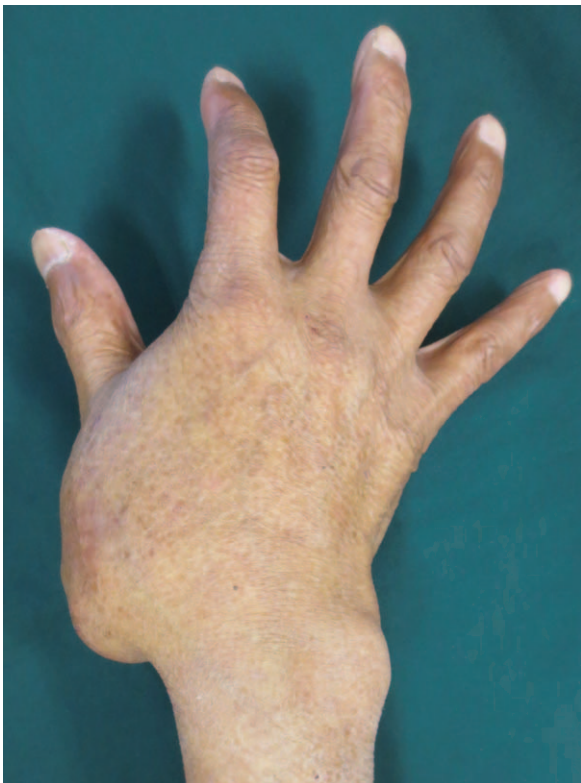

Figure 3. Photograph of the right hand prior to surgery. The patient complained of an unaesthetic appearance of the right hand.

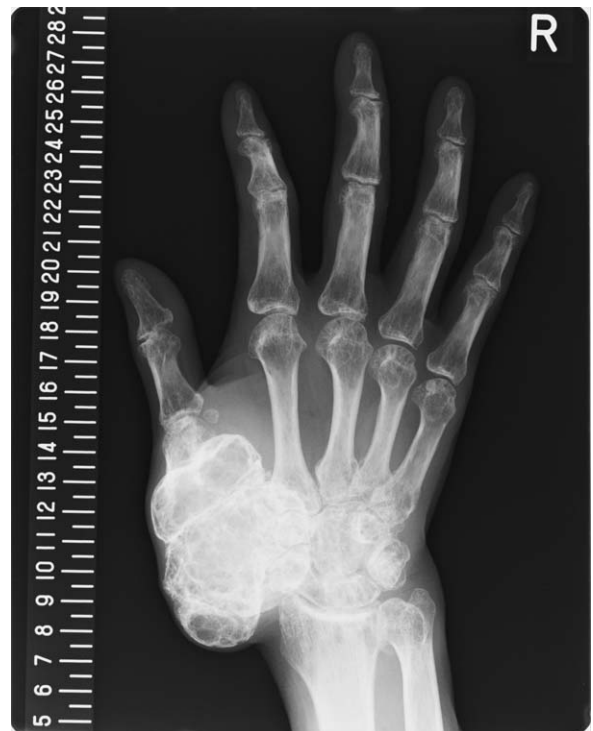

Figure 4. X-ray image of the right hand prior to surgery. The metastatic lesion to the trapezium had increased in size, formed new bone resembling a birdcage, and become involved the first metacarpal bone.

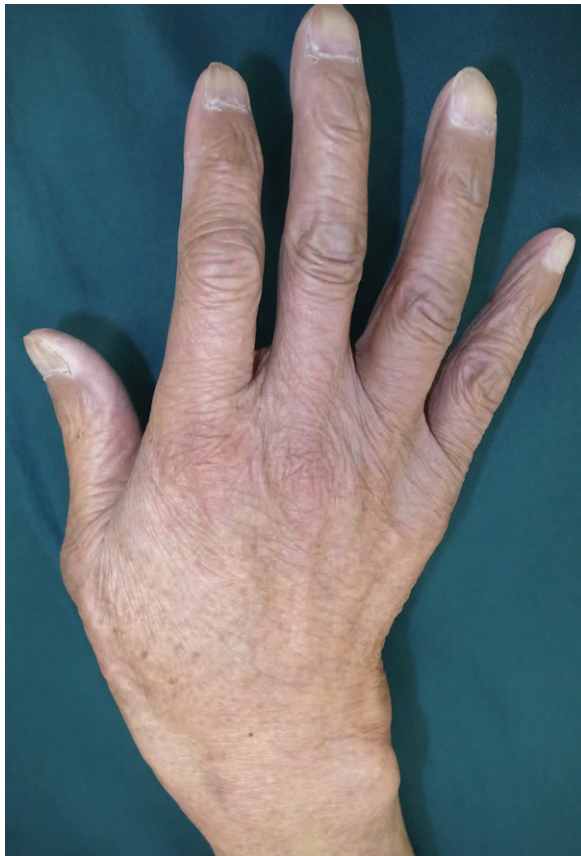

Figure 5. Photograph of the right hand 12 months postoperatively. The patient was satisfied with the appearance of the reconstructed hand.

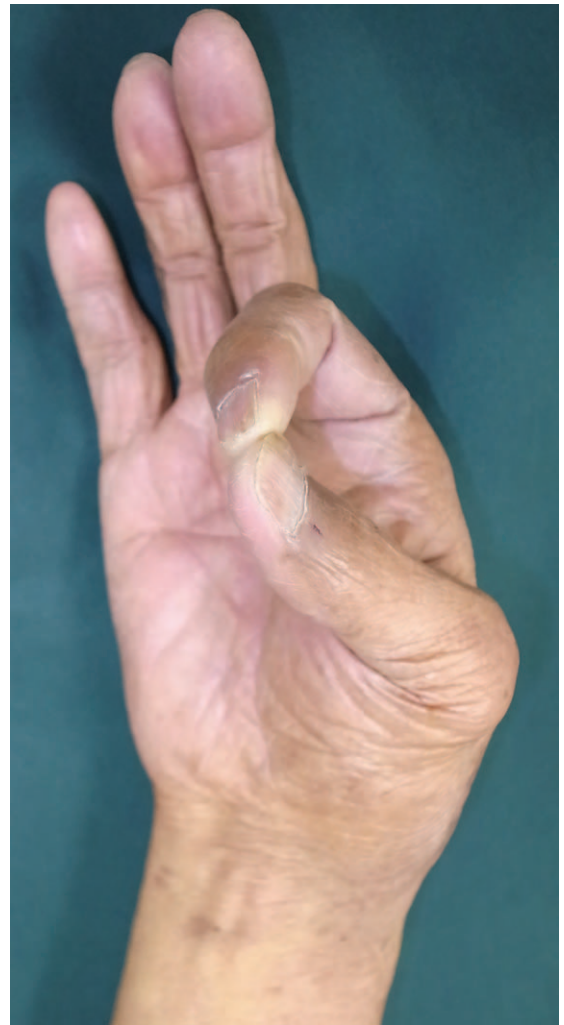

Figure 6. Photograph of the right hand 12 months postoperatively. The patient was satisfied with the function of the hand.

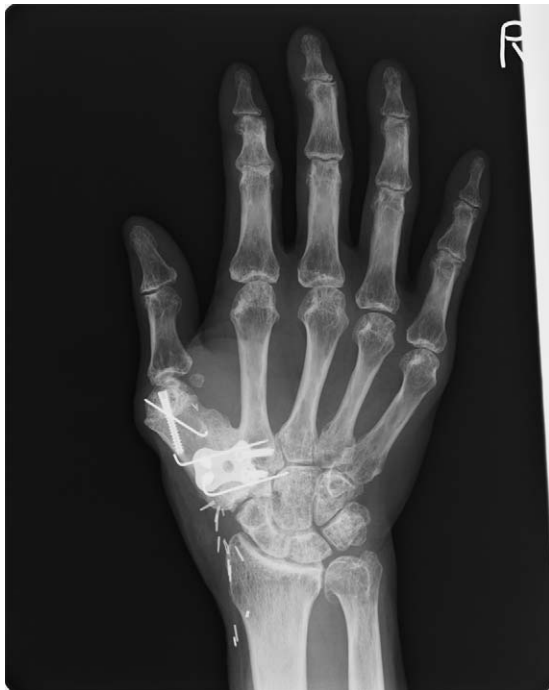

Figure 7. X-ray image of the right hand 12 months postoperatively. The grafted scapular bone had become united with the second metacarpal bone and trapezium.

size of the gastric cancer had substantially decreased and that no other distant metastases were present. Histological analyses of specimens obtained by multiple needle biopsies of the right hand revealed no viable tumor cells. The patient complained of an unaesthetic appearance of the right hand and a tingling sensation over the dorsal thumb. The thumb and wrist function were well preserved in spite of the huge size of the base of the thumb. The Disabilities of the Arm, Shoulder and Hand (DASH) score was 21.67, and the side pinch power in the right hand was 8.7kg.

We performed marginal resection of the tumor to improve the appearance of the hand. A lazy S incision was performed over the dorsal skin between the first and second metacarpal bones and extended to the radial side of the distal forearm. The thinning skin over the trapezium was retracted, and the entrapped superficial radial nerve between the skin and trapezium was released. The extensor pollicis longus (EPL) tendon remained intact. The abductor pollicis longus (APL) and the extensor pollicis brevis tendon were ruptured and adhered to the tumor. The trapezium and proximal four-fifths of the first metacarpus were resected with the periosteum of the adjacent second metacarpal bone and trapezium and distal articular portion of the scaphoid. The remaining bone defect and loss of subcutaneous fat tissue were reconstructed with vascularized lateral scapular bone and

Table 1**Characteristics of 7 previous cases and the present case of trapezial metastasis.**

Age/sex	Primary tumor	History of malignancy	Other metastases	Treatment	Survival	Dominant side	Diseased side	Ref
78/F	Sigmoid colon adenocarcinoma	4 years	Lung	Chemotherapy	6 months	N/A	L	Buckley and Peebles Brown ^[3]
39/F	Gastric adenocarcinoma	2 years	Rib, left capitale bone	RT (30 Gy), chemotherapy	N/A	N/A	R	Park et al ^[4]
Mid-40s/F	Nonsmall cell lung carcinoma	+	None	Excision of trapezium	3 months	R	R	Gaston et al ^[5]
80/F	Esophageal adenocarcinoma	3 years	Lung	Below-elbow amputation	7 months	R	L	Wurapa et al ^[6]
70/M	Renal cell carcinoma	None	Femur	None	N/A	N/A	R	Borghain et al ^[7]
74/M	Large cell lung carcinoma	None	None	Below-elbow amputation	6 months	N/A	L	Rinonapoli et al ^[8]
70/M	Non-small cell lung carcinoma	Stage T4 prostate cancer	None	Hemi-trapeziectomy	N/A	R	R	Song and Yao ^[9]
64/M	Gastric adenocarcinoma	None	None	RT (30 Gy), chemotherapy, excision of trapezium and first metacarpal, and reconstruction	36 months	R	R	Present case

F=female, L=left, M=male, N/A=not assessed, R=right, RT=radiotherapy.

parascapular fascio-fat tissue. The right circumflex scapular artery was anastomosed to the radial artery and cephalic vein located on the distal forearm in an end-to-end fashion. The harvested lateral border of the scapular bone was placed at the bone defect. After positioning the bone with the thumb to 40° of radial abduction and 20° of palmar abduction, a reconstruction plate was used for fixation among the scapular bone, trapezoidal bone, and second metacarpal bone. The scapular bone was fixed to the head of the first metacarpal bone using a screw and K-wire.

We created a small space between the grafted scapula and distal end of the scaphoid to avoid obstruction of the scaphoid motion with wrist motion. The APL tendon was reconstructed with a free tendon graft using a half-slip of the ruptured EPL tendon graft between the distal ruptured APL tendon end and the proximal ruptured EPL tendon. The harvested fascio-fat tissue was inserted between the reconstructed tendons and the grafted bone to prevent tendon adhesion and maintain the natural round appearance of the base of the thumb. The histopathological diagnosis was total necrosis.

Eighteen months postoperatively, the patient was satisfied with the appearance of the reconstructed hand and disappearance of the tingling numbness over the dorsal thumb. The patient was right handed and was able to use his right thumb in activities of daily living, such as writing and using chopsticks (Figs. 5 and 6). His DASH score was 12.5 and side pinch power in the right hand was 5.1 kg. A radiograph demonstrated bony union of the free scapular flap (Fig. 7). Neither recurrence nor new distant metastasis was observed.

3. Discussion

Metastatic lesions to the trapezium are very rare; only 7 cases have been reported (Table 1).^[3–9] Of these, 3 cases involved a single metastasis to the trapezium from a lung carcinoma.^[5,8,9] To the best of our knowledge, this is the first report of a single metastasis to the trapezium from a gastric adenocarcinoma.

One reason for the delayed diagnosis of carpal metastasis is the rarity of this location for metastatic lesions.^[8] Symptoms of carpal metastasis mimic those of septic or rheumatoid arthritis, osteomyelitis, and avascular necrosis. Metastasis to the trapezium causes tenderness over the volar aspect of the thumb CMC joint and pain on the axial grind test, both of which are consistent

with thumb CMC arthritis.^[5] Our patient had undergone conservative treatment for thumb CMC osteoarthritis before his presentation to our institute. Although rare, metastasis to the trapezium should be considered in patients with persistent and progressive thumb CMC joint pain.

The optimal treatment of hand metastasis remains controversial. Conservative therapy (chemotherapy and/or radiotherapy) is the most common treatment because patients with hand metastasis may have limited survival rates. Because there is no evidence that surgical resection improves the prognosis of patients with stage IV gastric cancer, we had no indications for surgery including the primary tumor. In the present case, the gastric cancer was successfully treated with chemotherapy, although gastric cancer with metastasis generally has a poor prognosis.^[10] The size of the metastatic lesion did not change after radiation, and the histologic appearance of the multiple needle biopsies was negative for viable cells, although the lesion increased in size during adjuvant chemotherapy. The hand and wrist function were well preserved despite the bulky size of the trapezium with destruction of the thumb CMC and scapho-trapezial joint.

The patient wished to regain an acceptable appearance of the hand without sacrificing hand or wrist function. Therefore, total resection of the metastatic lesion was performed. We performed reconstruction using a vascularized bone graft because prostheses are associated with risks including infection and loosening in patients who undergo total trapeziectomy. The lateral border of the scapula was selected to fit the proper size of the first metacarpus and to easily unite the remaining head of the first metacarpus. Fascio-fat tissue, including the scapular flap, was used to form the natural contour of the thenar eminence as well as to protect the adhesion of the reconstructed extensor tendons. We did not need to use a monitoring skin flap because the skin of the dorsal hand was already expanded by the tumor and a monitoring flap would have disturbed the cosmetic appearance.

Acknowledgment

We thank Angela Morben, DVM, ELS, from Edanz Group (www.edanzediting.com/ac) for editing a draft of this manuscript.

References

- [1] Kerin R. Metastatic tumors of the hand. A review of the literature. *J Bone Joint Surg Am* 1983;65:1331–5.
- [2] Flynn CJ, Danjoux C, Wong J, et al. Two cases of acrometastasis to the hands and review of the literature. *Curr Oncol* 2008;15:51–8.
- [3] Buckley N, Peebles Brown DA. Metastatic tumors in the hand from adenocarcinoma of the colon. *Dis Colon Rectum* 1987;30:141–3.
- [4] Park KH, Rho YH, Choi SJ, et al. Acute arthritis of carpal bones secondary to metastatic gastric cancer. *Clin Rheumatol* 2006;25:258–61.
- [5] Gaston RG, Lourie GM, Scott CC. Isolated metastatic lesion of the trapezium. *Am J Orthop (Belle Mead NJ)* 2008;37:E144–145.
- [6] Wurapa RK, Bickel BA, Mayerson J, et al. Metastatic esophageal adenocarcinoma of the carpus. *Am J Orthop (Belle Mead NJ)* 2010;39:283–5.
- [7] Borgohain B, Borgohain N, Khonglah T, et al. Occult renal cell carcinoma with acrometastasis and ipsilateral juxta-articular knee lesions mimicking acute inflammation. *Adv Biomed Res* 2012;1:48.
- [8] Rinonapoli G, Caraffa A, Antenucci R. Lung cancer presenting as a metastasis to the carpal bones: a case report. *J Med Case Rep* 2012;6:384.
- [9] Song Y, Yao J. Trapezial metastasis as the first indication of primary non-small cell carcinoma of the lung. *J Hand Surg Am* 2012;37:1242–4.
- [10] Houdek MT, Wagner ER, Wyles CC, et al. New options for vascularized bone reconstruction in the upper extremity. *Semin Plast Surg* 2015;29:20–9.