



Carcinoid Klatskin tumour: A rare cause of obstructive jaundice

Suhail Khuroo¹, Arshad Rashid², Rajandeep Singh Bali², Majid Mushtaque², Farzana Khuroo³

1. KEM Hospital & Seth GS Medical College, Mumbai, India; 2. Lok Nayak Hospital & Maulana Azad Medical College, Delhi, India; 3. Sopore Nursing Home, Sopore, India

CASE REPORT

Please cite this paper as: Khuroo S, Rashid A, Bali RS, Mushtaque M, Khuroo F. Carcinoid Klatskin tumour: A rare cause of obstructive jaundice. AMJ 2014, 7, 6, 243–246. <http://doi.org/10.21767/AMJ.2014.1934>

Corresponding Author:

Dr Arshad Rashid
1/E Umar Abad Colony, Sopore, India
Email: arsh002@gmail.com

ABSTRACT

Carcinoid tumours of the extrahepatic biliary ducts represent an extremely rare cause of bile duct obstruction. We report a case of obstructive jaundice secondary to carcinoid tumour arising at the hilar confluence. Resection of the primary tumour was done and the patient is doing well on follow-up. This case demonstrated that surgery offers the only potential cure for biliary carcinoid and aggressive surgical therapy should be the preferred treatment in cases of potentially resectable biliary tumours.

Key Words

Carcinoid tumour; Klatskin tumour; Neuro-endocrine tumour; Biliary tract; Obstructive Jaundice

Implications for Practice:

1. What is known about this subject?

Carcinoid tumour of the hilar region is extremely rare; only 14 cases have been published to date.

2. What new information is offered in this study?

A carcinoid tumour occurring at the hilar region is an extremely rare cause of obstructive jaundice. Surgery offers the best chance of a cure.

3. What are the implications for research, policy, or practice?

This case advocates surgery as the preferred option for resectable carcinoid Klatskin tumour; however, further studies are needed to establish protocols for treatment in cases of unresectable disease.

Background

Carcinoma of the extrahepatic biliary ducts account for less than 2 per cent of all cancers, and adenocarcinoma is the most common neoplasm arising from the epithelium of the biliary tree accounting for up to 80 per cent of all duct cancers.^{1,2} The overall incidence of carcinoid tumours is estimated to be 1 to 2 per 100,000; however, carcinoid tumours of the extrahepatic biliary ducts are exceedingly rare, accounting for only 0.1–0.2 per cent of all carcinoids of the gastrointestinal tract.^{3,4} Bile duct carcinoids occur more commonly in younger patients and more commonly in women.⁵ A review of the published literature since the first reported case in 1959 identified 70 cases with carcinoid tumours arising from the biliary tree have been reported, among which 14 cases present with hilar tumours.^{6–8} We report here a case of obstructive biliopathy secondary to carcinoid tumour arising at the hilar confluence.

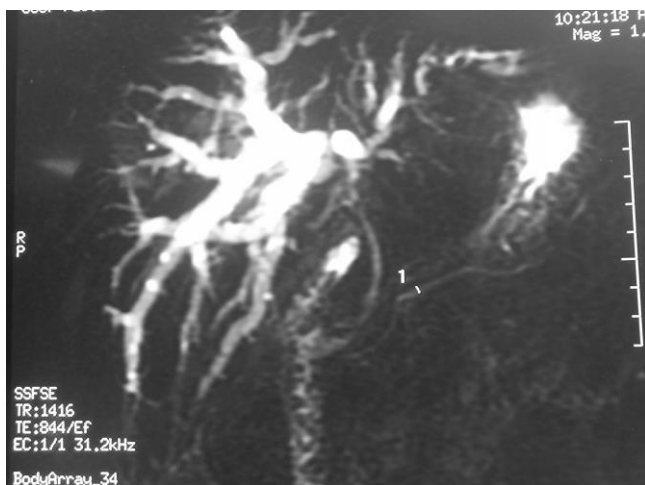
Case details

A 56-year-old female presented with a 6-month history of right upper abdominal pain and a 1-month history of progressive jaundice with weight loss. The patient had undergone cholecystectomy seven years back for gallstone disease. Clinical examination revealed icterus and mild tenderness in the right hypochondrium without any palpable abdominal mass. Laboratory investigations

were unremarkable except for grossly deranged liver function tests with markedly elevated alkaline phosphatase.

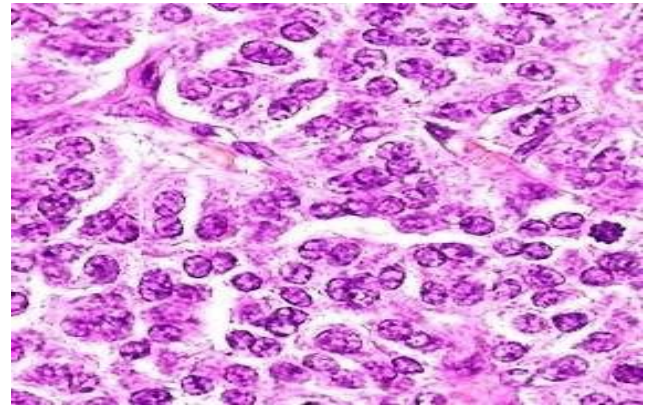
Abdominal ultrasound showed post-cholecystectomy status with mild dilatation of intrahepatic biliary radicles (IHBR). Magnetic resonance cholangiopancreatography (MRCP) revealed a mitotic soft tissue mass in porta obliterating biliary confluence with IHBR dilatation in both lobes suggestive of Klatskin tumour (Figure 1). Contrast enhanced computed tomography (CECT) scan suggested a soft tissue mass in the porta hepatis obstructing the common hepatic duct without major vascular involvement.

Figure 1: MRCP showing dilated IHBR in both lobes with cut off at the hilum



The patient was planned for surgery and resection of the hilar tumour; hepatico-jejunostomy was also accomplished with lymph node dissection in the peri-portal and peri-choledochal area. A white, well-circumscribed firm nodular mass measuring 1.7 x 1.3 x 0.8cm was found at the hilum. Histopathology revealed small round cells arranged in tubules and glands with a rosette-like pattern that was consistent with features of carcinoid tumour (Figure 2). Surgical margins were clear and a total of nine lymph nodes were found that were negative for metastases. The tumour cells were argyrophilic and were positive for chromogranin A and serotonin on immunohistochemistry. There was no intra-operative or post-operative complication and the patient was discharged from the hospital six days after the operation. The patient has been on regular follow-up for the last 18 months and is doing well.

Figure 2: Small round cells arranged in tubules, glands, and rosettes



Discussion

Carcinoid tumours arise from enterochromaffin cells, also known as argentaffin or Kulchitsky cells that are thought to arise from embryonic neural crest cells in the gastrointestinal tract and respiratory cells.³ The term enterochromaffin refers to the ability to stain with potassium chromate, a feature of cells that contain serotonin. These cells are located in the gastrointestinal tract, most commonly the small intestine, appendix, and rectum, or at various sites within the respiratory tract or the pelvic cavity (uterine, cervix, ovary, and testis), the larynx and the breast.¹⁻⁹ A small number of these cells also exists in the biliary tree.¹⁰ Chronic inflammation of the biliary tract causes an increased number of these cells, thus leading to the development of carcinoid tumours.¹¹

The term "carcinoid tumour" has been replaced by the term "well-differentiated endocrine tumour" by Capella et al. in the latest World Health Organization (WHO) classification of tumours.¹² The WHO staging system is based on criteria such as: tumour size, histological differentiation, Ki-67 immunostaining, invasion of adjacent structures, and vascular and perineural invasion.¹²

Pilz reported the first case of a carcinoid tumour that unmistakably arose from the extra-hepatic biliary tract, and since then 70 cases have been reported.¹³ Biliary neuroendocrine tumours can be hormonally active and many stain positive for somatostatin, serotonin, and gastrin. Most of the reported cases had non-functioning tumours without evidence of systemic endocrine manifestations. Biliary carcinoids tend to be small (1.1 to 5.5cm) and their presenting symptoms like jaundice, biliary colic, abdominal pain, cholangitis, weakness, weight loss, and backache seem to be secondary to either



local invasion into surrounding tissues or metastatic spread.^{14,15} Urinary levels of hydroxyindoleacetic acid are elevated in these patients.^{16,17} The most common anatomical locations for extrahepatic carcinoid tumours are common bile duct (58 per cent), perihilar duct (28 per cent), cystic duct (11 per cent), and common hepatic duct (3 per cent).¹ Our patient had a tumour located in the hilar region. These tumours are more common in women than in men, with a female-to-male ratio of 1.6:1.⁷ Their incidence peaks in the sixth decade of life.¹¹ Our patient was a female in her sixth decade.

Differential diagnosis of carcinoid Klatskin tumour includes cholangiocarcinoma, choledocholithiasis, and hilar strictures. MRCP and CECT can help in differentiating stones from tumours; however, carcinoid tumour can only be distinguished from cholangiocarcinoma by histopathology. Appropriate surgical management for this disease includes resection of the biliary tree with negative margins and restoration of continuity by hepatico-enterostomy along with dissection of lymph nodes in the hepato-duodenal ligament (peri-portal and peri-choledochal).

Available data extrapolated from the existing literature suggest that carcinoid tumours of the extra hepatic biliary tree are of low malignant potential and have a favourable overall prognosis following appropriate surgical management.¹⁸ However, these neoplasms tend to metastasise if left untreated.⁹ Complete resection of localised tumours, without metastases, results in a five-year survival rate of 60–100 per cent.¹⁹ Radiotherapy offers no benefit and chemotherapy has been used in metastatic disease with few reports to support any definitive conclusions.²⁰ As our patient was having a localised disease, surgery offered the best possible treatment for her.

References

1. Modin IM, Lye KD, Kidd M. A 5 decade analysis of 13,715 carcinoid tumours. *Cancer* 2003;97:934–59.
2. Squillaci S, Marchione R, Piccolomini M, Colombo F, Bucci F, Bruno M, Bisceglia M. Well differentiated neuroendocrine carcinoma (malignant carcinoid) of extrahepatic biliary tract: Report of two cases and literature review. *APMIS*. 2010 Aug;118(8):543–56.
3. Are C, Gonen M, D'Angelica M, DeMatteo RP, Fong Y, Blumgart LH, Jarnagin WR. Differential diagnosis of proximal biliary obstruction. *Surgery* 2006;140:756–63.
4. Jarnagin WR, Fong Y, DeMatteo RP, Gonen M, Burke EC, Bodniewicz BS J, Youssef BA M, Klimstra D, Blumgart LH. Staging, resectability and outcome in 225 patients with hilar cholangiocarcinoma *Ann Surg*. 2001 Oct;234(4):507–17; discussion 517–9.
5. Modlin IM, Sandor A. An analysis of 8305 cases of carcinoid tumours. *Cancer*. 1997 Feb 15;79(4):813–29.
6. Godwin JD. Carcinoid tumours: An analysis of 2387 cases. *Cancer*. 1975 Aug;36(2):560–9.
7. Kopelman D, Schein M, Kerner H, Bahuss H, Hashmonai M. Carcinoid tumour of common bile duct. *HPB Surg*. 1996;10(1):41–3.
8. Davies AJ. Carcinoid tumour (argentaffinoma). *Ann R Coll Surg Engl*. 1959 Dec;25(5):277–97.
9. Modlin IM, Shapiro MD, Kidd MD. An analysis of rare carcinoid tumours: Classifying these clinical conundrums. *World J Surg*. 2005 Jan;29(1):92–101.
10. Christie AC. Three cases illustrating the presence of argentaffin (Kulchitsky) cells in human gall bladder. *J Clin Pathol* 1954;7:318–21.
11. Barron LP, Manivel JC, Mendez AN, Jessunin J. Carcinoid tumour of common bile duct. Evidence for its origin in metaplastic endocrine cells. *Am J Gastroenterol* 1991;86:1073–76.
12. Capella C, Sobin LH, Arnold R. Endocrine tumours of the gall bladder and extrahepatic bile ducts. In: Hamilton RAL, ed. *Pathology & Genetics of tumours of the digestive system, WHO classification of tumours IARC press; Lyon, France*. 2000:214–66.
13. Pilz E. On carcinoid of the bile duct. *Zentralbl Chir*. 1961 Jul 8;86:1588–90.
14. Chamberlain RS, Blumgart LH. Carcinoid tumours of the extrahepatic bile ducts. A rare case of malignant biliary obstruction. *Cancer*. 1999 Nov 15;86(10):1959–65.
15. Nesi G, Lombardi A, Batignani G, Ficari F, Rubio CA, Tonelli F. Well differentiated endocrine tumour of the distal CBD: A case study and literature review. *Virchows Arch*. 2006 Jul;449(1):104–11.
16. Little JM, Gibson AA, Kay AW. Primary common bile duct carcinoid. *Br J Surg*. 1968 Feb;55(2):147–9.
17. Vitaux J, Salmon RJ, Languille O, Buffet C, Martin E, Chaput JC. Carcinoid tumour of the common bile duct. *Am J Gastroenterol*. 1981 Oct;76(4):360–2.
18. Maitra A, Krueger JE, Tascilar M, Offerhaus GJ, Angeles-Angeles A, Klimstra DS, Hruban RH, Albores-Saavedra J. Carcinoid tumours of the extrahepatic bile ducts: a study of seven cases. *Am J Surg Pathol*. 2000 Nov;24(11):1501–10.
19. Skogseid B, Grama D, Rastad J, Eriksson B, Lindgren PG, Ahlström H, Lörelius LE, Wilander E, Akerström G, Oberg K. Operative tumour yield obviates preoperative pancreatic tumour localisation in multiple endocrine neoplasia type I. *J Intern Med*. 1995 Sep;238(3):281–8.



20. Podnos YD, Jimenez JC, Zainabadi K, Ji P, Cooke J, Busuttill RW, Imagawa DK. Carcinoid tumours of the common bile duct: report of two cases. *Surg Today*.2003;33(7):553–5.

PEER REVIEW

Not commissioned. Externally peer reviewed.

CONFLICTS OF INTEREST

The authors declare that they have no competing interests.

PATIENT CONSENT

The authors, Khuroo S, Rashid A, Bali RS, Mushtaque M, and Khuroo F, declare that:

1. They have obtained written, informed consent for the publication of the details relating to the patient(s) in this report.
2. All possible steps have been taken to safeguard the identity of the patient(s).
3. This submission is compliant with the requirements of local research ethics committees.