



A case of conjunctival malignant melanoma with local recurrence

Somen Misra, Neeta Misra, Pratik Gogri, Venugopal Reddy, Akshay Bhandari

Department of Ophthalmology, Pravara Institute of Medical Sciences, Loni, India

CASE REPORT

Please cite this paper as: Misra S, Misra N, Gogri P, Reddy V, Bhandari A. A case of conjunctival malignant melanoma with local recurrence. AMJ 2013, 6, 6, 344-347. <http://doi.org/10.21767/AMJ.2013.1728>

Corresponding Author:

Pratik Gogri
Department of Ophthalmology, Rural Medical College,
Pravara Institute of Medical Sciences, Loni- 413736,
Taluka- Rahata, Ahmednagar, Maharashtra, India.
Email: pratikgogri@yahoo.com

Abstract

Malignant melanoma of the conjunctiva is a rare tumour of middle and old age. It is seen predominantly in whites, and is rare in those of pigmented ethnicity. Its clinical presentation varies, and making a clinical diagnosis may be difficult. The tumour is potentially fatal and displays a high rate of recurrence, which can be attributed to delay in diagnosis, as well as inadequate surgical approach. The literature on this melanoma is scanty, even in the West, particularly regarding the precise surgical technique.

We report a case of malignant melanoma of the conjunctiva which showed a local recurrence one year after the primary surgery. However, there was no evidence of distant metastasis on either occasion. This case highlights the need for care in making a diagnosis, meticulous attention to the surgical technique, and careful follow-up to detect further disease activity.

Key Words

De novo, Conjunctival malignant melanoma, Local recurrence

Implications for Practice

- **What is known about such cases?** Conjunctival malignant melanoma is rare with very few cases reported in literature.
- **What are the implications for future practice?** The recommended surgical approach for conjunctival

malignant melanoma is meticulous wide local excision with around 4mm free margins with adjunctive cryotherapy.

- **Follow-up?** Long-term follow up of surgically treated cases of conjunctival malignant melanoma should be done for early detection of recurrence.

Background

A population based study in Denmark calculated the incidence of conjunctival malignant melanoma to be around 0.052 cases per year per 100,000 population.¹ The majority of malignant melanomas in the eye are seen in the choroid (85%), while only about 1 in 20 are found in the conjunctiva.² Very few cases of conjunctival malignant melanoma have been reported among Indian patients.^{3,4}

Conjunctival malignant melanoma is potentially lethal. Anastassiou et al. reported a recurrence rate of 50% and tumour-related mortality of 32%.⁵ Several factors have been implicated in the recurrence of the disease, amelanotic or mixed pigmentation, deep tumour invasion and incomplete surgical excision being the most important determinants. We report a case of local recurrence of conjunctival malignant melanoma one year after excision of the primary tumour.

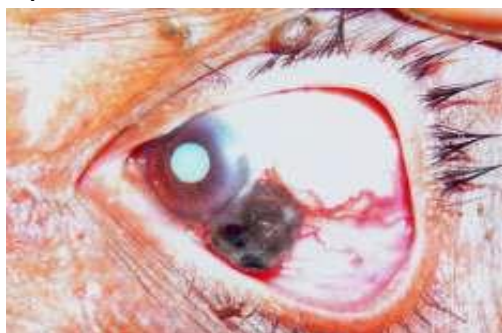Case details

A 65-year-old lady presented to the Ophthalmology Department (OPD) with complaints of a painless slowly growing dark coloured mass in her left eye of two months duration preceded by a small black coloured nodule at the same location approximately six months prior. There were no associated complaints related to central nervous system, chest or the abdomen. There was no history of any surgical treatment, ocular or otherwise.

On examination, the left eye showed a globular black coloured mass of about 8mm diameter at 3 o'clock limbus. The growth was lobulated with spots of superficial haemorrhages and covered by a thin capsule (Figure 1). The base of the growth was narrow. The surrounding conjunctiva showed few prominent vessels running up to the base of the mass. Cornea was clear without any pigmentation. Vision in the left eye was perception of light

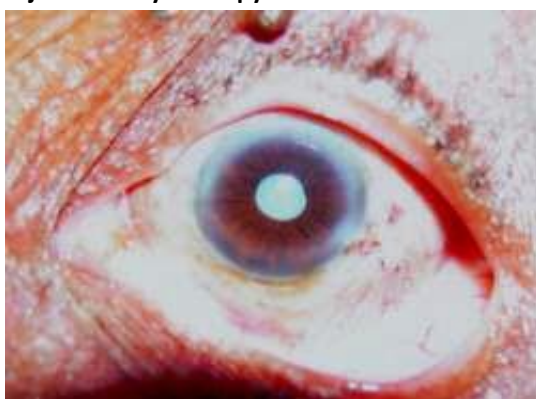with accurate projection of rays. Anterior chamber was shallow with the presence of mature cataract. Intraocular pressure was normal on applanation tonometry. Right eye examination was normal with vision of 6/9. USG B-scan showed that the ocular coats were intact and there was no intraocular extension of the mass. MRI orbit and brain, X-ray chest and an ultrasound of the abdomen and pelvis were normal. All blood investigations were also within normal limits. CT-scan of the chest and abdomen with pelvis was within normal limits.

Figure 1: Conjunctival malignant melanoma of the left eye on initial presentation



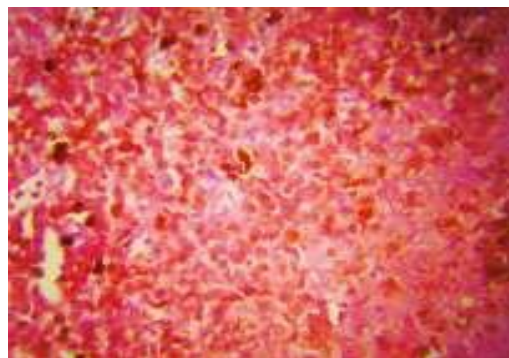
With an informed written consent, the patient presented for surgery. Wide local excision of the tumour, with a clear margin of 4mm was achieved using no touch technique followed by double freeze thaw cryotherapy of the conjunctival margins and the scleral bed. The residual conjunctival defect was closed with primary closure using a second set of instruments to avoid contaminating the field with the previous instruments. Postoperative recovery was uneventful (Figure 2). The cataract was left untreated.

Figure 2: Post operative outcome after wide local excision with adjunctive cryotherapy



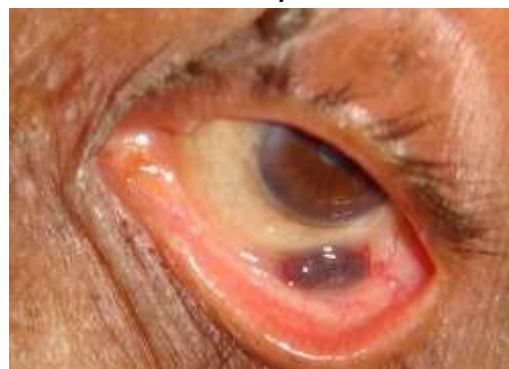Histopathology of the lesion showed sheets of polyhedral melanocytes with large hyper chromatic nuclei and clumps of coarse melanin granules in the cytoplasm (Figure 3). The excision margins of the specimen were reported as free from tumour cells.

Figure 3: Microphotograph of the histopathology slide, showing sheets of melanoma cells, HE stain, 400X



The patient came for regular follow-up over the next two months and no abnormality was noted. However, she missed the subsequent follow-up visits. After one year of surgery, the patient again reported to the OPD with complaints of a similar growth in the same eye, since 15 days prior. Examination showed a flat, dark coloured growth of 0.8 X 0.5 mm in the lower fornix of the left eye (Figure 4). No other lesions were noted anywhere in the conjunctiva. Systemic examination revealed no other positive findings. Workup for systemic and local spread including routine blood indices, examination of the preauricular and submandibular lymph nodes, MRI orbit and brain; also computed tomography of the chest, abdomen and pelvis was negative.

Figure 4: Recurrence after one year



The patient was taken up for surgery again and wide local excision similar to the primary surgery was done, using adjunctive cryo-application considering all surgical precautions. Histopathology confirmed it as malignant melanoma. A week later, she underwent an uneventful cataract surgery in the same eye with good visual result. The patient has participated in regular follow up, without any further problems, for more than two years to date.

Discussion

Conjunctival melanoma is rare, accounting for less than 2% of ocular melanomas and fewer than 1% of malignant tumours of the eye.⁶ It is typically seen in patients 40-70



years of age and most commonly occurs in the intrapalpebral region near the limbus but may occur anywhere on the bulbar and palpebral conjunctiva as well as in the caruncle.^{7,8} Literature regarding the clinical features, disease progression, treatment modalities and prognosis of conjunctival malignant melanoma is sparse, especially regarding the Indian population.

Malignant melanoma of the conjunctiva can arise in three ways: a) de novo, from apparently normal conjunctiva; b) From primary acquired melanosis (PAM); and c) from pre-existing naevi. Primary acquired melanosis (PAM) is a disease of mostly middle aged Caucasians and is a benign proliferative condition of the melanocytes that are normally present in the conjunctiva. In a study by Folberg et al., melanoma with PAM constituted 74.8% of cases and the rest (25.2%) appeared de novo.⁹ However, this did not seem to affect recurrence or eventual mortality.

Some cases like the present one, present little difficulty in clinical diagnosis. However this type of tumour has been acknowledged as a disease that follows no clinical pattern, with varied presentation. Melanomas that arise de novo are said to be more common near the limbus and have a short horizontal growth phase followed by a rapid vertical growth phase.⁹ This is what seems to have happened in the present case. Changes that can denote a malignant degeneration in a pre-existing naevus or PAM are an increase in size, change towards more nodular form, increased vascularity, and fixation to underlying tissue.

Currently the technique recommended for the treatment of small localised tumours is removal of the main mass with wide surgical excision (clear margin of 4mm), alcohol application, and supplemental cryotherapy.¹⁰ Localised alcohol corneal epithectomy is advised in the case of a limbal tumour invading cornea. In all cases a "no touch" technique is used and direct manipulation of the tumour is avoided. Orbital exenteration, which was once considered the safest modality, is now reserved for cases with extensive orbital involvement and widespread local cancerous melanosis which is otherwise difficult to excise. Distant metastasis carries poor prognosis for life, and palliative treatment is the only option left.

The tumour is well known for local recurrence as well as distant metastasis. Spread occurs via lymphatics as well as the blood stream. Various studies of conjunctival melanoma describe 5-year survival rate between 74–93% and 10-year survival rates between 41–87%.^{7,8} Local recurrence of conjunctival melanoma has been reported in 56–65% of patients. About half of them experienced more than one

recurrence.⁷ The mean interval between the first treatment and the first recurrence was 2.5 years.⁷ A higher rate of recurrence is seen in patients treated by surgical excision alone than those receiving adjuvant treatment as well. Patients with multifocal disease, usually originating in PAM with atypia are more likely to develop recurrences than patients with one tumour. Other risk factors for recurrence are location of the melanoma in a site other than the limbus, and the involvement of surgical margins. Local recurrences are managed by the same methods used for the primary melanoma.

This case highlights the importance of meticulous surgical technique in the excision of conjunctival malignant melanoma. If the workup for systemic disease is negative, then surgery for definitive local control should be carefully planned and executed with wide local excision of around 4mm clinically normal conjunctival margins and histopathologically tumour free margins along with adjunctive cryotherapy. Long term follow up is a must for early detection of recurrence.

References

1. Norregaard JC, Gerner N, Jensen OA, Prause JU. Malignant melanoma of the conjunctiva: Occurrence and survival following surgery and radiotherapy in a Danish population. *Graefes Arch Clin Exp Ophthalmol.* 1996;234(9):569-72.
2. Jay B. Malignant melanoma of the orbit in a case of oculodermal melanosis. (Naevus of Ota). *Br J Ophthalmol.* 1965;49:359-363.
3. Grover AK, Rastogi A, Chaturvedi KU, Sota LD, Gupta AK. Malignant melanoma of the conjunctiva. *Indian J Ophthalmol.* 1993;41:26-9.
4. Betharia SM, Vashist S, Kalra BR. Malignant melanoma of conjunctiva following surgical excision of naevus. *Indian J Ophthalmol.* 1985;33:259-61.
5. Anastassiou G, Heiligenhaus A, Bechrakis N, Bader E, Bornfeld N, Steuhl KP. Prognostic value of clinical and histopathological parameters in conjunctival melanomas: A retrospective study. *Br J Ophthalmol.* 2002;86:163-67.
6. Scotto J, Fraumeni JF Jr., Lee JA. Melanomas of the eye and other noncutaneous sites: Epidemiologic aspects. *J Natl Cancer Inst.* 1976;56(3):489-91.
7. Shields CL, Shields JA, Gündüz K, Cater J, Mercado GV, Gross N. Conjunctival melanoma: risk factors for recurrence, exenteration, metastasis and death in 150 consecutive patients. *Arch Ophthalmol.* 2000;118:1497-507.
8. Paridaens AD, Minassian DC, McCartney AC, Hungerford JL. Prognostic factors in primary



malignant melanoma of the conjunctiva: A clinicopathological study of 256 cases. *Br J Ophthalmol.* 1994;78(4):252-9.

9. Jakobiec FA, Folberg R, Iwamoto T. Clinicopathologic characteristics of premalignant and malignant melanocytic lesions of the conjunctiva. *Ophthalmology.* 1989;96(2):147-66.
10. Shields JA, Shields CL, De Potter P. Surgical approach to conjunctival tumours. The 1994 Lynn B McMahan Lecture. *Arch Ophthalmol.* 1997;115:808-15.

ACKNOWLEDGEMENTS

We express our sincere gratitude to Dr. Ravindra Karle, Professor, Department of Pathology, Pravara Institute of Medical Sciences, Loni for his cooperation and support for the histopathology diagnosis and pictures.

PEER REVIEW

Not commissioned. Externally peer reviewed.

CONFLICTS OF INTEREST

The authors declare that they have no competing interests.

PATIENT CONSENT

The authors, Somen Misra, Neeta Misra, Pratik Gogri, Venugopal Reddy and Akshay Bhandari declare that:

1. They have obtained written, informed consent for the publication of the details relating to the patient(s) in this report.
2. All possible steps have been taken to safeguard the identity of the patient(s).
3. This submission is compliant with the requirements of local research ethics committees.