



# Enterococcus faecium related emphysematous cystitis and bladder rupture

Stalin Viswanathan<sup>1</sup>, Rangarajan Pakshi Rajan<sup>2</sup>, Nayyar Iqbal<sup>2</sup>, Jayaprakash Subramani<sup>2</sup>, Vivekanandan Muthu<sup>1</sup>

1. Indira Gandhi Medical College, Pondicherry

2. Pondicherry Institute of Medical Sciences, Pondicherry

## CASE REPORT

Please cite this paper as: Viswanathan S, Rajan RP, Iqbal N, Subramani J, Muthu V. Enterococcus faecium related emphysematous cystitis and bladder rupture. AMJ 2012, 5, 11, 581-584. <http://doi.org/10.21767/AMJ.2012.1416>

### Corresponding Author:

Name: Stalin Viswanathan

Address: Department of General Medicine, Indira Gandhi Medical College, Pondicherry-605009

Email: [stalinviswanathan@ymail.com](mailto:stalinviswanathan@ymail.com)

## Abstract

We describe a 32-year-old lady who was admitted with a urinary tract infection following vacuum-assisted delivery. She was diagnosed with *Enterococcus faecium* related emphysematous cystitis, bladder gangrene and rupture necessitating emergency laparotomy and partial cystectomy. She had a repeat laparotomy nine days later due to continuing bladder necrosis on cystoscopy. The patient stayed in hospital for over two months due to complications including hospital acquired Klebsiella pneumonia, adult respiratory distress syndrome and malnutrition. Discharge occurred one week after an ileal conduit and ileostomy were performed.

### Key Words

Emphysematous cystitis, bladder rupture, gangrenous cystitis

## Implications for Practice

**1. What is known about such cases?** Emphysematous cystitis is extremely rare with less than 250 cases reported. Only six cases of infectious rupture bladder described.

**2. What is the key finding reported in this case report?** This patient was immunocompetent but had a prolonged labour. This is the first known case of *Enterobacter faecium* causing bladder rupture to be reported. It is also the first case

reported in English literature of bacterial bladder rupture in which the patient survived.

### 3. What are the implications for future practice?

Rapid institution of medical therapy may not prevent rupture in immunocompetent and non-diabetic patients. Early and aggressive multi-specialty (surgery, gynaecology, and urology) intervention may be necessary in such patients. Prolonged antibiotics and supportive therapy is essential.

## Background

Though Keyes first described emphysematous cystitis (EC) in 1882,<sup>1</sup> pneumaturia, a symptom of emphysematous cystitis,<sup>2</sup> was reported way back in 1671.<sup>3</sup> EC refers to the presence of air within the bladder wall as well as within the lumen.<sup>3</sup> Two-thirds of patients affected are women, and the median age of patients is 66 years.<sup>4</sup> Risk factors include conditions resulting in immunocompromised states such as diabetes, renal infarction and systemic lupus, and drugs which have effects on the immune system such as corticosteroids, cyclophosphamide and those taken by transplant recipients.<sup>2</sup> Bladder rupture following EC has been reported in only six instances,<sup>5-7</sup> four of them following candida infections.<sup>8,9</sup> We report a 38-year-old woman with bladder gangrene, emphysematous cystitis and bladder rupture causing peritonitis that was treated with antibiotics, surgical drainage and reconstruction.

## Case details

This 32-year-old [gravida 3, para1] presented five days after a vacuum-assisted vaginal delivery, with fever, loose stools, abdominal pain and decreased urine output of two days' duration. Although her second stage of labour had lasted 40 minutes, she had delivered approximately 20 hours after her contractions first started. Examination revealed temperature 100°F, tachycardia 120/min, tachypnoea 36/min, blood pressure 100/76mmHg, bilateral fine basal crackles, distended and tender lower abdomen. There was passage of foul smelling 'muddy' urine (Figure 1a) following urethral catheterisation. The lady was diagnosed with urosepsis and was admitted for administration of

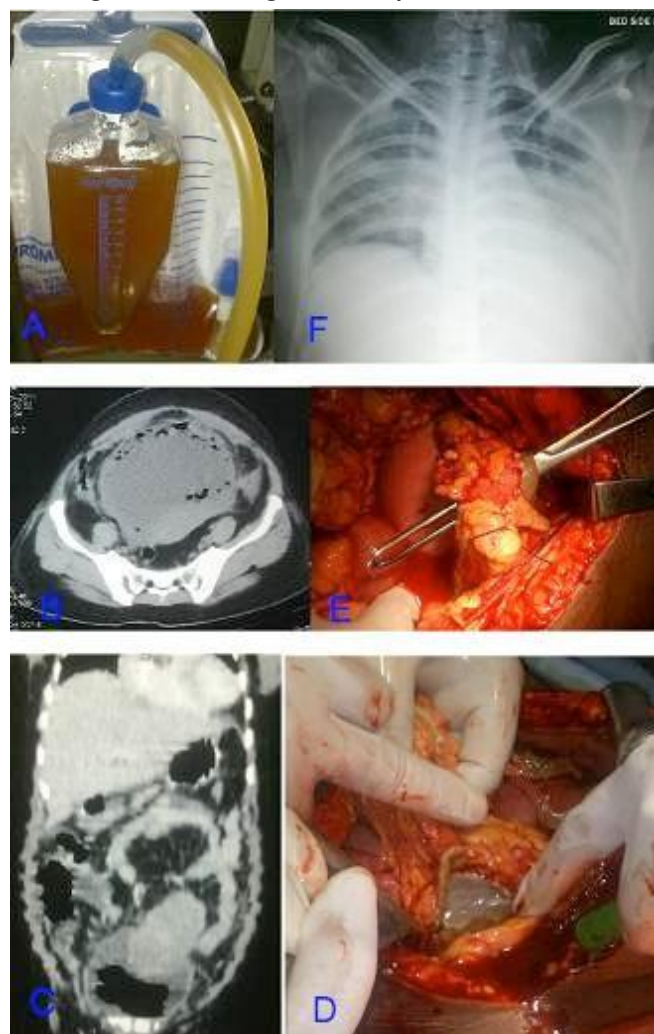
intravenous ceftazidime and amikacin. Results of her blood tests included, haemoglobin 10g%, total leukocyte counts  $7.4 \times 10^9/L$  with 80% neutrophilia, platelets  $190 \times 10^9/L$ , urea 39.2mmol/L [2.5-7.0], creatinine 140 $\mu$ mol/L, bilirubin 91.8 $\mu$ mol/L [5.1-22] with direct bilirubin 68  $\mu$ mol/L [3.4-15.222], aspartate aminotransferase 1.95 $\mu$ kat/L [0.20-0.65], alanine aminotransferase 0.90  $\mu$ kat/L [0.12-0.70] and alkaline phosphatase 5.25  $\mu$ kat/L [0.5-1.6]. Urine examination showed 4+ albumin, 40-50RBCs/hpf and pus cells 20-25/hpf. CT abdomen revealed emphysematous cystitis (Figure 1b). Surgery consult was sought and she was admitted into intensive care; a jugular central venous line was placed and she was monitored for worsening of symptoms. Due to increasing abdominal distension and absent bowel sounds, repeat CT was performed the next day and she was taken up for an emergency laparotomy due to presence of free peritoneal air (Figure 1c). During surgery it was noted that the upper 2/3rds of the bladder was gangrenous (Figure 1d). Perforation in the dome of diaphragm, necrotic bladder mucosa, 1.5 litres free fluid in peritoneum, and minimal pus in pelvis and paracolic gutters were also observed (Figure 1e). Cultures from admission revealed urinary *Enterococcus faecium* and *Acinetobacter baumannii* bacteremia. Meropenem [1gQ8h] and ampicillin [500mgq6h] was initiated on the fourth day. On day 9, due to persistent urinary leak and continuing bladder gangrene on cystoscopy, repeat laparotomy was performed revealing free fluid and a leak from one site in the bladder. Bilateral cutaneous ureterostomy was performed. From day 13 onwards, the lady was managed with oral ampicillin and trimethoprim for a total duration of 21 days. She remained in hospital for the next two months due to hospital-acquired *Klebsiella* related pneumonia and ARDS (Figure 1f) and weight loss. Ileal conduit with ileostomy was performed on the 70th day after admission and she was discharged one week later. Complete cystectomy was not done due to severe fibrosis. Two weeks following discharge, she was readmitted for a surgical site infection that was controlled with amikacin and ciprofloxacin.

## Discussion

Gas reaches the urinary tract by infection, trauma, fistula and instrumentation.<sup>2</sup> In infections, hyperglycaemia and impaired tissue perfusion contribute towards development of EC. Elevated urinary albumin [in non-diabetics] and glucose fermentation cause gas formation.<sup>4</sup> Also, carbon dioxide producing bacteria metabolise the sugar in urine and in the bladder parietal wall. In EC, gas can form in the scrotum, prostate and periurethral tissues as well. Without immune compromise, known risk factors include neurogenic bladder, bladder obstruction and enterovesical fistula,<sup>9</sup> chronic urinary tract infections, indwelling catheters,<sup>3</sup>

endoscopic urologic procedures, colonic surgery, cystic fibrosis and ulcerative colitis, none of which were seen in our patient. Malignancies are seen in 8 to 16% of EC.<sup>4</sup> Half of the reported cases of EC have been described in the last two decades due to better radiological investigations. Fifty per cent of EC cases occur in diabetics. In descending order, *E. coli*, *Klebsiella pneumoniae*, *Enterobacter aerogenes*, *Clostridium perfringens*, *Candida albicans* and *Candida tropicalis* are the five most common organisms<sup>2,3</sup> that cause EC.

**Figure 1: (a) Urobag containing foul smelling 'muddy' urine; (b) CT abdomen on day 1 revealing air in the bladder suggestive of emphysematous cystitis; (c) CT abdomen on day 2 showing increased intravesical air and presence of free peritoneal air and sub-diaphragmatic air; (d) Intraop finding on day 2, showing bladder necrosis in the dome of the bladder; (e) Intraop finding also on day 2, showing spontaneous bladder wall rupture; (f) CXR showing ARDS following *Klebsiella pneumoniae***



Seven per cent of cases of EC are asymptomatic while classic symptoms of urinary tract infections are seen in about 50%.<sup>4</sup> Symptoms include urgency, frequency, nocturia, dysuria, gross haematuria, supra pubic pain,



pyuria, nausea and vomiting. Abdominal pain is the most common symptom in immunocompetent people.<sup>10</sup> Pyuria, haematuria, glycosuria and acetonuria are seen on urinalysis. Complications of emphysematous cystitis include ureteric and renal parenchymal extension, rupture of bladder and overwhelming sepsis.<sup>2</sup> Diarrhoea and acute abdomen are typical presentations and this was seen in our patient. Diagnosis is mostly radiological, due to the non-specific nature of symptoms.<sup>4</sup> Diagnosis is made by plain radiography, ultrasonography, abdominal computed tomography [CT] and cystourethroscopy.<sup>3</sup> CT is used for delineating severity and extent and to rule out fistulae and malignancies.<sup>2,3</sup> Broad-spectrum antibiotics, aggressive glycaemic control and surgical interventions such as cystectomy can be lifesaving.<sup>4</sup> Bladder necrosis, gangrene and urosepsis contribute to mortality.<sup>4</sup> Bladder gangrene has been reported in 240 instances worldwide,<sup>8</sup> but it is not known whether they were all associated with emphysematous cystitis. Ten per cent of patients with the diagnosis of emphysematous cystitis die.<sup>1</sup> Ten to 15% need a laparotomy, as in our patient.<sup>4</sup>

We believe, in our patient, prolonged labour [>20 hours] may have caused neuropraxia of pelvic nerves, hypotonic bladder and over distension leading to primary gangrenous cystitis and gas formation. Our patient was catheterised at the second stage of labour. Other details were not available.

Bladder rupture can be caused by urinary obstruction, bladder obstruction, bladder calculi, pelvic radiation and infections.<sup>8</sup> Four cases of candida EC without rupture have been described.<sup>9</sup> Patient reports of those who have experienced bladder rupture following candida infection report that all survived following laparotomy, intravenous fluconazole and on some occasions amphotericin.<sup>7</sup> The candida species included *C tropicalis*, *C glabrata* and *C albicans*. Two cases of *E coli* related EC with subsequent bladder rupture have been described<sup>7,8</sup> with both patients dying – one because of lack of consent to surgically intervene in a 81-year-old lady with lung malignancy and the other in a 53-year-old lady with chronic kidney disease and Parkinsonism due to associated MRSA sepsis. The only other case of bacterial EC causing bladder rupture in a 69-year-old diabetic with neurogenic bladder has been reported in Spanish literature.<sup>6</sup>

Previous reports of survival in bacterial emphysematous cystitis with bladder rupture have not been described in English language literature. Also *Enterococcus faecium* related EC and subsequent bladder rupture (in an immunocompetent patient) has not been hitherto reported. Clinicians should expect such complications (even in an

immunocompetent patient) with prolonged labour and urinary infection symptoms so that significant morbidity can be prevented. Close cooperation with surgical and urological teams enabled us to coordinate treatment of this patient. Care towards adequate nutrition (parenteral nutrition not given due to unaffordability) and avoidance of hospital acquired pneumonia as in our case care would have remarkably shortened the patient's hospital stay. Mortality in this case was prevented with prolonged antibiotics use and aggressive surgical measures.

---

## References

1. Leclercq P, Hanssen M, Borgoons P, Bruyere PJ, Lancellotti P. Emphysematous cystitis. CMAJ. 2008 Mar 25;178(7):836.
2. Bobba RK, Arsura EL, Sarna PS, Sawh AK. Emphysematous cystitis: an unusual disease of the genito-urinary system suspected on imaging. Ann Clin Microbiol Antimicrob. 2004 Oct 5;3:20.
3. Thomas AA, Lane BR, Thomas AZ, Remer EM, Campbell SC, Shoskes DA. Emphysematous cystitis: a review of 135 cases. BJU Int. 2007 Jul;100(1):17-20.
4. De Baets K, Baert J, Coene L, Claessens M, Hente R, Taily G. Emphysematous Cystitis: Report of an atypical case. Case Rep Urol. 2011;2011:280426.
5. Hu SY, Tsan YT. Emphysematous cystitis with perforation in a non-diabetic patient. Postgrad Med J. 2009 Jun;85(1004):292.
6. Bañón Pérez VJ, García Hernández JA, Valdelvira Nadal P, Nicolás Torralba JA, Server Pastor G, Coves R, et al. [Intraperitoneal bladder perforation in emphysematous cystitis]. [Article in Spanish]. Actas Urol Esp. 2000 Jun;24(6):501-3.
7. Shin HI, Kim HH, Park CH. Emphysematous cystitis with bladder rupture. Keimyung Medical Journal 2011;30:98-102.
8. Hinev A, Anakievski D, Krasnaliev I. Gangrenous cystitis: report of a case and review of the literature. Int J Urol 2010;85:479-81.
9. Kim KS, Moon SY, Yoon JU, Lee SS, Cho JS, Chung DR. Emphysematous cystitis with bladder rupture by *Candida albicans*. J Infect Chemother. 2005 Apr;11(2):84-8.
10. Kelesidis T, Osman S, Tsiodras S. Emphysematous cystitis in the absence of known risk factors: an unusual clinical entity. South Med J. 2009 Sep;102(9):942-6.

## ACKNOWLEDGEMENTS

None

## PEER REVIEW

Not commissioned. Externally peer reviewed.



**CONFLICTS OF INTEREST**

The authors declare that they have no competing interests.

**FUNDING**

None

**PATIENT CONSENT**

The authors, Viswanathan S, Rajan RP, Iqbal N, Subramani J, Muthu V, declare that:

1. They have obtained written, informed consent for the publication of the details relating to the patient(s) in this report.
2. All possible steps have been taken to safeguard the identity of the patient(s).
3. This submission is compliant with the requirements of local research ethics committees.