



Antiretroviral therapy associated mastopathy

Smita Sankaye¹, Sushil Kachewar²

1 Senior Resident in Pathology, Rural Medical College, PIMS, Loni, India

2. Faculty in Radio-diagnosis, Rural Medical College, PIMS, Loni, India

CASE REPORT

Please cite this paper as: Sankaye SB, Kachewar SG. Antiretroviral therapy associated mastopathy. AMJ 2012, 5, 8, 418-420. <http://doi.org/10.21767/AMJ.2012.1248>

Corresponding Author:

Dr Smita B Sankaye

Rural Medical College, PIMS (DU), Pravara Medical Trust, Loni, Maharashtra, India, PIN 413736

Email: smitasankaye@gmail.com

Abstract

Reports about bilateral breast enlargement in patients on antiretroviral therapy are rare. It forms a constituent of the human immunodeficiency virus lipodystrophy syndrome. Often clinical suspicion followed by appropriate imaging evaluation is confirmative.

A case of antiretroviral therapy associated mastopathy is therefore presented here so that increased awareness would obviate the need of mastectomy in such cases. We also emphasise the role of adequate counselling in this scenario in alleviating patients' anxiety.

Key Words: Breast cancer; breast mass; mastopathy, antiretroviral therapy mastopathy; lipodystrophy.

Implications for Practice

1. Antiretroviral therapy associated mastopathy can clinically present as distressing and socially disturbing mastomegaly.
 2. A proper history, laboratory and imaging work-up can establish the diagnosis in most cases.
 3. Proper counselling, changing the medicines or reduction mammoplasty is effective in managing such cases.
-

With widespread availability and subsequent use of antiretroviral therapy, more and more cases of breast enlargement are being reported globally in males as well as females who are human immunodeficiency virus (HIV) infected patients.^{1,2}

Important entities that can lead to this mastomegaly are gynaecomastia (proliferation of ducts and periductal stroma), lipomastia (adipose-tissue deposition), and malignancy. We describe a case of a 28-year-old HIV-infected widow, currently on antiretroviral therapy for the past three years and who presented with disturbing bilateral breast enlargement.

Case report

A 28-year-old lady had been receiving antiretroviral therapy for the past three years after being infected from her husband who passed away two years ago. She had no other illnesses. Her family history was unremarkable. Over the past eight months she has been noticing rapid bilateral breast enlargement such that she had to significantly increase the size of her thoracic undergarments (by = /> 4 bra sizes) within this duration. There was neither any history of trauma nor was she lactating. No secretions were being produced or expressed from either of the breasts.

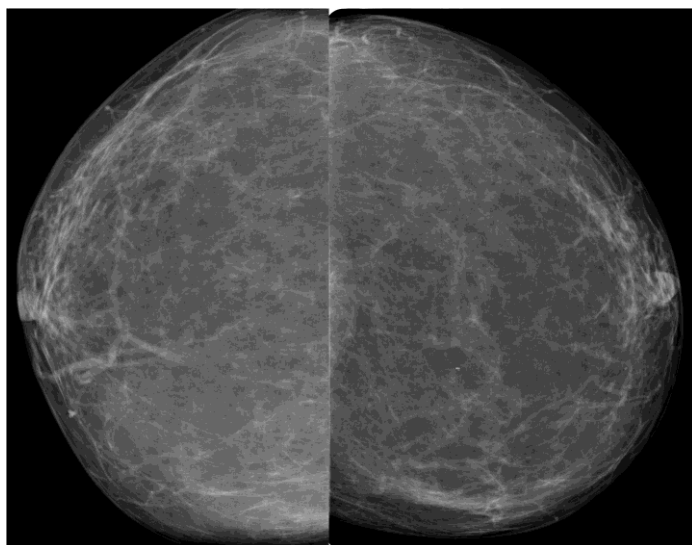
On physical examination both breasts were smooth, firm and freely mobile over the underlying thoracic musculature, and devoid of any palpable mass lesions. There was no nipple discharge, skin abnormalities or any axillary lymphadenopathy (Figure 1).

X-ray mammography revealed enlargement of both breasts without any focal obvious mass. Parenchymal opacity was indicative of predominant fatty composition. There were no architectural distortions, abnormal micro calcifications or masses. Overlying skin was neither thickened nor was the nipple puckered (Figure 2).

Figure 1: Photograph of a 28-year-old lady on antiretroviral therapy for the past three years now showing enlarged breasts

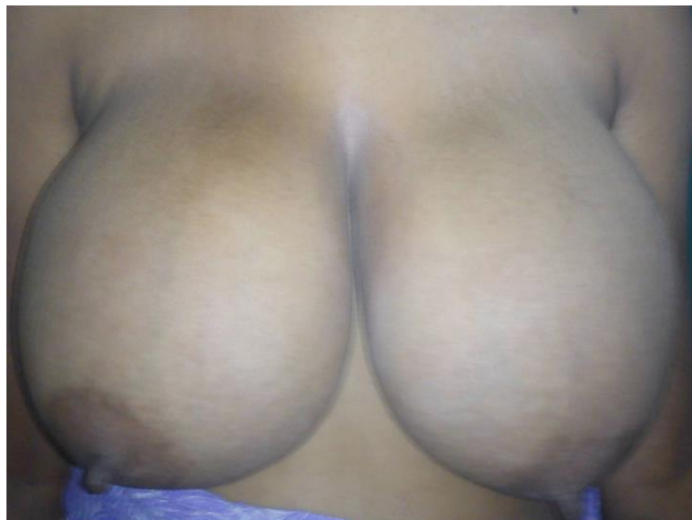

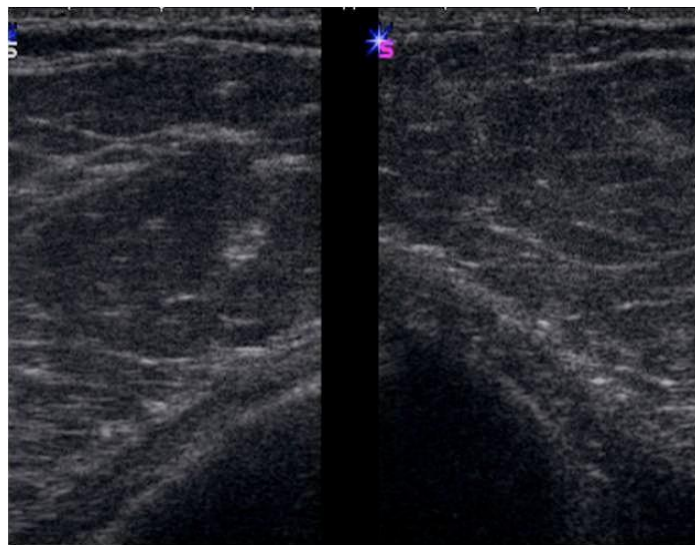
Figure 2: Bilateral cranio-caudal mammograms showing prominent fat density tissue as the cause of mastomegaly. No other obvious mass or nodule is seen



Sonomammogram of the breasts showed mastomegaly due to fatty tissue. No obvious mass, nodule or calcification was seen (Figure 3). Breast MRI was not performed due to its local unavailability and lack of affordability by the patient.

A final diagnosis of antiretroviral therapy associated mastopathy was thus made based on clinico-radiological findings. The patient was managed by thorough psychological counselling. She was also informed about the option of reduction mammoplasty, which she declined. A written consent was taken from the patient for counselling.

Figure 3: Sonomammogram of both breasts showing predominant fatty parenchymal pattern as the cause of mastomegaly



Discussion

Mastomegaly has been reported in antiretroviral therapy-associated HIV lipodystrophy syndrome in males as well as females.³

This side effect of multidrug antiretroviral regimes in HIV-infected patients occurs due to changes in fat metabolism and distribution. In this pattern of fat redistribution, on one side there is progressive enlargement of the breast and abdomen while on the other side there is fat loss over the thighs. It is reported in 10% of HIV-infected women treated with combined antiretroviral therapy.⁴

Immunology studies showed that in vitro production of TNF alpha and IL-10 was lower and IL-12 production higher in them, though it is not clear whether it is a cause or an effect of fat redistribution.⁴ In the same study 50% of the patients treated with triple therapy had lipodystrophy at one year follow-up, that manifested as weight loss, face-wasting and hyperglycaemia.

Of the multiple antiretroviral drugs available; four protease inhibitors (saquinavir, indinavir, nelfinavir and ritonavir) are associated with the development of abnormal body fat.⁵ The pathophysiology for these events remains unclear and a specific drug or drug class linkage is still uncertain.

Following three types of fat distribution have been reported⁶ either separately or in combination in HIV-infected patients who are undergoing active antiretroviral therapy:



1. Fat depletion or 'lipoatrophy' syndrome which might be related to the use of stavudine;
2. Mixed syndrome or fat redistribution syndrome related to an unusual side-product of effective virus control; and
3. Subcutaneous adiposity syndrome reflecting increase in caloric intake.

In those who were affected, changing the treatment was associated with limb fat-sparing and fat restoration compared with continued treatment with stavudine and/or protease inhibitor.⁷

Treatment options for patients with distress caused by mastomegaly include changing the medicines to halt or regress this lipodystrophy, or sometimes reduction mammoplasty may even be needed.⁸

In addition to the medical and surgical aspects, we believe that counselling plays a major role in this scenario. This is because all the different antiretroviral medications may not be available at the same time and cosmetic surgeries are either unaffordable or are not covered under insurance for the common lot. Hence proper explanation may alleviate anxiety in patients so that they come to terms with the new body image and accept the change and prefer not to 'go under the knife', as was seen in the patient reported here. They need to be ensured time and again that this mastomegaly is not a malignancy so that their hopes are sustained and quality of life improved.

References

1. Evans DL, Pantanowitz L, Dezube BJ, Aboulafia DM. Breast enlargement in 13 men who were seropositive for human immunodeficiency virus. *Clin Infect Dis.* 2002; 35(9):1113-1119.
2. Galli M, Ridolfo AL, Adorni F, Cappelletti A, Morelli P, Massetto B et al. Correlates of risk of adipose tissue alterations and their modifications over time in HIV-1-infected women treated with antiretroviral therapy. *Antivir Ther.* 2003; 8(4):347-354.
3. Deonarain J, Ramdial PK, Singh B. Bilateral lipomastia in men: a side effect of highly active antiretroviral therapy. *Int J Surg Pathol.* 2008; 16(2):171-175.
4. Norbiato G, Trifirò G, Galli M, Gervasoni C, Clerici M. Fat redistribution in HIV-infected patients. A new hormonal-immune disorder? *Ann N Y Acad Sci.* 2000; 917:951-955.
5. Mann M, Piazza-Hepp T, Koller E, Struble K, Murray J. Unusual distributions of body fat in AIDS patients: a review of adverse events reported to the Food and Drug Administration. *AIDS Patient Care STDS.* 1999; 13(5):287-295.
6. Saint-Marc T, Partisani M, Poizot-Martin I, Rouviere O, Bruno F, Avellaneda R et al. Fat distribution evaluated by

computed tomography and metabolic abnormalities in patients undergoing antiretroviral therapy: preliminary results of the LIPOCO study. *AIDS.* 2000; 14(1):37-49.

7. John M, McKinnon EJ, James IR, Nolan DA, Herrmann SE, Moore CB et al. Randomized, controlled, 48-week study of switching stavudine and/or protease inhibitors to combivir/abacavir to prevent or reverse lipoatrophy in HIV-infected patients. *J Acquir Immune Defic Syndr Hum Retrovirol.* 2003; 33(1):29-33.

8. Tarallo M, Cigna E, Fino P, Lo Torto F, Scuderi N. Macromastia surgical therapy. *Ann Ital Chir.* 2011; 82(3):191-195.

ACKNOWLEDGEMENTS

None

PEER REVIEW

Not commissioned. Externally peer reviewed.

CONFLICTS OF INTEREST

The authors declare that they have no competing interests

FUNDING

None

PATIENT CONSENT

The authors, Sankaye SB, Kachewar SG, declare that:

1. They have obtained written, informed consent for the publication of the details relating to the patient(s) in this report.
2. All possible steps have been taken to safeguard the identity of the patient(s).
3. This submission is compliant with the requirements of local research ethics committees.