

Zero % long term biliary stricture in microscopic reconstruction (MBR) of Hepatico-Jejunal Biliary Roux en Y choice of biliary drainage of adult liver transplant

Ali Ghannam¹, Tsan-Shiun Lin², and Chao-Long Chen³

1. Fellow of Liver Surgery and Transplant, Consultant HPB Laparoscopic Surgery, Taiwan
2. Department of Surgery, Kaohsiung Chang Gung Memorial Hospital, Taiwan
3. Kaohsiung Chang Gung Memorial Hospital, Niao-Sung, Kaohsiung, Taiwan

RESEARCH

Please cite this paper as: Ghannam A, Lin TS, Chen CL. Zero % long term biliary stricture in microscopic reconstruction (MBR) of Hepatico-Jejunal Biliary Roux en Y choice of biliary drainage of adult liver transplant. AMJ 2019;12(3):81–89. <https://doi.org/10.21767/AMJ.2018.3569>

Corresponding Author:

Chao-Long Chen
Director, Liver Transplantation Program
Kaohsiung Chang Gung Memorial Hospital
123 Ta-Pei Road, Niao-Sung, Kaohsiung, Taiwan
Email: clchen@adm.cgmh.org.tw

ABSTRACT

Background

Routine use of (MBR) by Roux en Y in adult Orthotopic Liver Transplantation (OLT) has not been elucidated. The usual choice of enteric drainage got expected morbidities of biliary enteric anastomosis. Patients of liver transplant clinical differences are compared. Choices, current status, efficacy, application, short and long term outcome of biliary reconstruction by (MBR) roux en Y anastomosis in adult liver transplant was compared to Conventional roux en y.

Aim

The primary aim of the study is to clarify the influence to the diseased liver recipient duct to the future graft biliary drainage.

Methods

Study of consecutive liver transplant patients was retrieved. Total Number of 1234 OLT, By the End of July 2014. Group A

16 patients of Conventional Period up to 22 March, 2006. Group B 50 patients of (MBR) up to 31 JULY 2014.

Results

In group A 8/16 got short and long term complication. However, in group B only 4/50 got short term problems, with no death.

Conclusion

In Spite of the drawback of adult OLT roux en Y hepatico-jejunal anastomosis including anatomical challenges and graft position, we developed graft survival in adults liver transplant with widened application of (MBR).

There is accessible and durable intact biliary drainage choice by (MBR) hepatica enteric anastomosis for adults OLT patients that can be encouraged and advised by microscopic surgery.

Key Words

Biliary Reconstruction, microscopic technique, biliary complication, living donor liver transplant, diseased donor liver transplant, orthotopic liver transplant, Roux en Y Hepatico-Jejunostomy, extra hepatic biliary drainage, microscopic biliary reconstruction, duct to duct reconstruction

What this study adds:

1. What is known about this subject?

There is an influence to the diseased liver recipient duct to the future graft biliary drainage. The usual choice of enteric drainage got expected morbidities of biliary enteric anastomosis.

2. What new information is offered in this study?

Microscopic biliary reconstruction used in duct to duct anastomosis was successful in overcoming post OLT biliary

complication. Hepatica enteric drainage by microscopic technique got encouraging result too.

3. What are the implications for research, policy, or practice?

There is accessible and durable intact biliary drainage choice by hepatica enteric anastomosis for OLT patients that can be encouraged and advised by microscopic surgery.

Background

Original article layout includes literature review of MBR, (RY), biliary tree evaluation and operation details.

Microscopic OLT

In adults liver transplant duct to duct (D-D) is the dominant method used for biliary reconstruction (BR) as non-biliary disease is common indication in adult group.

(D-D) choledochocolostomy for biliary reconstruction is currently accepted as a standard method for adults' recipients.¹⁻⁴ The application of RY anastomosis is controversial and is limited in adults (BR) liver transplant. Liver transplantation is the only effective treatment for the end stage liver disease. Although considerable progress has been achieved and surgical techniques have been refined for liver transplant. The incidence of biliary complication remains significant.¹⁻⁴

(BR) has always been regarded as Achilles heel of liver transplant.⁵⁻⁹ This contention is particularly evident in reduced size LT, including split LT and LDLT.⁹ The (BC) Have been conspicuously ascribed to technical difficulties due to small size and multiple ducts particularly in right lobe liver graft.^{9,10} To overcome these complexities our institution has routinely employed the use of MBR since 2006.⁹

The main stay of (BR) in human liver transplantation is duct to duct anastomosis, in which the bile duct of liver graft is connected to the recipients' native bile duct. However, when there is large disparity in size between the recipient's bile duct and the donors bile ducts, surgeons tend to deviate from duct to duct, and different techniques' such as roux-en-Y hepatico jejunostomy and choledochoduodenostomy are used. Another indication for deviation from (D-D) anastomosis is diminished viability of native extra hepatic bile duct or reduced patency due to inflammation and stricture.¹¹

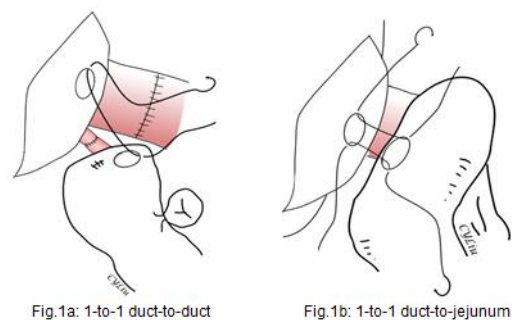
(D-D) Anastomosis has several advantages: it is simple and faster to perform without intestinal manipulation. It helps to maintain the physiological bilio enteric continuity by preserving the function of the sphincter of Oddi, it leads to

an early start of oral intake and it facilitate the management of endoscopic treatment in cases with post-operative (BC).^{1,4,12,13}

On the other hand, dehiscence of (RY) anastomosis can be associated with septic peritonitis.¹ In addition, (RY) patients is prone to ascending cholangitis; Greif et al.^{1,14} reported that biliary leakage in (RY) anastomosis was associated with a higher rate of mortality (54.5%) than leakage in D-D anastomosis (8.5%).

In our previous report about routine use of (MBR) in LDLT, showed that this technical innovation leads to decreased early anastomotic complication.^{9,15} We elucidated the feasibility and the attitude of this technique for significantly lowering the biliary complication (BC) in LDLT.⁹ Also, the early and long term result of this technique has been highlighted.⁹ We have also presented the routine (MBR) in paediatric LDLT where biliary reconstruction is through a (RY).⁵ Graft and recipient duct surgical principle in LDLT discussed in previous studies. The technique and result of the CGMH liver centre Kaohsiung is also overviewed in the previous studies. The relation of biliary complication and graft survival and quality of life is essential for overall benefit of liver transplant was a conclusion of previous centre study (Figure 1).

Figure 1: Hepaticojejunostomy in OLT



Advantages:

1. Minimal graft duct dissection and effective recipient biliary drainage.
2. Technical demands of hepaticojejunostomy can be trained.
3. Graft biliary anastomosis survival.
4. The conduit length sufficient blood supply of jejunal loop (long drainage tube). Overcome the possibility of angulation (sharp angle placement) crane neck deformity of expected graft growth and disparity of

the duct size and number between graft and recipient.

5. Treat and overcome cases of sensitive biliary tree to ischemia (duct ischemia time), infection, stricture and leak.

Disadvantages (Limited application):

1. Time consuming.
2. Intestinal manipulation.
3. Extra jejunojejunostomy.
4. Anastomosis leak in (RY) can be focal (biloma) or fatal generalized as it is associated with septic peritonitis.
5. Break in the physiological bilioenteric continuity, with loss of function of sphincter of ODDI:
 - This leads to delayed oral feeding.
 - Difficult endoscopic or percutaneous intervention in post-operative complication.

It was used in:

Choleducal cyst
Autoimmune liver disease
PBC with extra hepatic biliary tree involvement
Poly cystic liver disease (displaced recipient CBD)

Patients with chronic liver disease have high possibility of biliary tree disease like:

CBD Stone or Sludge
Dilated CHD
Cholangitis – infection
Previous intervention and stenting
Resection of diseased extra biliary or hepatic tree. (Hilar biliary stricture post lap cholecystectomy)
UN available duct (post whipped procedure) or diseased duct

Other factor affects the biliary tree:

Child's stage (ascites+portal hypertension+chronic alcoholic pancreatitis+post splenectomy)
Expected vascular inflow (Hepatic artery or Portal vein) events. Atherosclerosis, fragile vessel or poor flow
Redo hepatic artery anastomosis (Hepatic artery twist or kink)
Revision of D-D (Rejection, re-transplant, recurrence of liver failure)
Patient age factor (medical co morbidity)
Intraoperative iatrogenic recipient bile duct burn or cut. (Avulsion or Traction)

Biliary tree evaluation in OLT:

At our centre, the choice for (RY) for patients undergoing (BR) is based on:¹¹

- 1- Preoperative imaging of biliary tract (MRCP or ERCP).

Graft lobe duct numbers and size.

- 2- Intraoperative inspection, assessment of patency of the native bile duct (clinical evaluation-fragile bile duct, IOC, probing or choledocho scope).

Preoperative planning in liver transplant

- Wide (IDD): distance more than the total addition of the ducts diameters of the graft duct orifices especially in right lobe grafts.
- Relation of graft hepatic artery (interposition).
- Cases not fit for ductoplasty.
- The needs for even distribution of the sutures.
- Combined stitching of the posterior and anterior wall of the biliary tree.
- Tension free anastomosis.
- Adjustment of numbers of suture stitches.
- Inadequate apposition.
- The need for even distribution of tension along the suture line.
- Plan for expected and possible bile duct complication post-transplant.

Complication of Biliary Anastomosis (BC)

Early biliary complication occurring within 12 months of transplant.^{5,16}

Late biliary complications were defined as complication occurring after 12 months up to two years.

High biliary complication in adult LDLT affects graft survival and quality of life. More complication with the right lobe graft due to multiple orifices of the duct and artery compared with the constant duct of left lobe graft.

Patient survival is defined as the time interval between the date of OLT and the patient death. Graft survival was defined as the time between OLT and re-transplantation or death.¹¹ (BC) including leak and stricture are commonly managed with non-operative measures, including radiological interventions such as endoscopic treatment and percutaneous Trans hepatic cholangio drainage (PTCD).

1. Anastomotic biliary stricture

Any abnormality that needed treatment is counted as biliary stricture.¹ Cholangitis is defined as the presence of fever, elevated bile duct enzymes and elevated inflammatory parameters.¹ Anastomotic stricture is caused by (surgical) technical or anatomical and (non-surgical) ischemic{ hepatic artery thrombosis (HAT)} or immunological factors (CMV infection, rejection, preservation solution injury, ischemia time, bacterial colonization). Stricture is defined as

intrahepatic duct dilatation more than 3mm in the presence of a notable extra hepatic biliary narrowing and symptoms or abnormal liver function. From our previous publication we defined, perioperative biliary complication, as either bile leak or stricture occurring within 90 days (3 months) of the surgery. Long outcome up to two years is related to non-surgical causes.

2. Bile leak

Early perioperative bile leaks not from the cut surface or aberrant duct. Defined as the presence of bile material in the closed suction drain that persisted beyond one week after transplantation or the presence of biloma within the area of anastomosis. Doppler ultrasound is performed regularly. Ultrasound initially is used to ascertain significant fluid collections and biliary dilatation. Patients with ultrasound findings suggestive of biliary complication are further evaluated by computed tomography or magnetic resonance imaging. Percutaneous Trans hepatic cholangiography is performed if required in cases of biliary complication.⁵

3. Stone at the anastomosis

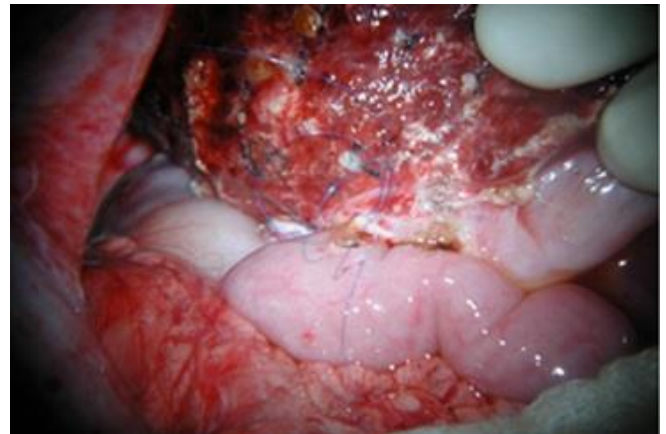Operation (superiority of MBR)

Conventional Biliary reconstruction is done with interrupted 6-0 PDS suture with or without loupes. (x2.5).¹⁶ Stents sometimes are used, an external biliary stent tube (3- or 4 fr polyethylene tube) is passed through the jejunal wall, choledochal wall, stump of the cystic duct or other stump of hepatic duct that is not used for the anastomosis and then it is passed outside the abdomen. Tension during the anastomosis procedure is avoided. All suture knots are tied extraluminally. (Text book) In Roux en y, jejunal limb is anastomosed to graft hepatic duct in an end to side fashion. Trans anastomotic tube 4fr is routinely exteriorized with the WITZEL maneuver.¹

In MBR technique, all reconstructions are performed under an operating microscope (Carl Zeiss, Jena, Germany) with magnification of 10-20 X. The technique of ductoplasty for multiple small duct openings is similar to the conventional method but under microscope. Our techniques of donor graft hepatectomy, recipient total hepatectomy, and graft implantation in paediatric LDLT are described previously.^{5,17} Our technique of conventional biliary reconstruction and (MBR) are also described in previous publication^{5,16} The anastomosis is performed with 6-0 prolene sutures (Johnson and Johnson, Somerville, NJ) on a 6-0 gauge cardiovascular-point needle. Interrupted suture technique is used for posterior wall anastomosis first. Anterior wall sutured by continuous suture and interrupted tie technique

or the (combined micro vascular anastomosis technique).^{5,18} All suture knots are tied extra luminal. Modification of the MBR technique is discussed in the previous report and biliary reconstruction classification according to number of graft duct opening and when there is two or more graft. The manner in which these ducts were reconstructed (with or without ductoplasty) and type of conduits used for reconstructing the biliary tree is also discussed in detail. The conduit used could be either recipient (right, left or common) hepatic duct or the jejuna loop. The size of the duct openings and IDD (Intra Ductal Diameter) duct opening are measured with calliper. The size of the opening created in jejunal roux n Y limb is always patterned to that of hepatic ducts in the graft (Figure 2).

Figure 2: Microscopic photo of hepatica enteric anastomosis



Method

Strength and limitation

It is a single centre study (control, retrospective and cohort study). CGMH, KAOHSIUNG, LIVER TRANSPLANT CENTRE in south Taiwan is affiliated referral centre. A pioneer centre in microscopic liver surgery. The study protocol received a prior approval from an appropriate institutional review committee. Eligible patients hard and soft medical files were reviewed and data collected. General limitations exclude duct to duct biliary drainage. Long term means two years follow up for stricture. Patient's demography, post-operative complication, donor and surgical variables were assessed.

OLT liver transplant centre CGMH Kaohsiung

At Kaohsiung, Chang Gung Memorial Hospital, Taiwan. We begin MBR after 22-3-2006; cut end the period of conventional era. All (MBR) are performed by a single micro surgeon using microsurgical technique. Within the era of conventional (BR) Loup was used with stent in anastomosis.

All patients and donors in this study were ABO compatible.

We have performed OLT 1271 {1110 LDLT (87%) (Split LDLT 1095 +5 dual"2 transplant each" +10 re-transplant) DDLT 161} by the end of July 2014.

Total adult (76%) patients are 978. The last adult (RY) was DDLT in 30-6-2014 and included in the study.

All patients completed two years long term follow up by now. Outcome of those who underwent MBR were compared with the outcome of historical cohort, 16 patients underwent conventional biliary reconstruction before March 22, 2006.

OLT liver transplant center CGMH Kaohsiung

LDLT	1110	Ped	250
		Adult	860
DDLTL	161	Ped	43
		Adult	118

Statistical analysis

The analysis was done with SPSS computer software (SPSS version 22 for Windows, SPSS, Inc., Chicago, IL):

Student’s t, Mann Whitney u, chi-square, or fisher’s exact tests will be used as appropriate. Categorical data will be presented as proportion; continuous data will be presented as mean, ranges and standard deviation or median and inter-quartile-range as appropriate. *p*<0.05 will be used to indicate statistical significance. All values were expressed as means and ranges when appropriate. The t test and chi – square test were used to compare recipients and between the MBR and the conventional reconstruction groups.

1. Demography

Liver transplant is a disease of no sex differences. I have separated the age group above and below 50. This margin is important to show the chronicity of liver disease and the associated common medical co- morbidity like DM, HTN, hyperlipidaemia, CAD and IHD. Also, age signify previous surgical procedure. With the advance in the anti-hepatitis drugs there is a decrease in recurrence of hepatitis post liver transplant including decrease cholangitis and rejection. These make hepatitis patients in both groups more common than other causes of liver failure. HCC cases is included in our comparison between the two era of (RY) biliary drainage either conventional or MBR. In spite of the development in the indication of liver transplant with HCC downgrading and multiple modalities of previous surgical, radiological or endoscopic intervention there was no significant differences before 2006 and after. The *p* value

was less than 0.5. There was no significant difference in the two groups. So, both groups had the bases to be compared in both short and long term (Table 1).

Table 1: Demography

Category	Conventional(16)	MBR (50 patients)	P value
Male / Female	Eight /Eight	37/13	0.121
Age less than 50/more than 50	Nine/Seven	34/16	0.547
With HCC	3	18	0.234
HBV	8	16	0.238
HCV	3	17	0.353
Both HBV+HCV	1	2	0.572
Non hepatitis	6	14	0.585

2. Anatomical and pathological factor

In this special circumstance, we created a table for both anatomical and pathological factors related to biliary tree surgery in liver transplant. Indication of MBR carries special care and precise decision. It is not easy and indication overlap could happen. It focuses on the difficulties of biliary reconstruction in liver transplant. We advise clear justification for biliary anastomosis choices. The choice between either (D-D) or (RY) needs such elaboration. It is actually a tool for biliary drainage assessment in surgical practice. Anatomical and pathological factors evaluation at this moment is essential to overcome previous morbidity (Table 2).

The anatomical factors:

Anatomical variants should be evaluated for both graft and native bile duct. Peri operative planning includes:

1. The size (small).
2. The number of the ducts.
3. Discrepancy (between graft and recipient duct size).
4. Position of the ducts:
 - How the duct face the surgeon hands.
 - The ducts position to each other (apposition).
 - The duct relation to the vessels: portal vein and hepatic arteries
 - The accessibility to do the arterial anastomosis comfortably.
 - The relation of the artery and other ducts.
 - Artery length and apposition.
5. CPD (cephaloperitoneal diameter) the diameter

between the abdominal wall and the graft pedicle. It reflects the difficulty of the working hand and microscope fitting.

Pathological factors (non biliary disease):

- Previous surgery.
- Re-transplant.
- Redo of the ducts after vascular events like raw surface bleeding, hepatic artery thrombosis, hepatic artery spasm, cases of redo hepatic artery.
- Quality of the artery and fragility. Intimal dissection degree (mild, moderate or severe) hepatic artery flow or occlusion.
- The quality of native duct: CBD dilatation, tension, burn, obstruction, stricture, iatrogenic cut during surgery either because the difficult position or as a part of damage control in cases of severe bleeding in recipient surgery, duct stones and previous intervention like ERCP, biliary balloon dilatation, stent, stone extraction or PTCD.

Table 2: Anatomical and pathological factor

Anatomical factors	Pathological factors
26 patients	24 patients
Small narrow space	Quality of biliary tree (burned or cut-short-fragile -stone)
Discrepancy between two ends of duct	Re do (re transplant +re look)
Position	Hepatic artery mild or severe intimal dissection
CPD more than 10 (ASCITES-PCLD)	Hepatic artery flow (reverse or poor flow)
CPD less than 10 (babies-thin)	Biliary tree(dilated-obstructed-stricture-adenoma)
Portal vein and hepatic artery relation to the duct	Fragile-thrombosis-occluded hepatic artery
Apposition	Donor hepatic artery intimal dissection
Difficult	Combination

It was easy to justify the pathological factors for indication of (RY) in OLT. However, 26 patients got anatomical factor and narrow space out of 50.

This explains the importance of anatomical factor in feasibility and safety of biliary drainage. The fight against anatomical difficulties is easier by the MBR.

3. Indication for transplant

Initial experience in conventional era used split right lobe adult liver transplant. Variability in duct number and position of the right lobe and the hepatic artery anatomy makes duct to duct biliary drainage difficult, and the (RY) was a choice for biliary drainage in OLT.

On the other hand, MBR era right and left were nearly equal. The liver split graft, right or left, plays equal role in the decision of type of biliary drainage in MBR. Left lobe shared the same problematic anatomical and pathological factors in liver transplant, left lobe apposition of the duct systems and graft growth with possible angulation of biliary tree and vascular pedicle affect the choice of biliary drainage procedure.

Furthermore right or left graft includes number of bile duct opening and graft duct diameter.

Both groups conventional and MBR are elaborated in the coming table. Although there was a trend towards smaller graft duct in the MBR group, we got the chance to use right and left lobe equally.

We did 116 whole liver transplants, DDLT five by MBR (RY). DDLT was not always related to acute on chronic (alcoholic, HBV, HCV). Two cases were related to pathological factors. In one patient MBR (RY) biliary drainage for re-transplant after 20 years, post biliary atresia LDLT and another case due to poor quality CBD. However, in adults the left lobe late complication is absent compared with paediatric group. The limited graft and abdomen growth in adult left lobe graft could be the explanation. Although there was a trend towards smaller graft duct in the MBR group, this did not reach statistical significant.

Earlier, liver failure and high grade disease were the sole indication for liver transplant. In the conventional era we used to do OLT more in high grade disease. It is known that in the last 10 years we did liver transplant for HCC patients according to Milan criteria. Indications includes early Childs grade A and B. This adds extra load to the liver transplant surgery. HCC OLT MBR by (RY) carries about 40% of patients. Actually, HCC patients are associated with previous surgical resection, biliary endoscopic intervention and radiologic intervention for instance PEI, RFA, Hepatic Artery Embolization (TAE) or (TACE). Combination between these modalities is also common in each and every case of HCC. These interventions affected the recipient biliary tree. (RY) biliary drainage by MBR was a choice in those challenging HCC patients of even early Childs grade. As long as we did liver transplant for different Childs grades, the Childs grade

got limited role in the decision of MBR by (RY). MBR by (RY) overcome difficulties of previous biliary, surgical and radiological intervention. In advanced disease a lot of anatomical and pathological factors are expected. Thick intestinal wall due to ascites, portal hypertension and displaced biliary tree due to wide peritoneal cavity as well as shrieked cirrhotic liver affected the biliary tree.

Majority of the patient was hepatitis in both study groups. 36/50 in the MBR and 6/10 in the conventional era. Non – hepatitis patients included biliary atresia, primary biliary cirrhosis and alcoholic liver cirrhosis.

On the other hand, in MBR eight extra non hepatitis patients were (hilar biliary stricture+Wilson's+biliary dilatation+polycystic liver disease+portal vein occlusion+choleduchal cyst+2 intrahepatic duct stone). By this we included nearly most of the varieties of bile duct pathology in the MBR era. The MBR (BY) has widen the number of indication with decreased post OLT morbidity. The (RY) reconstruction is essential in adult OLT. It overcome the large abdominal cavity, shortened conduit, risk to arterial anastomosis and unhealthy duct due to previous stone, infection or ERCP.

MBR of enterico hepatico anastomosis may be essential for a new scope of hepaticobiliary disease in LDLT.

Re-transplant arise in the late era. In re-transplant MBR by (RY) was mandatory. In our centre we did 10 patients, 4 of them underwent this choice of MBR biliary drainage. It is clear now that this is related to previous surgery and intervention including bile duct complication.

Re-transplant patients (3 DDLT+2SPLIT LEFT LDLT):

1. Chronic rejection bile duct stricture HCV.
2. DE novo HBV alcoholic.
3. HCV recurrence.
4. Alcoholic.
5. Bile duct stenosis after Wilson's disease.

All patients of mixed graft (both bile duct and jejunal lobe are used for the same graft as a biliary drainage conduit) were in the MBR era this added extra scope in liver transplant surgery. One mixed dual - left duct to duct and right lobe to jejunal loop- biliary drainage. Right lobe graft was 4 patients. Number of the graft duct and relation to hepatic artery and portal vein forced the drainage procedure to be both jejunal and duct to duct on the same OLT (Table 3).

Table 3: Indication for transplant

Category	Conventional(16)	MBR (50 patients)
Right lobe	15	23
Left lobe	1	22
Whole liver	0	5
Childs a	1	14
Childs b	8	15
Childs c	7	21
HBV	6	13
HCV	2	15
Fulminant	1	2
Alcoholic	1	3
Primary biliary cirrhosis	3	1
Biliary atresia	2	1
Re transplant	0	5
Others	0	8
Mixed	0	4 patients (one dual)
Staged	0	28/40

Secondary study

Sub clinical, secondary analysis of delayed biliary tree reconstruction in liver transplant (DBR) (biliary tree reconstruction to be delayed for 24-48 hours to check for bleeding from raw surfaces in recipient and also because of bowel oedema due to the advanced).

(DBR) by hepatico enteric anastomosis overcome bowel congestion in advanced liver disease. Previous surgery is the cause of marked adhesions and bleeding from raw abdominal surfaces.¹⁸⁻²¹ This is an indication for Staged duct anastomosis and it is done mostly by (RY).

One more point, delayed biliary reconstruction in OLT by hepaticojejunostomy can overcome cases of vascular events (hepatic artery or portal vein). In re-check for bleeding and open vascular intervention, revision of biliary tree anastomosis is a part of DBR.

Results and Discussion

From the above mentioned data we offered very much new insights about adults OLT indication associated comorbidity including HCC and associated consequences.

It is not only different age group but also different disease behaviour beside the use of right lobe graft with a lot of diversity from paediatric age group

Stratified biliary complication

All complications develop within 90 days after transplantation. The table shows the risk calculation for the development of complication. Based on analysis of cohort

study, conventional reconstruction has increased the risk of biliary complications by 2.4 times. There was a significant difference in p value (Table 4).

There were three bile leak in the MBR group and one biloma. Leak is minor in (RY) MBR. There were no late biliary complications. No stricture.

Three bile leakage in the conventional reconstruction group and three biloma. Two recipients out of 16 patients developed stricture. Stricture was common before MBR era.

Table 4: Stratified biliary complication

	Group A (16)	Group B (50)	P Value
Biliary complication	8	4	0.001
Stricture	2	0	0.056
Leak	3	3	0.148
Biloma (early)	3	1	0.041
Needs intervention	5	1	0.002

Secondary study

Detailed secondary study of complication management is shown in the coming table. In conventional (RY) eight out of 16 patients managed conservatively by non-surgical procedures first. Biloma was resolved in two patients but one treated latter as a case of secondary biliary cirrhosis. Another third patient got anastomosis revision as part of hepatic artery re-anastomosis.

Two leak patients diagnosed as (RY) perforation and another patient with bile peritonitis got an immediate redo. Late Stricture with repeated cholangitis treated non-surgically. The 8th patient underwent initial percutaneous trans hepatic biliary drainage but followed by revision of hepatico jejunostomy as the patient went to leak- stricture complication. Also (RY) was the sole choice for biliary drainage in some cases of OLT in the era before MBR; this choice was associated with high morbidity. Leak used to be generalised – not focal (biloma). (RY) used to be a redo or repeated procedure due to fatal complication before the MBR era (Table 5).

MBR complication was managed non-surgically. Biloma case was controlled by PTCD. The other three leak cases got spontaneous resolution without any further complication. In both group the deaths were not related to biliary complication.

Table 5: Early era of conventional and recent era of MBR hepatico biliary drainage outcome

(RY) BILOMA	RESOLVED	
(RY) BILOMA	RESOLVED	SECONDARY BILIRY CIRRHOSIS
(RY) BILOMA	RE DO HA	REVISION
(RY) LEAK	RY PERFORATION	RE DO
(RY) LEAK	BILE PERITONITIS	RE DO
(RY) LEAK	STRICTURE	REVISION
(RY) SRICTURE	REPEATED CHOLANGITIS	
(RY) SRICTURE	POST LEAK	PTCD+PIGTAIL+REVISION
MBR BILOMA		PTCD+PIGTAIL+REVISION
MBR LEAK	STAGED	RESOLVED
MBR LEAK	STAGE MIXED	RESOLVED
MBR LEAK	STAGED MIXED DUAL	RESOLVED

Secondary analysis for leak patients took place too. All the leak patients were staged procedures. Three staged (MBR) patients out of 28 (RY) of the total 40 cases down in the centre got leak.

Four mixed patients are performed in our centre. This is a small number of mixed cases which include cases of both D-D and RNYHJ in the same patient of OLT. Two patients (50%) developed early leak which has resolved spontaneously. One of the mixed cases was Dual patient liver transplant.

Conclusion

- The choice of MBR for duct to jejunum anastomosis in adults LDLT and DDLT is important and needs to be defined and safely practiced.
- Enteric biliary drainage merits and demerits give superiority of MBR over the conventional biliary anastomosis in adults liver transplant.
- Indications for adults liver transplant can be widened with comparable low post-operative complication.
- Anatomical factors and pathological factors got overlap in adult OLT indication.
- The left lobe shared the same problematic anatomical and pathological factors. The fight against the difficulties is easier by the MBR.
- MBR hepaticojejunostomy can overcome the complication of conventional surgical reconstruction.
- It is essential for a new scope of cases of hepaticobiliary disease in OLT like special cases of re-transplant, staged (DBR), mixed and (dual). But it needs extra precaution to overcome the possibility of leak.
- MBR have balanced decision regarding Childs grade.
- Acceptable short term outcome is proved to be low in early period and no stricture in long term outcome.

References

1. Yamamoto H, Hayashida S, Asonuma K, et al. Single-centre experience and long-term outcomes of duct-to-duct biliary reconstruction in infantile living donor liver transplantation. *Liver Transpl.* 2014;20(3):347–54.
2. Ishiko T, Egawa H, Kasahara M, et al. Duct-to-duct biliary reconstruction in living donor liver transplantation utilizing right lobe graft *Ann Surg.* 2002;236:235–240.
3. Soejima Y, Taketomi A, Yoshizumi T, et al. Biliary strictures in living donor liver transplantation; incidence, management, and technical evolution, *Liver Transpl.* 2006;12:979–986.
4. Haberal M, Karakayali H, Atiq A, et al. Duct-to-duct biliary reconstruction without a stent in paediatric living-donor liver transplantation. *Transplant Proc.* 2011;43:595–597.
5. Chen CL, Concejero AM, Lin TS, et al. Outcome of routine use of microsurgical biliary reconstruction in paediatric living donor liver transplantation. *J Hepatobiliary Pancreat Sci.* 2013;20(5):492–7.
6. Calne RY. A new technique for biliary drainage in orthotopic liver transplantation utilizing the gall bladder as a pedicle graft conduit between the donor and recipient common bile ducts. *Ann Surg.* 1967;184:605–9.
7. Starzl TE, Putnam CW, Hansbrough JF, et al. Biliary complications after liver transplantation with special reference to the biliary cast syndrome and technique of secondary duct repair. *Surgery.* 1977;81:212–21.
8. Ishiko T, Egawa H, Kasahara M, et al. Duct-to-duct biliary reconstruction in living donor liver transplantation utilizing right lobe graft. *Ann Surg.* 2002;236:235–240.
9. Lin TS, Chen CL, Concejero AM, et al. Early and long-term results of routine microsurgical biliary reconstruction in living donor liver transplantation. *Liver Transpl.* 2013;19(2):207–14.
10. Kasahara M, Egawa H, Takada Y, et al. Biliary reconstruction in right lobe living –donor liver transplantation; comparison of different techniques in 321 recipients. *Ann Surg.* 2006;243:559–566.
11. Sutton ME, Bense RD, Lisman T, et al. Duct-to-duct reconstruction in liver transplantation for primary sclerosing cholangitis is associated with fewer biliary complications in comparison with hepaticojejunostomy. *Liver Transpl.* 2014;20(4):457–63.
12. Chang JH, Lee IS, Choi JY, et al. Biliary stricture after adult right-lobe living-donor liver transplantation with duct-to-duct anastomosis: Long-term outcome and its related factors after endoscopic treatment. *Gut Liver.* 2010;4:226–233.
13. Tade S, Yazumi S, Chiba T. Endoscopic management is an accepted first-line therapy for biliary complications after adults living donor liver transplantation. *Am J Gastroenterol.* 2007;102:1331.
14. Greif F, Bronsther OL, Van Thiel DH, et al. The incidence, timing and management of biliary tract complications after ortho-topic liver transplantation. *Ann surg.* 1994;219:40–45.
15. Lin TS, Concejero AM, Chen CL, et al. Routine microsurgical biliary reconstruction decreases early anastomotic complications in living donor liver transplantation. *Liver Transpl.* 2009;15:1766–1775.
16. Matthews JB, Gertsch P, Baer HU, et al. Biliary stricture following hepatic resection. *HPB Surg.* 1991;3:181–190.
17. Liu CL, Lo CM, Chan SC, et al. Safety of duct-to-duct biliary reconstruction in right –lobe live-donor liver transplantation without biliary drainage. *Transplantation.* 2004;77:726–732.
18. Fan ST, Lo CM, Liu CL, et al. Biliary reconstruction and complication of right lobe live donor liver transplantation. *Ann Surg.* 2002;236:676–638.
19. Chen CL, Concejeron AM, Lin TS, et al. Staged biliary reconstruction is feasible procedure to overcome intraoperative critical condition in liver transplant. *Liver Transplantation.* 2012;18:S282.
20. Yong CC, Chen CL, Wang CC, et al. Delayed biliary reconstruction to overcome intraoperative hemodynamic instability and prevent early biliary anastomotic complication in liver transplantation. *Liver Transplantation.* 2011;17:s297.
21. Yan L, Li B, Zeng Y, et al. Introduction of microsurgical technique to biliary reconstruction in living donor liver transplantation. *Transplant Proc.* 2007;39:1513–16.

ACKNOWLEDGEMENTS

Dr. Mohammed al Sharef for SPSS analysis.

PEER REVIEW

Not commissioned. Externally peer reviewed.

CONFLICTS OF INTEREST

The authors declare that they have no competing interests.

FUNDING

None