



## Hamstrings tendon graft preparation for anterior cruciate ligament reconstruction using the WhipKnot™ soft tissue cinch technique

Amin Masoumiganjgah, Umesh Dhanjee, Tendai Mwaturura, Cameron Carmody

Toowoomba Hospital, University of Queensland, QLD, Australia

---

### RESEARCH

---

Please cite this paper as: Masoumiganjgah A, Dhanjee U, Mwaturura T, Carmody C. Hamstrings tendon graft preparation for anterior cruciate ligament reconstruction using WhipKnot™ soft tissue cinch technique. AMJ 2012, 5, 4, 236-238. <http://doi.org/10.21767/AMJ.2012.1241>

---

#### Corresponding Author:

Amin Masoumiganjgah, MD  
Toowoomba Hospital  
Pechey Street,  
Toowoomba, QLD, 4350  
Email: [amasoumig@gmail.com](mailto:amasoumig@gmail.com)

---

### Abstract

---

#### Background

Appropriate graft tension and secure graft incorporation in bone tunnels are essential for successful anterior cruciate ligament (ACL) reconstruction using hamstrings tendon autografts. The WhipKnot™ soft tissue cinch, introduced by Smith and Nephew in 2004, is an alternative option to the commonly used whipstitch technique during preparation of the hamstring autograft in ACL reconstruction.

#### Aims

To investigate the effectiveness of the WhipKnot™ soft tissue cinch and technique during the preparation of the tendon graft for ACL reconstruction.

#### Method

A total of 33 ACL reconstruction operations performed between February 2011 and December 2011 were included in this study. These were performed by a single senior surgeon who used the Whipknot™ technique for the preparation of each graft. Four were used for each operation; two for each end of the harvested hamstrings tendons, including semitendinosus and gracilis tendons respectively.

#### Results

In total, 132 WhipKnots were used during the knee operations. Use of the WhipKnot™ technique resulted in successful graft preparations, tensioning and effective graft placement in the tibial and femoral tunnels in almost all

instances. Only one case of WhipKnot™ failure (slippage) was recorded.

#### Conclusion

These results indicate that the Whipknot™ technique is a safe, reliable and practical option for the preparation of the hamstrings autografts.

#### Key Words

Anterior Cruciate Ligament, Whipknot™, graft preparation, reconstruction

---

#### What this study adds:

1. What is known about this subject? Cadaver studies show that WhipKnot™ can be used as an alternative for whipstitch in ACL reconstruction.
2. What new information is offered in this study? This is the first clinical experience published about WhipKnot™ technique.
3. What are the implications for research, policy or practice? WhipKnot™ is a practical and reliable technique for graft preparation for ACL reconstruction.

---

#### Background

Anterior cruciate ligament (ACL) rupture is an injury commonly encountered in orthopaedic practice. It can occur as an isolated injury or within the spectrum of multiple ligament injured knee. Restoration of the ACL function is very important, with ACL reconstruction using autografts, either hamstrings or bone-patella tendon-bone currently being the preferred technique.<sup>1,3,4</sup>

During ACL reconstruction with double looped hamstring autografts, the free ends of the tendon are usually sutured to improve the intraoperative handling. This also permits adequate tensioning of the graft. A number of options are available for the suturing of the tendon ends and a commonly used technique involves the application of a whipstitch to the ends of the graft. The stitched portion of the graft itself does not contribute to the definitive fixation of the reconstructed ligament within the tibial tunnel.

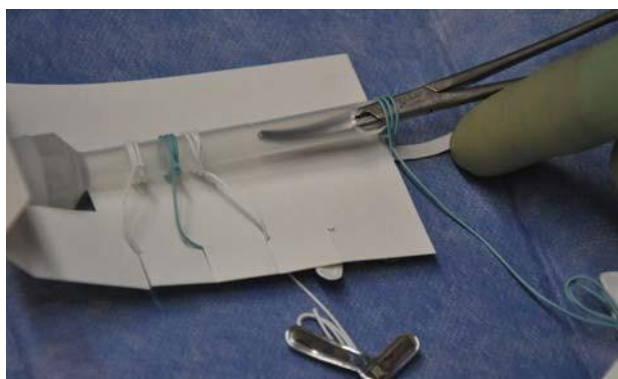
WhipKnot™ soft tissue cinch is an alternative technique, which was introduced by Smith and Nephew, USA in 2004



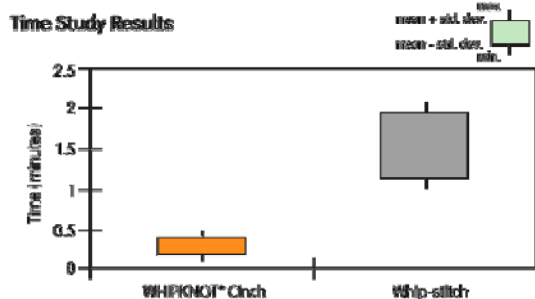
(Figure 1). Cadaver studies show that WhipKnot™ has a holding strength of 48.79lb, and that use of the WhipKnot™ soft tissue cinch results in a significant decrease in the amount of time needed for graft preparation compared to the whip-stitch (Figure 2).<sup>2</sup> There are no clinical studies that indicate WhipKnot™'s clinical reliability in autograft preparation for ACL reconstruction.

This study aims to demonstrate that the WhipKnot™ is a reliable and safe method for tendon graft preparation, tensioning and passing of tendon grafts through the tibial and femoral tunnels.

**Figure 1: The Whipknot™ as supplied by Smith & Nephew. Four WhipKnots (two white, two blue) are shown prior to use during surgery. The left three are still *in situ* in the original packaging and the knot to the right has been moved on to the shaft of the clamp.**



**Figure 2:<sup>2</sup>Previous cadaver studies show that the mean time required for use of the WhipKnot™ cinch (15 seconds) is statistically significantly smaller ( $p < 0.001$ ) than the time to whip-stitch a comparable tendon end (1.5 minutes)<sup>[2]</sup>.**



### Method

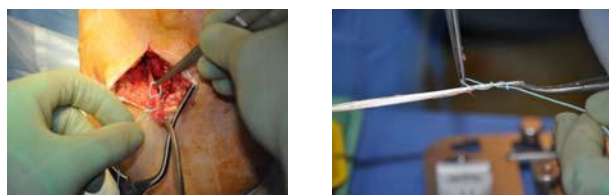
The study was conducted prospectively from February 2011 to December 2011. A total of 33 patients consisting of 26 male and seven female patients (range 16-45 years, mean age 26 years) with ACL rupture were included in the study. Inclusion criteria were clinical diagnosis of ACL rupture and the confirmation of complete ACL rupture with MRI scan.

The surgical procedure was explained to all of the patients, and written consent was obtained from the patients pre-operatively. ACL reconstruction operation was performed by a senior orthopaedic surgeon using an arthroscopic technique that utilised hamstring autografts (gracilis, semitendinosus). A junior registrar assisted the surgeon in all of the operations.

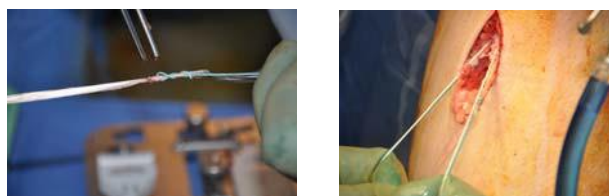
One WhipKnot™ was applied at each end of the tendon after removal of the tendon (Figure 3). The WhipKnots are colour coded so as to identify the harvested semitendinosus and gracilis tendons after preparation; graft ends are kept under tension with the WhipKnot™ until it is passed through the tibial and femoral tunnels (Figure 4). Once the graft is passed through the tunnels and the fixation is achieved, the ends of the WhipKnot™ and tendon are cut off and discarded (Figure 5).

The effectiveness of the WhipKnot™ technique in holding the tendon graft during tendon harvesting, tensioning and passing of the tendon grafts through the tibial and femoral tunnels was noted. Technique failure was defined as slipping of the tendon graft during the process of graft preparation or unsuccessful passing of the tendon graft through the tibial or femoral tunnels.

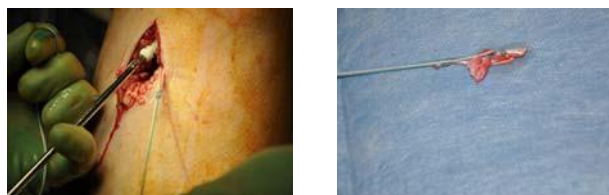
**Figure 3: One WhipKnot™ is applied at each end of the tendon.**



**Figure 4: WhipKnot™ is used to hold and tension graft inside tunnel.**



**Figure 5: Once the fixation is achieved, the ends of the WhipKnot™ and tendon are cut off and discarded.**





## Results

Operations were performed on 17 right and 16 left knees during the study period with 132 WhipKnots used during surgery. Only one failure of WhipKnot™ was recorded; the failure was rectified by the application of a replacement WhipKnot™ and surgery was completed without any ramifications for the patient. All of the patients had at least 3-6 month follow-up, which did not show any complications including ACL reconstruction failure.

## Discussion

Our study is the first clinical experience reported with the use of the WhipKnot™ technique. From a total number of 132 WhipKnots that were used on 33 patients there was just one failure of the WhipKnot™, indicating that the WhipKnot™ is an extremely reliable method of graft preparation. A junior registrar assisted the senior surgeon in all operations and our experience shows that even the first-time use of the WhipKnot™ Soft Tissue Cinch can result in a successful application of the WhipKnot for tendon-end preparation within a surgical procedure.

There are some limitations that need to be noted. This study is focused on the use of the WhipKnot™ in the clinical setting without considering other factors that could contribute to the success of graft preparation procedures. Additionally, the present study is single surgeon/centre experience.

Using the whipstitch technique may lead to permanent viscoplastic elongation of the constructs due to slippage of the suture material within the tendon tissue; furthermore it is reasonable to assume that a high amount of suture material might impair healing.<sup>5</sup> The length of the suture augmentation using the WhipKnot™ is approximately 5mm with a larger area of tendon in the tunnel without suture augmentation. WhipKnot™ has equal mechanical properties compared to the whipstitch technique.<sup>2</sup> Additionally, the use of WhipKnot™ provides a larger area in the tendon–bone interface without suture material, compared with the whipstitch technique. Therefore, use of the WhipKnot™ has the potential to further improve the success of ACL reconstruction procedures over and above the benefits of time-saving and reliability that have been demonstrated.

There are other considerations with respect to the possible benefits of the WhipKnot™ soft tissue cinch. Our observations indicate that a whipstitch provides suture material in the whole extent of the tendon–bone interface in the tibial tunnel. The clinical relevance of maintaining suture material in the tunnel is not known, with one possibility being that this excess material may impair healing. We hypothesize that the WhipKnot™ may improve

biological incorporation of hamstring tendon autografts, however further clinical and histological studies are needed to confirm that less suture material in the tendon–bone interface improves tendon-to-bone healing.

## Conclusion

While the passage of a whipstitch during ACL reconstruction is widespread practice and has reliable results, this study showed that the use of WhipKnot™ soft tissue cinch appears to be a viable, reliable and effective alternative technique.

---

## References

1. Fink C, Hoser C, Benedetto KP, Hackl W, Gabl M. Long-term outcome of conservative or surgical therapy of anterior cruciate ligament rupture (in German). *Unfallchirurg*. 1996;99:964–969.
2. Gabriel SM, Smith & Nephew PE, Inc.. Endoscopy Division Hamstrings Tendon Graft Preparation: Smith & Nephew WHIPKNOT™ Soft Tissue Cinch versus Whip-stitching, Endoscopy, Smith & Nephew, Inc. Andover, MA 01810 USA.
3. Seitz H, Chrysopoulos A, Egkher E, Mousavi M. Long-term results of replacement of the anterior cruciate ligament in comparison with conservative therapy (in German). *Chirurg*. 1994;65:992–998.
4. Wittenberg RH, Oxford HU, Plafki C. A comparison of conservative and delayed surgical treatment of anterior cruciate ligament ruptures. A matched pair analysis. *Int Orthop*. 1998;22:145–148.
5. Hoher J, Scheffler SU, Withrow JD, Livesay GA, Debski RE, Fu FH, Woo SL. Mechanical behavior of two hamstring graft constructs for reconstruction of the anterior cruciate ligament. *J Orthop Res*. 2000. 18:456–461.
6. Fu FH, Bennett CH, Lattermann C, Ma CB. Current trends in anterior cruciate ligament reconstruction. Part I. Biology and biomechanics of reconstruction. *Am J Sports Med*. 2000; 28:124.

## PEER REVIEW

Not commissioned. Externally peer reviewed

## CONFLICTS OF INTEREST

The authors declare that they have no competing interests

## CONSENT

The authors declare that they have obtained informed consent for the operations and for the publication of the details relating to the patients in this report.