



Review

# The Old and the New in Subacute Thyroiditis: An Integrative Review

Nicola Lanzo <sup>1</sup>, Bohdan Patera <sup>1</sup>, Gaia Francesca Maria Fazzino <sup>1</sup>, Daniela Gallo <sup>2</sup> , Adriana Lai <sup>2</sup>, Eliana Piantanida <sup>1,2</sup>, Silvia Ippolito <sup>2,\*</sup> and Maria Laura Tanda <sup>1,2</sup>

- <sup>1</sup> Department of Medicine and Surgery, University of Insubria, 21100 Varese, Italy; nicola.lanzo@hotmail.it (N.L.); bdn.patera@gmail.com (B.P.); gaiafmazzino@gmail.com (G.F.M.F.); eliana.piantanida@uninsubria.it (E.P.); maria.tanda@uninsubria.it (M.L.T.)
- <sup>2</sup> Endocrine Unit, ASST dei Sette Laghi, 21100 Varese, Italy; dgallo@hotmail.it (D.G.); adriana.lai@asst-settelaghi.it (A.L.)
- \* Correspondence: silviaippolito.md@gmail.com

**Abstract:** Subacute thyroiditis (SAT) is the most common cause of neck pain and thyrotoxicosis. Although this disease was recognized already by the end of the 18th century, new concepts regarding pathogenesis have emerged in recent years. Moreover, in the last two years, literature on SAT has increased significantly due to articles describing the possible connection with coronavirus disease 2019 (COVID-19). This integrative review depicts old and new concepts of this disease, proposing a detailed overview of pathogenesis, a practical approach to diagnosis and treatment, and a thorough description of the latest discoveries regarding the association of SAT with COVID-19.

**Keywords:** subacute thyroiditis; De Quervain thyroiditis; destructive thyroiditis; SARS-CoV-2; COVID-19



**Citation:** Lanzo, N.; Patera, B.; Fazzino, G.F.M.; Gallo, D.; Lai, A.; Piantanida, E.; Ippolito, S.; Tanda, M.L. The Old and the New in Subacute Thyroiditis: An Integrative Review. *Endocrines* **2022**, *3*, 391–410. <https://doi.org/10.3390/endocrines3030031>

Academic Editor: Rasa Zarnegar

Received: 3 May 2022

Accepted: 28 June 2022

Published: 4 July 2022

**Publisher's Note:** MDPI stays neutral with regard to jurisdictional claims in published maps and institutional affiliations.



**Copyright:** © 2022 by the authors. Licensee MDPI, Basel, Switzerland. This article is an open access article distributed under the terms and conditions of the Creative Commons Attribution (CC BY) license (<https://creativecommons.org/licenses/by/4.0/>).

## 1. Introduction

Subacute thyroiditis (SAT), also called De Quervain thyroiditis or granulomatous thyroiditis, is the most common cause of thyrotoxicosis and a common cause of thyroid dysfunction, mainly thyrotoxicosis. SAT is presumed to be caused by viral infections, mainly from viruses affecting the upper respiratory tract, recently including severe acute respiratory syndrome-coronavirus-2 (SARS-CoV-2).

Although this disease was recognized already by the end of the 18th century [1] and is relatively frequently seen and treated by endocrinologists and internal medicine doctors, in the latest years new concepts have emerged, especially concerning pathogenesis. Moreover, in the last two years, the literature on SAT has increased significantly due to articles describing the possible connection between COVID-19 and SAT.

This updated review depicts old and new concepts on every aspect of this disease, from epidemiology and pathogenesis to clinical features, natural history, and treatment.

A dedicated paragraph will summarize and comment the consistent available literature on the association of SAT and SARS-CoV-2 infection and/or vaccination.

## 2. Materials and Methods

Original articles, clinical trials, systematic reviews, meta-analyses, and case reports or series were retrieved from a search of electronic databases including PubMed, Google Scholar, Embase, and Scopus.

The search was updated on 20 April 2022, with no language restrictions. The search string included specific key terms: subacute thyroiditis, destructive thyroiditis, De Quervain thyroiditis.

### 3. Integrative Review

#### 3.1. Epidemiology

The incidence of SAT is about 4.9/100,000 people per year [1]. The reported age of incidence in literature typically varies between 25 and 50 years of age, with a female-to-male ratio of approximately 4:1 [2]. Few cases of SAT have been described during pregnancy [3,4] and in children [5,6].

Some investigators have reported a higher rate of SAT during the summer months, reflecting the peak incidence of coxsackievirus A and B and echovirus infections [7]. In the Italian series by Martino et al. [8], the reported onset of SAT was predominant between June and September, with almost half of the cases between July and August, thus confirming the overlapping seasonal distribution of SAT and enterovirus infections. Similarly, Japanese data from 1061 SAT patients by Iitaka et al. [9] indicated a higher frequency of SAT cases in summer than in winter.

However, other authors found no significant differences in distribution throughout the year. Although seasonal differences may be observed in a mild climate like Italy's, no statistically significant seasonal variation was found in studies from Minnesota [1] and Finland [10], where the periodic climatic contrast is much more severe [11].

#### 3.2. Pathophysiology

Although SAT was described for the first time already in 1895 by Mygind [12], the exact pathogenesis and determinants of its clinical course still remain unclear nowadays [13]. The current opinion is that a viral trigger may cause a painful and destructive thyroiditis in patients with a certain genetic background.

Viruses that have been associated with SAT are coxsackie viruses, echoviruses, adenoviruses, influenza viruses, mumps and rubella viruses, parvovirus B19, orthomyxovirus, HIV, Epstein-Barr virus, hepatitis E, measles virus [14,15], and dengue virus [16,17]. In recent years, during the COVID-19 pandemic, SARS-CoV-2 emerged as a potential SAT-triggering factor. SARS-CoV-2, indeed, exhibits significant tissue tropism, with a peculiar affinity for the thyroid tissue, mediated by the angiotensin converting enzyme 2 (ACE-2) receptor. In the last two years, since the onset of the COVID-19 pandemic, many cases of SAT related to SARS-CoV-2 infection and vaccination have been reported [18,19]. Therefore, SARS-CoV-2 should now be included into the list of viruses associated with SAT.

The association of SAT with specific genetic backgrounds has been postulated since 1975, when predisposition to SAT was found to be related to human leukocyte antigen (HLA) genes [14]. HLA alleles were demonstrated not only to increase the risk of SAT, but also to correlate with SAT clinical course and to its risk of recurrence [14]. The great majority of patients with SAT, up to 70% [20], indeed present the HLA-B35 antigen, suggesting that the disease may be caused by a viral infection in genetically predisposed individuals [12].

There are two main hypotheses: (i) the HLA-B35-restricted viral antigen presentation hypothesis suggests that viral antigens may cross-react with host antigens, resulting in tissue destruction; (ii) viral infection may cause direct damage to thyroidal tissue, releasing high quantities of self-antigens, that may be recognized as foreign by HLA-B35, leading to the development of an autoimmune process and further tissue damage [21,22]. Some cases of familial occurrence of SAT related to the HLA-B35 allele have been described too [21]. More recently, Stasiak et al. [20] reported HLA-B18:01 and HLA-DRB101 alleles as independent risk factors for SAT development. Some authors also reported other possible associations between SAT and haplotypes such as HLA-Dw1, HLA-DRw8, HLA-B67, and HLA-Cw3 [22]. However, these studies applied mostly serological methods, and only some associations were confirmed when high-resolution methods were used [20].

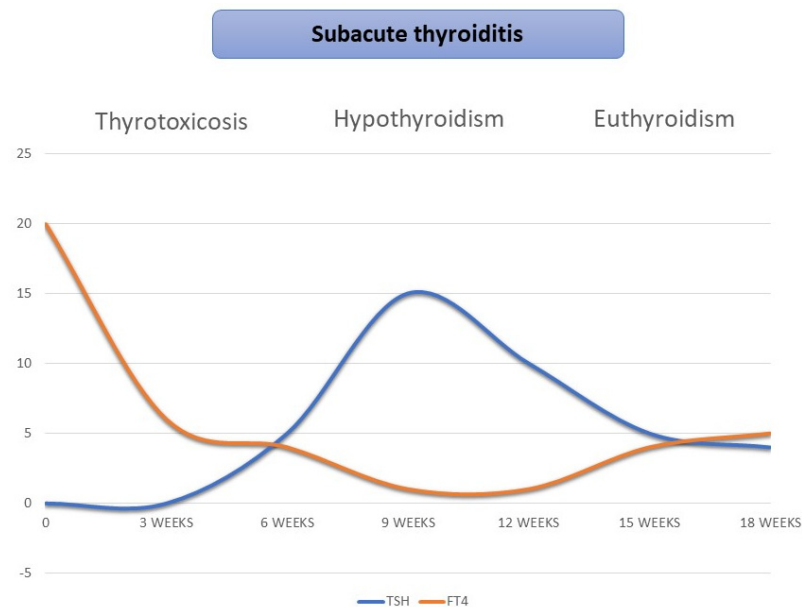
Other pathogenetic factors or co-factors have been proposed. For instance, SAT cases associated with bacterial infection (bacterial sinusitis [23], scrub typhus [24]), or with immunotherapy with recombinant interleukin-2 [25], TNF-alpha inhibitors [26], interferon [27], or lithium treatment [28] have been described. SAT cases occurring after vaccination against common viruses such as H1N1 [29], seasonal influenza virus [30,31], human

papillomavirus [32,33], and hepatitis B [34] have been reported; since the advent of the vaccination for SARS-CoV-2, several SAT cases following immunization have been described [18], following the nucleic acid (mRNA) [35], viral vector (adenovirus) [36], and the inactivated virus vaccine [37,38]. The exact mechanism is not known, but the presumed pathogenesis of SAT after vaccinations may involve the autoimmune/inflammatory syndrome induced by adjuvants (ASIA) [39], an immune reaction triggered by a class of excipients named adjuvants, primarily used in vaccines, which could cause dysregulation of both the innate and adaptive immune systems [40]. A second hypothesis involves molecular mimicry; a recent in-vitro study [41] found that antibodies directed against SARS-CoV-2 antigens could cross-react with self-tissue antigens, including thyroid peroxidase (TPO). This mechanism represents a potential pathogenic trigger for immune-mediated adverse events both after SARS-CoV-2 infections [42] and SARS-CoV-2 vaccination. A possible association between HLA genotypes and vaccine-induced SAT has been described [43,44].

Vitamin D has been proposed as a protective factor. Calapkulu et al. [13] recently reported that 25(OH) vitamin D levels in SAT patients are significantly lower compared to the healthy control group, though with no effect on disease prognosis nor permanent hypothyroidism development or recurrence rate. This could be a consequence of the protective effect of vitamin D on respiratory tract infections [45].

### 3.3. Natural History

SAT is typically a self-limiting disease. The characteristic triphasic clinical course (Figure 1) arises with a thyrotoxicosis phase lasting 3 to 6 weeks, determined by the damage of thyroid follicular cells and consequent release of thyroid hormones; symptoms of this phase encompass tachycardia, sweating, and weight loss. As thyroid hormone stores are depleted, a hypothyroid phase usually follows and could last up to 6 months; therefore, in some cases, levothyroxine treatment could be needed. In the majority of patients, SAT ultimately results in a full recovery of normal thyroid function [2]. However, in approximately 5–15% of patients, permanent hypothyroidism requiring life-long thyroid replacement therapy might occur [7].



**Figure 1.** Classic triphasic pattern of subacute thyroiditis.

### 3.4. Clinical Manifestations

SAT is typically characterized by anterior neck pain that may radiate to the jaw or ears [46]. It can involve one [47] or both thyroid lobes, often starting on one side and migrating to the other: the so-called “creeping thyroiditis”. The gland is typically enlarged

and firm to palpation, but thyroid adherence to surrounding structures, a common feature of Riedel's thyroiditis, is usually minimal or absent [48].

Patients might complain of somatic symptoms such as fatigue, myalgia, and arthralgia. Mild to moderate fever can also occur, sometimes as the sole clinical presentation. As a matter of fact, atypical SAT may present as a fever of unknown origin [49,50] even in the absence of anterior neck pain or thyrotoxicosis [51,52].

In trained athletes, adrenergic manifestations of thyrotoxicosis could be masked by the frequently observed resting bradycardia; less typical signs and symptoms such as undesired weight loss, fatigue, and performance level decrease can be present [53]. In addition, it should be noted that long-term immunosuppressive therapy may lead to a milder clinical presentation of SAT with low pyrexia and minimal neck pain, regardless of the severity of thyrotoxicosis [54].

### 3.5. Laboratory Findings

The typical laboratory finding is the exceedingly high erythrocyte sedimentation rate (ESR). C-reactive protein (CRP) is also elevated in most cases, though it is a less peculiar finding [13]. White blood count could also be elevated, with about half of the patients presenting neutrophilia and a positive correlation with granulocyte-colony stimulating factor (G-CSF), at least in the active phase of SAT before treatment [55]. Hematological parameters, such as higher platelet-to-lymphocyte ratio and neutrophil-to-lymphocyte ratio values, are typical in SAT patients compared to healthy control subjects, as well as a lower mean platelet volume value [56,57], correlating with ESR and CRP parameters [58]. Interleukin-6 (IL-6), a mediator of acute phase response, is also increased in SAT, though no correlation was found between serum concentration of IL-6 and serum free thyroid hormone values [59].

Thyroid function tests during the initial phase of SAT often reveal a suppressed TSH and elevations of triiodothyronine (T3) and thyroxine (T4) consistent with the thyrotoxic state. As compared to Graves' disease, SAT often displays a lower T3/T4 ratio, typically less than 20 [60,61]. Peak levels of laboratory abnormalities are reached within one week after disease onset, according to a study [12] analyzing 852 cases of SAT.

Although SAT is usually associated with laboratory evidence of thyrotoxicosis, some patients may show normal laboratory findings along with clinical characteristics and ultrasound (US) findings typical of SAT. This could be due to the fact that neck pain could precede the appearance of abnormal laboratory findings by up to 3 weeks [62]. As hypothesized by Ito et al. [63], patients with SAT are admitted earlier to clinic because of neck pain, thus might have incomplete TSH suppression due to short-term thyrotoxicosis, as compared to patients with silent thyroiditis or Graves' disease who seek medical advice because of delayed symptoms secondary to thyrotoxicosis, such as palpitation and weight loss.

The thyrotoxicosis phase is generally followed by transient subclinical hypothyroidism with slightly elevated TSH levels and T3 and T4 within the normal limits [64]. Serum thyroglobulin levels are usually elevated, consistently with follicular destruction [65].

Some patients show a positive thyroid antibody pattern. Stasiak et al. [66] reported 15.5% antithyroid peroxidase antibodies (TPOAb) and 33.3% antithyroglobulin antibodies (TgAb) positivity in SAT patients. A Turkish study [67] on the local population reported about 4% positivity for TPOAb and about 20% positivity for TgAb. In another study by Nishihara et al. [68], patients' samples were moderately positive for TgAb in a first phase, with titres decreasing or disappearing afterwards.

In most cases, this transient antibody positivity might be a consequence of thyroid antigen release following thyroid follicle damage, rather than a veritable autoimmune disease [69]. To note, antibodies titers were significantly lower than those observed in Hashimoto's thyroiditis [68]. In the same study by Stasiak et al. [66], TSH receptor antibody (TRAb) levels were increased in 6% of patients with SAT.

### 3.6. Imaging

Nuclear medicine imaging and US are the main diagnostic tools for SAT, and provide clinical guidance for diagnosis and treatment of this disease, with the latter being easier to operate, more economical, better tolerated, and with wider applications [70].

In painful SAT, at US evaluation, the thyroid gland usually presents irregularly shaped hypoechoic areas with blurred margins and has low vascularity on color-flow Doppler, especially in the acute phase of the disease [71–73]. The pressure exerted during US may cause tenderness and pain exacerbation, which is a specific sign [70]. On the contrary, enhanced vascular signal may be appreciated during disease recovery.

According to Omori et al. [74], hypoechoic area extensions reflect the degree of inflammation and correlate with the intensity of pain experienced by the patient and with the increase in FT4 levels. The presence of multiple ill-defined hypoechoic areas allows clinicians to distinguish SAT from Hashimoto's thyroiditis and Graves' disease, which typically show a diffuse, homogeneous, hypoechoic texture instead [75]. These features are typical of SAT; thus, even in cases with no clinical symptoms, SAT should be considered as a differential diagnosis for every lesion presenting these characteristics [72].

In some patients with SAT, a nodular space-occupying lesion can be observed and some of these lesions may mimic thyroid malignancy, given also their hypoechoic nature at US and firmness on palpation [76]. On the other hand, it is worth remembering that the presence of supposed inflammatory nodules on US during SAT does not exclude the concomitant presence of suspicious neoplastic nodules, as US changes in SAT might even hide a coexisting thyroid carcinoma or thyroid lymphoma [77,78]. The evaluation of cervical lymphadenopathy can also be challenging because inflammatory lymphadenopathies in SAT are extremely common. However, specific patterns of malignancy, e.g., cystic appearance, hyperechoic punctuations, loss of hilum, and peripheral vascularization of lymph nodes, should raise concerns about the possibility of a coexisting thyroid cancer [79].

A small study conducted by Xie et al. [80] demonstrated that even US elastography cannot provide conclusive information about the differential diagnoses of SAT and thyroid cancer. In fact, especially in the early phase of SAT, because of the intrafollicular cellular infiltration with partial or complete loss of colloid, thyroid tissue shows increased stiffness, which is also a typical finding in thyroid cancer. In SAT, however, a subsequent restoration to normal values is generally observed [81].

Therefore, US follow-up is recommended after symptom resolution and laboratory value normalization to identify an underlying nodular disease [78]. Despite the variety of sonographic interval changes in the lesions, most lesions show progressive regression [82] as well as a reduction in size and number of hypoechoic areas [72]. In some cases, however, hypoechoic areas continue to increase or do not disappear, thus suggesting the need for further medical treatment or possibly identifying early disease recurrence [83].

Thyroid scintigraphy is another valuable option and, especially in the early stages of SAT, it represents the most useful diagnostic tool. Thyroid tissue can absorb and concentrate Iodine-131 (<sup>131</sup>I), and is able to uptake <sup>99m</sup>Tc-pertechnetate [70]. As opposed to cases of increased thyroid function, such as in Graves' disease, typically associated with normal or high thyroid tracer uptake [84], in the case of destructive thyroiditis, such as in SAT, thyroid scintigraphy in the first phase of the disease presents a very low or absent tracer uptake in the thyroid gland; this pattern is common to other forms of destructive thyroiditis (e.g., type-2 amiodarone-induced thyroid dysfunction). The very low radioactive iodine uptake reflects the inability of the damaged thyroid follicles to concentrate iodine [85]. According to the stage of the disease, the tracer uptake loss can be seen in the whole or in part of the gland. It is also possible that even when SAT affects only a certain part of the gland, e.g., one lobe of the thyroid, the scan shows a complete lack of uptake in the whole gland due to the suppression of TSH levels and the consequent lack of stimulation of thyroid cells [86].

The potential of Technetium-99m tetrofosmin and Technetium-99m sestamibi scintigraphy in SAT has been evaluated in few studies. As opposed to <sup>131</sup>I and <sup>99m</sup>Tc-pertechnetate,

which show reduced or absent uptake during the acute stage of SAT, the  $^{99m}\text{Tc}$ -tetrofosmin and  $^{99m}\text{Tc}$  sestamibi thyroid uptake is increased in the SAT destructive phase. The authors suggest that these findings may reflect the ongoing inflammatory process rather than the residual thyroid follicular cell function [87,88].

Other imaging modalities, such as CT scan or magnetic resonance imaging (MRI), are not routinely used as diagnostic tools for various reasons. However, MRI has been used in some selected cases for differential diagnosis of SAT. Few reports described MRI features associated with SAT, in particular, slightly high signal intensity of the thyroid gland on T1-weighted images and markedly increased intensity on T2-weighted images [89], findings that typically disappear on MRI follow-up [90,91].

### 3.7. Cyto-Histopathology

Clinical and laboratory data are usually adequate for SAT diagnosis and fine needle aspiration (FNA) is rarely indicated [92].

Cytological features alone are often non-specific [93] and can vary as the disease stage evolves [94,95], so the interpretation may be challenging, especially because SAT findings can resemble other benign or malignant thyroid lesions [93]. In everyday practice, cytopathology may be useful in selected cases to differentiate SAT from other conditions, such as painful Hashimoto's or Riedel's thyroiditis [96], acute suppurative thyroiditis [97], or malignancies [98]. Correct communication between the endocrinologist and the pathologist is critical so that US and cellular specimen findings can be interpreted in the specific clinical context.

The typical, yet not pathognomonic, histological findings during a full-blown SAT include intra-vacuolar follicular cell granules, epithelioid granulomas, and multinucleated giant cells in an inflammatory background [99]. Degenerated follicular cells with atypia and scant colloid can also be observed [94]. Conversely, fire-flare cells, hypertrophic follicular cells, oncocyctic cells, and transformed lymphocytes are usually absent [99]. As inflammation decreases, a variable range of fibrosis with epithelioid granulomas can be observed, while growth factors promote follicular cell regeneration and thyroid tissue repair [100]. In the late phase of SAT, typical cytological features are fibrous tissue fragments, fibroblasts, regenerative epithelial cells, multinucleated giant cells, and lymphocytes [93].

Multinucleated giant cells and non-caseating granulomas are not entirely specific to SAT and can be observed in other benign and malignant thyroid conditions, such as Hashimoto's thyroiditis, multinodular goiter with degenerative changes, papillary thyroid carcinoma (PTC), and even anaplastic thyroid carcinoma [72,101]. As SAT and PTC can coexist in about 0.5% of patients [102], PTC cytological features (papillary structure, swirl pattern, powdery chromatin, and intranuclear cytoplasmic pseudoinclusions) should be excluded prior to diagnosing SAT [93]. It should be noted that early reactive cellular atypia and late regenerative microfollicles observed in SAT may lead to a false cytological diagnosis [93,95].

As previously described by Lu et al. [103], ultrasonographic improvement of the thyroid echostructure usually occurs earlier than cytologic healing. Nishihara et al. [102] analyzed sequential ultrasonographic and histopathological findings in five SAT cases complicated by PTC. The authors concluded that ultrasonographic precocious hypoechoic lesions observed in SAT could reflect the early inflammatory change (e.g., neutrophilic infiltration). Histological evidence of granulomas and fibrosis was still seen about 3 months after SAT onset; residual fibrosis persisted for several additional months, interestingly with no ultrasonographic evidence of hypoechoic lesions. Further, the authors suggested that the inflammatory and regenerative processes of SAT in thyroid cells did not affect papillary carcinomas [102]. For this reason, if US had been performed during the active SAT phase and suspicious hypoechoic areas had been identified after clinical and biochemical SAT resolution, US re-examination and fine-needle aspiration biopsy (FNAb) of persistent hypoechoic areas of at least 10 mm would be recommended.

### 3.8. Diagnosis

When symptoms, laboratory findings, and imaging are typical, diagnosis seems straightforward, but diagnostic errors could occur. Stasiak et al. [14] recently proposed updated SAT diagnostic criteria. Two main criteria (elevation of ESR or CRP and hypoechoic areas with blurred margin and decreased vascularization at US) should be met, together with at least one additional criterion (hard thyroid swelling, pain and tenderness of the thyroid gland or lobe, elevation of serum FT4 and suppression of TSH, decreased radioiodine uptake, FNAb result typical for SAT).

To note, SAT diagnosis should be considered in patients during or after SARS-CoV-2 infection with unexpected symptoms or laboratory markers of thyrotoxicosis. Besides, SAT can occasionally present without neck pain [1], remarkably so in SAT cases caused by SARS-CoV-2 [104]. Thus, the presence of pain should not be treated as a SAT essential diagnostic criterion. Furthermore, as SAT may be the only manifestation of COVID-19, testing for SARS-CoV-2 infection could be considered in patients with SAT diagnosed during an epidemic flare [14].

Despite the availability of efficient diagnostic tools, differential diagnosis could be challenging, especially for a non-endocrinologist, thus delaying proper diagnosis and treatment [46]. Lack of awareness or recognition of this disorder, e.g., by primary care physicians, may cause misdiagnoses, with the most common error being pharyngitis diagnoses and subsequent antibiotic overuse [46,85]. Indeed, neck pain and laboratory results, especially in SAT cases with no thyrotoxic symptoms, can be easily confused with common infective processes. Two recent studies [46,105] reported a delay in SAT diagnosis of over 2 weeks in 73–82% of cases and unnecessary antibiotic prescriptions in about 47–59% of patients. Furthermore, a lack of improvement in patients' symptoms can lead to repeated visits to different specialists, thus increasing healthcare costs.

The typical symptoms of SAT, such as thyroid pain and tenderness, could be caused by other conditions that hence need to be ruled out, such as painful goiter in Graves' disease [106], thyroid cyst hemorrhage [107], thyroid amyloidosis [2], primary or secondary lymphoma involvement [108], thyroid tuberculosis [109], or malignancy [110,111].

Improper diagnosis of SAT in patients with thyroid malignancies of poor prognosis, in particular anaplastic cancer, non-thyroid cancer infiltrating the gland or metastasizing to the thyroid, is rare but may constitute a life-threatening problem. Besides, these conditions, because of their typical rapid growth, can stretch the capsule and infiltrate surrounding tissue, causing the same neck pain characteristic of SAT [112]. Thus, differentiating these conditions may not be so straightforward. Since SAT can involve the entire thyroid gland but can also present in an asymmetric manner, the disease should be differentiated from a carcinoma, as such asymmetry is also typical of malignancies [48]. Moreover, there is considerable imaging overlap in the two conditions at both US and technetium scans. Thyroid malignancies, such as differentiated thyroid cancer (DTC), or rarer conditions such as medullary thyroid cancer or undifferentiated thyroid carcinoma, have been reported in few cases and thus should be considered for differential diagnosis [93]. A case of leukemic thyroiditis in recurrent acute lymphocytic leukaemia (ALL) mimicking SAT has also been described [113]. The correct diagnosis can be provided by FNAb, evaluated by an experienced cytopathologist, and an adequate US quality examination, thus minimizing unneeded surgery and subsequent morbidity risk [114]. *Ex juvantibus* diagnosis could be reached if a rapid clinical improvement is obtained soon after corticosteroid treatment initiation.

While some authors [111] have suggested that a different diagnosis than SAT should be suspected if pain and swelling do not resolve within 72 h, others [1,115] reported pain relief achievement during SAT in longer periods. Thus, rapid pain improvement is expected during corticosteroid treatment, but no precise cut-off time has been established [111].

It is also important to exclude acute suppurative thyroiditis [116], since this could be worsened by corticosteroid treatment and require antibiotics and/or surgical drain of the abscess. Typical US images in early acute suppurative thyroiditis show unifocal

lesions collection of small amounts of fluid around the affected thyroid lobe with a unifocal hypoechoic lesion [117].

Other possible differential diagnoses are silent thyroiditis and postpartum thyroiditis. SAT is extremely rare during pregnancy. In those cases, however, diagnosis may be tricky and cannot be aided by scintigraphic evaluation, the latter being contraindicated in pregnant women [118].

Graves' disease hyperthyroidism, hashitoxicosis, iodine-induced thyroiditis, checkpoint inhibitor-induced thyroiditis, radiation thyroiditis, or exogenous thyrotoxicosis (factitious or iatrogenic [84]) are other possible differential diagnoses, that could be effectively ruled out with a comprehensive clinical interview and patient evaluation. Urine iodine levels could be helpful in differential diagnosis, with levels lower than 500 mcg/L in SAT and higher in iodide-induced thyroiditis (e.g., amiodarone or other drugs or products containing iodide, iodide contrast agent, . . . ) [7]. In very few cases, Hashimoto's thyroiditis itself can present with a tender goiter or fever (painful Hashimoto's thyroiditis) [119], thus mimicking SAT [120], sometimes with little relief from thyroxine or corticosteroid treatment and with unremitting pain, possibly requiring total thyroidectomy [121].

### 3.9. Treatment

The goals of SAT management are pain relief and symptom control. Treatment guidelines are mostly based on observational data and expert opinion with limited trials being available.

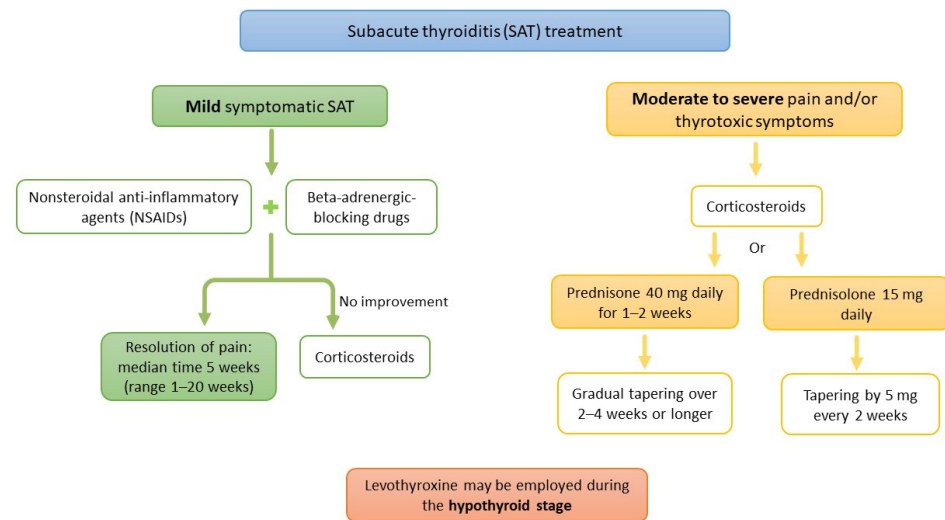
First-line treatment of SAT is based on NSAIDs, such as salicylic acid (600 mg orally every 6 h) or ibuprofen (400 to 800 mg orally every 8 h), for patients with mild to moderate symptoms [122]. Beta-blockers can be used to control thyrotoxic symptoms [122]. Using NSAIDs alone, a complete resolution of pain is expected within 5 weeks, with a reported range of 1 to 20 weeks [1]. Nevertheless, a large retrospective study [123] concluded that NSAIDs fail to provide clinical remission in more than half of SAT patients, with reduced symptomatic relief in patients with higher ESR and CRP levels.

In the case of lack of response to anti-inflammatory therapy and/or in patients with more severe symptoms, second line treatment is represented by corticosteroids that should be started with an initial dose of prednisone 40 mg daily for 1–2 weeks, gradually tapered over 2–4 weeks, or an initial dose of prednisolone 15 mg with tapering by 5 mg every 2 weeks [122,124] (Figure 2). Pain resolution can be obtained faster with steroids rather than with NSAIDs, but if glucocorticoid treatment is tapered too fast or interrupted, a recurrence of pain is often observed, requiring resumption of therapy [1]. SAT exacerbations can also occur after gradual withdrawal of steroid therapy [125], with the need to re-introduce corticosteroids, prolonging treatment duration.

The regimen of about 6 weeks of prednisone has been recommended by international guidelines for SAT treatment [122], but this scheme has been debated in recent years. In a recent trial by Duan and colleagues [126], conducted on patients with moderate-to-severe symptoms of SAT, fewer side effects of glucocorticoids and similar efficacy and recurrence rates were observed with short-term prednisone (30 mg/day prednisone for 1 week, followed by 1 week of NSAIDs) when compared to the 6-week treatment. Other studies proposed the use of prednisolone (PSL), with different initial dosages, such as 30 mg/day [127], 20 mg/day [128], and 15 mg/day [129], resulting in comparable effectiveness and fewer potential side effects. However, 20% of patients that were treated with 15 mg/day as an initial dose required a longer time before discontinuing the glucocorticoid treatment [129]. In another study by Hepsen et al. [130], patients were enrolled in either the 16 or 48 mg methylprednisolone groups, and it was observed that low-dose steroid therapy could as well achieve complete symptom resolution and even better outcomes in SAT. Moreover, the high-dose steroid treatment was associated with a higher rate of recurrence, whereas no difference was observed in permanent hypothyroidism rates between the two groups [130]. Few investigators have also proposed intrathyroidal steroid injection as an alternative therapeutic approach for SAT, suggesting it could provide a faster, safer, and generally



better tolerated approach [131], with most of the patients requiring only one injection to achieve complete cure [131,132].



**Figure 2.** Therapeutic algorithm for the management of subacute thyroiditis (based on ATA recommendation [122]).

Colchicine 1 mg/day, due to the inhibition it can exert on tumor necrosis factor- $\alpha$  and pro-inflammatory cytokines signaling, has been proposed as a therapeutic adjunctive tool in patients with steroid-refractory recurrent SAT [127].

The role of surgery in treating SAT is usually marginal, but described in few reports; Mazza et al. [133] reported an unusual case of SAT resistance to high-dose steroids that was treated with total thyroidectomy. Surgery could thus represent a rare alternative option for a few selected patients with SAT resistant to steroid treatment and with persistent pain [134].

In the single report of this kind in literature, Dumitriu et al. [135] also described very few cases of recurrent SAT treated with radioiodine (RAI). After 2–3 recurrences, occurring despite glucocorticoid treatment, radioiodine was administered with no further relapse.

Eventually, iopanoic acid, ipodate sodium and *Prunella vulgaris* have also been proposed as adjunctive tools in selected cases [107,136].

Levothyroxine could be prescribed in the hypothyroid phase but should be withdrawn during the follow-up, generally in 3 to 6 months; long-term therapy should be prolonged only if hypothyroidism endures. Permanent hypothyroidism rate is not affected by the use of nonsteroidal anti-inflammatory or corticosteroid treatment, but overall, patients that require corticosteroid therapy show more often the need for replacement therapy, probably because of the severity of SAT in such cases [137].

Several studies have focused on the recurrence rates among different treatment groups. A recent systematic review and cohort study meta-analysis [138] reported a pooled SAT recurrence rate of 12.0%, with a higher risk of recurrence in the glucocorticoids group compared to the NSAIDs group. The results of another study showed that SAT recurrence rate during PSL therapy correlated with the number of days required for tapering the dose of PSL to 5 mg/day, but not with the starting dose of PSL, suggesting a relatively longer period of steroid tapering could prevent the recurrence of SAT [139].

### 3.10. Follow-Up

In terms of thyroid dysfunction following SAT, hypothyroidism is the main event, but in most cases, it is temporary. The study of a contemporary and relatively large series of patients with SAT by Benbassat et al. [140] defined that the degree of biochemical thyrotoxicosis is associated with a prolonged disease duration and a more profound hypothyroid phase; in another interesting work carried out retrospectively on 252 patients, Nishihara and colleagues [141] reported that the rates of thyroid dysfunction after SAT were signifi-

cantly lower in patients receiving prednisone. In this study, steroid-treated SAT patients had a higher recurrence rate, but developed permanent hypothyroidism less frequently. Therefore, the authors concluded that steroid therapy should be considered, especially in most severe cases, such as anti-TPO positive SAT patients and patients with high-level ESR and CRP.

The extent of hypoechogenic areas in the thyroid may represent another possible marker for developing thyroid dysfunction after SAT [141]. A small study conducted by Teixeira et al. [142] demonstrated a low thyroid reserve detectable even after five years of follow-up after the spontaneous course of SAT. These findings could be related to the progression towards thyroid fibrosis even in apparently healed patients [142]. Görges et al. [143] investigated the long-term follow-up of SAT for up to 30 years, concluding that one-quarter of patients with SAT develop hypothyroidism in the long term. Recently, a Chinese study [144] reported that patients with higher CRP and lower TSH levels were at a higher risk of developing hypothyroidism. A possible role of TRAb in the development of prolonged hypothyroidism was hypothesized by Tamai et al. [145], in particular regarding TSH-blocking antibodies (TSH-BAb). According to this study, increased TSH-blocking antibody activity was correlated to a prolonged period of hypothyroidism, whereas hypothyroidism without TSH-BAb was more transient [145].

Some studies have described the development of permanent hypothyroidism in about 5–15% of patient with SAT [1,65]. Since this can also occur several years after diagnosis, long-term follow-up, i.e., annual monitoring of thyroid function tests, in these patients is important as late-onset hypothyroidism may occur [65].

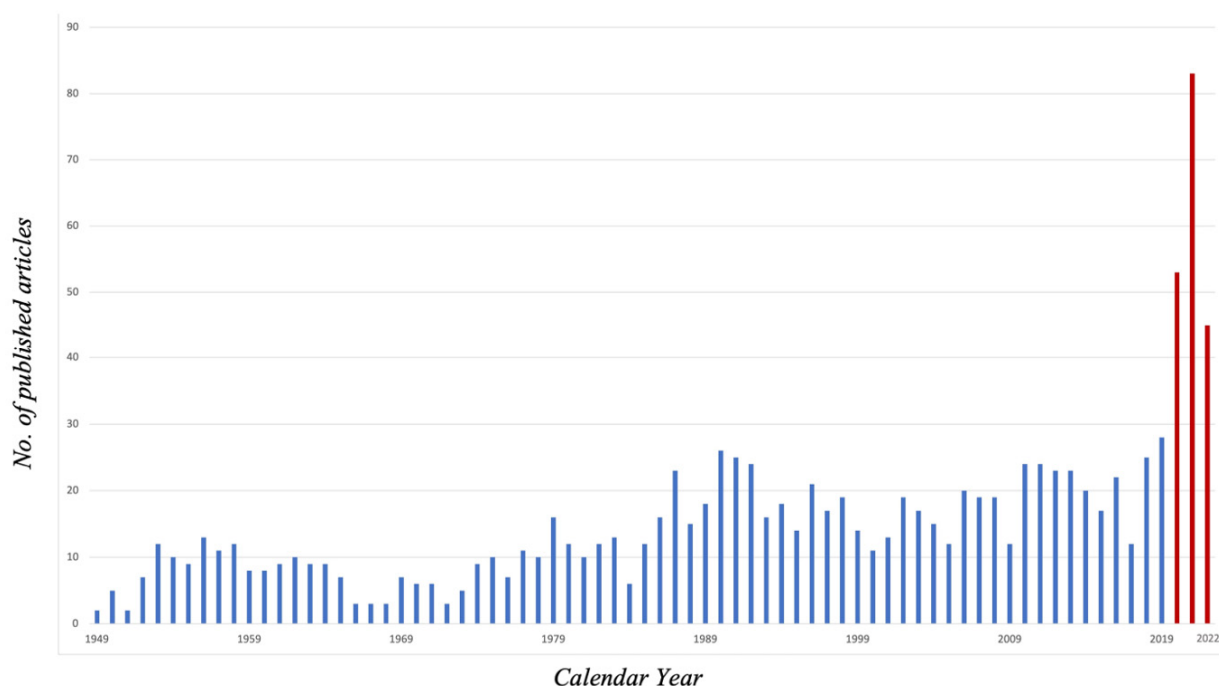
It should also be noted that cases of autoimmune thyroid dysfunction development after SAT have been described [146], including Hashimoto's thyroiditis [147] and Graves' disease onset [148,149], also arising several years after SAT onset [150]. Possibly, destructive thyroiditis, inducing the release of self-antigens, may trigger thyroid autoimmunity.

SAT recurrency is thought to be uncommon, but reported prevalence ranges from 2% [9,12] up to 20% [144], usually occurring within one year after diagnosis. However, late recurrence after several years has also been described, even after more than ten years [9,65,151]. In a recent meta-analysis, Zhang et al. [138] found that in 12% of patients, the disease might relapse. Besides, the recurrence rate in patients treated with steroids seems greater than in those treated with NSAIDs [138]. According to this study, potential predictors of SAT recurrence included treatment-related factors, HLA haplotype, sialic acid level, TSH levels at the end of treatment, and further extension of the US hypoechoic area and increased thyroid volume [138].

Interestingly, the risk of SAT recurrence was demonstrated to be HLA-dependent, and the determining factor was the co-presence of HLA-B\*18:01 and -B\*35 [152]. In such high-risk patients, it is suggested that the steroid treatment regimen should be intensified with a slower dose reduction [152]. The association between the presence of HLA-A\*26 with recurrent SAT has also been reported [151].

### 3.11. SAT and COVID-19

During the SARS-CoV-2 pandemic, SAT emerged as a possible disease triggered by COVID-19. In May and June 2020, during the first SARS-CoV-2 pandemic, two independent reports of SAT induced by SARS-CoV-2 have been published [19,153] and, since then, many case reports or series on this topic were published, determining a substantial increase in articles regarding SAT in the last few years; according to the PubMed database, there has been a peak of 53 articles in 2020, 83 articles in 2021, with already 45 articles in the first months of 2022, showing a substantial increase compared to the previous years (Figure 3).



**Figure 3.** PubMed articles regarding subacute thyroiditis per publication year. Red columns represent years from 2020 to April 2022, since the beginning of COVID-19 pandemic.

SAT may occur due to a direct infection of the gland by SARS-CoV-2, according to the evidence of viral presence in the thyroid [154,155], and supported by the abundant presence of ACE-2 mRNA in thyroid follicular cells [156], which SARS-CoV-2 is able to bind to via the spike protein. Another possible pathogenetic hypothesis may involve the hyperinflammatory status caused by COVID-19 with high levels of cytokines that may trigger thyroid damage.

Whether this association really means causation has been, and still is, a matter of debate. Indeed, this correlation is corroborated by several case reports or series and few retrospective studies: an Italian study evaluated 287 patients affected by COVID-19 requiring hospitalization, reporting thyrotoxicosis in 20% of cases [157]. Such manifestation was possibly caused by SAT destructive thyroiditis, since the clinical course was self-limiting, TSH-receptor autoantibodies were negative and there was correlation with increased levels of serum IL-6, which have been linked with SAT, as previously reported, as with other forms of destructive thyroiditis such as in amiodarone-induced thyrotoxicosis [158] and, more recently, with immune checkpoint inhibitors thyroiditis [159]. A similar result has been reported by Muller et al., who found an increased prevalence of thyrotoxicosis possibly determined by SAT in a cohort of 85 COVID-19 patients admitted to the high intensity of care units (HICUs) as compared to that reported in 78 patients admitted to the same HICUs in 2019 (15% vs. 0.5%) [160]. Other series acknowledging the association of COVID-19 and various thyroid disorders, including SAT, have been published [161]. An interesting systematic review by Trimboli et al. [162] detailed the epidemiology, clinics, and laboratory results of 27 SAT in patients diagnosed with COVID-19. According to this study, neck pain is present in more than 90% of cases and fever in three quarters of patients, with elevation of inflammation indexes; most patients present with suppressed TSH, normal fT3, and moderately high fT4 (median values of 0.01 mU/L, 10.79 pmol/L, and 27.2 pmol/L, respectively); when performed, typical ultrasonographic features of SAT were observed in 83% of cases; most of the patients were treated with steroids and complete remission of SAT was reported in almost all cases.

However, some contrasting studies have also been published. In a UK study including 334 COVID-19 patients, no case of overt thyrotoxicosis, and indeed no case of SAT, has

been recorded [163]. Campi et al. identified 12 out of 115 patients (10.4%) with low TSH at hospital admission for COVID-19, but assumed that such thyroid alteration could have been related to the effect of SARS-CoV-2 on TSH secretion and deiodinase activity, and likely not to a destructive thyroiditis [164]. Pirola et al. [165] did not find an actual increase in the incidence of SAT cases in northern Italy (Brescia) during the first pandemic outbreak; however it should be noted that the COVID outbreak and the consequent lockdown determined a consistent decrease in the diffusion of other respiratory viruses that could be linked to viral SAT. It could be possible, therefore, that the absolute number did not change but SARS-CoV-2 determined most SAT cases that would have been caused by other viruses in the lack of social limitations. According to this hypothesis, Brancatella et al. identified two peaks in 2020 SAT cases which correspond to the SARS-CoV-2 outbreaks in the second and the fourth quarters, in contrast to the previous (2016–2019) SAT cases which peaked in the third quarters, identifying a shift in the annual timing and severity of SAT cases [166].

Variations in prevalence of SAT between centers may be secondary to differences in the setting and severity of patients (e.g., patients admitted to a medicine ward or ICU), timing of evaluation (at admission, during hospitalization or after discharge), medications (pain killers or steroids), and possible use of contrast agents containing iodide. Nevertheless, we believe that enough evidence brings to the conclusion that SAT may be associated with SARS-CoV-2, still it is not a frequent complication, and it should be investigated in case of thyrotoxicosis or suspicious symptoms.

As previously reported, in recent months, many case reports and series on SARS-CoV-2 post-vaccination SAT have been published. Recently, our group published a patient-level systematic review [18] collecting data from 51 patients (48 published patients and three patients evaluated by the authors): epidemiological and clinical features, and the treatment of patients affected by post-vaccination SAT were analogue to SAT classic presentation. Interesting evidence from our review is that all cases of previously diagnosed autoimmune thyroid diseases were in the mRNA-based vaccine group, conceivably identifying a susceptibility to develop SAT after the mRNA SARS-CoV-2 vaccine due to ASIA syndrome, which could be triggered by a personal or familial history of autoimmune diseases [167].

One open question is whether steroid treatment for SAT could impair the immune response to the vaccine; aiming for safety it could be suggested, if SAT symptoms occur shortly after the vaccine shot, to avoid or delay steroid treatment, if feasible, according to symptoms and thyrotoxicosis severity. Moreover, SARS-CoV-2 vaccine-associated SAT typically has a mild or moderate severity course and can be treated in most cases with NSAIDs or steroids; therefore, it should not raise concern regarding the advantages of the vaccination, since the risks of COVID definitely outweigh the risks of the vaccine.

#### 4. Conclusions

SAT is a destructive inflammatory disorder of the thyroid gland determining transient thyrotoxicosis, characterized by neck pain and symptoms caused by thyroid hormone excess. It is usually self-limiting and displays a characteristic triphasic clinical course: an initial thyrotoxic phase, a transient hypothyroidism phase and, in 85% to 95% of patients, the subsequent restoration to baseline thyroid function within 12 months.

Viruses are considered the main trigger of SAT, especially considering its frequent association with recent viral infections of the upper respiratory tract. Genetic susceptibility also seems to have a central function in pathogenesis, as SAT is often associated with some HLA haplotypes, peculiarly, HLA-B35. Thus, all the scientific discoveries on SAT lead to think that the main pathogenetic trigger is a viral infection in genetically predisposed individuals.

SAT presents a wide span of possible differential diagnoses. Notably, false positive diagnoses of SAT in patients with malignancies of poor prognosis may constitute a life-threatening problem. Considerable similarities exist between US characteristics of SAT and malignant thyroid nodules or thyroid lymphoma, such as undefined lesion margins or hypoechogenicity. Therefore, it is recommended that patients with SAT nodular ultrasonographic pattern undergo US not only for the initial evaluation but also after recovery, since

the resolution of US findings alongside the resolution of symptoms is the definitive proof of benignity. FNAb should be considered in selected patients with focal masses to rule out a malignancy and should be performed in all doubtful cases and in patients that show no improvement in the short term. In such cases, the patient's history is of paramount importance and may suggest important clues aiding the differential diagnosis.

First-line treatment for SAT includes anti-inflammatory drugs or steroids. Salicylates and NSAIDs can be used in patients with mild or moderate forms of the disorder, while symptomatic treatment in the acute phase could benefit from  $\beta$ -blockers for thyrotoxic symptoms, whereas methimazole, acting on thyroid hormone production but not on FT4/FT3 peripheral effect, is not useful to reduce the systemic thyroid hormone excess. Glucocorticoid use is recommended in moderate to severe cases, with adequate tapering, and for refractory or severe pain and thyrotoxic symptoms.

The optimal treatment protocol and regimen have been a matter of debate in recent years. Steroids offer faster pain relief and tend to shorten disease duration, but their use has been correlated with higher recurrence rates in different series. Studies have often shown opposing results concerning the correlation of the treatment modalities with permanent hypothyroidism. Since no sure predictive factors have been noticed so far, it is worth remembering that permanent hypothyroidism usually develops within one year after SAT, but given the fact that later onset has also been described, long-term follow-up with annual monitoring of thyroid function tests in these patients is recommended.

Soon after the onset of the recent pandemic, many cases of SAT induced by SARS-CoV-2 have also been published. SAT diagnosis should be considered in patients during or after SARS-CoV-2 infection with typical symptoms or laboratory markers of thyrotoxicosis, even without thyroid pain, which is not always present. As SARS-CoV-2 may trigger different types of thyroid damage [168], thyroid function tests should be performed in most patients hospitalized due to COVID-19, especially in those referred to ICUs. Since SAT may be the only manifestation of COVID-19, testing for SARS-CoV-2 infection could be considered in patients with SAT diagnosed during the pandemic. SAT has also been reported after several vaccinations, including some cases following SARS-CoV-2 vaccination, whether for mRNA, the viral vector, or the inactivated virus vaccine. Potential explanations for post-vaccination SAT have been proposed, yet distinct mechanisms remain unclear, with ASIA syndrome and molecular mimicry currently being the two main pathogenetic hypotheses. The SARS-CoV-2 vaccine-associated SAT is a recent discovery: this condition shares epidemiological and clinical characteristics with the classic post-viral SAT but is triggered by peculiar mechanisms associated with immunization. Though SAT in such cases should not raise concern regarding vaccination, this condition needs to be recognized in order to avoid incongruous treatment, monitor long-term thyroid function, and to notify these cases for pharmacovigilance.

**Author Contributions:** Conceptualization and literature search: S.I. and N.L.; Writing: S.I., N.L., B.P. and G.F.M.F.; Review and editing: S.I., D.G., A.L., E.P. and M.L.T. All authors have read and agreed to the published version of the manuscript.

**Funding:** This research received no external funding.

**Institutional Review Board Statement:** Not applicable.

**Informed Consent Statement:** Not applicable.

**Conflicts of Interest:** The authors declare no conflict of interest.

## References

1. Fatourehchi, V.; Aniszewski, J.P.; Fatourehchi, G.Z.E.; Atkinson, E.J.; Jacobsen, S. Clinical Features and Outcome of Subacute Thyroiditis in an Incidence Cohort: Olmsted County, Minnesota, Study. *J. Clin. Endocrinol. Metab.* **2003**, *88*, 2100–2105. [[CrossRef](#)] [[PubMed](#)]
2. Samuels, M.H. Subacute, silent, and postpartum thyroiditis. *Med. Clin. N. Am.* **2012**, *96*, 223–233. [[CrossRef](#)] [[PubMed](#)]

3. Hiraiwa, T.; Kubota, S.; Imagawa, A.; Sasaki, I.; Ito, M.; Miyauchi, A.; Hanafusa, T. Two cases of subacute thyroiditis presenting in pregnancy. *J. Endocrinol. Investig.* **2006**, *29*, 924–927. [[CrossRef](#)]
4. Bai, C.-F.; Shen, G.-H.; Yang, Y.; Yang, K.; Hayden, M.R.; Zhou, Y.-Y.; Geng, X.-Q. Subacute thyroiditis during early pregnancy: A case report and literature review. *BMC Pregnancy Childbirth* **2022**, *22*, 19. [[CrossRef](#)]
5. Bilbao, N.A.; Kaulfers, A.D.; Bhowmick, S.K. Subacute thyroiditis in a child. *AACE Clin. Case Rep.* **2019**, *5*, 897–900. [[CrossRef](#)] [[PubMed](#)]
6. Ramineni, P.; Kamath, S.P.; Joshi, J.; Rao, S. Subacute thyroiditis with airway compromise in a 5-year-old boy. *BMJ Case Rep.* **2020**, *13*, e236909. [[CrossRef](#)] [[PubMed](#)]
7. Tabassom, A.; Chippa, V.; Edens, M.A. De Quervain Thyroiditis. [Updated 1 May 2022]. In *StatPearls [Internet]*; StatPearls Publishing: Treasure Island, FL, USA, 2022. Available online: <https://www.ncbi.nlm.nih.gov/books/NBK526066/> (accessed on 15 April 2022).
8. Martino, E.; Buratti, L.; Bartalena, L.; Mariotti, S.; Cupini, C.; Aghini-Lombardi, F.; Pinchera, A. High prevalence of subacute thyroiditis during summer season in Italy. *J. Endocrinol. Investig.* **1987**, *10*, 321–323. [[CrossRef](#)]
9. Iitaka, M.; Momotani, N.; Ishii, J.; Ito, K. Incidence of subacute thyroiditis recurrences after a prolonged latency: 24-year survey. *J. Clin. Endocrinol. Metab.* **1996**, *81*, 466–469. [[CrossRef](#)]
10. Oksa, H.; Järvenpää, P.; Metsähonkala, L.; Pasternack, A.; Leinikki, P. No seasonal distribution in subacute de Quervain’s thyroiditis in Finland. *J. Endocrinol. Investig.* **1989**, *12*, 495. [[CrossRef](#)]
11. Greer, M.A. Subacute thyroiditis. *West J. Med.* **1991**, *155*, 83.
12. Nishihara, E.; Ohye, H.; Amino, N.; Takata, K.; Arishima, T.; Kudo, T.; Ito, M.; Kubota, S.; Fukata, S.; Miyauchi, A. Clinical Characteristics of 852 Patients with Subacute Thyroiditis before Treatment. *Intern. Med.* **2008**, *47*, 725–729. [[CrossRef](#)]
13. Calapkulu, M.; Sencar, M.E.; Sakiz, D.; Unsal, I.O.; Ozbek, M.; Cakal, E. The Importance of Vitamin D Level in Subacute Thyroiditis Disease and the Effect of Vitamin D on Disease Prognosis. *Endocr. Pract.* **2020**, *26*, 1062–1069. [[CrossRef](#)] [[PubMed](#)]
14. Stasiak, M.; Lewiński, A. New aspects in the pathogenesis and management of subacute thyroiditis. *Rev. Endocr. Metab. Disord.* **2021**, *22*, 1027–1039. [[CrossRef](#)] [[PubMed](#)]
15. Martínez-Artola, Y.; Poncino, D.; García, M.L.; Munné, M.S.; González, J.; García, D.S. Acute hepatitis E virus infection and association with a subacute thyroiditis. *Ann. Hepatol.* **2015**, *14*, 141–142. [[CrossRef](#)]
16. Assir, M.Z.K.; Jawa, A.; Ahmed, H.I. Expanded dengue syndrome: Subacute thyroiditis and intracerebral hemorrhage. *BMC Infect. Dis.* **2012**, *12*, 240. [[CrossRef](#)]
17. Mo, Z.; Dong, Y.; Chen, X.; Yao, H.; Zhang, B. Acute transverse myelitis and subacute thyroiditis associated with dengue viral infection: A case report and literature review. *Exp. Ther. Med.* **2016**, *12*, 2331–2335. [[CrossRef](#)]
18. Ippolito, S.; Gallo, D.; Rossini, A.; Patera, B.; Lanzo, N.; Fazzino, G.F.M.; Piantanida, E.; Tanda, M.L. SARS-CoV-2 vaccine-associated subacute thyroiditis: Insights from a systematic review. *J. Endocrinol. Investig.* **2022**, *45*, 1189–1200. [[CrossRef](#)]
19. Ippolito, S.; Dentali, F.; Tanda, M.L. SARS-CoV-2: A potential trigger for subacute thyroiditis? Insights from a case report. *J. Endocrinol. Investig.* **2020**, *43*, 1171–1172. [[CrossRef](#)]
20. Stasiak, M.; Tymoniuk, B.; Michalak, R.; Stasiak, B.; Kowalski, M.L.; Lewiński, A. Subacute Thyroiditis is Associated with HLA-B\*18:01, -DRB1\*01 and -C\*04:01—The Significance of the New Molecular Background. *J. Clin. Med.* **2020**, *9*, 534. [[CrossRef](#)]
21. Kramer, A.B.; Roozendaal, C.; Dullaart, R.P. Familial Occurrence of Subacute Thyroiditis Associated with Human Leukocyte Antigen-B35. *Thyroid* **2004**, *14*, 544–547. [[CrossRef](#)]
22. Ohsako, N.; Tamai, H.; Sudo, T.; Mukuta, T.; Tanaka, H.; Kuma, K.; Kimura, A.; Sasazuki, T. Clinical characteristics of subacute thyroiditis classified according to human leukocyte antigen typing. *J. Clin. Endocrinol. Metab.* **1995**, *80*, 3653–3656. [[CrossRef](#)] [[PubMed](#)]
23. Collazos, J.; Gener, B.; de Miguel, J. Bacterial sinusitis associated with subacute, granulomatous thyroiditis. *J. Infect.* **1997**, *34*, 158–159. [[CrossRef](#)]
24. Kim, S.H.; Park, T.S.; Baek, H.S.; Jin, H.Y. Subacute painful thyroiditis accompanied by scrub typhus infection. *Endocrine* **2013**, *44*, 546–548. [[CrossRef](#)] [[PubMed](#)]
25. Abad, S.; Blanche, P.; Moachon, L.; Brunet, A.; Héripert-Fredouille, L.; Sicard, D.; Salmon-Céron, D. Unusual thyroiditis after recombinant interleukin-2 therapy. *Int. J. STD AIDS* **2002**, *13*, 790–791. [[CrossRef](#)] [[PubMed](#)]
26. Cañas, C.A.; Tobón, G.J.; Arango, L.G.; Guarín, N. Developing of granulomatous thyroiditis during etanercept therapy. *Clin. Rheumatol.* **2009**, *28* (Suppl. 1), 17–19. [[CrossRef](#)]
27. Paraná, R.; Cruz, M.; Lyra, L.; Cruz, T. Subacute thyroiditis during treatment with combination therapy (interferon plus ribavirin) for hepatitis C virus. *J. Viral Hepat.* **2000**, *7*, 393–395. [[CrossRef](#)]
28. Sinnott, M.J.; McIntyre, H.D.; Pond, S.M. Granulomatous thyroiditis and lithium therapy. *Aust. N. Z. J. Med.* **1992**, *22*, 84. [[CrossRef](#)]
29. Girgis, C.M.; Russo, R.R.; Benson, K. Subacute thyroiditis following the H1N1 vaccine. *J. Endocrinol. Investig.* **2010**, *33*, 506. [[CrossRef](#)]
30. Altay, F.A.; Güz, G.; Altay, M. Subacute thyroiditis following seasonal influenza vaccination. *Hum. Vaccines Immunother.* **2016**, *12*, 1033–1034. [[CrossRef](#)]
31. Hsiao, J.-Y.; Hsin, S.-C.; Hsieh, M.-C.; Hsia, P.-J.; Shin, S.-J. Subacute Thyroiditis Following Influenza Vaccine (Vaxigrip®) in A Young Female. *Kaohsiung J. Med. Sci.* **2006**, *22*, 297–300. [[CrossRef](#)]

32. Xie, Q.; Mu, X.Y.; Li, S.Q. Subacute Thyroiditis Following HPV Vaccination: A Case Report. *Sichuan Da Xue Xue Bao Yi Xue Ban.* **2021**, *52*, 1047–1048. (In Chinese) [[CrossRef](#)] [[PubMed](#)]
33. Pellegrino, P.; Perrone, V.; Pozzi, M.; Carnovale, C.; Perrotta, C.; Clementi, E.; Radice, S. The epidemiological profile of ASIA syndrome after HPV vaccination: An evaluation based on the Vaccine Adverse Event Reporting Systems. *Immunol. Res.* **2014**, *61*, 90–96. [[CrossRef](#)]
34. Toft, J.; Larsen, S.; Toft, H. Subacute thyroiditis after hepatitis B vaccination. *Endocr. J.* **1998**, *45*, 135. [[PubMed](#)]
35. Alkis, N.; Baysal, M. Subacute thyroiditis after SARS-CoV-2 BNT162b2 vaccine in a multiple myeloma patient. *SAGE Open Med Case Rep.* **2022**, *10*, 2050313X221091392. [[CrossRef](#)]
36. Oyibo, S.O. Subacute Thyroiditis After Receiving the Adenovirus-Vectored Vaccine for Coronavirus Disease (COVID-19). *Cureus* **2021**, *13*, e16045. [[CrossRef](#)] [[PubMed](#)]
37. Iremlı, B.G.; Şendur, S.N.; Ünlütürk, U. Three Cases of Subacute Thyroiditis Following SARS-CoV-2 Vaccine: Postvaccination ASIA Syndrome. *J. Clin. Endocrinol. Metab.* **2021**, *106*, 2600–2605. [[CrossRef](#)]
38. Yorulmaz, G.; Tekin, M.S. SARS-CoV-2 vaccine-associated subacute thyroiditis. *J. Endocrinol. Investig.* **2022**, *45*, 1341–1347. [[CrossRef](#)]
39. Das, L.; Bhadada, S.K.; Sood, A. Post-COVID-vaccine autoimmune/inflammatory syndrome in response to adjuvants (ASIA syndrome) manifesting as subacute thyroiditis. *J. Endocrinol. Investig.* **2021**, *45*, 465–467. [[CrossRef](#)]
40. Shoenfeld, Y.; Agmon-Levin, N. 'ASIA'—Autoimmune/inflammatory syndrome induced by adjuvants. *J. Autoimmun.* **2011**, *36*, 4–8. [[CrossRef](#)]
41. Vojdani, A.; Kharrazian, D. Potential antigenic cross-reactivity between SARS-CoV-2 and human tissue with a possible link to an increase in autoimmune diseases. *Clin. Immunol.* **2020**, *217*, 108480. [[CrossRef](#)]
42. Dotan, A.; Muller, S.; Kanduc, D.; David, P.; Halpert, G.; Shoenfeld, Y. The SARS-CoV-2 as an instrumental trigger of autoimmunity. *Autoimmun. Rev.* **2021**, *20*, 102792. [[CrossRef](#)]
43. Şendur, S.N.; Özmen, F.; Oğuz, S.H.; Iremlı, B.G.; Malkan, Y.; Gürlek, A.; Erbas, T.; Ünlütürk, U. Association of Human Leukocyte Antigen Genotypes with Severe Acute Respiratory Syndrome Coronavirus 2 Vaccine-Induced Subacute Thyroiditis. *Thyroid* **2022**, *32*, 640–647. [[CrossRef](#)] [[PubMed](#)]
44. Stasiak, M.; Zawadzka-Starczewska, K.; Lewiński, A. Clinical Manifestation of Subacute Thyroiditis Triggered by SARS-CoV-2 Infection Can Be HLA-Dependent. *Viruses* **2021**, *13*, 2447. [[CrossRef](#)] [[PubMed](#)]
45. Ginde, A.A.; Mansbach, J.M.; Camargo, C.A., Jr. Association Between Serum 25-Hydroxyvitamin D Level and Upper Respiratory Tract Infection in the Third National Health and Nutrition Examination Survey. *Arch. Intern. Med.* **2009**, *169*, 384–390. [[CrossRef](#)] [[PubMed](#)]
46. Bostan, H.; Sencar, M.E.; Calapkulu, M.; Hepsen, S.; Duger, H.; Unsal, I.O.; Ozbek, M.; Cakal, E. Two Important Issues in Subacute Thyroiditis Management: Delayed Diagnosis and Inappropriate Use of Antibiotics. *Eur. Thyroid J.* **2021**, *10*, 323–329. [[CrossRef](#)] [[PubMed](#)]
47. Sari, O.; Erbaş, B.; Erbaş, T. Subacute thyroiditis in a single lobe. *Clin. Nucl. Med.* **2001**, *26*, 400–401. [[CrossRef](#)] [[PubMed](#)]
48. Zacharia, T.T.; Perumpallichira, J.J.; Sindhvani, V.; Chavhan, G. Gray-scale and color Doppler sonographic findings in a case of subacute granulomatous thyroiditis mimicking thyroid carcinoma. *J. Clin. Ultrasound* **2002**, *30*, 442–444. [[CrossRef](#)]
49. Candrina, R.; Giustina, G. Case Report: Iodine-Induced Subacute Thyroiditis with Thyrotoxicosis Presenting as Fever of Unknown Origin. *Am. J. Med Sci.* **1990**, *300*, 37–40. [[CrossRef](#)]
50. Raj, R.; Yada, S.; Jacob, A.; Unnikrishnan, D.; Ghali, W. Fever of Unknown Origin as a Sole Presentation of Subacute Thyroiditis in an Elderly Patient: A Case Report with Literature Review. *Case Rep. Endocrinol.* **2018**, *2018*, 5041724. [[CrossRef](#)]
51. Bahowairath, F.A.; Woodhouse, N.; Hussain, S.; Al Busaidi, M. Lesson of the month 1: Subacute thyroiditis: A rare cause of fever of unknown origin. *Clin. Med.* **2017**, *17*, 86–87. [[CrossRef](#)]
52. Tsai, C.-H.; Lee, J.-J.; Liu, C.-L.; Tzen, C.-Y.; Cheng, S.-P. Atypical subacute thyroiditis. *Surgery* **2010**, *147*, 461–462. [[CrossRef](#)] [[PubMed](#)]
53. Duhig, T.J.; McKeag, D. Thyroid Disorders in Athletes. *Curr. Sports Med. Rep.* **2009**, *8*, 16–19. [[CrossRef](#)] [[PubMed](#)]
54. Obuobie, K.; Al-Sabah, A.; Lazarus, J. Subacute thyroiditis in an immunosuppressed patient. *J. Endocrinol. Investig.* **2002**, *25*, 169–171. [[CrossRef](#)] [[PubMed](#)]
55. Sakane, S.; Murakami, Y.; Sasaki, M.; Yamano, Y.; Takamatsu, J.; Kuma, K.; Ohsawa, N. Serum Concentrations of Granulocyte Colony-Stimulating Factor (G-CSF) Determined by A Highly-Sensitive Chemiluminescent Immunoassay during the Clinical Course of Subacute Thyroiditis. *Endocr. J.* **1995**, *42*, 391–396. [[CrossRef](#)]
56. Calapkulu, M.; Sencar, M.E.; Sakiz, D.; Duger, H.; Unsal, I.O.; Ozbek, M.; Cakal, E. The prognostic and diagnostic use of hematological parameters in subacute thyroiditis patients. *Endocrine* **2019**, *68*, 138–143. [[CrossRef](#)]
57. Taşkaldıran, I.; Omma, T.; Önder, E.; Firat, S.N.; Koç, G.; Kiliç, M.K.; Kuşkonmaz, M.; Çulha, C. Neutrophil to lymphocyte ratio, Monocyte to lymphocyte ratio, platelet to lymphocyte ratio in different etiological causes of thyrotoxicosis. *Turk. J. Med. Sci.* **2019**, *49*, 1687–1692. [[CrossRef](#)]
58. Cengiz, H.; Varım, C.; Demirci, T.; Cetin, S. Hemogram parameters in the patients with subacute thyroiditis. *Pak. J. Med. Sci.* **2019**, *36*, 240–245. [[CrossRef](#)]

59. Bartalena, L.; Brogioni, S.; Grasso, L.; Martino, E. Increased serum interleukin-6 concentration in patients with subacute thyroiditis: Relationship with concomitant changes in serum T4-binding globulin concentration. *J. Endocrinol. Investig.* **1993**, *16*, 213–218. [CrossRef]
60. Amino, N.; Yabu, Y.; Miki, T.; Morimoto, S.; Kumahara, Y.; Mori, H.; Iwatani, Y.; Nishi, K.; Nakatani, K.; Miyai, K. Serum Ratio of Triiodothyronine to Thyroxine, and Thyroxine-Binding Globulin and Calcitonin Concentrations in Graves' Disease and Destruction- Induced Thyrotoxicosis\*. *J. Clin. Endocrinol. Metab.* **1981**, *53*, 113–116. [CrossRef]
61. Hennessey, J. *Subacute Thyroiditis, Acute and Subacute, and Riedel's Thyroiditis (Endotext [Internet] 2018; MDText.com, Inc.: South Dartmouth, MA, USA, 2018; Available online: <https://www.endotext.org/chapter/subacute-thyroiditis/> (accessed on 15 April 2022).*
62. Tachibana, T.; Orita, Y.; Ogawara, Y.; Matsuyama, Y.; Abe, I.; Nakada, M.; Sato, Y.; Nishizaki, K. Time-lag between symptom onset and laboratory findings in patients with subacute thyroiditis. *Auris Nasus Larynx* **2014**, *41*, 369–372. [CrossRef]
63. Ito, M.; Takamatsu, J.; Yoshida, S.; Murakami, Y.; Sakane, S.; Kuma, K.; Ohsawa, N. Incomplete Thyrotroph Suppression Determined by Third Generation Thyrotropin Assay in Subacute Thyroiditis Compared to Silent Thyroiditis or Hyperthyroid Graves' Disease. *J. Clin. Endocrinol. Metab.* **1997**, *82*, 616–619. [CrossRef] [PubMed]
64. Lio, S.; Pontecorvi, A.; Caruso, M.; Monaco, F.; D'Armiento, M. Transitory subclinical and permanent hypothyroidism in the course of subacute thyroiditis (de Quervain). *Eur. J. Endocrinol.* **1984**, *106*, 67–70. [CrossRef] [PubMed]
65. Engkakul, P.; Mahachoklertwattana, P.; Poomthavorn, P. Eponym. *Eur. J. Pediatr.* **2010**, *170*, 427–431. [CrossRef] [PubMed]
66. Stasiak, M.; Michalak, R.; Stasiak, B.; Lewinski, A. Clinical characteristics of subacute thyroiditis is different than it used to be-current state based on 15 years own material. *Neuro Endocrinol. Lett.* **2019**, *39*, 489–495.
67. Erdem, N.; Erdogan, M.; Ozbek, M.; Karadeniz, M.; Cetinkalp, S.; Ozgen, A.G.; Saygili, F.; Yilmaz, C.; Tuzun, M.; Kabalak, T. Demographic and clinical features of patients with subacute thyroiditis: Results of 169 patients from a single University Center in Turkey. *J. Endocrinol. Investig.* **2007**, *30*, 546–550. [CrossRef]
68. Nishihara, E.; Amino, N.; Kudo, T.; Kohsaka, K.; Ito, M.; Fukata, S.; Nishikawa, M.; Nakamura, H.; Miyauchi, A. Moderate Frequency of Anti-Thyroglobulin Antibodies in the Early Phase of Subacute Thyroiditis. *Eur. Thyroid J.* **2019**, *8*, 268–272. [CrossRef]
69. Prajapati, S.; Hernandez-Prera, J.C. Putting All the Pieces Together: Clinical, Macroscopic and Microscopic Characteristics of Subacute Thyroiditis. *Head Neck Pathol.* **2018**, *13*, 231–234. [CrossRef]
70. Zhuo, L.; Nie, Y.; Ma, L.; Shen, L.; Zhou, X.; Li, F. Diagnostic value of nuclear medicine imaging and ultrasonography in subacute thyroiditis. *Am. J. Transl. Res.* **2021**, *13*, 5629–5634.
71. Mundy-Baird, G.; Kyriacou, A.; Syed, A.A. De Quervain subacute thyroiditis. *Can. Med. Assoc. J.* **2021**, *193*, E1007. [CrossRef]
72. Park, S.Y.; Kim, E.-K.; Kim, M.J.; Kim, B.M.; Oh, K.K.; Hong, S.W.; Park, C.S. Ultrasonographic Characteristics of Subacute Granulomatous Thyroiditis. *Korean J. Radiol.* **2006**, *7*, 229–234. [CrossRef]
73. Kunz, A.; Blank, W.; Braun, B. De Quervain's Subacute Thyroiditis-Colour Doppler Sonography Findings. *Ultraschall der Med.-Eur. J. Ultrasound* **2005**, *26*, 102–106. [CrossRef] [PubMed]
74. Omori, N.; Omori, K.; Takano, K. Association of the Ultrasonographic Findings of Subacute Thyroiditis with Thyroid Pain and Laboratory Findings. *Endocr. J.* **2008**, *55*, 583–588. [CrossRef] [PubMed]
75. Li, J.H.; Daniels, G.H.; Barbesino, G. Painful Subacute Thyroiditis is Commonly Misdiagnosed as Suspicious Thyroid Nodular Disease. *Mayo Clin. Proc. Innov. Qual. Outcomes* **2021**, *5*, 330–337. [CrossRef]
76. Park, H.K.; Kim, D.W.; Lee, Y.J.; Ha, T.K.; Kim, D.H.; Bae, S.K.; Jung, S.J. Suspicious sonographic and cytological findings in patients with subacute thyroiditis: Two case reports. *Diagn. Cytopathol.* **2014**, *43*, 399–402. [CrossRef]
77. Ucan, B.; Delibas, T.; Cakal, E.; Arslan, M.S.; Bozkurt, N.C.; Demirci, T.; Ozbek, M.; Sahin, M. Papillary thyroid cancer case masked by subacute thyroiditis. *Arq. Bras. Endocrinol. Metabol.* **2014**, *58*, 851–854. [CrossRef]
78. Valentini, R.B.; De Macedo, B.M.; Izquierdo, R.F.; Meyer, E.L.S. Painless thyroiditis associated to thyroid carcinoma: Role of initial ultrasonography evaluation. *Arch. Endocrinol. Metab.* **2016**, *60*, 178–182. [CrossRef]
79. Leboulleux, S.; Girard, E.; Rose, M.; Travagli, J.P.; Sabbah, N.; Caillou, B.; Hartl, D.M.; Lassau, N.; Baudin, E.; Schlumberger, M. Ultrasound Criteria of Malignancy for Cervical Lymph Nodes in Patients Followed Up for Differentiated Thyroid Cancer. *J. Clin. Endocrinol. Metab.* **2007**, *92*, 3590–3594. [CrossRef]
80. Xie, P.; Xiao, Y.; Liu, F. Real-time ultrasound elastography in the diagnosis and differential diagnosis of subacute thyroiditis. *J. Clin. Ultrasound* **2011**, *39*, 435–440. [CrossRef]
81. Ruchała, M.; Szczepanek-Parulska, E.; Zybek, A.; Moczko, J.; Czarnywojtek, A.; Kaminski, G.; Sowinski, J. The role of sonoelastography in acute, subacute and chronic thyroiditis: A novel application of the method. *Eur. J. Endocrinol.* **2012**, *166*, 425–432. [CrossRef]
82. Lee, Y.J.; Kim, D.W. Sonographic Characteristics and Interval Changes of Subacute Thyroiditis. *J. Ultrasound Med.* **2016**, *35*, 1653–1659. [CrossRef]
83. Solbiati, L.; Osti, V.; Cova, L.; Tonolini, M. Ultrasound of thyroid, parathyroid glands and neck lymph nodes. *Eur. Radiol.* **2001**, *11*, 2411–2424. [CrossRef] [PubMed]
84. De Leo, S.; Lee, S.Y.; Braverman, L.E. Hyperthyroidism. *Lancet* **2016**, *388*, 906–918. [CrossRef]
85. Peter, S.A. Painful subacute thyroiditis (de Quervain's thyroiditis). *J. Natl. Med. Assoc.* **1992**, *84*, 877. [PubMed]
86. Mariani, G.; Tonacchera, M.; Grosso, M.; Fiore, E.; Falcetta, P.; Montanelli, L.; Bagattini, B.; Vitti, P.; Strauss, H.W. The Role of Nuclear Medicine in the Clinical Management of Benign Thyroid Disorders. Part 2. Nodular Goiter, Hypothyroidism, and Subacute Thyroiditis. *J. Nucl. Med.* **2021**, *62*, 886–895. [CrossRef] [PubMed]



87. Hiromatsu, Y.; Ishibashi, M.; Miyake, I.; Nonaka, K. Technetium-99m tetrofosmin imaging in patients with subacute thyroiditis. *Eur. J. Pediatr.* **1998**, *25*, 1448–1452. [[CrossRef](#)]
88. Hiromatsu, Y.; Ishibashi, M.; Nishida, H.; Kawamura, S.; Kaku, H.; Baba, K.; Kaida, H.; Miyake, I. Technetium-99m Sestamibi Imaging in Patients with Subacute Thyroiditis. *Endocr. J.* **2003**, *50*, 239–244. [[CrossRef](#)]
89. Loevner, L.A. Imaging of the thyroid gland. *Semin. Ultrasound CT MRI* **1996**, *17*, 539–562. [[CrossRef](#)]
90. Jhaveri, K.; Shroff, M.M.; Fatterpekar, G.M.; Som, P.M. CT and MR Imaging Findings Associated with Subacute Thyroiditis. *Am. J. Neuroradiol.* **2003**, *24*, 143–146.
91. Otsuka, N.; Nagai, K.; Morita, K.; Fukunaga, M.; Okazaki, S.; Onishi, M.; Nanba, K.; Sato, M.; Taketa, K. Magnetic resonance imaging of subacute thyroiditis. *Radiat. Med.* **1994**, *12*, 273–276.
92. Yeo, S.; Lee, S.; Hwang, I.; Ahn, E. Subacute Thyroiditis Presenting as a Focal Lesion on [18F] Fluorodeoxyglucose Whole-Body Positron-Emission Tomography/CT. *Am. J. Neuroradiol.* **2010**, *32*, E58–E60. [[CrossRef](#)]
93. Sahin, D.; Akpolat, I. Diagnostic cytological features and differential diagnosis of subacute granulomatous (De Quervain's) thyroiditis. *Diagn. Cytopathol.* **2019**, *47*, 1251–1258. [[CrossRef](#)] [[PubMed](#)]
94. Vural, C.; Paksoy, N.; Gök, N.D.; Yazal, K. Subacute granulomatous (De Quervain's) thyroiditis: Fine-needle aspiration cytology and ultrasonographic characteristics of 21 cases. *Cytojournal* **2015**, *12*, 9. [[CrossRef](#)] [[PubMed](#)]
95. Öfner, C.; Hittmair, A.; Kröll, I.; Bangerl, I.; Zechmann, W.; Totsch, M.; Ladurner, D.; Bocker, W.; Schmid, K.W. Fine Needle Aspiration Cytodiagnosis of Subacute (De Quervain's) Thyroiditis In an Endemic Goitre Area. *Cytopathology* **1994**, *5*, 33–40. [[CrossRef](#)] [[PubMed](#)]
96. Zimmerman, R.S.; Brennan, M.D.; McConahey, W.M.; Goellner, J.R.; Gharib, H. Hashimoto's Thyroiditis: An uncommon cause of painful thyroid unresponsive to corticosteroid therap. *Ann. Intern. Med.* **1986**, *104*, 355–357. [[CrossRef](#)] [[PubMed](#)]
97. Houghton, D.J.; Gray, H.W.; MacKenzie, K. The tender neck: Thyroiditis or thyroid abscess? *Clin. Endocrinol.* **1998**, *48*, 521–524. [[CrossRef](#)]
98. Jin, M.; Kim, T.Y. Anaplastic Thyroid Carcinoma with Initial Ultrasonography Features Mimicking Subacute Thyroiditis. *Endocrinol. Metab.* **2021**, *36*, 201–202. [[CrossRef](#)]
99. García Solano, J.; Giménez Bascuñana, A.; Sola Pérez, J.; Campos Fernández, J.; Martínez Parra, D.; Sánchez Sánchez, C.; Montalbán Romero, S.; Pérez-Guillermo, M. Fine-needle aspiration of subacute granulomatous thyroiditis (De Quervain's thyroiditis): A clinico-cytologic review of 36 cases. *Diagn. Cytopathol.* **1997**, *16*, 214–220. [[CrossRef](#)]
100. Toda, S.; Tokuda, Y.; Koike, N.; Yonemitsu, N.; Watanabe, K.; Koike, K.; Fujitani, N.; Hiromatsu, Y.; Sugihara, H. Growth Factor-Expressing Mast Cells Accumulate at the Thyroid Tissue-Regenerative Site of Subacute Thyroiditis. *Thyroid* **2000**, *10*, 381–386. [[CrossRef](#)]
101. Shabb, N.S.; Salti, I. Subacute thyroiditis: Fine-needle aspiration cytology of 14 cases presenting with thyroid nodules. *Diagn. Cytopathol.* **2005**, *34*, 18–23. [[CrossRef](#)]
102. Nishihara, E.; Hirokawa, M.; Ohye, H.; Ito, M.; Kubota, S.; Fukata, S.; Amino, N.; Miyauchi, A. Papillary Carcinoma Obscured by Complication with Subacute Thyroiditis: Sequential Ultrasonographic and Histopathological Findings in Five Cases. *Thyroid* **2008**, *18*, 1221–1225. [[CrossRef](#)]
103. Lu, C.-P.; Chang, T.-C.; Wang, C.-Y.; Hsiao, Y.-L. Serial Changes in Ultrasound-Guided Fine Needle Aspiration Cytology in Subacute Thyroiditis. *Acta Cytol.* **1997**, *41*, 238–243. [[CrossRef](#)] [[PubMed](#)]
104. Christensen, J.; O'Callaghan, K.; Sinclair, H.; Hawke, K.; Love, A.; Hajkovicz, K.; Stewart, A.G. Risk factors, treatment and outcomes of subacute thyroiditis secondary to COVID-19: A systematic review. *Intern. Med. J.* **2021**, *52*, 522–529. [[CrossRef](#)] [[PubMed](#)]
105. Stasiak, M.; Michalak, R.; Stasiak, B.; Lewiński, A. Time-Lag Between Symptom Onset and Diagnosis of Subacute Thyroiditis—How to Avoid the Delay of Diagnosis and Unnecessary Overuse of Antibiotics. *Horm. Metab. Res.* **2019**, *52*, 32–38. [[CrossRef](#)] [[PubMed](#)]
106. Chao, C.-S.; Lin, S.-Y.; Sheu, W.H.-H. Graves' Disease Presented as Painful Goiter. *Horm. Res. Paediatr.* **2002**, *57*, 53–56. [[CrossRef](#)] [[PubMed](#)]
107. Ross, D.S. Syndromes of thyrotoxicosis with low radioactive iodine uptake. *Endocrinol. Metab. Clin. N. Am.* **1998**, *27*, 169–185. [[CrossRef](#)]
108. Guarda, M.L.A.; Baskin, M.H.J. Inflammatory and Lymphoid Lesions of the Thyroid Gland: Cytopathology by Fine-Needle Aspiration. *Am. J. Clin. Pathol.* **1987**, *87*, 14–22. [[CrossRef](#)]
109. Gupta, N.; Sharma, K.; Barwad, A.; Sharma, M.; Rajwanshi, A.; Dutta, P.; Sharma, A. Thyroid tuberculosis-role of PCR in diagnosis of a rare entity. *Cytopathology* **2010**, *22*, 392–396. [[CrossRef](#)]
110. Kasagi, K. Painful Hashimoto's Thyroiditis. *Intern. Med.* **2006**, *45*, 351–352. [[CrossRef](#)]
111. Meier, D.A.; Nagle, C.E. Differential diagnosis of a tender goiter. *J. Nucl. Med.* **1996**, *37*, 1745.
112. Stasiak, M.; Michalak, R.; Lewinski, A. Thyroid primary and metastatic malignant tumours of poor prognosis may mimic subacute thyroiditis-time to change the diagnostic criteria: Case reports and a review of the literature. *BMC Endocr. Disord.* **2019**, *19*, 86. [[CrossRef](#)]
113. Byrd, J.C.; Dow, N.S.; Gaertner, E.; Hargis, J.B.; Raber, T.R.; Burrell, L.; Weiss, R.B. Leukemic thyroiditis as the initial relapsing sign in a patient with acute lymphocytic leukemia and blast expression of the neural cell adhesion molecule. *Am. J. Hematol.* **1997**, *55*, 212–215. [[CrossRef](#)]

114. Ranganath, R.; Shaha, M.A.; Xu, B.; Migliacci, J.; Ghossein, R.; Shaha, A.R. de Quervain's thyroiditis: A review of experience with surgery. *Am. J. Otolaryngol.* **2016**, *37*, 534–537. [[CrossRef](#)] [[PubMed](#)]
115. Sato, J.; Uchida, T.; Komiya, K.; Goto, H.; Takeno, K.; Suzuki, R.; Honda, A.; Himuro, M.; Watada, H. Comparison of the therapeutic effects of prednisolone and nonsteroidal anti-inflammatory drugs in patients with subacute thyroiditis. *Endocrine* **2016**, *55*, 209–214. [[CrossRef](#)] [[PubMed](#)]
116. Szabo, S.M.; Allen, D.B. Thyroiditis. Differentiation of acute suppurative and subacute. Case report and review of the literature. *Clin. Pediatr.* **1989**, *28*, 171–174. [[CrossRef](#)] [[PubMed](#)]
117. Masuoka, H.; Miyauchi, A.; Tomoda, C.; Inoue, H.; Takamura, Y.; Ito, Y.; Kobayashi, K.; Miya, A. Imaging Studies in Sixty Patients with Acute Suppurative Thyroiditis. *Thyroid* **2011**, *21*, 1075–1080. [[CrossRef](#)] [[PubMed](#)]
118. Anastasilakis, A.D.; Karanicola, V.; Kourtis, A.; Makras, P.; Kampas, L.; Gerou, S.; Giomisi, A. A case report of subacute thyroiditis during pregnancy: Difficulties in differential diagnosis and changes in cytokine levels. *Gynecol. Endocrinol.* **2010**, *27*, 384–390. [[CrossRef](#)]
119. Doniach, D.; Hudson, R.V.; Roitt, I.M. Human Auto-immune Thyroiditis: Clinical Studies. *BMJ* **1960**, *1*, 365–373. [[CrossRef](#)]
120. Seo, H.M.; Kim, M.; Bae, J.; Kim, J.-H.; Lee, J.W.; Lee, S.A.; Koh, G.; Lee, D.H. A Case of Painful Hashimoto Thyroiditis that Mimicked Subacute Thyroiditis. *Chonnam Med. J.* **2012**, *48*, 69–72. [[CrossRef](#)]
121. Kon, Y.C.; DeGroot, L.J. Painful Hashimoto's Thyroiditis as an Indication for Thyroidectomy: Clinical Characteristics and Outcome in Seven Patients. *J. Clin. Endocrinol. Metab.* **2003**, *88*, 2667–2672. [[CrossRef](#)]
122. Ross, D.S.; Burch, H.B.; Cooper, D.S.; Greenlee, M.C.; Laurberg, P.; Maia, A.L.; Rivkees, S.A.; Samuels, M.; Sosa, J.A.; Stan, M.N.; et al. 2016 American Thyroid Association Guidelines for Diagnosis and Management of Hyperthyroidism and Other Causes of Thyrotoxicosis. *Thyroid* **2016**, *26*, 1343–1421. [[CrossRef](#)]
123. Sencar, M.E.; Calapkulu, M.; Sakiz, D.; Hepsen, S.; Kus, A.; Akhanli, P.; Unsal, I.O.; Kizilgul, M.; Ucan, B.; Ozbek, M.; et al. An Evaluation of the Results of the Steroid and Non-steroidal Anti-inflammatory Drug Treatments in Subacute Thyroiditis in relation to Persistent Hypothyroidism and Recurrence. *Sci. Rep.* **2019**, *9*, 16899. [[CrossRef](#)] [[PubMed](#)]
124. Volpé, R. The Management of Subacute (DeQuervain's) Thyroiditis. *Thyroid* **1993**, *3*, 253–255. [[CrossRef](#)] [[PubMed](#)]
125. Topuzovic, N.; Smoje, J.; Karner, I. The therapeutic approach in subacute (de Quervain's) thyroiditis. *J. Nucl. Med.* **1997**, *38*, 1665. [[PubMed](#)]
126. Duan, L.; Feng, X.; Zhang, R.; Tan, X.; Xiang, X.; Shen, R.; Zheng, H. Short-Term Versus 6-Week Prednisone In The Treatment Of Subacute Thyroiditis: A Randomized Controlled Trial. *Endocr. Pract.* **2020**, *26*, 900–908. [[CrossRef](#)] [[PubMed](#)]
127. Tian, Z.; Su, Y.; Zhang, M.; Zhang, X.; Guan, Q. Successful Management of Recurrent Subacute Thyroiditis by Adding Colchicine to Glucocorticoid Treatment: A Case Series Study. *Horm. Metab. Res.* **2020**, *52*, 712–717. [[CrossRef](#)]
128. Koirala, K.P. Treatment of Acute Painful Thyroiditis with Low Dose Prednisolone: A Study on Patients from Western Nepal. *J. Clin. Diagn. Res.* **2015**, *9*, MC01. [[CrossRef](#)]
129. Kubota, S.; Nishihara, E.; Kudo, T.; Ito, M.; Amino, N.; Miyauchi, A. Initial Treatment with 15 mg of Prednisolone Daily Is Sufficient for Most Patients with Subacute Thyroiditis in Japan. *Thyroid* **2013**, *23*, 269–272. [[CrossRef](#)]
130. Hepsen, S.; Akhanli, P.; Sencar, M.E.; Duger, H.; Sakiz, D.; Kizilgul, M.; Unsal, I.O.; Ucan, B.; Ozbek, M.; Cakal, E. The Evaluation of Low- and High-Dose Steroid Treatments in Subacute Thyroiditis: A Retrospective Observational Study. *Endocr. Pract.* **2020**, *27*, 594–600. [[CrossRef](#)]
131. Li, J.; Zhang, J.; Jiang, L.; Li, Z.; Li, F.; Chen, H.; Feng, L. Efficacy and safety of ultrasound-guided intrathyroidal injection of glucocorticoids versus routine oral administration of glucocorticoids for subacute thyroiditis: Protocol of systematic review and meta-analysis. *Medicine* **2019**, *98*, e18564. [[CrossRef](#)]
132. Forkert, I.O.; Melekhovets, O.K.; Kalynychenko, D.O.; Melekhovets, Y.V.; Kovalenko, E.L. Painful subacute thyroiditis treatment approach. *Wiad. Lek.* **2021**, *74*, 1921–1924. [[CrossRef](#)]
133. Mazza, E.; Quaglino, F.; Suriani, A.; Palestini, N.; Gottero, C.; Leli, R.; Taraglio, S. Thyroidectomy for Painful Thyroiditis Resistant to Steroid Treatment: Three New Cases with Review of the Literature. *Case Rep. Endocrinol.* **2015**, *2015*, 138327. [[CrossRef](#)]
134. Duinink, T.M.; van Heerden, J.A.; Fatourechi, V.; Curlee, K.J.; Farley, D.R.; Thompson, G.B.; Grant, C.S.; Lloyd, R.V. De Quervain's Thyroiditis: Surgical Experience. *Endocr. Pract.* **2002**, *8*, 255–258. [[CrossRef](#)]
135. Dumitriu, L.; Gudovan, E.; Ursu, H. Radioiodine treatment in recurrences of subacute thyroiditis. *Endocrinologie* **1990**, *28*, 21–23. [[PubMed](#)]
136. Shen, X.; Yang, R.; An, J.; Zhong, X. Analysis of the Molecular Mechanisms of the Effects of *Prunella vulgaris* against Subacute Thyroiditis Based on Network Pharmacology. *Evid.-Based Complement. Altern. Med.* **2020**, *2020*, 9810709. [[CrossRef](#)] [[PubMed](#)]
137. Saklamaz, A. Is There a Drug Effect on the Development of Permanent Hypothyroidism in Subacute Thyroiditis? *Acta Endocrinol.* **2017**, *13*, 119–123. [[CrossRef](#)] [[PubMed](#)]
138. Zhang, J.; Ding, G.; Li, J.; Li, X.; Ding, L.; Li, X.; Yang, S.; Tang, F. Risk Factors for Subacute Thyroiditis Recurrence: A Systematic Review and Meta-Analysis of Cohort Studies. *Front. Endocrinol.* **2021**, *12*, 783439. [[CrossRef](#)]
139. Arao, T.; Okada, Y.; Torimoto, K.; Kurozumi, A.; Narisawa, M.; Yamamoto, S.; Tanaka, Y. Prednisolone Dosing Regimen for Treatment of Subacute Thyroiditis. *J. UOEH* **2015**, *37*, 103–110. [[CrossRef](#)]
140. Benbassat, C.A.; Olchovsky, D.; Tsvetov, G.; Shimon, I. Subacute thyroiditis: Clinical characteristics and treatment outcome in fifty-six consecutive patients diagnosed between 1999 and 2005. *J. Endocrinol. Investig.* **2007**, *30*, 631–635. [[CrossRef](#)]

141. Nishihara, E.; Amino, N.; Ohye, H.; Ota, H.; Ito, M.; Kubota, S.; Fukata, S.; Miyauchi, A. Extent of hypoechogenic area in the thyroid is related with thyroid dysfunction after subacute thyroiditis. *J. Endocrinol. Investig.* **2009**, *32*, 33–36. [[CrossRef](#)]
142. Teixeira, V.L.; Romaldini, J.; Rodrigues, H.F.; Tanaka, L.M.; Farah, C.S. Thyroid function during the spontaneous course of subacute thyroiditis. *J. Nucl. Med.* **1985**, *26*, 457–460.
143. Görges, J.; Ulrich, J.; Keck, C.; Müller-Wieland, D.; Diederich, S.; Janssen, O.E. Long-term Outcome of Subacute Thyroiditis. *Exp. Clin. Endocrinol. Diabetes* **2019**, *128*, 703–708. [[CrossRef](#)] [[PubMed](#)]
144. Tang, C.; Dong, Y.; Lu, L.; Zhang, N. C-reactive protein and thyroid-stimulating hormone levels as risk factors for hypothyroidism in patients with subacute thyroiditis. *Endocr. Connect.* **2021**, *10*, 965–972. [[CrossRef](#)] [[PubMed](#)]
145. Tamai, H.; Nozaki, T.; Mukuta, T.; Morita, T.; Matsubayashi, S.; Kuma, K.; Kumagai, L.F.; Nagataki, S. The Incidence of Thyroid Stimulating Blocking Antibodies during the Hypothyroid Phase in Patients with Subacute Thyroiditis. *J. Clin. Endocrinol. Metab.* **1991**, *73*, 245–250. [[CrossRef](#)] [[PubMed](#)]
146. Mathew, A.A.; Papaly, R.; Maliakal, A.; Chandra, L.; Antony, M.A. Elevated Graves' Disease-Specific Thyroid-Stimulating Immunoglobulin and Thyroid Stimulating Hormone Receptor Antibody in a Patient with Subacute Thyroiditis. *Cureus* **2021**, *13*, e19448. [[CrossRef](#)]
147. Minciullo, P.L.; Ruggeri, R.M.; Vita, G.; Benvenega, S.; Gangemi, S. Development of Hashimoto's Thyroiditis After Subacute Thyroiditis: An Unusual Patient. *Thyroid* **2009**, *19*, 73–74. [[CrossRef](#)]
148. Iitaka, M.; Kakinuma, S.; Yamanaka, K.; Fujimaki, S.; Oosuga, I.; Wada, S.; Katayama, S. Induction of Autoimmune Hypothyroidism and Subsequent Hyperthyroidism by TSH Receptor Antibodies following Subacute Thyroiditis: A Case Report. *Endocr. J.* **2001**, *48*, 139–142. [[CrossRef](#)]
149. Hallengren, B.; Planck, T.; Åsman, P.; Lantz, M. Presence of Thyroid-Stimulating Hormone Receptor Antibodies in a Patient with Subacute Thyroiditis followed by Hypothyroidism and Later Graves' Disease with Ophthalmopathy: A Case Report. *Eur. Thyroid J.* **2015**, *4*, 197–200. [[CrossRef](#)]
150. Fukata, S.; Matsuzuka, F.; Kobayashi, A.; Hirai, K.; Kuma, K.; Sugawara, M. Development of Graves' disease after subacute thyroiditis: Two unusual cases. *Eur. J. Endocrinol.* **1992**, *126*, 495–496. [[CrossRef](#)]
151. Yamamoto, M.; Saito, S.; Sakurada, T.; Tamura, M.; Kudo, Y.; Yoshida, K.; Kaise, K.; Kaise, N.; Fukazawa, H.; Itagaki, Y.; et al. Recurrence of Subacute Thyroiditis Over 10 Years after the First Attack in Three Cases. *Endocrinol. Jpn.* **1988**, *35*, 833–839. [[CrossRef](#)]
152. Stasiak, M.; Tymoniuk, B.; Stasiak, B.; Lewiński, A. The Risk of Recurrence of Subacute Thyroiditis Is HLA-Dependent. *Int. J. Mol. Sci.* **2019**, *20*, 1089. [[CrossRef](#)]
153. Brancatella, A.; Ricci, D.; Viola, N.; Sgrò, D.; Santini, F.; Latrofa, F. Subacute Thyroiditis After Sars-COV-2 Infection. *J. Clin. Endocrinol. Metab.* **2020**, *105*, 2367–2370. [[CrossRef](#)] [[PubMed](#)]
154. Tanda, M.L.; Ippolito, S.; Gallo, D.; Baj, A.; Novazzi, F.; Genoni, A.; Annoni, M.; Mancini, N.; Clementi, N.; Finzi, G.; et al. SARS-CoV-2 detection in primary thyroid sarcoma: Coincidence or interaction? *J. Endocrinol. Investig.* **2022**, *45*, 1059–1063. [[CrossRef](#)] [[PubMed](#)]
155. Poma, A.M.; Bonuccelli, D.; Giannini, R.; Macerola, E.; Vignali, P.; Ugolini, C.; Torregrossa, L.; Proietti, A.; Pistello, M.; Basolo, A.; et al. COVID-19 autopsy cases: Detection of virus in endocrine tissues. *J. Endocrinol. Investig.* **2021**, *45*, 209–214. [[CrossRef](#)] [[PubMed](#)]
156. Rotondi, M.; Coperchini, F.; Ricci, G.; Denegri, M.; Croce, L.; Ngnitejeu, S.T.; Villani, L.; Magri, F.; Latrofa, F.; Chiovato, L. Detection of SARS-COV-2 receptor ACE-2 mRNA in thyroid cells: A clue for COVID-19-related subacute thyroiditis. *J. Endocrinol. Investig.* **2020**, *44*, 1085–1090. [[CrossRef](#)]
157. Lania, A.; Sandri, M.T.; Cellini, M.; Mirani, M.; Lavezzi, E.; Mazziotti, G. Thyrotoxicosis in patients with COVID-19: The thyrcov study. *Eur. J. Endocrinol.* **2020**, *183*, 381–387. [[CrossRef](#)]
158. Bartalena, L.; Grasso, L.; Brogioni, S.; Aghini-Lombardi, F.; Braverman, L.E.; Martino, E. Serum interleukin-6 in amiodarone-induced thyrotoxicosis. *J. Clin. Endocrinol. Metab.* **1994**, *78*, 423–427. [[CrossRef](#)]
159. Ippolito, S.; Di Dalmazi, G.; Pani, F.; Sabini, E.; Caturegli, P. Distinct Cytokine Signatures in Thyroiditis Induced by PD-1 or CTLA-4 Blockade: Insights from a New Mouse Model. *Thyroid* **2021**, *31*, 1839–1849. [[CrossRef](#)]
160. Muller, I.; Cannavaro, D.; Dazzi, D.; Covelli, D.; Mantovani, G.; Muscatello, A.; Ferrante, E.; Orsi, E.; Resi, V.; Longari, V.; et al. SARS-CoV-2-related atypical thyroiditis. *Lancet Diabetes Endocrinol.* **2020**, *8*, 739–741. [[CrossRef](#)]
161. Lui, D.T.W.; Lee, C.H.; Chow, W.S.; Lee, A.C.H.; Tam, A.R.; Fong, C.H.Y.; Law, C.Y.; Leung, E.K.H.; To, K.K.W.; Tan, K.C.B.; et al. Thyroid Dysfunction in Relation to Immune Profile, Disease Status, and Outcome in 191 Patients with COVID-19. *J. Clin. Endocrinol. Metab.* **2020**, *106*, e926–e935. [[CrossRef](#)]
162. Trimboli, P.; Cappelli, C.; Croce, L.; Scappaticcio, L.; Chiovato, L.; Rotondi, M. COVID-19-Associated Subacute Thyroiditis: Evidence-Based Data From a Systematic Review. *Front. Endocrinol.* **2021**, *12*, 707726. [[CrossRef](#)]
163. Khoo, B.; Tan, T.; Clarke, S.A.; Mills, E.G.; Patel, B.; Modi, M.; Phylactou, M.; Eng, P.C.; Thurston, L.; Alexander, E.C.; et al. Thyroid Function Before, During, and After COVID-19. *J. Clin. Endocrinol. Metab.* **2020**, *106*, e803–e811. [[CrossRef](#)] [[PubMed](#)]
164. Campi, I.; Bulgarelli, I.; Dubini, A.; Perego, G.B.; Tortorici, E.; Torlasco, C.; Torresani, E.; Rocco, L.; Persani, L.; Fugazzola, L. The spectrum of thyroid function tests during hospitalization for SARS COV-2 infection. *Eur. J. Endocrinol.* **2021**, *184*, 699–709. [[CrossRef](#)] [[PubMed](#)]

165. Pirola, I.; Gandossi, E.; Rotondi, M.; Marini, F.; Cristiano, A.; Chiovato, L.; Castellano, M.; Ferlin, A.; Cappelli, C. Incidence of De Quervain's thyroiditis during the COVID-19 pandemic in an area heavily affected by Sars-CoV-2 infection. *Endocrine* **2021**, *74*, 215–218. [[CrossRef](#)] [[PubMed](#)]
166. Brancatella, A.; Viola, N.; Rutigliano, G.; Sgrò, D.; Santini, F.; Latrofa, F. Subacute thyroiditis at the time of SARS-CoV-2 pandemic. *J. Endocr. Soc.* **2021**, *5*, bvab130. [[CrossRef](#)]
167. Bragazzi, N.L.; Hejly, A.; Watah, A.; Adawi, M.; Amital, H.; Shoenfeld, Y. ASIA syndrome and endocrine autoimmune disorders. *Best Pract. Res. Clin. Endocrinol. Metab.* **2020**, *34*, 101412. [[CrossRef](#)]
168. Ruggeri, R.M.; Campenni, A.; Deandrei, D.; Siracusa, M.; Tozzoli, R.; Petranović Ovčariček, P.; Giovanella, L. SARS-CoV-2-related immune-inflammatory thyroid disorders: Facts and perspectives. *Expert Rev. Clin. Immunol.* **2021**, *17*, 737–759. [[CrossRef](#)]