

Original Research Article

Retinal abnormalities in children suffering from low hemoglobin levels

Sharda Punjabi, Gauri Devasthali*, Archana Gulati

Department of Ophthalmology, Geetanjali Medical College and Hospital, Udaipur, Rajasthan, India

Received: 11 January 2021

Accepted: 19 January 2021

***Correspondence:**

Dr. Gauri Devasthali,

E-mail: Gauridevasthali95@gmail.com

Copyright: © the author(s), publisher and licensee Medip Academy. This is an open-access article distributed under the terms of the Creative Commons Attribution Non-Commercial License, which permits unrestricted non-commercial use, distribution, and reproduction in any medium, provided the original work is properly cited.

ABSTRACT

Background: Anemia is a major public health problem with total prevalence of 30%. It is one of the hematological disorders which can induce retinal changes that are due to retinal hypoxia that leads to nerve fiber layer infarction. Other change includes increased vascular permeability, venous stasis, angiospasm and increased blood viscosity.

Methods: This is the cross-sectional study that includes 230 children with age group of 1 to 15 years having hemoglobin levels less than 10 gm/dl referred to eye OPD. Ocular examination was done which included-visual acuity, anterior segment, dilated fundus examination.

Results: Retinopathy was observed in 95% children of severe anemia and 84% children of moderate anemia. Common findings observed vascular changes, dot blot hemorrhages, flame shaped hemorrhages, sub hyaloids hemorrhages, disc pallor and macular edema.

Conclusions: Retinopathy is a frequent finding seen in moderate to severe anemic patients, as the retinal changes were found significantly in maximum patients, it is recommended that all anemic patients particular Hb less than 10 g/dl must undergo routine fundus examinations.

Keywords: Anemia, Venous tortuosity, Flame shaped hemorrhages, Dot blot hemorrhages, Sub hyaloid hemorrhages, Macular edema, Disc pallor

INTRODUCTION

Anemia is a major public health problem worldwide current data suggest that total prevalence of anemia worldwide is 30% and for developing countries it is 36%. Young children and pregnant women are the most affected groups with an estimated global prevalence of 43 and 51% respectively, followed by school age children 37%, adult females (including pregnant) 35% and adult males 18%.¹

According to WHO anemia in pediatric age group can be classified into mild, moderate and severe on the basis of hemoglobin concentration, mild anemia=10-13 g/dl, moderate anemia=7-10 g/dL and severe anemia is below 7 g/dL.² Micronutrient deficiency (especially iron deficiency) and parasitic infections (specially malaria) have been found to be the main culprits of anemia. Other

etiologies include: inadequate diet, haemoglobinopathies (sickle cell anemia, thalassemia), infections (intestinal helminths like hookworm, *Ascaris lumbricoides*).³

Anemia is a hematological disorder which can induce retinopathy. Pathological changes in anemic retinopathy are mainly due to retinal hypoxia leading to nerve fiber layer infarction and other changes like increased blood viscosity, angiospasm, venous stasis and increased vascular permeability.⁴

In anemia retinal changes can be in the form of disc pallor, retinal hemorrhages; Roth spots, dot blot hemorrhage, flame shaped hemorrhage, sub hyaloids hemorrhage, vascular changes (venous dilatation and tortuosity) and macular oedema.

Other than retinopathy various ocular manifestations of anemia are conjunctival pallor followed by visual disturbances, lid oedema, subconjunctival haemorrhage.⁵

Prevalence of retinopathy is 28.3% in severe anemia and 38% among the patients with concomitant anemia and thrombocytopenia.⁶

Aim of the study was to evaluate the prevalence of anemic retinopathy in children (1-15 years of age) suffering from moderate to severe anemia presenting to the ophthalmology outpatient department (OPD) of Geetanjali medical college and hospital Rajasthan.

METHODS

A cross-sectional of patients having hemoglobin less than 10 g/dl was done between 1st February to 30th November 2020 at Geetanjali medical college and hospital Rajasthan.

Inclusion criteria

All the anemic children between age group 1 to 15 years having hemoglobin <10 gm/dl were included in the study.

Exclusion criteria

All children whose parents refused consent, severely sick and bed ridden patients, patients diagnosed with bacterial endocarditis, diabetes, hypertension were excluded from the study.

All anemic children presenting to eye O.P.D or referred from pediatric O.P.D at Geetanjali medical college and hospital having hemoglobin <10 gm/dl were included in study. After taking informed consent from guardian, detailed history including the patient’s age, sex, hemoglobin level, menstrual history and systemic diseases was recorded for all cases. A brief general and systemic examination was carried out. Cases were categorized into moderate and severe anemia according to hemoglobin levels.

Ocular examination included: The best corrected visual acuity in school going children was assessed using log mar chart for distant vision and Jaeger’s chart for near vision. Teller’s visual acuity cards were used for less than 5-year children. Dry or wet retinoscopy was done accordingly, periorbital skin and eyelids were examined under diffuse light, slit lamp examination was done for conjunctival and corneal lesions along with anterior segment evaluation, twice instillation of mydriatic eyedrops at interval of 15 minutes {tropicamide (0.8%) and phenylephrine (5%)} was done for dilatation of pupils. Dilated fundus examination with the help of indirect ophthalmoscopy with 20D/28D lens was done. Fundus photography was done accordingly and data was entered in Microsoft excel and analysis was done using SPSS version 20. Descriptive statistical analysis was

done. Results on categorical measurements were presented as percentages.

RESULTS

According to our study we observed that retinal hemorrhages were the commonest ocular manifestation present in about 49% cases followed by vascular changes (39%), disc pallor (11%) and macular edema (1%). Flame shaped hemorrhages were commonest out of all hemorrhages found of 30% and 10% in moderate and severe anemia respectively. Second commonest hemorrhage noted was dot and blot type observed in 14% and 17% cases of moderate and severe anemia respectively. Roth spots were seen in 5% and 15% cases of moderate and severe anemia respectively. Sub hyaloids hemorrhage was found in 10% cases of severe anemia. The results were statistically significant for disc pallor, vascular changes, Roth spots, sub hyaloids hemorrhages (p<0.05).

Table 1: Frequency and types of retinal abnormalities in anaemic retinopathy.

Anemic retinopathy	Moderate anemia (%)	Severe anemia (%)	P
Flame shaped hemorrhages	53 (30)	2 (10)	0.12
Dot blot hemorrhages	24 (14)	4 (17)	0.524
Roth spots hemorrhages	9 (5)	3 (15)	0.002
Sub hyaloids hemorrhages	0	2 (10)	0.011
Vascular changes	73 (42)	3 (15)	0.013
Disc pallor	15 (9)	6 (28)	0.005
Macular edema	0	1 (5)	0.108

Table 2: Age distribution of total cases.

Age (year)	No. of children	Percentage (%)
0-5	108	47
5-10	70	30
10-15	52	22

Table 3: Gender distribution of total cases.

Age group (year)	Females	Males
0-5	58	50
5-10	38	32
10-15	36	16

Table 2 and 3 indicates sociodemographic variables of study population. Maximum children were observed in age group 1-5 years and least were found in age group 10-15 years. Also, females were more in frequency as compared to males.

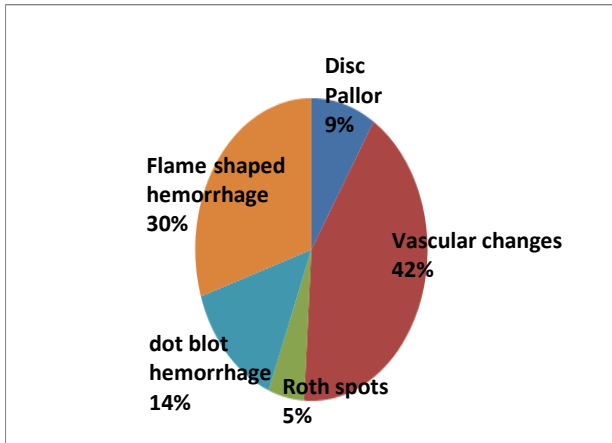


Figure 1: Fundus changes in moderate anemia.

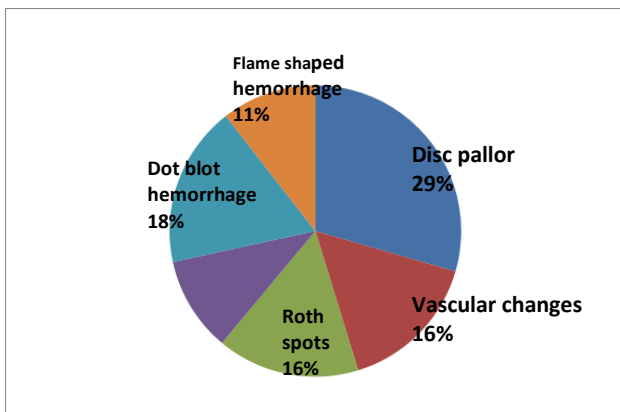


Figure 2: Fundus changes in severe anemia.

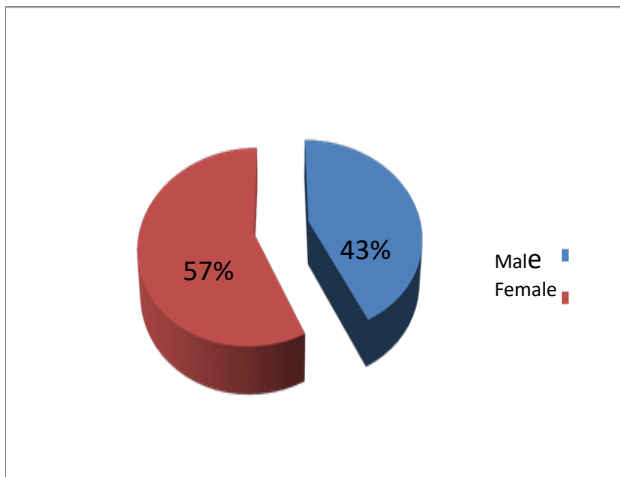


Figure 3: Gender ratio.

DISCUSSION

Anemia presents with a myriad of ocular manifestations involving various segments of the eye. The manifestations of anemic retinopathy are non-specific. Hypertensive retinopathy, non-proliferative diabetic retinopathy, Terson syndrome and Valsalva retinopathy

should be excluded first before reaching to any conclusive diagnosis. Since anemic retinopathy is almost always reversible with correction of the anemia, regular and repeated fundus examination should be carried out.⁷

In our study 230 children with hemoglobin levels of less than 10 g/dl were examined in eye OPD. Moderate anemia was seen in 207 children (90%) and severe anemia was seen in 23 children (10%). We deduced 21 (95%) severely anemic children and 173 (84%) moderately anemic children had retinopathy respectively (Figure 4). Hemorrhages and disc pallor were commonest among all retinal changes in moderate and severe anemia respectively.

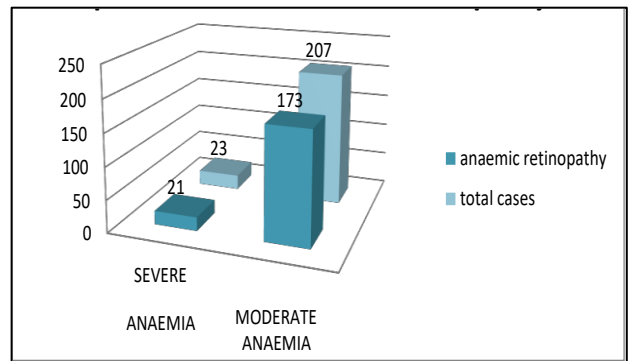


Figure 4: Prevalence of anemic retinopathy.

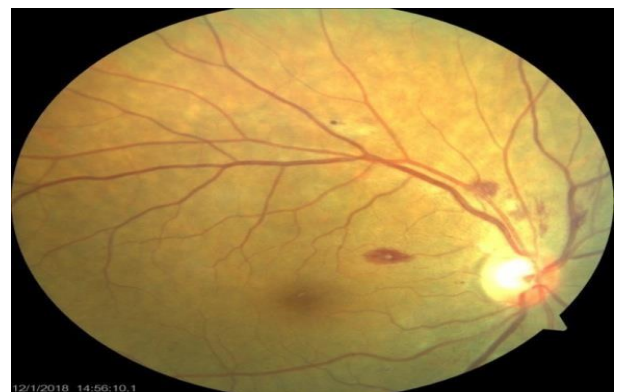

Figure 5: Roth spots and flame shaped hemorrhages.

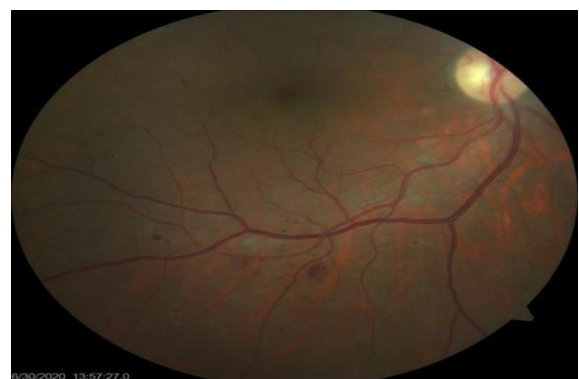

Figure 6: Dot blot hemorrhages.

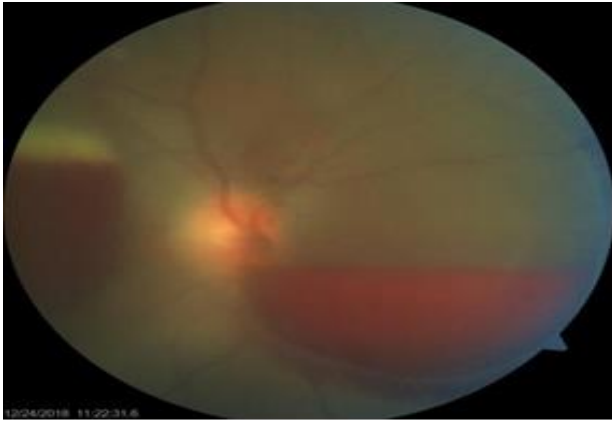


Figure 7: Sub hyaloid hemorrhages.

Figure 5, 6 and 7 showing various types of retinal hemorrhages seen in anemic retinopathy.

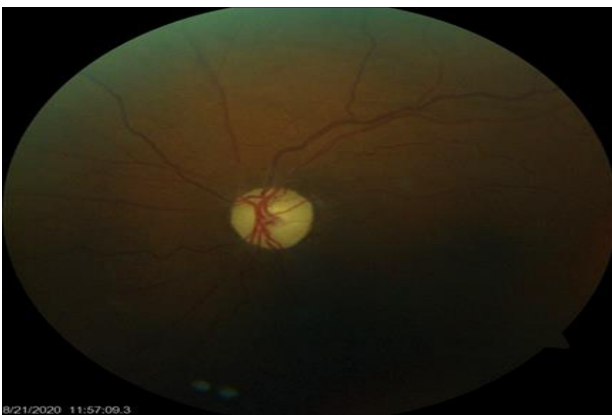

Figure 8: Disc pallor and venous tortuosity.

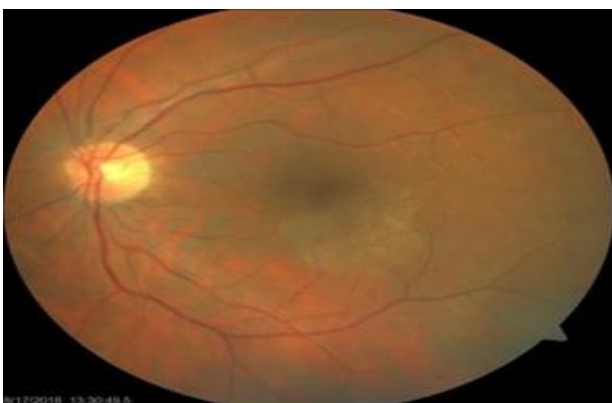


Figure 9: Macular edema.

Overall, most common retinal changes were retinal hemorrhages (49%) mainly flame shaped hemorrhages (Figure 5), dot blot hemorrhages (Figure 6), Roth spots and sub hyaloids hemorrhages (Figure 7) followed by venous dilation and tortuosity (39%), disc pallor (11%) (Figure 8), macular edema (1%) (Figure 9).

Dr. Ajay Kumar studied prevalence of retinopathy in 120 patients, he concluded that retinal hemorrhages mainly deep retinal hemorrhages were most common finding.⁴ Nusrat et al concluded in their study that conjunctival pallor and retinal hemorrhages were commonest in ocular features in anemic patients.⁸ Holt et al studied 63 patients with anemia and noted that flame shaped hemorrhages were the commonest type of hemorrhage.⁹ Suresh et al studied 34 patients with anemia and found that flame shaped hemorrhages were common followed by deep haemorrhage.¹⁰ Ajit et al also observed that severity of retinal manifestations of anemia was related to the severity of anemia.¹¹

Limitations

Other than anemia, retinal changes such as superficial hemorrhages and Roth spots are also commonly seen in thrombocytopenia and leukemia. In our study we considered only one variable that is hemoglobin so one must evaluate other parameters such as complete blood count, peripheral blood film etc.

CONCLUSION

Hence our findings were consistent with various previous studies. One should be vigilant for retina examination in all patients with hemoglobin less than 10g/dl. As the severity of anemia increases, chances of retinopathy also increase.

Funding: No funding sources

Conflict of interest: None declared

Ethical approval: The study was approved by the Institutional Ethics Committee

REFERENCES

1. DeMaeyer EA, Adiels-Tegman M. The prevalence of anaemia in the world. World health statistics quarterly. 1985;38(3):302-16.
2. Sudhagandhi B, Sundaresan S, William WE, Prema A. Prevalence of anaemia in the school children of Kattankulathur, Tamil Nadu, India. Int J Nutri Pharmacol Neurol Dis. 2011;1(2):184.
3. Ngesa O, Mwambi H. Prevalence and risk factors of anaemia among children aged between 6 months and 14 years in Kenya. PLoS One. 2014;9(11):e113756.
4. Kumar A. A Prospective Cross-Sectional Study of Ocular Manifestations in Patients with Anemia. J Dental Med Sci. 2019;18(11):10-15.
5. Garg P, Agrawal A. Ocular manifestations in patients with anaemia. J Evid Based Med. Healthc. 2017;4(79):4646-9.
6. Carraro MC, Rossetti L, Gerli GC. Prevalence of retinopathy in patients with anaemia or thrombocytopenia. Eur j haematol. 2001;67(4):238-44.
7. Basak S. A case of anemic retinopathy. University J Surg Spec. 2020;28;6(7).

8. Shaheen N, Wani JS, Nasti AR, Quadri MI. Ocular manifestations in anaemia-A clinical study. *J K Practitioner.* 2005;12(3):128-30.
9. Holt JM, Gordon-Smith EC. Retinal abnormalities in diseases of the blood. *Br J Ophthalmol.* 1969;53(3):145.
10. Suresh K, Sampath R, Tanvi. Ocular manifestations in haematological disorders. *Shri Ramchandra J Med.* 2011;4(1):1-4.
11. Majji AB, Bhatia K, Mathai A. Spontaneous bilateral peripapillary, subhyaloid and vitreous haemorrhage

with severe anaemia secondary to idiopathic thrombocytopenic purpura. *Indian J Ophthalmol.* 2010;58(3):234-6.

Cite this article as: Punjabi S, Devasthali G, Gulati A. Retinal abnormalities in children suffering from low hemoglobin levels. *Int J Res Med Sci* 2021;9:401-5.