

Original Research Article

Variant anatomy of common hepatic artery and its branching pattern: a cadaveric study with clinical implication

Swati Thamke^{1*}, Pooja Rani²

¹Department of Anatomy, People's College of Medical Sciences and Research Centre, Bhopal, Madhya Pradesh, India

²Department of Anatomy, PGIMS, Rohtak, Haryana, India

Received: 14 July 2017

Accepted: 10 August 2017

*Correspondence:

Dr. Swati Thamke,

E-mail: drswatimkurwe@gmail.com

Copyright: © the author(s), publisher and licensee Medip Academy. This is an open-access article distributed under the terms of the Creative Commons Attribution Non-Commercial License, which permits unrestricted non-commercial

ABSTRACT

Background: With the advent of new diagnostic, therapeutic and operative techniques within the abdominal cavity, a sound knowledge of the variant courses of the abdominal vessels become important for dealing clinicians, surgeons and interventional radiologists. Surgeons undertaking hepatobiliary and gastric surgery must be acquainted with the anatomy of common hepatic artery and should be able to recognize its multiple anatomical variants to avoid subsequent thrombosis leading to ischaemia of the liver or bile duct and stomach with distressing consequences. The present study was carried out to document the normal anatomy and different variations of the common hepatic artery and to evaluate the possible clinical implications.

Methods: A total of 36 properly embalmed and formalin fixed cadavers were dissected in the abdominal region and viscera were mobilized to expose the origin of important branches of the common hepatic artery.

Results: Classical branching pattern of common hepatic artery was seen in 91.66% cases. Origin of right hepatic artery from superior mesenteric artery and accessory cystic artery from gastroduodenal artery was seen in 2.77% cases. In 5.55% cases, right gastric artery originated from left hepatic artery.

Conclusions: Knowledge of such variations will play a significant role in avoiding technical difficulties during infusion therapy and chemoembolization of neoplasm in the liver. It is also valuable in carrying out surgical intervention safely in the abdomen and also in the interpretation of angiographic reports.

Keywords: Accessory cystic artery, Common hepatic artery, Right gastric artery, Superior mesenteric artery

INTRODUCTION

The common hepatic artery originates from coeliac trunk, a branch of abdominal aorta, along with splenic and left gastric arteries. After its origin, it gives a gastroduodenal branch which heads downwards posterior to the pyloric part of stomach and the first part of duodenum. The hepatic artery proper arises from the common hepatic artery as one of the terminal branches and reaches the porta hepatis through the right free margin of the lesser omentum where it lies anterior to the portal vein and to the left of bile duct. The right gastric artery usually arises from hepatic artery proper. Hepatic artery proper then

divides into right and left branches which supply the right and left lobes of the liver respectively. The gall bladder is supplied by a cystic branch from the right hepatic artery.¹ Although variations of the branching pattern and distribution of the common hepatic artery are common, variations in its origin and course are relatively rare and are important in surgical and radiological point of view. One of the rare origins of the hepatic artery is from the superior mesenteric artery.²

Variations in the origin and course of branches of common hepatic artery are not only anatomically and embryologically significant but are also important for

correct interpretation of various complicated roentgenographic films while performing arteriography and have acquired a special importance during surgery for more accurate treatment. Knowledge of these arterial variations prevents the injury of such vessels during surgery which might lead to hepatic damage and serious morbidity as there is no anastomosis between the hepatic arteries. Since it is known that the common hepatic arteries vary in relation to its branching pattern, the present study aimed to record the prevalence of these variations in cadavers. Clinical correlation and the embryological basis of abnormal branching pattern of common hepatic artery have been discussed.

METHODS

The present study was conducted in department of Anatomy, University College of Medical Sciences and GTB Hospital, Delhi from June 2012 to August 2015. Total thirty-six adult embalmed cadavers were dissected according to guidelines of "Cunningham's manual of practical anatomy" volume two, fifteenth edition.³ Dissection was carried out according to guidelines of "Cunningham's manual of practical anatomy" volume two, fifteenth edition.³ A midline skin incision was taken from the xiphisternal junction to the pubic symphysis, encircling the umbilicus. Transverse incision from the xiphoid process to a point on the midaxillary line was made. Incision on skin was extended from pubic symphysis to anterior iliac spine then up to a point on midaxillary line. From medial to lateral aspect skin was reflected towards the midaxillary line. Layer wise dissection of anterior abdominal wall was done. Muscles of anterior abdominal wall were dissected. Peritoneal cavity was opened, coeliac trunk and its branches identified and traced to their origins.

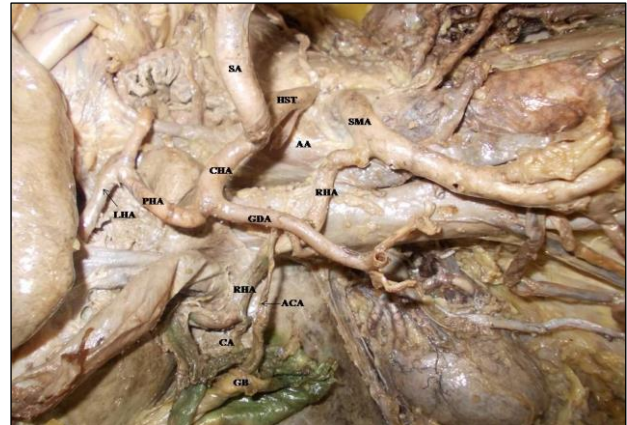
Their variations were observed and recorded with special emphasis on common hepatic artery. Origin and branches of superior mesenteric artery was also traced.

RESULTS

The common hepatic artery arises from coeliac trunk passes to the right and continue upwards within the right free margin of lesser omentum and in front of the epiploic foramen as proper hepatic artery after giving the gastroduodenal artery. Proper hepatic artery now reaches the porta hepatis of the liver and divides into larger right and smaller left branch of hepatic artery to corresponding lobes of the liver. The right hepatic artery also gives cystic artery to gall bladder.

In the present study, we observed that the classic branching pattern was present in 33 cases (91.66%). In three (8.33%) cases, we found out unusual branching patterns. In one case (2.77%) origin of right hepatic artery from superior mesenteric artery was reported origin of right hepatic artery from superior mesenteric artery which normally arises from the proper hepatic

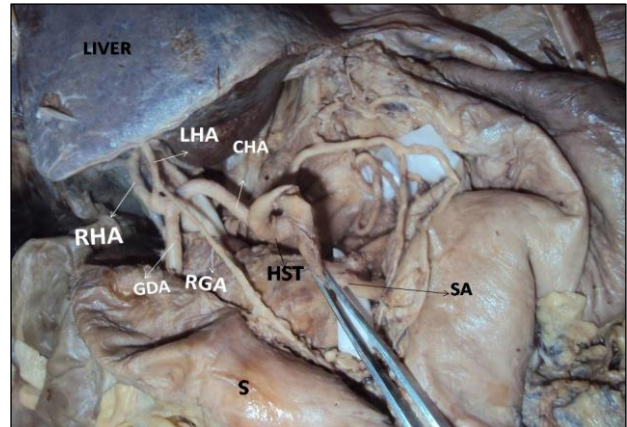
artery and gastroduodenal artery gave accessory cystic artery in addition to normal cystic artery, which is a branch of right gastric artery (Figure 1).



LHA: Left hepatic artery, CHA: Common hepatic artery, PHA: Proper hepatic artery, RIP: Right inferior phrenic artery, AA: Abdomen aorta, CHST: Common hepatosplenic trunk, SA: Splenic artery, CHA: Common hepatic artery, CA: Cystic artery.

Figure 1: Right hepatic artery (RHA) arising from superior mesenteric artery (SMA) and gastroduodenal artery (GDA) giving accessory cystic artery (ACA).

In two cases (5.55%) right gastric artery took origin from left hepatic artery (Figure 2 and 3).



HST: Common hepatosplenic trunk, CHA: Common hepatic artery, SA: Splenic artery, GDA: Gastroduodenal artery, RHA: Right hepatic artery.

Figure 2: Right gastric artery (RGA) arising from left hepatic artery (LHA).

Variation 1

Common hepatic artery and Splenic artery arose from hepatosplenic trunk from the coeliac artery. After giving gastroduodenal artery, common hepatic artery continues as proper hepatic artery. Surprisingly only left hepatic artery arose from proper hepatic artery and right hepatic artery took origin from superior mesenteric artery. After its origin, right hepatic artery crossed anterior to the

portal vein from left to right in right free margin of lesser omentum and passed behind the common hepatic duct to enter the Calot's triangle to the left of the cystic duct. As it approached the cystic duct, it gave off the cystic artery and then turned upwards behind the right hepatic duct to enter the right lobe of liver. Interestingly it was also observed that accessory cystic artery was present which was originated from gastroduodenal artery and it supplied the gall bladder (Figure 1).

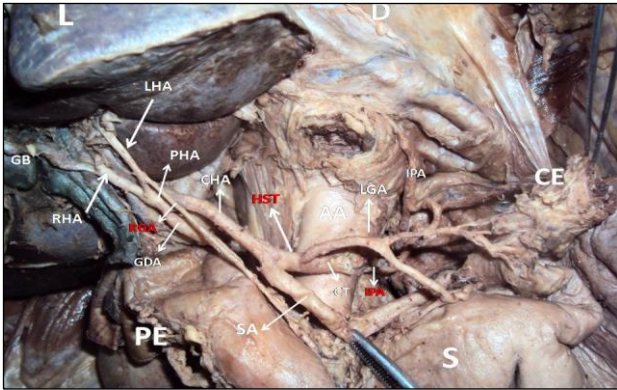


Figure 3: Right gastric artery (RGA) arising from left hepatic artery (LHA).

Variation 2 and 3

Common hepatic artery and splenic artery originated from hepatosplenic trunk from the coeliac artery. Gastroduodenal artery arose from common hepatic artery and proper hepatic artery divided into left and right hepatic arteries. Cystic artery originated from right hepatic artery. Unexpectedly it is found that descended right gastric artery arose from left hepatic artery and descends to the pyloric end of the stomach, and passes from right to left along its lesser curvature, supplying it with branches and anastomosing with the left gastric artery (Figure 2 and 3).

DISCUSSION

Abdominal organs like stomach, duodenum up to major duodenal papilla, liver, pancreas, gall bladder is supplied by the branches of common hepatic artery. It is an important content of abdomen. Any variation from the usual branching pattern of the artery may lead to complications during various interventions in this region.

Few studies in the past on the arterial branching pattern have reported variations in the branches of common hepatic artery.

Right hepatic artery

Hiatt J R et al studied surgical anatomy of the hepatic arteries in 1000 cases that underwent liver harvesting for orthotopic transplantation between 1984 and 1993.⁴ They recorded arterial patterns in order of frequency included

the normal type one anatomy (n = 757), with the common hepatic artery arising from the celiac axis to form the gastroduodenal and proper hepatic arteries and the proper hepatic dividing distally into right and left branches; Type two (n = 106), with a replaced or accessory right hepatic artery originating from the superior mesenteric artery; Type three (n = 97), with a replaced or accessory left hepatic artery arising from the left gastric artery; Type four (n = 23), with both right and left hepatic arteries arising from the superior mesenteric and left gastric arteries, respectively; Type five (n = 15), with the entire common hepatic artery arising as a branch of the superior mesenteric; and Type six (n = two), with the common hepatic artery originating directly from the aorta.

The present study corresponds with the above finding stating origin of right hepatic artery is most commonly from proper hepatic artery.

Judy MJ et al noted right hepatic artery branching off the superior mesenteric artery and its potential implications in 64-year-old caucasian male cadaver.⁵

Perez-Saborido B et al performed a retrospective study of 325 liver transplantation between 2001 and December 2011.⁶ They detected variations in the hepatic artery in 91 transplantations (32%) including 29 donors (8.9%), 57 recipients (17.5%), and five both (1.5%). The main variation among donors was a right hepatic artery originating from the mesenteric artery (38.2%), and a left hepatic artery from the left gastric artery (35.3%). Recipients also showed the same distribution: right hepatic artery from upper mesenteric artery (38.7%) and left hepatic artery from left gastric artery (12.9%). Yuksel M and Sargon M have also reported an aberrant right hepatic artery derived from the superior mesenteric artery.⁷

Mugunthan N et al observed anatomical variations in the arterial supply of liver in a 70-year-old male cadaver.⁸ They found right hepatic artery taking origin as replaced right hepatic artery from superior mesenteric artery. In addition to normal left hepatic artery, an accessory left hepatic artery arose from gastroduodenal artery.

If the artery supplies the right lobe in place of the typical branch from celiac trunk it is defined as replaced, but if the artery merely serves as an additional branch it would be referred to as aberrant.

These are few articles suggesting superior mesenteric artery gave right hepatic artery as well as replaced right hepatic artery. Present finding suggesting a replaced right hepatic artery from superior mesenteric artery correlates with above studies.

The embryological basis of the aforesaid variations can be explained as follows:

Roots of four upper ventral segmental arteries of abdominal region are anastomosed by a longitudinal ventral artery. Disappearance of the two central roots results in the joining of first and fourth root with longitudinal anastomoses. The hepatic, splenic and the left gastric arteries derive from this longitudinal anastomosis. In present case, the variations of the branches of coeliac trunks are due to developmental changes in the longitudinal anastomosis between above mentioned ventral segmental arteries. Separation of these branches from the fourth root (the future superior mesenteric artery) takes place below their terminal end. If this separation takes place at a higher level, one of the branches is displaced to the superior mesenteric artery. This explains origin of replaced right hepatic artery from the persistence of the longitudinal ventral arterial segment connected to the superior mesenteric artery.⁹

Accessory cystic artery

Embryologically, the extrahepatic biliary system is developed from an intestinal diverticulum and supplied primordially by the vessels from aorta, celiac and mesenteric arteries.

Later most of these vessels are absorbed with development of mature vascular system. Due to variability in the absorption pattern, cystic artery and its branches derived from any other artery in the vicinity. Also, the growth of the liver and pancreas and curved arrangement of the stomach and duodenum alter the simple branching pattern of the gastroduodenal and hepatobiliary vasculature.¹⁰

According to Patil SJ et al, the cystic artery originates most commonly from right hepatic artery (63.9%), other sources of origin are hepatic trunk (26.9%), left hepatic (5.5%), gastroduodenal (2.6%), superior pancreaticoduodenal (0.3%), right gastric (0.1%), celiac trunk (0.3 %) and superior mesenteric artery (0.8%).¹¹

Williams et al and Price and Holden noted that origin of cystic artery is most commonly from right gastric artery.^{12,13} The other origins include the left hepatic artery, the proper hepatic artery, the common hepatic artery, the gastroduodenal artery, the superior pancreaticoduodenal artery and the superior mesenteric artery.

Vishnumaya G et al observed anomalous origin of cystic artery from gastroduodenal artery 2.5 cm distal to the origin of common hepatic artery in 34-year-old male cadaver.¹⁴

It was also observed the most common site of origin of cystic artery is right gastric artery. In addition, we also noted one variation in which accessory cystic artery was arising from gastroduodenal artery. Patil SJ et al, Williams et al and Vishnumaya G et al mentioned anomalous origin of cystic artery from gastroduodenal

artery, but we did not find any cadaveric study with quantitative data regarding origin of accessory cystic artery from gastroduodenal artery in literature search.^{11,12,14}

Right gastric artery

The most common origin of right gastric artery is from proper hepatic artery distal to the origin of gastroduodenal artery. The other sites of origin of right gastric artery may be from gastroduodenal artery, common hepatic, left and right hepatic artery.

Very few studies concerning variations in the origin of right gastric artery are available.

Insufficient development of one of the primitive vitellin arteries or disorders of ventral anastomosis may cause many variations in the branching mode of common hepatic artery.⁹

Fok LSY mentioned in 'mastery of surgery' that right gastric artery arises from proper hepatic artery in 50-68% and left hepatic artery in 28.8- 40.5%.¹⁵

Wood WC et al in 'anatomic basis of tumor surgery' stated origin of right gastric artery is most commonly from proper hepatic artery.¹⁶ Other sources of origin are gastroduodenal artery, common hepatic artery, left hepatic artery.

Similar to above studies, in the present study we ascertained out that the origin of right gastric artery is most commonly from proper hepatic artery. In 5.55% cases left hepatic artery gave right gastric artery.

Although these vascular patterns are quite infrequent, yet the vascular surgeons and interventionists must be aware of this uncommon existence while operating in abdominal region so as to avoid any vascular catastrophe. Radiologists must also be aware of such presentation of right gastric and left hepatic artery so as to correctly interpret the angiograms.

CONCLUSION

Occluded superior mesenteric artery is a common clinical problem and if the replaced right hepatic artery is present, not only the gut but also the liver will become necrotic.¹⁷

The results of this study can be helpful to successfully accomplish surgical, oncologic, or interventional procedures including hepatic arterial infusion chemotherapy to prevent significant morbidity because of the large visceral territory supplied by a single common hepatic artery.¹⁸

This study may throw light on the possible variants of the vascular patterns of right gastric and accessory cystic arteries, which will be help to surgeons in performing an

effective hiatal surgery for gastroesophageal reflux and is also valuable in bariatric, gastric, gall bladder surgeries.

Funding: No funding sources

Conflict of interest: None declared

Ethical approval: Not required

REFERENCES

1. Nayak SB, Ashwini LS, Ravindra SS, Abhinitha P, Marpalli S, Patilet J. Surgically important accessory hepatic artery: a case report. *J Morphol Sci.* 2012;29(3):187-8.
2. Nayak SB. Hepatomesenteric trunk and gastro-spleno-phrenic trunk. *Int J Anatomical Variations.* 2008;1:2-3.
3. Romanes GJ. The abdominal cavity. In: Romanes GJ, eds. *Cunningham's manual of practical anatomy.* 15th ed. Oxford, Oxford Medical Publication; 1986:91-127.
4. Hiatt JR, Gabbay J, Busuttil RW. Surgical anatomy of the hepatic arteries in 1000 cases. *Ann Surg.* 1994;220:50-2.
5. Moon JJ, Coen WA, James WM. Right hepatic artery branching off the superior mesenteric artery and its potential implications. *Int J Anatomical Variations.* 2009;2:143-5.
6. PerezSaborido B, Pacheco-Sánchez D, Barrera Rebollo A, Fuentes PP, Díaz AE, Rodriguez LF. Incidence of hepatic artery variations in liver transplantation: does it really influence short- and long-term results?. *Transplant Proceeding.* 2012;44(9):2606-8.
7. Yuksel M, Sargon M. A variation of a coeliac trunk. *Okajimas Folia Anatomica Japonica* 1992;69:173-5.
8. Mugunthan N, Jansirani DD, Felicia C, Anbalagan J. Anatomical variations in the arterial supply of liver. *Int J Anatomical Variations.* 2012;5:107-9.
9. Moore KL, Persaud TVN. *The developing human (clinically oriented embryology).* 7th ed. Philadelphia, Saunder; 2003:335.
10. Loukas M, Ferguson A, Louis Junior RG, Colborn GL. Multiple variations of the hepatobiliary vasculature including double cystic arteries, accessory left hepatic artery and hepatosplenic trunk: a case report. *Surg Radiologic Anatomy.* 2006;28(5):525-8.
11. Patil SJ, Rana K, Kakar S, Mittal AK. Unique origin of cystic artery from celiac trunk and its importance in laparoscopic cholecystectomy. *J Morphol Sci* 2013;30(3):200-2.
12. Williams PL, Warwick R, Dyson M, Bannister LH. *Gray's Anatomy.* Edinburgh, Churchill Livingstone; 1989:768-72.
13. Price P, Holden C. Anatomic variance in the cholecystic blood supply: a case report. *Am Surg* 199;59(5):278-80.
14. Bhagath VG, Potu K, Vasavi, Gorantla R, Thejodhar P. Anomalous origin of cystic artery from gastroduodenal artery: a case report. *Int J Morphol.* 2008;26(1):75-6.
15. Law SY Fok. edited by Josef E, Fischer, Kirby I, Bland Mark P, Callery Josef. *Mastery of surgery. Part VII: the gastrointestinal tract;* 1997;1:770.
16. Wood WC, Moore S, Staley C, Skandalakis JE. *Anatomic basis of tumor surgery. Chapter 6: stomach and abdominal wall;* 2nd edition. Springer-Verlag Berlin Heidelberg; 2010:308.
17. Barakate MS, Cappe I, Curtin A, Engel KD, Li-Kim-Moy J, Poon MS, Sandeman. Management of acute superior mesenteric artery occlusion. *A NZ J Surg.* 2002;72:25-9.
18. Losanoff JE, Millis JM, Harland RC, Testa G. Hepato-spleno-mesenteric trunk. *J Am Coll Surg.* 2007;204:511.

Cite this article as: Thamkea S, Rani P. Variant anatomy of common hepatic artery and its branching pattern: a cadaveric study with clinical implication. *Int J Res Med Sci* 2017;5:3966-70.