

Case Report

Stomach versus heart: case report of a giant hiatal hernia with perforated gastric ulcer with obstructive shock

Yankel A. Sanchez^{1*}, Omar Z. Ayub²

¹Surgery Service, Hospital De Especialidades Centro Medico Nacional La Raza, Seguro Social, Mexico City, Mexico

²Emergency Service, Hospital General Regional no. 66. Instituto Mexicano Del Seguro Social, Chihuahua, Mexico

Received: 14 November 2022

Accepted: 06 December 2022

*Correspondence:

Dr. Yankel A. Sanchez,

E-mail: yankeloffice@gmail.com

Copyright: © the author(s), publisher and licensee Medip Academy. This is an open-access article distributed under the terms of the Creative Commons Attribution Non-Commercial License, which permits unrestricted non-commercial use, distribution, and reproduction in any medium, provided the original work is properly cited.

ABSTRACT

A giant paraesophageal hernia is defined when at least 30% of the stomach has moved to the thorax or the presence of another intra-abdominal organ. We describe the presentation of a clinical case of a giant hiatal hernia with perforated gastric ulcer in a 52-year-old man who presented to the emergency department with pain in the inguinal region developing obstructive shock. Presentation of hiatal hernias is usually asymptomatic and in some cases with atypical signs and symptoms involving cardiovascular and respiratory disorders. In patients with a history of gastroesophageal reflux disease/ with atypical thoracic symptoms, hiatal hernia and its complications should be ruled out.

Keywords: Hiatal hernia, Obstructive shock, Perforated gastric ulcer

INTRODUCTION

Hiatal hernias are defined as displacement of stomach or other abdominal organs into rib cage through esophageal hiatus of the diaphragm and are the most common type of acquired diaphragmatic hernias. They have been described in 2.9-20% of patients undergoing gastroscopy. In reality, they may occur much more frequently, even in up to 10-50% of the population.¹ Sliding hernias are the most common type, occurring in up to 90% of cases. On other hand, giant para-esophageal hernia is defined when at least 30% of stomach has moved into the thorax.¹

This article describes the presentation of a clinical case of a giant hiatal hernia with perforated gastric ulcer in a 52-year-old man who presented to the emergency department with pain in the inguinal region.

CASE REPORT

A 52-year-old male with no history of chronic degenerative diseases or surgery came to the emergency

department of a second level hospital because of pain in the left inguinal region, His current condition began 4 years ago with the detection of increased volume in the left inguinal region with progression of its dimensions and progressive worsening of pain. Upon admission to the emergency department, he was classified as yellow TRIAGE, with vital signs and somatometry: TA 136/85 mmHg, HR 100 beats per minute, FR 22 breaths per minute, Temperature 36.6 °C, weight 74 kg, height 1.60 mts. and referred intense colicky pain in the area of the left inguinal hernia radiating to the hypogastrium, adding nausea, lethargy and diaphoresis. Initiating management for pain control based on NSAIDs partially improving symptoms, then performing ultrasound of the inguinal region reporting right inguinal hernia with bowel loops and omentum in its non-reducible content surrounding vascular structures without thrombosis data or alterations in its diameter, moderate amount of fluid to the right scrotum is anechoic without septa without floating lumps, testicles and left scrotum normal no fluid in the abdominal cavity. However, the patient continues with pain and chest pain of oppressive type, tachycardia and shortness of breath, being transferred to the shock area

with the following vital signs: TA 071/042 mmHg HR 140 beats per minute FR 26 breaths per minute, temperature 36.8 °C SaO₂ 97%, an electrocardiogram was requested, cardiac biomarkers CPK 104, CPK-MB 117, electrocardiogram with data of atrial fibrillation with rapid ventricular response without ST segment deviation or data of ischemia or necrosis, ruling out the diagnosis of acute coronary syndrome. Vascular volume replacement and Norepinephrine infusion were indicated with poor response to treatment, laboratory tests showed no data of systemic inflammatory response, leukocytes of 3.40 10³/uI, and blood gases showed moderate metabolic acidosis as primary disorder and respiratory alkalosis as secondary disorder. Chest X-ray was requested after placement of central venous catheter and drawing attention to the displacement of the mediastinum to the left (Figure 1), so the protocol for obstructive shock was initiated and a thoracic and abdominal tomography was performed with findings: Right pleural effusion, air space consolidation at the level of the right upper lobe, not ruling out concomitant pneumonic process, (Figure 2) Thickening of the minor fissure, with passive atelectasis, secondary. Image compatible with abscess and pneumoperitoneum in the right subphrenic region, images compatible with paraesophageal hiatal hernia with stomach and esophagus, this hernia with a transverse diameter of 14 cm in diameter (Figure 3-5).

He was evaluated by the general surgery service who performed emergency surgical management with the finding of an abdomen with purulent and gastrobiliary free abdominal liquid, dilated intestinal loops with lax adhesions, multiple loop-asa abscesses, presence of gastric fundus and gastric antrum, presence of gastric fundus and antrum displaced towards the thorax finding perforated ulcer in the gastric antrum, when reducing 2 liters of liquid from the thorax with serous characteristics and gastric content, right inguinal hernia with viable bowel loops inside. Performing hiatal hernia reduction + primary closure of gastric ulcer. In the postoperative period he was admitted to the intensive care unit, with a torpid evolution and died of lethal arrhythmia 96 hours later.

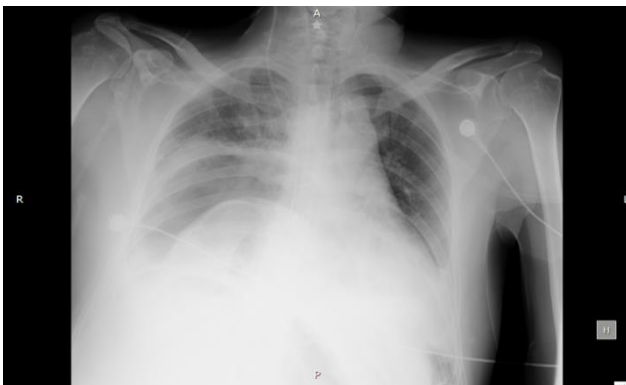

Figure 1: Chest X-ray, gastric bubble is observed in right side.

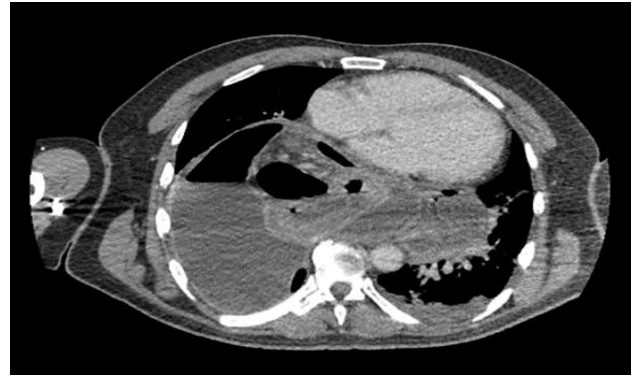


Figure 2: Chest TC, axial section, stomach in right thorax and bilateral pleural effusion.

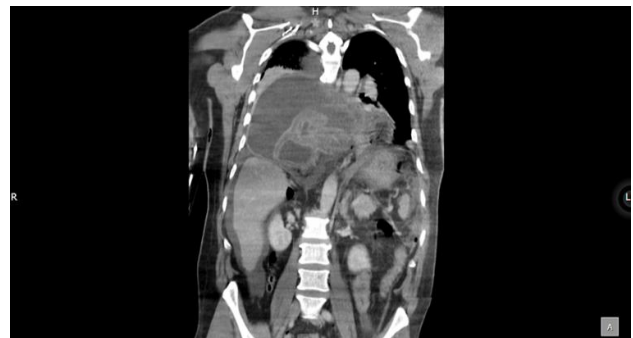

Figure 3: Chest TC, fluid in right thorax.

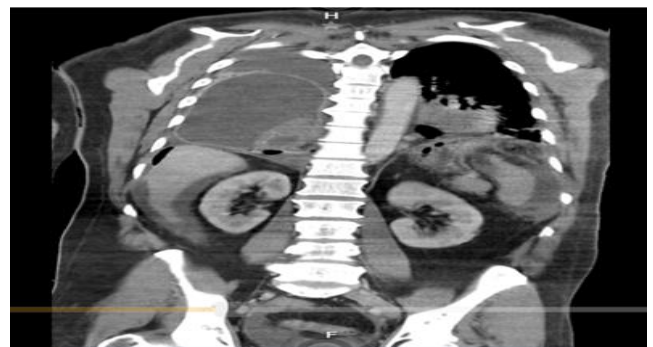

Figure 4: Chest TC, coronal section, stomach in right thorax.

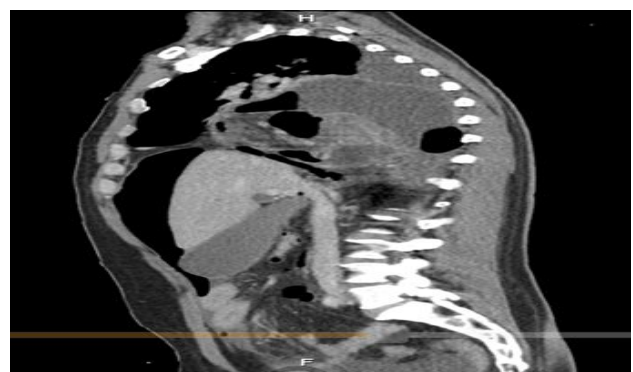

Figure 5: Chest TC scan sagittal section, liquid is observed in mediastinum.

DISCUSSION

Giant hiatal hernia accounts for 0.3% to 15% of all hiatal hernias. A number of studies have reported acute complications of giant hiatal hernia, such as acute gastric volvulus, intrathoracic gastric perforation, and incarcerated obstruction of the herniated viscera.²

The presentation of symptoms is usually nonspecific and in most cases the diagnosis results from an imaging study finding.

When symptoms do present, they usually manifest as vague and intermittent epigastric and retrosternal pain or discomfort. Patients may have early satiety, dysphagia or regurgitation with large hernias.³

The risk of progression to symptomatic hernia has been suggested to be approximately 14% per year, although the risk of symptoms requiring emergency surgery is no more than 2% per year.³

In this case the patient debuts with a clinical picture compatible with obstructive shock and cardiac arrhythmia. The anatomical proximity of the left atrium to the hiatal hernia makes the atria prone to mechanical irritation, neural connections and inflammation that may increase the risk of atrial fibrillation. The relationship between gastrointestinal symptoms and arrhythmias was first described by Ludwig Roemheld, under the name of "Roemheld's gastrocardiac syndrome", in which an esophago-gastric stimulus was able to induce arrhythmia-related symptoms.⁴

The diagnosis of hiatal hernias is almost never primary. A chest X-ray may reveal a retrocardiac hydroaerial level or a nasogastric tube that coils into the chest and does not proceed inferior to the diaphragm. Definitive diagnosis can be made by barium swallow if the axial hernia is larger than 2 cm or by endoscopy. Hernias smaller than 2 cm can usually only be identified intraoperatively on inspection and are generally clinically insignificant. Barium swallow is the primary diagnostic modality as it provides information on the size of the hernia, the origin of the stomach and the location of the esophagogastric junction.³

In terms of treatment, laparoscopic repair has become the standard approach for hiatal hernia repair, with the rare

exception of cases with gastric necrosis, thoracic contamination or difficulty in performing a laparoscopic Collis gastroplasty.³

CONCLUSION

Hiatal hernias are a common pathology in the general population, which often presents asymptotically and therefore does not usually require pharmacological or surgical treatment although sometimes it is often associated with gastroesophageal reflux disease being the main cause for which patients seek medical attention. Sometimes the progression of the hernia usually has lethal complications such as perforation of peptic ulcer and gastric volvulus, which lead to complications in intrathoracic organs such as chemical pneumonitis and cardiac arrhythmias. In young patients with a history of gastroesophageal reflux disease or upper abdominal symptoms who present with cardiac arrhythmias, it is necessary to rule out the presence of hiatal hernia as a cause of this and to provide a timely treatment to reduce the risk of complications.

Funding: No funding sources

Conflict of interest: None declared

Ethical approval: Not required

REFERENCES

1. Banki F. Giant paraesophageal hiatal hernia: A complex clinical entity. J Thorac Cardiovasc Surg. 2017;154(2):752-3.
2. Guan L, Nie Y, Yuan X, Chen J, Yang H. Laparoscopic repair of giant hiatal hernia for elderly patients. Ann Translational Med. 2021;9(8):704.
3. Siegal SR, Dolan JP, Hunter JG. Modern diagnosis and treatment of hiatal hernias. Langenbecks Arch Surg. 2017;402(8):1145-51.
4. Cristian DA, Constantin AS, Barbu M, Spătaru D, Burcoş T, Grama FA. Paroxysmal postprandial atrial fibrillation suppressed by laparoscopic repair of a giant paraesophageal hernia compressing the left atrium. J Gastrointest Liver Dis. 2015;24(1):113-6.

Cite this article as: Sanchez YA, Ayub OZ. Stomach versus heart: case report of a giant hiatal hernia with perforated gastric ulcer with obstructive shock. Int J Res Med Sci 2023;11:xxx-xx.