

Research Article

Role of Alcian blue (pH 2.5) histochemical stain in diagnostic thyroid pathology: how far is it helpful?

Seetu Palo^{1*}, Dayananda S. Biligi²

¹Department of Pathology, Maharajah Institute of Medical Sciences, Vizianagram, Andhra Pradesh, India

²Department of Pathology, Bangalore Medical College and Research Institute, Bengaluru, Karnataka, India

Received: 21 October 2015

Accepted: 20 November 2015

*Correspondence:

Dr. Seetu Palo,

E-mail: seetu.pearl@gmail.com

Copyright: © the author(s), publisher and licensee Medip Academy. This is an open-access article distributed under the terms of the Creative Commons Attribution Non-Commercial License, which permits unrestricted non-commercial use, distribution, and reproduction in any medium, provided the original work is properly cited.

ABSTRACT

Background: Controversies and pitfalls are well-known in diagnostic thyroid pathology. Since, the luminal surface of neoplastic thyroid follicular cells is said to be covered by a glycoproteinaceous material, there is a need to investigate the efficacy of mucin stains like Alcian blue (pH 2.5), which can be used as an adjunctive tool in difficult cases.

Methods: 60 thyroidectomy specimens, received at Department of Pathology, were included in this retrospective analytical study. Alcian blue histochemical (pH 2.5) staining was done on representative sections and assessed for positivity.

Results: Of the 60 cases analysed, all cases of papillary/nodular hyperplasia (n=10), follicular adenoma (n=14), follicular carcinoma (n=4) and medullary carcinoma (n=1) were negative for Alcian blue. Only 3/16 (18.7 %) cases of classical papillary carcinoma and 2/15 (13.3%) cases of follicular variant of papillary carcinoma showed positivity.

Conclusions: We got statistically insignificant results with Alcian blue (pH 2.5) staining, making it unreliable in diagnostic thyroid pathology.

Keywords: Alcian blue, Histochemical, Thyroid, Glycoprotein

INTRODUCTION

Thyroid lesions are commonly encountered in clinical practice. From a clinical standpoint, the possibility of neoplastic disease is of major concern in persons who present with thyroid enlargement. Although tumors of the thyroid account for only 1% of the overall human cancer burden, they represent the most common malignancies of the endocrine system and pose a significant challenge to pathologists, surgeons and oncologists.¹ Although histopathological examination is the acknowledged 'gold standard' in diagnosing thyroid lesions, controversies and pitfalls do exist. Today, we, pathologists try to seek the answers in the immunohistochemical markers. However, simple histochemical stains sometimes can be of immense help and the pathologist can arrive at a diagnosis without the immunohistochemical aid, which is

undoubtedly a costly affair. It is known that the luminal surface of thyroid follicular tumor cells is covered by a glycoproteinaceous material that reacts positively with mucin stains,² like Alcian blue.

Alcian blue is a group of water soluble polyvalent basic dyes. The blue color, that is imparted, is due to the presence of copper in the molecule. The 3% acetic acid solution (pH 2.5) Alcian blue stains both sulfated and carboxylated acid mucopolysaccharides and sialomucins (glycoproteins) by forming salt linkages with the acid groups of acid mucopolysaccharides.

There is a need to investigate the efficacy of Alcian blue (pH 2.5) staining which can be used as a cheap diagnostic tool in difficult cases, especially in laboratories which do not have access to immunohistochemistry.

METHODS

The present study is retrospective analytical type comprising of 60 thyroidectomy specimens received at Department of Pathology, Victoria hospital and Bowring and Lady Curzon Hospitals, attached to Bangalore medical college and research centre, between November 2012 and October 2014.

All thyroidectomy specimens that were histologically diagnosed as hyperplastic, primary benign and malignant neoplasms, were included. Frank cases of colloid goitre, multinodular goitre and Hashimoto's thyroiditis were excluded from the study.

The H & E slides were microscopically analyzed by an independent pathologist. Based on the microscopic findings, a single paraffin block, containing the representative area was selected per case for subsequent histochemical staining.

The selected blocks were taken and 4-5 μ thin sections were cut. The sections were stained with Alcian Blue (pH 2.5) according to the standard protocol. Neutral red was used as a counterstain. Sections of appendix were used as positive control. The stained slides were examined microscopically for presence or absence of staining. The data was tabulated in a standardized format and analysed. A 'p' value less than 0.01 was considered as significant.

RESULTS

Of the 60 analyzed cases, 10 (16.7%) cases showed hyperplastic nodules, 14 cases (23.3%) were diagnosed as benign neoplasms and 36 cases (60.0%) as primary malignant neoplasms (Table 1 & 2).

Table 1: Distribution of various lesions of thyroid in the current study according to nature of the lesion.

Histomorphologic diagnosis	Total number of cases (%)
Hyperplastic nodule	10 (16.7)
Benign neoplasms	14 (23.3)
Malignant neoplasms	36 (60.0)
Total	60 (100)

All cases of papillary/nodular hyperplasia (Figure 1), follicular adenoma, follicular carcinoma and medullary carcinoma were negative for Alcian blue. Only 3/16 (18.7%) cases of classical papillary carcinoma (Figure 2) and 2/15 (13.3%) cases of follicular variant of papillary carcinoma (Figure 3) showed positive staining of the glycocalyx coating the tumor cells (Table 3). Thus, diagnostic ability of Alcian blue (pH 2.5) staining in distinguishing between hyperplastic, benign and malignant thyroid lesions were statistically not significant ($p > 0.01$) in our study (Table 4).

Table 2: Distribution of various lesions of thyroid in the current study based on histomorphologic diagnosis.

Histomorphologic diagnosis	Total number of cases (%)
Nodular hyperplasia	10 (16.7)
Follicular adenoma	14 (23.3)
Classical papillary carcinoma	16 (26.6)
Follicular variant of Papillary Carcinoma	15 (25.0)
Follicular carcinoma	04 (06.7)
Medullary carcinoma	01 (01.7)
Total	60 (100)

Table 3: Number of Alcian blue (pH 2.5) positive and negative cases.

Histologic diagnosis	No. of positive cases (%)	No. of negative cases (%)
Nodular hyperplasia (n=10)	0 (0.0)	10 (100)
Follicular adenoma (n=14)	0 (0.0)	14 (100)
Classical PTC (n=16)	3 (18.7)	13 (81.3)
FVPTC (n=15)	2 (13.3)	13 (86.7)
Follicular carcinoma (n=04)	0 (0.0)	04 (100)
Medullary carcinoma(n=01)	0 (0.0)	1(100)

Table 4: Number of Alcian blue (pH 2.5) positive and negative cases in hyperplastic, benign and malignant lesions of thyroid. [$p > 0.01$]

Histologic diagnosis	No. of positive cases (%)	No. of negative cases (%)
Hyperplastic lesion (n=10)	0 (0.0)	10 (100)
Benign neoplasm (n=14)	0 (0.0)	14 (100)
Malignant neoplasm (n=36)	5 (13.9)	31 (86.1)

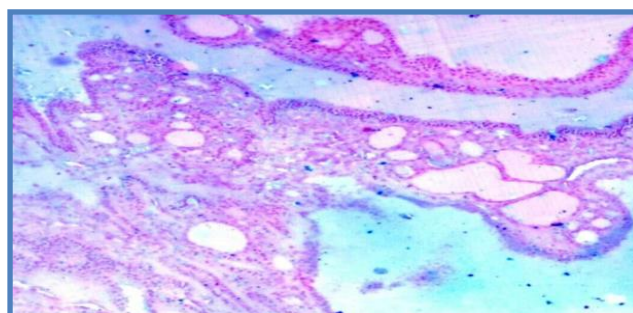


Figure 1: Papillary hyperplasia – negative for Alcian blue (pH 2.5) (100x).

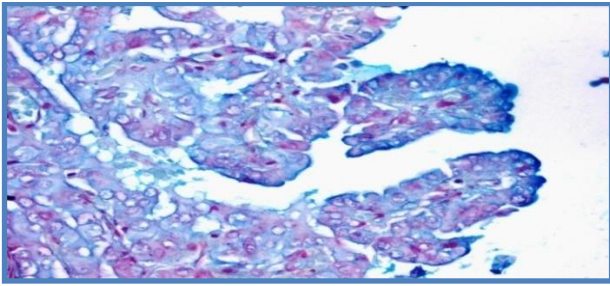


Figure 2: Alcian blue (pH 2.5) positivity noted in the glycocalyx coating the tumor cells in a case of classical papillary carcinoma of thyroid (400x).

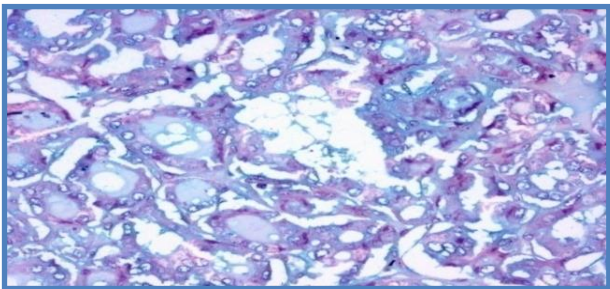


Figure 3: Alcian blue (pH 2.5) positivity noted in a case of follicular variant of papillary thyroid carcinoma (200x).

DISCUSSION

In majority of the cases, the pathological diagnosis of surgically removed thyroid specimen is possible by morphological examination alone in routine H & E stained sections. However, histomorphological criteria are insufficient or do not help the pathologist to come to a concrete diagnosis in certain instances, such as:-

- 1) Hyperplastic nodules (or adenomatoid nodules) with an exclusive microfollicular or macrofollicular architecture versus follicular adenomas with thin capsules.³
- 2) Papillary hyperplasia/hyperplastic nodule versus classical papillary carcinoma.⁴
Hyperplastic nodules may sometimes mimic some histological features of papillary carcinoma.^{5,6} In some cases of nodular goiter, the nuclear clearing and inclusions can be present in most of the cells.⁶ Multinodular goitre may exhibit delicate papillary budding which further adds to the difficulty.⁷
- 3) Fibrosing thyroiditis versus papillary microcarcinoma.⁸
- 4) Hyalinizing trabecular adenoma can mimic papillary carcinoma of thyroid.⁹
- 5) Most papillary carcinoma of thyroid can be diagnosed with ease by utilizing morphological criteria, except cases in which there is a paucity of diagnostic nuclear features^{10,11} such as in cystic variant of papillary carcinoma. This variant exhibits large edematous papillary structures lined by cells having nuclei with dispersed chromatin.¹²⁻¹⁴

- 6) Last but not the least, the so called “follicular patterned” thyroid lesions may pose diagnostic challenge even to the most experienced pathologist.¹⁵ One may encounter problems while distinguishing between hyperplastic nodules and follicular adenoma, follicular adenoma and minimally invasive follicular carcinoma, and follicular adenoma/carcinoma and the follicular variant of papillary carcinoma.

All of the above mentioned diagnostic dilemmas have important consequences on the management and prognosis of the patients. Also, intra- and inter-observer variation is a well-documented fact in thyroid pathology.¹⁶⁻¹⁸ Thus, to overcome these difficulties, several workers have proposed different IHC markers,⁴ such as, CK19, CK 903, CITED1, CD 26, CD 57, cyclin D1, cyclooxygenase-2, fibronectin-1, galectin-3, HBME-1, ki67, p27, p63, Ret oncoprotein, S 100, TPO and their efficacy in diagnosis, treatment and prognosis are being evaluated.

In the present era of immunohistochemistry, we often tend to forget about simple histochemical stains. Way back in 1990, Damiani S et al.¹⁹ performed histochemistry for alcianophilic substances in 17 cases of papillary thyroid carcinomas and 11 cases of benign thyroid lesions showing papillary changes. In 15/17 (88.2%) papillary carcinoma cases, the glycocalyx of the cells lining the papillary structures was strongly positive with Alcian blue pH 2.5 stain whereas none of the cases of benign thyroid lesions showed positivity in the cells lining the papillary structures. Hence, they concluded that presence and distribution of alcianophilic substances may be useful in distinguishing benign from malignant papillary thyroid lesions. However, after that, histochemistry in diagnostic thyroid pathology has been a dormant area and not much has been spoken about it in the literature. In our study, we have made an effort to contribute in this direction.

As opposed to Damiani S et al.¹⁹, in our study, only 3/16 (18.7 %) cases of classical papillary carcinoma and 2/15 (13.3%) cases of follicular variant of papillary carcinoma showed positive staining of the glycocalyx coating the tumor cells. In contrast, no cases of benign papillary hyperplasia showed positivity in their series and our study also showed concordant results with none of the cases of hyperplastic cases being positive.

In our series, only 5/31(16.1%) cases of papillary carcinoma (both classical type and the follicular variant) showed positivity, indicating that the utility of Alcian blue (pH 2.5) needs to be validated with further studies in this direction. Also, to the best of our knowledge, there is no literature stating the staining pattern among the various neoplastic follicular- patterned lesions of thyroid. In our study, none of the cases of follicular adenoma and follicular carcinoma exhibited positivity. All cases of follicular variant of papillary carcinoma were also

negative, except for two cases, wherein focal weak positivity was demonstrated.

CONCLUSION

In our view, Alcian blue (pH 2.5) staining cannot be used reliably in distinguishing hyperplastic, benign and malignant lesions ($p > 0.01$). Positive result, might, substantiate the diagnosis of papillary carcinoma but negative result does not rule out malignancy. Also, special care has to be taken for maintaining the pH of the staining reaction and standardizing the staining protocol.

ACKNOWLEDGEMENTS

I express my gratitude to Dr. Raghupathi A R, Professor, and Dr Nirmala CP, Associate Professor, Department of Pathology, Bangalore Medical college and research institute for their valuable support and suggestions.

Funding: No funding sources

Conflict of interest: None declared

Ethical approval: Not required

REFERENCES

1. DeLellis RA, Williams ED. Tumours of thyroid and parathyroid. In: DeLellis RA, Lloyd RV, Heitz PU, Eng C, eds. Pathology And Genetics. Tumors of Endocrine Organs. World Health Organization Classification of Tumors. Lyon, France: IARC Press; 2004:49-56.
2. Rosai J, Tallini G. Thyroid gland in Rosai and Ackerman's surgical pathology. 10th ed. Elsevier Mosby; 2011;1:487-539.
3. Baloch ZW, LiVolsi VA. Follicular-patterned lesions of the thyroid: the bane of the pathologist. Am J Clin Pathol. 2002;117:143-50.
4. Rydlova M, Ludvikovab M, Stankovac I. Potential Diagnostic Markers In Nodular Lesions Of The Thyroid Gland: An Immunohistochemical Study. Biomed Pap Med Fac Univ Palacky Olomouc Czech Repub. 2008, 152(1):53-60.
5. Erkilic S, Kocer NE. The role of cytokeratin 19 in the differential diagnosis of true papillary carcinoma of thyroid and papillary carcinoma like changes in Grave's disease. Endocr Pathol. 2005;16: 63-6.
6. Mustafa Kosem, Sabriye Polat, Mustafa Ozturk, et al. Differential diagnosis of papillary thyroid carcinoma: Immunohistochemical study of 112 cases. Eastern Jr Of Med 2005;10:15-9.
7. LiVolsi VA. Papillary thyroid carcinoma: an update. Mod Pathol. 2011;24:S1-S9.
8. Rosai J, Kuhn E, Carcangiu ML. Pitfalls in thyroid tumour pathology. Histopathology. 2006;49: 107-20.
9. Fischer S, Asa SL. Application of Immunohistochemistry to Thyroid Neoplasms. Arch Pathol Lab Med. 2008;132:359-72.
10. Baloch ZW, LiVolsi VA. Pathologic diagnosis of papillary thyroid carcinoma: today and tomorrow. Expert Rev Mol Diagn. 2005;5:573-84.
11. Papale F, Cafiero G, Grimaldi A, et al. Galectin-3 expression in thyroid fine needle cytology uncertain cases: validation of molecular markers and technology innovation. J Cell Physiol. 2013;228: 968-74.
12. Mc Laren KM, Cossar DW. The immunohistochemical localization of S-100 in the diagnosis of papillary carcinoma of the thyroid. Human Pathol. 1996; 27:633-6.
13. Miettinen M, Kovatich AJ, Karkkainen P. Keratin subsets in papillary and follicular thyroid lesions. Virchows Arch A Pathol Anat. 1997;431:407-20.
14. Yamamoto Y, Izumi K, Otsuka H. An immunohistochemical study of EMA, cytokeratin and vimentin in papillary carcinoma: Recognition of lethal and favorable prognostic types. Cancer. 1992; 70:2326-629.
15. de Matos P S, Ferreira A P, de Oliveira Facuri F, et al. Usefulness of HBME-1, cytokeratin 19 and galectin-3 immunostaining in the diagnosis of thyroid malignancy. Histopathology. 2005;47:391-40.
16. Elsheikh TM, Asa SL, Chan JK, et al. Interobserver and intraobserver variation among experts in the diagnosis of thyroid follicular lesions with borderline nuclear features of papillary carcinoma. Am J Clin Pathol. 2008;130(5): 736-44.
17. Hirokawa M, Carney JA, Goellner JR, et al. Observer variation of encapsulated follicular lesions of the thyroid gland. Am J Surg Pathol. 2002; 26(11):1508-14.
18. Lloyd RV, Erickson LA, Casey MB, et al. Observer variation in the diagnosis of follicular variant of papillary thyroid carcinoma. Am J Surg Pathol. 2004;28:1336-40.
19. Damiani S, Fratamico F, Lepertosa G, Dina R, Eusebi V. Alcian blue and epithelial membrane antigen are useful markers in differentiating benign from malignant papillae in thyroid lesions. Virchows Arch A Pathol Anat Histopathol. 1991;419(2):131-5.

Cite this article as: Palo S, Biligi DS. Role of Alcian blue (pH 2.5) histochemical stain in diagnostic thyroid pathology: how far is it helpful? Int J Res Med Sci. 2015;3:3766-9.