

Original Research Article

Functional and radiological outcome following operative skeletal stabilisation with bone grafting in distal femur non-unions: a study of 21 patients

Navin Balasubramanian^{1*}, Sindhuja P.²

¹Department of Orthopaedics, ²Department of Pathology, Saveetha Medical College, Chennai, India

Received: 12 January 2017

Revised: 24 January 2017

Accepted: 30 January 2017

***Correspondence:**

Dr. Navin Balasubramanian,

E-mail: drnavin_ortho@yahoo.co.in

Copyright: © the author(s), publisher and licensee Medip Academy. This is an open-access article distributed under the terms of the Creative Commons Attribution Non-Commercial License, which permits unrestricted non-commercial use, distribution, and reproduction in any medium, provided the original work is properly cited.

ABSTRACT

Background: The study was done to assess the functional and radiological outcome after operative skeletal stabilisation with bone grafting in 21 patients who presented to us with distal femur non-unions.

Methods: Between August 2008 and October 2015, 21 patients (M:F- 14:7) with established non-unions of the distal femur were included. All patients presented to us with established non-union following treatment with a native bone setter using splints. There were 16 patients with AO Type A, 4 with AO Type B and one patient with Type C. All patients underwent open reduction, internal fixation with plate and screws and bone grafting. Serial follow-ups were done at 4, 8, 12, 16, 20, 24 weeks and 6 monthly thereafter.

Results: All 21 patients had complete fracture healing at average of 19 weeks (Range 16-24). Knee flexion (ROM) improved from an average 16° pre-op to 66° post-operatively. There were no implant failure, infection or non-unions in our study. The Knee Society score improved from 54 pre-operatively to 74 post-operatively at last follow-up.

Conclusions: Even in established non-unions, good results can be expected if good surgical technique is followed and with bone grafting satisfactory union rated can be achieved. Knee ROM also improves with dedicated postoperative rehabilitation.

Keywords: Distal femur non-unions, Native bone setter, Knee society score

INTRODUCTION

In India, the number of road accidents are amongst the highest in the world. With an estimated 1,50,000 losing their lives on Indian roads every year. The number of non-fatal accidents with resulting long bone fractures is estimated to be in excess of 5 million each year. Although the number of health care centres, both government run and private owned is high, there are still a small but significant subset of people who throng to the native bone setters for their treatment inspite of the government's crackdown on such spurious centres. The main reason for this is the high cost involved in managing

such fractures and the taboo associated with surgical correction. This in the recent past has shown a declining trend and more patients are attending fracture clinics and hospitals because of better medical insurance coverage (both government and private) and better patient awareness towards the complications associated with such native splinting. However we still encounter sporadic cases of either fracture malunion and non-unions in our clinical practice.

Distal femur fractures show a bimodal age distribution.¹ They are mostly high velocity injuries in the young and domestic injuries due to osteoporosis in the elderly

population. ¹With prompt surgical care, these fractures heal well with excellent functional results. However due to the above mentioned native bone setters, a small group of such fractures often end with non-unions. The treatment of such non-unions still involves open reduction with internal fixation and bone grafting after freshening the fractures ends and removal of interposing soft and fibrous tissues. ¹ The AO principles must still be adhered to with a pinch of salt and soft tissues must be respected. Here we present our functional assessment of 21 patients with distal femur fracture non-unions treated by open reduction and internal fixation with supplemental bone grafting.

METHODS

Twenty five patients were treated between August 2008-October 2015 at a tertiary care centre with distal femur non-unions. Four patients were lost to follow-up. We have included 21 patients (M:F- 14:7) in our study. They were all classified under the AO-Muller classification as shown in Figure 1. The average age was 43.36 years (range 34-61 years). They presented to us on an average 6 months following injury (range 4-7 months). We proceeded to operative skeletal stabilisation, internal fixation with plate and screws and bone grafting in all our patients. Partial quadricepsplasty was done in 11 of our patients. Standard post-operative wound care protocol was followed. Knee mobilisation was started gradually with not more than 40° as a target at 4 weeks. Weight bearing was delayed till fracture healing. Pre-op and post-op Knee scores were recorded at each visit and compared. Static quadriceps exercises were taught to all our patients to start immediately after surgery. Suture removal was done at 14 days. Initial non-weight bearing walking with walking aid was started after 3rd post-operative day.

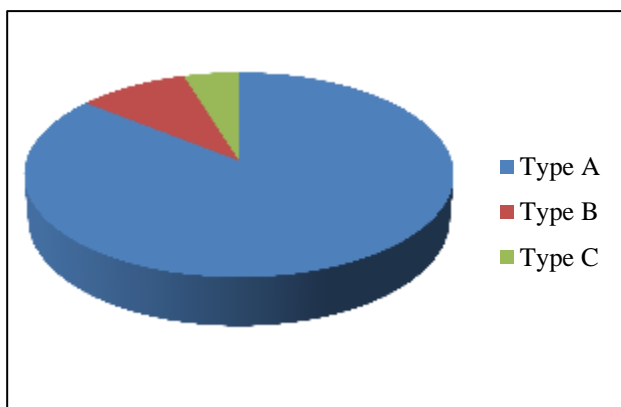


Figure 1: Data of AO-Muller classification.

Surgical technique

Through a standard lateral approach with patients supine with bolster under the knee, the tensor fascia lata was incised. In 11 patients, quadriceps was found adherent to the anterior surface of the femur. Quadricepsplasty was done in them. The fracture was

exposed, intervening soft tissue were cleared and anatomical reduction was done. We used the distal femur locked compression plating with a composite of both locked and cortical/ cancellous screws. Cancellous bone grafting from the iliac crest was harvested and packed at the fracture site. Image intensifier was used in all our cases. After checking for intra-operative stability, wound was closed in layers. Skin was closed over a suction drain. Serial follow-ups were done at 4, 8, 12, 16, 20 and 24 weeks.

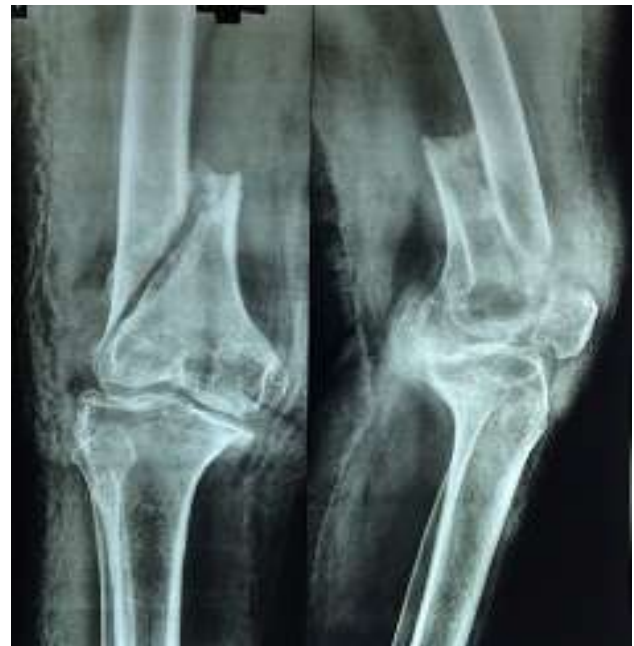

Figure 2: Pre-op X ray showing Type A1 Distal femur non-union with smooth margins.

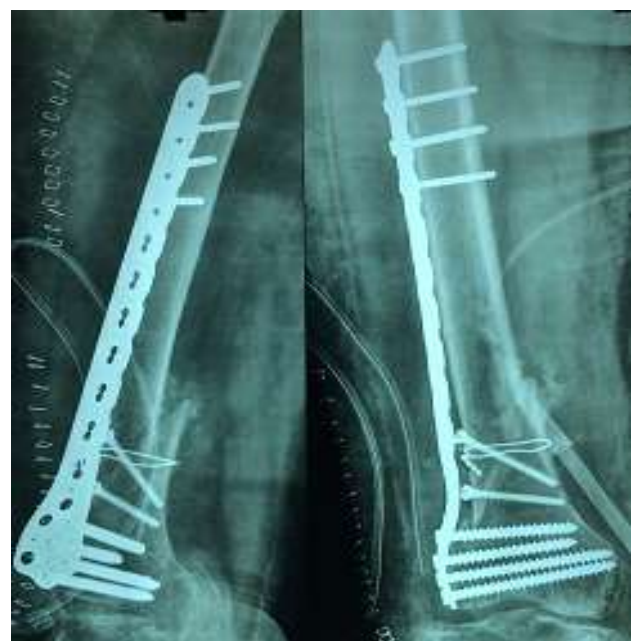

Figure 3: Post-op X ray with good reduction, plate and screws with bone grafting.

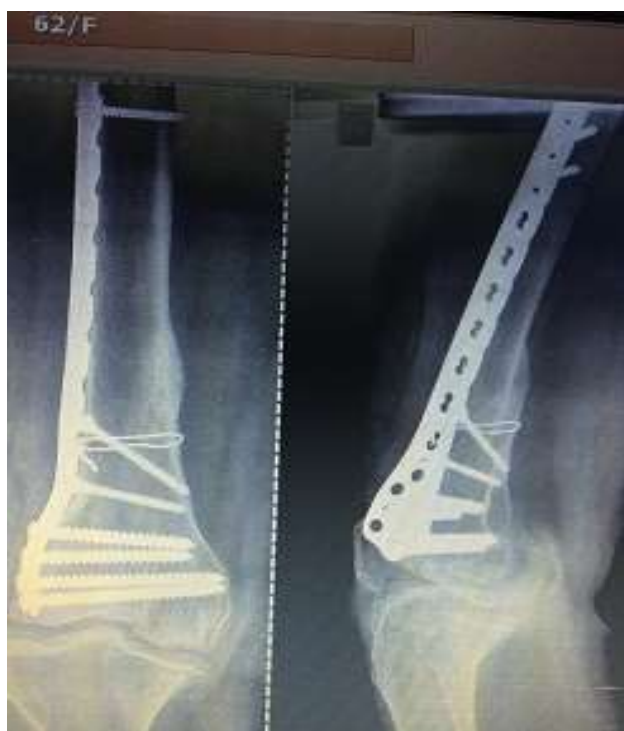

Figure 4: Follow-up X-ray at one year with good healing with implant in situ.

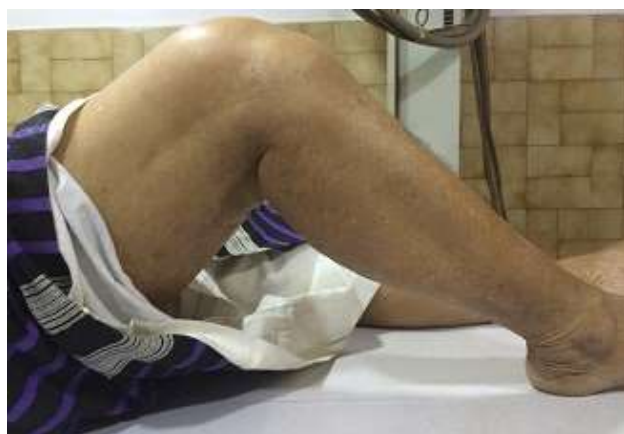

Figure 5: Follow-up at one year showing knee flexion of 70°.

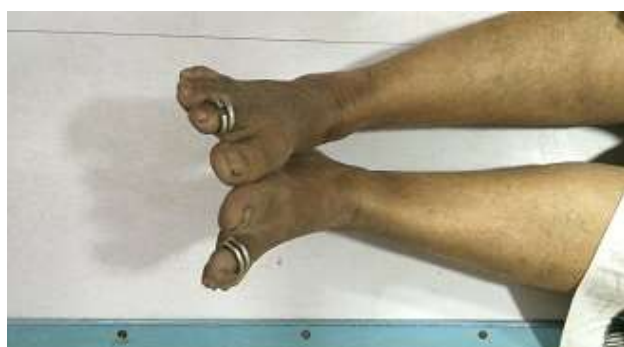

Figure 6: Follow-up at one year with no limb length discrepancy.

RESULTS

All 21 patients had union of the fracture site. The average knee range of motion (ROM) improved from 16° pre-operatively to 66° post-operatively at 6 month follow-up. The average knee society score improved from 54 pre-operatively to 74 post-operatively. One of our patients (AO Type C) had limited ROM (knee flexion of 30° at 6 months). All 20 other patients were well at last follow-up with good functional outcome. There were two patients with delayed surgical site healing which healed eventually. No secondary procedures of repeat bone grafting were required in our study. There were no infections or implant failures in our study. None of our patients were started on oral bisphosphonates although they were on supplemental calcium for a period of one year after surgery. Six of our patients complained of iliac crest site pain which eventually settled at 4 months following surgery. There were no donor site infection or anaesthesia reported.

DISCUSSION

Ebraheim et al conducted an extensive review of literature and found that non-unions of the distal femur are very rare and have specific pre-disposing factors as etiological causes.³ They reported however a union rate of 97.5% with an average tie to healing of 7.8 months which is comparable to our results.

Rodriquez et al showed in 28 cases of distal femur fractures treated primarily with plate and screws which did not progress to union that the various factors of obesity, smoking, age and diabetes were negative predictors of bone healing.⁴ They showed that each of these above factors contributed significantly to non-union with the non-union rates approaching 100% with more than one factor. In our study all our patients were treated by indigenous bone setters with native splints and they presented to us as primary non-unions.

Martin et al analysed 20 patients who had non-union following skeletal stabilisation and concluded that when compared to closed fractures, open fractures had a higher non-union rate (60.3% versus 80%) and also MIPPO techniques fared better than open techniques.⁵ In our study, all our patients underwent open reduction with removal of soft tissue and freshening of the edges with bone grafting. We reported a 100 % union rate with our study with good knee score.

Maheswari et al reported the use of adjuvant methods such as electrical stimulation, bone grafts, artificial bone substitutes in achieving a higher union rate.⁶ In our study however due to cost constraints we used autologous bone graft from the patients in favour of artificial bone substitutes.

Jun-Wen Wand et al treated 13 non-unions with a union rate of 100 % at 5 months with an average arc of motion

at 71° versus 66° in our study which is comparable.⁷ In our study we achieved union at 22.4 weeks which is slightly longer than their study.

Raju et al presented a series of resistant non-unions treated with custom mega prosthesis in 8 patients in which they showed an average knee society score of 88 which was slightly higher than our study but with the added financial burden of cost of the custom prosthesis.⁸

In our study however we achieved an average knee score of 74 which was good.

Waseem et al presented a case report of a non-union in a 77 year old elderly woman with open distal femur fracture.⁹ They used periodic pulsed electrical stimulation to achieve union at 16 weeks following open reduction and internal fixation.

Table 1: Comparison of union rates and union time with other similar studies.

Study	Union Rate (%)	Union time(weeks)
Ebraheim et al ³	97.5	31
Martin et al ⁵	94.5	34
Maheahwari t al ⁶	96	33
Jun-Wen et al ⁷	100	20
Present study	100	19

Table 2: Comparison of knee scores and ROM achieved.

Study	Knee ROM (flexion in degrees)	Knee score	Bone graft or substitutes	Remarks
Martin et al ⁵	70	71	Iliac crest	Nil
Maheshwari et al ⁶	74	76	Iliac crest	Used electrical stimulation
Jun-Wen et al ⁷	71	73	Artificial bone substitutes	Composite grafts
Raju et al ⁸	75	88	-	Custom prosthesis for failed non-unions
Present study	66	74	Iliac crest	Nil

CONCLUSION

Distal femur non unions are uncommon in the western world due to early hospital admission and early operative skeletal stabilisation with minimal invasive technique. In India the situation is quite contrasting with many of these complex fractures being treated by native bone setters and patients presenting to us after established non-unions. Even in established non-unions if the AO principles of good anatomical reduction, minimal soft tissues stripping and relative stability are adhered to, then these fractures will eventually heal. However patients must be counselled about the need for additional bone grafting and also the slow but painful rehabilitation process to restore knee movements as these patients often present with a stiff knee. In our study which is the largest so far reported in literature of established non-unions of distal femur, we have achieved a 100% union rate with significant improvement of both knee society score and range of movement from the pre-operative status.

Funding: No funding sources

Conflict of interest: None declared

Ethical approval: The study was approved by the institutional ethics committee

REFERENCES

- Westgeest J, Weber D, Dulai SK, Bergman JW, Buckley R, Beaupre LA. Factors Associated With Development of Nonunion or Delayed Healing After an Open Long Bone Fracture: A Prospective Cohort Study of 736 Subjects. J Orthop Trauma. 2016;30(3):149-55.
- Yue B, Ng A, Tang H, Joseph S, Richardson M. Delayed healing of lower limb fractures with bisphosphonate therapy. Ann R Coll Surg Engl. 2015;97(5):333-8.
- Ebraheim NA, Martin A, Sochacki KR, Liu J. Nonunion of distal femoral fractures: a systematic review. Orthop Surg. 2013;5(1):46-50.
- Rodriguez EK, Boulton C, Weaver MJ, Herder LM, Morgan JH, Chacko AT, et al. Predictive factors of distal femoral fracture nonunion after lateral locked plating: a retrospective multicenter case-control study of 283 fractures. Injury. 2014;45(3):554-9.
- Hoffmann MF, Jones CB, Sietsema DL, Tornetta III P, Koenig SJ. Clinical outcomes of locked plating of distal femoral fractures in a retrospective cohort. J Orthop Surg Res. 2013;8:43.
- Maheshwari P, Maheshwari P. Non Union Distal Femur Fracture: Causes and Management Options. Trauma Int. 2016;1(2):28-33.

7. Wang JW, Weng LH. Treatment of Distal Femoral Nonunion with Internal Fixation, Cortical Allograft Struts, and Autogenous Bone-Grafting. *J Bone Joint Surg Am*. 2003;85(3):436-40.
8. Vaishya R, Singh AP, Hasija R, Singh AP. Treatment of resistant nonunion of supracondylar fractures femur by megaprosthesis. *Knee Surg Sports Traumatol Arthrosc*. 2011;19:1137.
9. Waseem Z, Ford M, Syed K, Flannery J. Chronic nonunion in a patient with bilateral supracondylar

distal femur fractures treated successfully with twice daily low-intensity pulsed ultrasound. *PMR*. 2010;2(2):159-6.

Cite this article as: Balasubramanian N, Sindhuja P. Functional and radiological outcome following operative skeletal stabilisation with bone grafting in distal femur non-unions: a study of 21 patients. *Int J Res Orthop* 2017;3:150-4.