

2022

Metastatic Testicular Cancer Patient with Synchronous Oral Squamous Cell Carcinoma Presented with Gastrointestinal Bleeding: A Case Report

Manar F. Ashour

University of Babylon College of Medicine, Iraq, manarfashour@gmail.com

Sundus Nasim

Dow Medical College, Pakistan, sundusnasim9@gmail.com

Hallas M. kadhim

Imamein Kadhimein Medical City, Iraq, Hallas.alfartosi@gmail.com

Maan Faraj

University of Baghdad College of Medicine, Iraq, drfaraj.maan@gmail.com

Sylvia E. Eshak

Assiut University, Egypt, Sylvaisaac89@gmail.com

Follow this and additional works at: <https://scholar.rochesterregional.org/advances>



Part of the [Education Commons](#), [Medical Education Commons](#), and the [Medical Sciences Commons](#)

Recommended Citation

Ashour MF, Nasim S, kadhim HM, Faraj M, Eshak SE. Metastatic Testicular Cancer Patient with Synchronous Oral Squamous Cell Carcinoma Presented with Gastrointestinal Bleeding: A Case Report. *Advances in Clinical Medical Research and Healthcare Delivery*. 2022; 2(4). doi: 10.53785/2769-2779.1112.

ISSN: 2769-2779

This Case Report is brought to you for free and open access by RocScholar. It has been accepted for inclusion in *Advances in Clinical Medical Research and Healthcare Delivery* by an authorized editor of RocScholar. For more information, please contact Advances@rochesterregional.org.

Metastatic Testicular Cancer Patient with Synchronous Oral Squamous Cell Carcinoma Presented with Gastrointestinal Bleeding: A Case Report

Author ORCID ID:
0000-0002-4140-6176

Abstract

Testicular cancer is a curable oncologic disease of males mostly aged 15-44 years. Most of the patients are successfully treated with radical orchiectomy. However, a delayed presentation may lead to a dismal prognosis. There are several risk factors including cryptorchidism, a first-degree relative with testicular cancer, hypospadias, childhood inguinal hernia, and military pollutant exposure, among others. The distant metastasis of testicular carcinoma to the lung, liver, and brain are widely described. We present a unique case of a 28-year-old male who presented with gastrointestinal (GI) bleeding. Later, it was discovered that he had a metastatic testicular carcinoma synchronous with an oral squamous cell carcinoma. Metastasis was detected by imaging including X-ray, computerized tomography (CT) of the chest, abdomen, and brain magnetic resonance imaging (MRI). The presence of two primary cancers concurrently is rare and indicates a poor prognosis. Because of the absence of risk factors in this patient, he was thought to be potentially exposed to depleted uranium from warfare due to his residence in Iraq. Markedly raised beta-human chorionic gonadotropin (b-HCG) titers indicate a possible non-seminomatous type; however, the exact type is unknown as the patient declined fine needle aspiration (FNA)/biopsy and orchiectomy. This case focuses on the atypical presentation and the importance of when to seek medical attention, as a delayed presentation can lead to a poor prognosis. Moreover, it heightens awareness that other malignancies may occur concurrently. As well as to emphasize on means that can be used to educate high-risk groups.

Keywords

testicular cancer, oral squamous cell carcinoma, gastrointestinal bleeding, middle east, Iraq.

Conflict of Interest Statement

The authors have no conflict of interest to declare.

Cover Page Footnote

I would like to express my deepest appreciation to Dr. Deborah Marie Rib for her generous support and participation. As well as words cannot express my gratitude to everyone who participate in this research by any means.

CASE REPORT

Metastatic Testicular Cancer Patient with Synchronous Oral Squamous Cell Carcinoma Presented with Gastrointestinal Bleeding: A Case Report

Manar F. Ashour ^{a,*}, Sundus Nasim ^b, Hallas M. kadhim ^c, Maan Faraj ^d, Sylvia E. Eshak ^e

^a University of Babylon College of Medicine, Iraq

^b Dow Medical College, Pakistan

^c Imamein Kadhimein Medical City, Iraq

^d University of Baghdad College of Medicine, Iraq

^e Assiut University, Egypt

Abstract

Testicular cancer is a curable oncologic disease of males mostly aged 15–44 years. Most of the patients are successfully treated with radical orchiectomy. However, a delayed presentation may lead to a dismal prognosis. There are several risk factors including cryptorchidism, a first-degree relative with testicular cancer, hypospadias, childhood inguinal hernia, and military pollutant exposure, among others. The distant metastasis of testicular carcinoma to the lung, liver, and brain are widely described. We present a unique case of a 28-year-old male who presented with gastrointestinal (GI) bleeding. Later, it was discovered that he had a metastatic testicular carcinoma synchronous with an oral squamous cell carcinoma. Metastasis was detected by imaging including X-ray, computerized tomography (CT) of the chest, abdomen, and brain magnetic resonance imaging (MRI). The presence of two primary cancers concurrently is rare and indicates a poor prognosis. Because of the absence of risk factors in this patient, he was thought to be potentially exposed to depleted uranium from warfare due to his residence in Iraq. Markedly raised beta-human chorionic gonadotropin (b-HCG) titers indicate a possible non-seminomatous type; however, the exact type is unknown as the patient declined fine needle aspiration (FNA)/biopsy and orchiectomy. This case focuses on the atypical presentation and the importance of when to seek medical attention, as a delayed presentation can lead to a poor prognosis. Moreover, it heightens awareness that other malignancies may occur concurrently. As well as to emphasize on means that can be used to educate high-risk groups.

Keywords: Testicular cancer, Oral squamous cell carcinoma, Gastrointestinal bleeding, Middle east, Iraq

1. Introduction

Testicular cancer is a rare tumor in the general population. In the United States, men between 15 and 44 years old are at the highest risk for this cancer. In the years 1992–2011, rates of testicular germ cell tumor in the US increased significantly (Annual Percentage Change of 1.11, p -value < 0.0001), with a more remarkable rise in non-seminomas.¹ Comparatively, in Iraq, testicular

cancer usually affects men in the third and fourth decade of life, according to the country's cancer registry (1985–1996).² The annual incidence between 1986 and 1988 in ages 25–29 and 30–34 was recorded as 1.1% in each group, respectively.³ This incidence might not reflect the recent statistics, as the current data is limited. Testicular germ cell tumors are classified into seminomas and non-seminoma according to histological features. Non-seminomas are further classified into choriocarcinoma, embryonal

Accepted 14 September 2022.
Available online 21 December 2022

* Corresponding author.
E-mail address: manarfashour@gmail.com (M.F. Ashour).

<https://doi.org/10.53785/2769-2779.1112>
2769-2779/© 2022 Rochester Regional Health.

carcinoma, teratoma, and yolk sac carcinoma.⁴ We present the case of a 28-year-old Iraqi male who presented with gastrointestinal bleeding, and it was subsequently discovered that the etiology was metastatic testicular cancer of possible nonseminoma type. In addition, it was discovered that the patient had a simultaneous primary malignancy, an oral squamous cell carcinoma. The patient had skin lesions that were initially considered to be a result of metastasis, based on previous reports of their occurrence.⁵ This case report will highlight the need for patient and provider awareness of unusual manifestations of testicular cancer and increasing awareness that other malignancies may occur concurrently, even in young patients (particularly when exposed to radiation). It also addresses the provision of relevant information to decrease stigma about the evaluation of testicular swellings.

2. Case presentation

A 28-year-old previously healthy male presented to the emergency department with complaints of bleeding per-rectum associated with dizziness, fatigue, and mild dyspnea. The patient had two episodes of hemoptysis in the last month. He denied other symptoms, such as fever, weight loss, and night sweats. His past medical history was insignificant. He denied any smoking or drug use. The patient quit alcohol use a few years ago. Family history was irrelevant, and there were no occupational hazards. The patient has had a possible radiation exposure due to his residence in Iraq. Upon further questioning after the initial evaluation, the patient admitted to having testicular swellings for two years.

Physical examination revealed a male in moderate distress with pallor, poor air entry with a diffuse decrease in breath sounds, and reduced chest expansion bilaterally with no noted lymphadenopathy, organomegaly, or ascites. Multiple skin lesions were noted on the right side of each perioral region (Fig. 1A), axilla, and chest wall. Oral cavity mass was noticed (Fig. 1B). The patient stated that the skin lesions and the oral cavity mass started around one month back. The patient deferred pelvic examination.

We admitted the patient to the hospital for suspected upper or lower gastrointestinal bleeding. The initial investigations were ordered (Table 1). A blood smear showed microcytic and hypochromic anemia. We initiated supportive treatment, including IV fluids and blood transfusion. Oesophago-Gastro-Duodenoscopy (OGD) ruled out upper gastrointestinal bleeding.

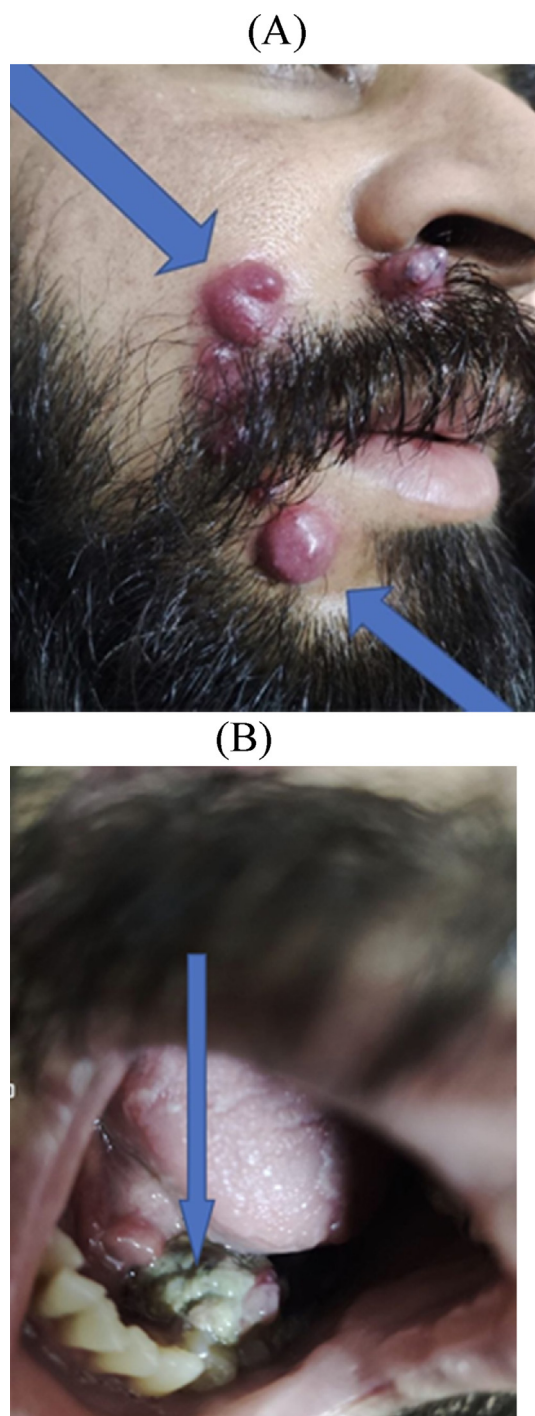


Fig. 1. (A) multiple right side perioral skin lesions. (B) Oral cavity mass.

Chest x-ray exhibited multiple lung lesions (cannonball metastases, Fig. 2A). CT scan of the chest with contrast showed multiple bilateral pulmonary masses of variable size with central necrosis and peripheral wall enhancement, largest mass size (78*53 mm) was seen in the right lower lobe

Table 1. Labs at the time of admission.

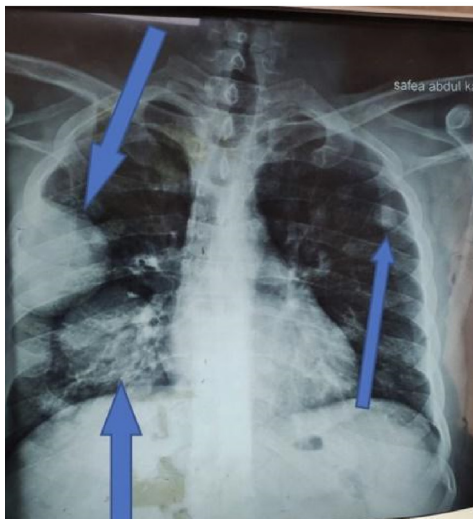
CBC:	
Hemoglobin:	5.4 g/dL (ref: 12.0–16.0 g/dL)
Hematocrit:	17.7% (ref: 38–52%)
MCV:	80.8 (ref: 76–96 f/L)
Platelet count:	264 (ref: 155–450 103/uL)
Metabolic panel:	
Glucose:	144.8 (ref: 70–115 mg/dL)
Urea:	47.1 (ref: 15–40 mg/dL)
Sodium:	123.7 (ref: 135–145 mmol/L)
CRP HS:	30.54 (ref: <5 mg/L)
PT:	12 (ref: 11–15 s)
PTT:	34 (ref: 25–40 s)
INR:	1.1 (ref: 0.8–1.2)

(Fig. 2B), which supported our suspicion of pulmonary lesions to be secondary.

In addition, scrotal ultrasound showed an enlarged left testicle, heterogeneous echo texture with significantly increased vascularity, containing multiple ill-defined solid masses, largest mass measuring 30*22 mm in size, while the right testicle was normal. In addition, an abdominal CT scan demonstrated multiple small liver masses with peripheral ring enhancement, which confirmed liver metastasis; the largest mass measured 1.5 cm in segment V (Fig. 3). Additional labs were ordered, and the results were as follows: high LDH (746.4 U/L, N = up to 250 U/L), high Alpha Feto Protein (13.41IU/ml, N = up to 8.0IU/ml), and high Beta-HCG (10,000 IU/L, N = less than 2.0).

An incisional biopsy from the lingual gingival mass was made to investigate the initial impression from distant metastasis. The biopsy findings were consistent with a poorly differentiated squamous cell carcinoma (Fig. 4). Since the patient declined orchiectomy and FNA/biopsy from distant metastasis such as lung or liver; clinical presentation, radiology, and tumor markers remained the mainstay of diagnosis. Supportive therapy was provided

(A)



(B)

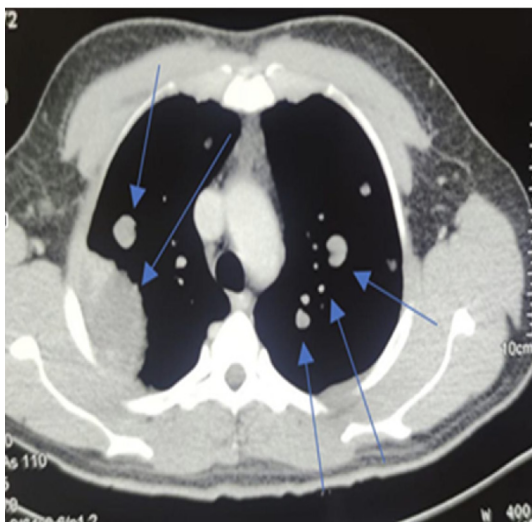


Fig. 2. (A) Chest X-ray showed multiple masses (cannonball metastases). (B) CT chest with contrast showing multiple lung masses.

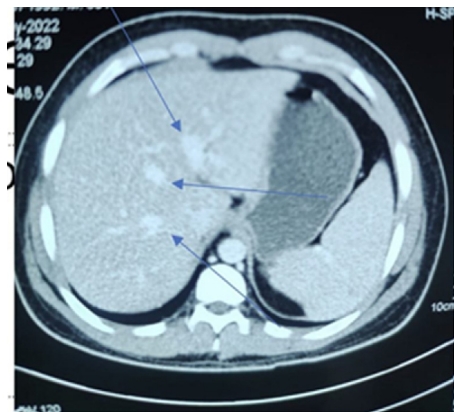


Fig. 3. CT abdomen with multiple liver masses.

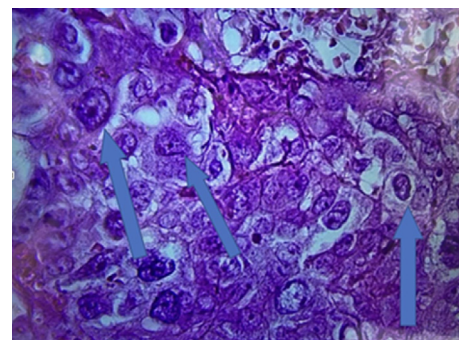


Fig. 4. Malignant squamous cells.

including pain management, fluid resuscitation, and blood transfusion.

While preparing the patient for colonoscopy to investigate the source of bleeding, a sudden seizure was developed. Consequently, a brain MRI was performed to evaluate the cause of the seizure. It showed numerous supra and infratentorial lesions, highly suggestive of hemorrhagic metastasis. He then lapsed into a coma. His condition deteriorated rapidly within a few days, and he died from multiple organ failure.

3. Discussion

An increase in the incidence of testicular cancer in the United States has been a cause of concern. Between the years 1992–2011 (Annual Percentage Change of 1.11, p -value <0.0001), with a greater rise in non-seminomas of all solid male cancers in the United States.¹ According to the data from the cancer registry in Iraq, from 1986 to 1988, testicular cancer had a low incidence but a contrastingly high mortality rate. The annual incidence of testicular cancer in Iraq from 1986 to 1988 was 0.63% in ages 20–24, 1.1% in ages 25–29, and 1.1% in ages 30–34.³ Due to limited recent data about the effects of warfare on Iraqis, this incidence might not be a great reflection of today's cancer statistics. The expected rise in the incidence of various cancers in Iraq may be attributed to military pollutant exposure, owing to the involvement in warfare. High levels of uranium crystals (average 1.6 $\mu\text{g/L}$, normal for healthy females 1.03 $\mu\text{g/L}$) in the tissues of cancer patients in Baghdad, Iraq, have been found. Researchers discovered that cancer tissue samples from middle and southern Iraq contain higher depleted uranium when compared with noncancerous diseases.⁶ Our patient was an Iraqi resident, so this evidence can be considered. Faa A et al. described the effect of depleted uranium on the Croatian population postwar from 1996 to 2012. He reported 3.5 times increase in the incidence of non-seminomas and seminomas.⁷ Unfortunately, due to limited resources in Iraq, the confirmed presence of uranium isotope decay in this patient's tissues was not investigated. This is indeed a valid area for future inquiry. Other risk factors for testicular cancer including cryptorchidism, a first-degree relative with testicular cancer, hypospadias, and a childhood inguinal hernia were not found in this patient.⁴

Testicular cancer can present as a painless swelling, mass with dull pain, and acute testicular pain. Systemic symptoms like malaise or weight loss can be seen. Pulmonary spread may lead to cough, dyspnea, and hemoptysis. In contrast, a retro

duodenal spread from the testes through the lymphatics presents with gastrointestinal symptoms like nausea, vomiting, or bleeding. Lymphadenopathy and a varicocele from the retroperitoneal spread are also possible.^{4,8} Our patient presented with bleeding per rectum, dyspnea, hemoptysis, and fatigue. GI metastasis is more associated with non-seminoma testicular cancer.⁸ Since the patient expired before investigations like positron emission tomography scan, biopsy, or colonoscopy could be performed; the exact cause of GI bleeding in this patient remains unknown. Whether this GI bleeding was due to metastasis from testicular cancer, oral SCC, or an independent finding remains a question of interest.⁹

Brain metastasis occurs in 28.6–36% of patients with testicular germ cell tumors. It can carry a poor prognosis, although some patients may benefit from aggressive chemotherapy, radiation, or surgical intervention.¹⁰ In our case, the patient presented late, and brain metastasis was discovered after he developed a seizure. Brain MRI confirmed the presence of metastasis as multiple hemorrhagic lesions.

The occurrence of skin lesions due to testicular cancer is not an unknown finding. Vanidassane I. et al. describe a case of testicular cancer presenting with an ulceroproliferative skin lesion with morphology like the non-seminomatous germ cell tumor found in the testis.¹¹ A metastatic germ cell tumor presenting as a pigmented non-tender swelling on the skin of the sternum and the chin area has also been described.¹² Our patient also had right perioral, axillary, and chest wall skin lesions; however, the relation of these lesions with testicular cancer was not proven as he expired before a biopsy could be done. To the best of our knowledge, interdiction of autopsy due to cultural or religious reasons by the patient and his family prohibited further inquiry.

Metastasis to the oral cavity is uncommon, about 1%. It usually occurs in the bone and soft tissues of the mouth and is an indicator of poor prognosis.¹³ Gingival involvement by a metastatic testicular cancer is seen as a fleshy soft tissue swelling or a typical epulis.^{12,14} Our patient had a lingual gingival mass, which was initially believed to be a consequence of metastasis.

Contrary to our assumption, biopsy results revealed a poorly differentiated squamous cell carcinoma. The simultaneous presence of oral squamous cell carcinoma with testicular carcinoma was unusual. Oral squamous cell carcinoma is becoming increasingly common in the young population (age ≤ 45 years) with unknown risk factors, according to a 2021 retrospective cohort study. It is usually found

in association with head and neck cancers. Known etiological factors include alcohol in the West and chewing tobacco in South Asia. While regional metastasis is common, distant metastasis most commonly to the lung is seen. Metastasis to the testis is not known. Biopsy, histopathology, and salivary biomarkers for diagnosis are essential. Constant vigilance and aggressive treatment are advised to improve survival outcome.^{15,16} Our patient had no known risk factors for oral cancer.

Early detection of testicular cancer increases the chances of a complete cure. Surgical orchiectomy is the mainstay of the treatment; chemotherapy and radiation are often used. The delayed presentation can lead to complications and metastasis, decreasing the chance of complete cure.⁴

In this case, we aim to highlight the importance of education on testicular swellings and seeking prompt medical attention in high-risk groups to improve survival outcomes. Fariduddin M.M. et al. also describe a similar case where a young male did not seek immediate evaluation of his testicular swelling. In his case, the testicular mass was painless and self-limiting, causing a delay in presentation and an ominous outcome.¹⁷ Medical professionals must provide adequate information about testicular self-exams to patients with risk factors.¹⁸ This can be addressed by teaching young males the importance of reporting testicular swellings; providing brochures, pamphlets, and videos in settings including schools, colleges, universities, and workplaces.¹⁹ According to the American Cancer Society, regular self-examination and physician screening do not improve outcome in asymptomatic males; however, these are essential for patients with risk factors.²⁰

4. Conclusion

Patients with testicular cancers can achieve a complete cure. However, in this case, an extensive cancer burden caused a fatal outcome. Increased awareness and early detection in high-risk groups will lead to prompt radical treatment and prevention of long-term complications. Keeping in mind the cultural stigma about testicular cancer combined with reluctance to seek primary care in Iraqi males, an outreach approach might be the solution to these challenges. Emphasis on a cost-effective annual physical examination and questioning young males about testicular swellings is a pressing priority. Similarly, increased education through brochures in the local language about reporting suspicious swellings may provide an improved outcome.

Acknowledgements

The authors express their deepest appreciation to Dr. Deborah Marie Rib for her generous support and participation.

Conflict of interest

The authors have no conflict of interest to declare.

References

- Ghazarian AA, Kelly SP, Altekruze SF, Rosenberg PS, McGlynn KA. Future of testicular germ cell tumor incidence in the United States: forecast through 2026. *Cancer*. 2017; 123(12):2320–2328. <https://doi.org/10.1002/cncr.30597>.
- Zangana AM, Razak AB. A giant testicular teratoma. *Saudi Med J*. 2007;28(3):465–467.
- Denic S. Frequency and management of germ-cell tumors in a third-world country. *Oncol Rep*. 1998;5(5):1241–1244. <https://doi.org/10.3892/or.5.5.1241>.
- Nauman M, Leslie SW. Nonseminomatous testicular tumors. In: *StatPearls. Treasure Island (FL)*. StatPearls Publishing; 2022. May 27.
- Shimizu S, Nagata Y, Han-yaku H. Metastatic testicular choriocarcinoma of the skin. Report and review of the literature. *Am J Dermatopathol*. 1996;18(6):633–636. <https://doi.org/10.1097/00000372-199612000-00016>.
- Al-Shammari AM. Environmental pollution associated to conflicts in Iraq and related health problems. *Rev Environ Health*. 2016;31(2):245–250. <https://doi.org/10.1515/reveh-2015-0024>.
- Faa A, Gerosa C, Fanni D, et al. Depleted uranium and human health. *Curr Med Chem*. 2018;25(1):49–64. <https://doi.org/10.2174/0929867324666170426102343>.
- Kabir Y, Kleynberg RL, Rotblatt MD, Miller JM, Feldman NR. The case of the missed physical examination: testicular carcinoma presenting as a GI bleed. *J Clin Oncol*. 2013;31(20):e338–e340. <https://doi.org/10.1200/JCO.2012.45.2680>.
- Tarangelo NP, Kistler CA, Daitch Z, Jiang W, Quirk DM. Synchronous gastric and duodenal metastases from head and neck squamous cell carcinoma: a unique presentation of upper gastrointestinal bleeding. *Ann Gastroenterol*. 2018;31(3):381–383. <https://doi.org/10.20524/aog.2018.0235>.
- Nishizaki T, Orita T, Tsuha M, Wakuta Y, Fujii M, Ito H. Brain metastasis of testicular tumor with massive hemorrhage—report of two cases. *Neurol Med -Chir*. 1991;31(9):586–589. <https://doi.org/10.2176/nmc.31.586>.
- Vanidassane I, Mittal A, Kumar C, Tanwar P, Sahoo RK, Batra A. Skin metastasis: a rare presentation in testicular germ cell tumour. *BMJ Case Rep*. 2018;2018. <https://doi.org/10.1136/bcr-2018-226385>. bcr2018226385. Published 2018 Sep 23.
- Bhatia K, Vaid AK, Rawal S, Patole KD. Pure choriocarcinoma of testis with rare gingival and skin metastases. *Singap Med J*. 2007;48(3):e77–e80.
- Gomes JB, Santos PS, Felix VB, Prospero JD, Nunes CC, de Freitas RR. Oral lesion as the first manifestation of choriocarcinoma of the testicle. *J Clin Oncol*. 2009;27(9):1522–1523. <https://doi.org/10.1200/JCO.2008.20.2226>.
- Lee L, Oppenheimer R, Jayaram L. Germ cell tumor metastatic to the oral cavity. *Ear Nose Throat J*. 2012;91(4):172–173. <https://doi.org/10.1177/014556131209100410>.
- Farhat MC, Dyalram D, Ord RA, Lubek JE. Oral squamous cell carcinoma in patients aged 45 and younger: prognosis, survival, and quality of life. *Oral Surg Oral Med Oral Pathol Oral Radiol*. 2022;133(5):518–525. <https://doi.org/10.1016/j.oooo.2021.08.023>.
- Bugshan A, Farooq I. Oral squamous cell carcinoma: metastasis, potentially associated malignant disorders, etiology and recent advancements in diagnosis. *F1000Res*. 2020;9:229.

- <https://doi.org/10.12688/f1000research.22941.1>. Published 2020 Apr 2.
17. Fariduddin MM, Syed W, Naqvi M. A case to overcome the stigma of testicular cancer. *Cureus*. 2021;13(1), e12994. <https://doi.org/10.7759/cureus.12994>. Published 2021 Jan 29.
 18. Ugboma HA, Aburoma HL. Public awareness of testicular cancer and testicular self-examination in academic environments: a lost opportunity. *Clinics*. 2011;66(7):1125–1128. <https://doi.org/10.1590/s1807-59322011000700001>.
 19. Thornton CP. Best practice in teaching male adolescents and young men to perform testicular self-examinations: a review. *J Pediatr Health Care*. 2016;30(6):518–527. <https://doi.org/10.1016/j.pedhc.2015.11.009>.
 20. American Cancer Society. Testicular cancer signs and symptoms. Available at: <https://www.cancer.org/cancer/testicular-cancer/detection-diagnosis-staging/signs-and-symptoms.html>. Accessed August 23, 2022.