



Nasal septum extramedullary plasmacytoma

Ekstramedularni plazmocitom nosnog septuma

Branislav Belić*, Slobodanka Mitrović†, Snežana Arsenijević‡, Ljiljana Erdevički‡, Jasmina Stojanović§, Stevan Stojanović‡, Radojica Stolić*

*Faculty of Medicine, University of Priština/Kosovska Mitrovica, Kosovska Mitrovica, Serbia; †Department of Histopathology, §Ear, Nose and Throat Clinic, Clinical Center Kragujevac, Kragujevac, Serbia, ‡Faculty of Medical Sciences, University of Kragujevac, Kragujevac, Serbia

Abstract

Introduction. Plasmacytomas are malignant tumors characterized by abnormal monoclonal proliferation of plasma cells. They originate in either bone – solitary osseous plasmacytoma, or in soft tissue – extramedullary plasmacytoma (EMP). EMP represents less than 1% of all head and neck malignancies. **Case report.** We presented a case of EMP of the nasal septum in a 44-year-old male who had progressive difficulty in breathing through the nose and frequent heavy epistaxis on the right side. Nasal endoscopy showed dark red, soft, polypoid tumor in the last third of the right nasal cavity arising from the nasal septum. The biopsy showed that it was plasmacytoma. Bence Jones protein in the urine, serum electrophoresis, bone marrow biopsy, skeletal survey and other screening tests failed to detect multiple myeloma. This confirmed the diagnosis of EMP. The mass was completely removed *via* an endoscopic approach, and then, 4 week later, radiotherapy was conducted with a radiation dose of 50 Gray. No recurrence was noted in a 3-year follow-up period. **Conclusion.** EMP of the nasal cavity, being rare and having long natural history, represents a diagnostic and therapeutic challenge for any ear, nose and throat surgeon. Depending on the resectability of the lesion, a combined therapy is the accepted treatment.

Key words:

plasmacytoma; nasal septum; diagnosis; differential; otorhinolaryngological surgical procedures; radiotherapy; treatment outcome.

Apstrakt

Uvod. Plazmocitomi predstavljaju maligne tumore koji se karakterišu abnormalnom proliferacijom plazma ćelija poreklom iz jednog klona. Nastaju ili u kostima – usamljeni koštani plazmocitom, ili u mekim tkivima – ekstramedularni plazmocitom (EMP). Manje od 1% svih malignih tumora glave i vrata čini EMP. **Prikaz bolesnika.** U radu je prikazan muškarac star 44 godine sa EMP, koji se javio na pregled zbog progresivnog otežanog disanja na nos i čestih epistaksi iz desne nosne šupljine. Endoskopijom nosa uočen je tamnocrven, mek, polipoidni izraštaj u zadnjoj trećini desne nosne šupljine, polazišta sa nosne pregrade. Patohistološki (PH) nalaz ukazao je na plazmocitom. U urinu nije bio Bence-Jonesovih proteina, elektroforeza seruma, biopsija koštane srži, RTG nalazi skeleta i ostali skrining testovi nisu pokazali da se radi o multiplom mijelomu, što je potvrdilo dijagnozu EMP. Tumor je kompletno uklonjen endoskopskim pristupom, a 4 nedelje nakon operacije, sprovedena je zračna terapija, radijacijskom dozom od 50 Gray-a. Tokom 3-godišnjeg praćenja bolesnika nije ustanovljen recidiv tumora. **Zaključak.** Zbog svog rariteta i nespecifičnih simptoma, koji mogu dugo da budu neprepoznati, EMP nosa predstavlja i dijagnostički i terapijski izazov za svakog otorinolaringologa. U odnosu na operabilnost tumora, kombinovan pristup (hirurgija i radioterapija) predstavlja prihvatljiv tretman.

Ključne reči:

plazmocitom; nos, septum; dijagnoza; diferencijalna; hirurgija, otorinolaringološka, procedure; lečenje, ishod.

Introduction

Plasmacytomas are malignant tumors characterized by abnormal monoclonal proliferation of plasma cells. They originate in either bone (solitary osseous plasmacytoma) or in soft tissue (extramedullary plasmacytoma – EMP)¹, and could be either primary (without evidence of disease in other foci) or a part of a systemic process during

the course of multiple myeloma. The etiology of EMP is unknown.

The first case of EMP was reported in 1905 by Schridde.² Alexiou et al.³ reviewed all previous reports of EMP and found 869 cases; 714 (82.2%) of them had occurred in the upper aerodigestive tract. The most frequently affected areas in the upper aerodigestive tract were the nasal cavity or paranasal sinuses (43.8%), followed by nasophar-

ynx (18.3%), oropharynx (17.8%), and larynx (11.1%)³. Wax et al.⁴ report that 75% of extramedullary plasmacytomas occur in the sinonasal/nasopharyngeal area, 12% in the oropharynx, 8% in the larynx. Other sites in the head and neck that have been reported include the tongue, minor salivary glands, thyroid, parotid, orbit and temporal bone⁴. EMP affects men 3–4 times more often in women and typically occurs in the 6th to 7th decade, with over 95% of cases occurring in patients above 40 years of age⁵. EMP is a destructive tumor and, beside the tendency for local recurrence^{5,6}, has the ability to spread to regional lymph nodes and ability for distant metastasis with progression to multiple myeloma. EMP is rare tumor and represents less than 1% of all head and neck malignancies^{7,8} and it accounts for 4% of all nonepithelial tumors of the nasal cavity, nasopharynx, and paranasal sinuses⁹.

The rarity of this tumor and its long natural history represent a diagnostic and therapeutic challenge for any ear, nose and throat (ENT) surgeon. To exclude multiple myeloma or plasmacytoma of the bone, a systemic work-up and follow-up of the patient are mandatory, including serum protein electrophoresis, urin analysis for the Bence-Jones protein, skeletal survey and bone marrow biopsy^{10,11}. The optimal management of EMP is controversial. However, based on the well-known radiation sensitivity of plasma-cell tumors, radiotherapy is generally, accepted as the treatment of choice for EMP, while the role of chemotherapy in these tumors is not well-defined¹². Surgery can achieve high rates of local control in certain situations. However, radical excision is often impossible due to the size or the location of the tumor¹³.

Most reports in the literature, relating to EMP, are descriptions of individual cases. In this paper we described an interesting case of EMP of nasal septum.

Case report

A 44-year-old male was admitted to the ENT Clinic, Clinical Center in Kragujevac, due to progressive difficulty in breathing through the nose at the right side in the last year and frequent heavy epistaxis from the same side. Because of that, in the past month, the patient was admitted to anterior nasal packing three times. The patient was in good physical condition, not consuming alcohol nor cigarettes, and not suffering from any chronic disease.

Nasal endoscopy showed dark red, soft, polypoid tumor, slightly bleeding to touch, in the right nasal cavity, approximately 2.5 cm in diameter, arising from the last third of the nasal septum and provoking obstruction almost in the entire nasal cavity, especially in its last third. The tumor extended toward the choana and obstructed it.

Computed tomography of the nasal cavities and paranasal sinuses with intravenous contrast showed a heterogenous soft tissue mass, dimensions of approximately 3.5 × 2.0 × 1.5 cm, which arised from the last third of nasal septum, filling the right nasal cavity with signs of mass effect of the medial wall of the right maxillary sinus, locally thinned with no signs of erosion. In the right maxillary sinus there was a content of thicker consistency (Figure 1).

No cervical lymph nodes were palpable. Ultrasonography of the neck and abdomen showed normal findings, and lung X-ray did not show the presence of secondary deposits.

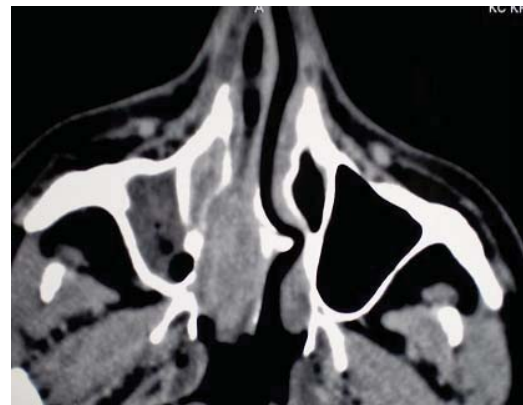


Fig. 1 – Computed tomography of paranasal sinuses (axial view) shows a heterogenous soft tissue mass in the right nasal cavity which arised from the last third of the nasal septum and obstructing the choana

We performed biopsy of the tumor endoscopically. Histopathologic findings, complemented by immunohistochemical examination, fully stressed the intermediate differentiation (Gr. 2 – intermediate grade) extramedullary tumor originating from plasma cells (tumor cells were clearly positive for CD79 α , MUM-1, CD138, CD38 and lambda) (Figure 2).

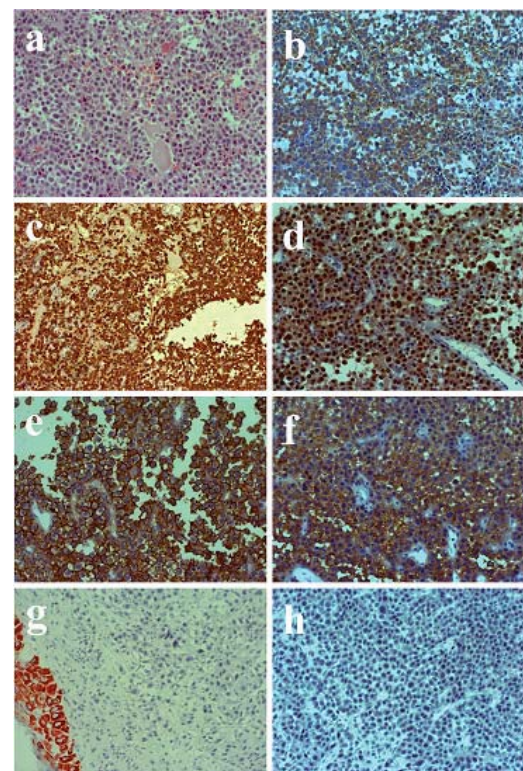


Fig. 2 – Histological and immunohistochemical characteristics of plasmacytomas (original magnification, × 200)

a) HE staining techniques – the tumor is easily constructed from polymorphic cells, high N/C ratio, large roundish nuclei, prominent nucleoli, basophilic cytoplasm easy; immunohistochemically, the cells were plasmacytomas: b) lambda positive, c) intensively express CD79 α , d) MUM1, e) CD138 and f) CD38, while negative for: g) Ael/Ae3 and h) CD20.

After this histopathologic findings, a systemic work-up to exclude (or confirm) multiple myeloma was performed. Renal and liver function were normal. Measurements of hematocrit, white blood cells, blood urea, serum creatinine, serum electrolytes, serum calcium, serum protein electrophoresis and immunoelectrophoresis were within normal limits. Bone marrow biopsy and complete skeletal radiographic survey (skull, AP and profile of cervical, thoracic and lumbar spine, chest, pelvis and long bones of extremities) were negative. Bence Jones protein was absent in the urine.

Since the possibility of multiple myeloma was excluded, the diagnosis of solitary extramedullary plasmacytoma of the nasal septum, stage 1 according to Wiltshaw, was established. Because of the size and location of the tumor, we decided to combine therapeutic approach. The patient underwent complete surgical removal of the tumor *via* transnasal endoscopy. Four week later, the patient received radiotherapy with a radiation dose of 50 Gray in 25 fractions.

No recurrence was detected at clinical examination or at CT scan performed during the first (Figure 3), second and third year after the treatment.

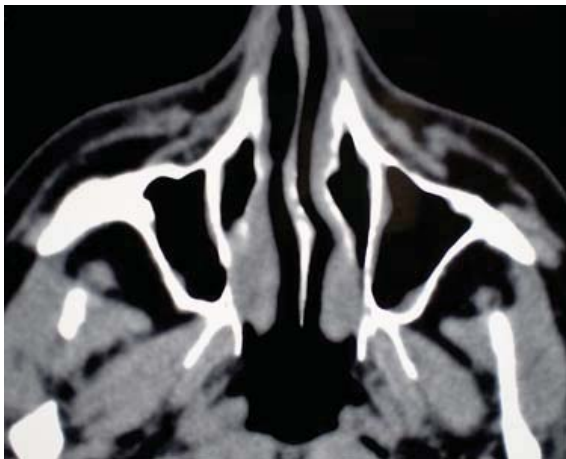


Fig. 3 – Computed tomography of paranasal sinuses (axial view) a year after the treatment, shows the normal anatomy

Discussion

It is important for otolaryngologists to recognize EMP since 80% of EMP occur in the head and neck as single lesions and 10%–20% of cases may present with multiple lesions⁶. This tumor is characterized by a slow clinical course, atypical symptoms, noncharacteristic clinical picture and untimely recognition. The diagnosis is somewhat difficult to made because of nonspecific CT and MRI features of solitary EMP of the sinonasal tract¹⁴. Although several reports regarding EMP in the nasal cavity have been published so far, a finding of such a lesion in the nasal septum is quite rare. For all these reasons, initially we were not thinking of EMP in the presented patient.

Physical examination usually reveals submucosal, dark red to grayish red, sessile or polypoid tumor, which bleeds easily with manipulation. The mucosa is typically intact but ulceration and necrosis may occur in advanced cases. Clinical

presentation is primarily a function of the mass effect and varies according to the site of involvement. Because most of these lesions arise in the sinonasal or nasopharyngeal area, the most common symptoms are nasal mass, nasal obstruction, and epistaxis¹⁵. In Kapadia et al.⁵ series of 20 patients of EMP of the head and neck, 80% of patients presented with the complaint of a mass or swelling, 35% of patients complained of airway obstruction, 35% complained of epistaxis, 20% of localized pain, 15% with proptosis, 10% with nasal discharge, 10% with regional lymphadenopathy, and 5% with a VI nerve palsy.

The diagnosis of EMP usually follows histologic examination. Immunohistochemical staining will demonstrate the monoclonal nature of plasma cells and confirm the neoplastic nature of the lesion. In addition, immunohistochemical study, too, is used to differentiate EMP from other malignant disorders, such as undifferentiated carcinoma, melanoma, and esthesioneuroblastoma^{15,16}. When plasmacytoma is confirmed histologically, secondary diagnostic procedures must be carried out to exclude systemic involvement. A systemic work-up including complete blood profile, renal and liver function, calcium, serum and urinary protein electrophoresis, serum immunoglobulin level, complete skeletal radiographic survey and bone marrow biopsy.

After the diagnosis have been confirmed, EMP can be staged as follows: stage 1 – limited to an extramedullary site (localized and controllable disease), stage 2 – involvement of regional lymph nodes or local extension, and stage 3 – multiple metastasis (although it is no longer a solitary plasmacytoma). In our case the finding confirmed the diagnosis of stage 1 extramedullary plasmacytoma.

The treatment of localized EMP of the head and neck somewhat is controversial. Some authors advocate radiation therapy alone and others advocate surgery alone. Based on the documented radiation sensitivity of plasma cell tumors, the accepted treatment is radiotherapy, but radiotherapy does not always reduce the size of the tumor, perhaps because of an abundant deposition of amyloid within the mass^{17–19}. Therefore, most clinicians recommend a combined approach (surgery and radiotherapy) for the management of nasal cavity extramedullary plasmacytoma^{6,19–22}. In fact, a combination treatment may provide the best results. Alexiou et al.³ in their review of 714 cases of upper aerodigestive tract extramedullary plasmacytomas reported between 1905–1997, found that the median overall survival or recurrence free survival was longer than 300 months for patients who underwent combined surgery and radiotherapy as compared to a median survival rate of 144 months for patients who underwent only radiotherapy and 156 months for only surgically managed patients. Chemotherapy may be considered for patients with refractory or relapsed disease.

The median survival of patients varies from 4–10 years. Local recurrence has been reported to occur in 8%–30% of adequately treated EMP in the upper aerodigestive tract^{6,23}. Because of the tendency of EMP to progress into disseminated multiple myeloma (conversion of EMP to multiple myeloma has been reported in 8%–36% of cases within 3 to 61 months),²⁴ a lifelong follow-up of these patients is rec-

ommended. CT and measurements of serum immunoglobulin and urinary Bence Jones protein levels may be useful in detecting recurrence or conversion to multiple myeloma²⁵.

Conclusion

Extramedullary plasmacytoma of the nasal cavity is rare and should be considered in the differential diagnosis

of nasal cavity masses. A multidisciplinary approach (haematologist, otorhinolaryngologist, pathologist, radiation oncologist, radiologist) is required for the optimal diagnosis and management of EMP. It is essential to exclude any systemic involvement before arriving at a diagnosis of solitary EMP. Depending on lesion resectability, a combined therapy (surgery and radiotherapy) is the treatment of choice.

R E F E R E N C E S

1. *Batsakis JG, Medeiros JL, Luna MA, El-Naggar AK.* Plasma cell dyscrasias and the head and neck. *Ann Diagn Pathol* 2002; 6(2): 129–40.
2. *Schridde H.* Weitere Untersuchungen über die Kornelungen der Plasmazellen. *Centralbl Allg Pathol Pathol Anat* 1905; 16: 433–5.
3. *Alexiou C, Kau RJ, Dietschfelbinger H, Kremer M, Spiess JC, Schratzenstaller B, et al.* Extramedullary plasmacytoma: tumor occurrence and therapeutic concepts. *Cancer* 1999; 85(11): 2305–14.
4. *Wax MK, Yun KJ, Omar RA.* Extramedullary plasmacytomas of the head and neck. *Otolaryngol Head Neck Surg* 1993; 109(5): 877–85.
5. *Kapadia SB, Desai U, Cheng VS.* Extramedullary plasmacytoma of the head and neck. A clinicopathologic study of 20 cases. *Medicine (Baltimore)* 1982; 61(5): 317–29.
6. *Wiltshaw E.* The natural history of extramedullary plasmacytoma and its relation to solitary myeloma of bone and myelomatosis. *Medicine (Baltimore)* 1976; 55(3): 217–38.
7. *Webb HE, Harrison EG, Masson JK, Remine WH.* Solitary extramedullary myeloma (plasmacytoma) of the upper part of the respiratory tract and oropharynx. *Cancer* 1962; 15: 1142–55.
8. *Rodriguez-de-Velasquez A, Weber AL, Montgomery W.* Extramedullary laryngeal plasmacytoma. *Ann Otol Rhinol Laryngol* 1996; 105(6): 483–6.
9. *Fu YS, Perçin KH.* Nonepithelial tumors of the nasal cavity, paranasal sinuses and nasopharynx. A clinicopathologic study. IX. Plasmacytomas. *Cancer* 1978; 42(5): 2399–406.
10. *Meis JM, Butler JJ, Osborne BM, Ordóñez NG.* Solitary plasmacytomas of bone and extramedullary plasmacytomas. A clinicopathologic and immunohistochemical study. *Cancer* 1987; 59(8): 1475–85.
11. *Sulzner SE, Amdur RJ, Weider DJ.* Extramedullary plasmacytoma of the head and neck. *Am J Otolaryngol* 1998; 19(3): 203–8.
12. *Susnerwala SS, Shanks JH, Banerjee SS, Scarffe JH, Farrington WT, Slevin NJ.* Extramedullary plasmacytoma of the head and neck region: clinicopathological correlation in 25 cases. *Br J Cancer* 1997; 75(6): 921–7.
13. *Michalaki VJ, Hall J, Henk JM, Nutting CM, Harrington KJ.* Definitive radiotherapy for extramedullary plasmacytomas of the head and neck. *Br J Radiol* 2003; 76(910): 738–41.
14. *Ching AS, Khoo JB, Chong VF.* CT and MR imaging of solitary extramedullary plasmacytoma of the nasal tract. *AJNR Am J Neuroradiol* 2002; 23(10): 1632–6.
15. *Miller FR, Lavertu P, Wanamaker JR, Bonafede J, Wood BG.* Plasmacytomas of the head and neck. *Otolaryngol Head Neck Surg* 1998; 119(6): 614–8.
16. *Komisar A, Schetman F, DaSilva M, Ioachim H, Blaugrund SM.* The histopathologic diagnosis of head and neck tumors by special stains. *Ear Nose Throat J* 1989; 68(9): 702, 705–6, 709–12.
17. *Lebowitz RA, Morris L.* Plasma cell dyscrasias and amyloidosis. *Otolaryngol Clin North Am* 2003; 36(4): 747–64.
18. *Hidaka H, Ikeda K, Oshima T, Ohtani H, Suzuki H, Takasaka T.* A case of extramedullary plasmacytoma arising from the nasal septum. *J Laryngol Otol* 2000; 114(1): 53–5.
19. *Windfuhr JP, Ott G.* Extramedullary plasmacytoma manifesting as a palpable mass in the nasal cavity. *Ear Nose Throat J* 2002; 81(2): 110–4.
20. *Castro EB, Lewis JS, Strong EW.* Plasmacytomas of Paranasal sinuses and nasal cavity. *Arch Otolaryngol* 1973; 97(4): 326–9.
21. *Kanımürk E.* Solitary plasmacytoma of the nasal passage—a case report. *Rhinology* 1978; 16(2): 99–101.
22. *Navarrete ML, Quesada P, Pellicer M, Ruiz C.* Extramedullary nasal plasmacytoma. *J Laryngol Otol* 1991; 105(1): 41–3.
23. *Knowling MA, Harwood AR, Bergsagel DE.* Comparison of extramedullary plasmacytomas with solitary and multiple plasma cell tumors of bone. *J Clin Oncol* 1983; 1(4): 255–62.
24. *Holland J, Trenker DA, Wasserman TH, Fineberg B.* Plasmacytoma. Treatment results and conversion to myeloma. *Cancer* 1992; 69(6): 1513–7.
25. *Baek JB, Kim WS, Park H, Park KJ, Han YK, Oh C.* Extramedullary plasmacytoma arising from the nasal septum. *Ear Nose Throat J* 2005; 84(11): 720–2.

Received on June 14, 2011.

Revised on October 4, 2011.

Accepted on December 13, 2011.