

# Primary Percutaneous Coronary Intervention in a Patient with Right Internal Mammmary Artery Graft Originating from Arteria Lusoria Dextra

Srdjan Aleksandrić<sup>1,2</sup>, Siniša Stojković<sup>1,2</sup>, Miloje Tomašević<sup>3,4</sup>, Jelena Kostić<sup>1,2</sup>, Marko Banović<sup>1,2</sup>, Nemanja Menković<sup>1,5</sup>, Miodrag Ostojić<sup>1,2</sup>

<sup>1</sup>School of Medicine, University of Belgrade, Belgrade, Serbia;

<sup>2</sup>Clinic of Cardiology, Clinical Center of Serbia, Belgrade, Serbia;

<sup>3</sup>Faculty of Medical Sciences, University of Kragujevac, Kragujevac, Serbia;

<sup>4</sup>Clinic of Cardiology, Clinical Center Kragujevac, Kragujevac, Serbia;

<sup>5</sup>Center of Radiology and Magnetic Resonance Imaging, Clinical Center of Serbia, Belgrade, Serbia

## SUMMARY

**Introduction** Congenital anomalies of the aortic arch, although numerous and heterogeneous, occur in less than 1% of individuals at autopsies. Left aortic arch with an aberrant right subclavian artery, also called arteria lusoria dextra, is the most common anomaly of the aortic arch, occurring in 0.5–2.5% of individuals.

**Case Outline** We report the case of a 48-year-old man suffering from acute inferoposterior-wall ST elevation myocardial infarction successfully treated by primary percutaneous coronary intervention. Ten years ago, the patient had undergone coronary artery bypass graft surgery with the implantation of two arterial grafts - left and right internal mammary arteries on both left anterior descending and right coronary artery. After several attempts to cannulate truncus brachiocephalicus, angiogram revealed the left aortic arch with the aberrant right subclavian artery. To our knowledge, this is the first described case of primary percutaneous coronary intervention via the aberrant right subclavian artery and right internal mammary artery graft with stent implantation in the infarct related lesion of the distal segment of right coronary artery. Subsequent 64-multidetector computed tomography confirmed the angiographic findings.

**Conclusion** Early recognition of congenital anomalies of the aortic arch and its great vessels, even before coronary artery bypass graft surgery, could be crucial for the urgent and successful treatment of patients with life-threatening conditions, such as ST segment elevation myocardial infarction.

**Keywords:** arteria lusoria dextra; aberrant right subclavian artery; ST elevation myocardial infarction; percutaneous coronary intervention; congenital aortic arch anomalies; radial approach

## INTRODUCTION

Congenital anomalies of the aortic arch, although numerous and heterogeneous, occur in less than 1% of individuals at autopsies [1, 2]. Left aortic arch with an aberrant right subclavian artery (ARSA) is the most common anomaly of the aortic arch, occurring in 0.5–2.5% of individuals [1, 2]. Distinctive features of this anomaly is the absence of truncus brachiocephalicus with contemporary four vessels arising sequentially from the left aortic arch: the right common carotid artery (CCA) originating separately as the first branch of the aortic arch; the left CCA originating as the second branch; the left subclavian artery originating as the third branch; and the ARSA originating as the fourth (last) branch either from the left aortic arch or from the proximal descending aorta. ARSA usually crosses upwards and to the right behind the esophagus (80%), but also may run between the esophagus and the trachea, or in front of the trachea [2]. ARSA is usually asymptomatic in adults and without pathological significance, unless large aneurysmal dilatation of Kommerell's diverticulum (aneurysm at the origin of ARSA) compresses esophagus

or/and trachea producing dysphagia lusoria (dysphagia to solids and not to liquids) and/or dyspnea and chronic cough [2, 3].

Unawareness of congenital anomalies of the aortic arch such as the left aortic arch with ARSA may significantly prolong time to reperfusion during primary percutaneous coronary intervention (PPCI) and, thus, total ischemic time in patients with ST elevation myocardial infarction (STEMI). This is of particular importance in the framework of increasing utilization of radial approach not only in diagnostic and elective procedures [4, 5], but in PPCI as well [6, 7]. Besides, these patients may receive a large amount of radiographic contrast agent before recognizing the anomaly of the aortic arch that could cause contrast-induced nephropathy (CIN) after PPCI [8]. In addition, this anomaly may lead to increased fluoroscopy time and the usage of multiple consumables.

To our belief, the early recognition of congenital anomalies of aortic arch and its great vessels, even before coronary artery bypass graft (CABG) surgery, might be crucial for the urgent and successful treatment of patients with life-threatening conditions, such as STEMI.

## Correspondence to:

Siniša STOJKOVIĆ  
Clinic of Cardiology  
Clinical Center of Serbia  
Višegradska 26, 11000 Belgrade  
Serbia  
sstojkovi@open.telekom.rs

## CASE REPORT

We report a case of a 48-year-old man admitted to our cardiac center due to sudden onset of chest pain two hours prior to admission with electrocardiogram signs of acute inferoposterior-wall STEMI. His cardiovascular risk factors were hypertension, dyslipidemia, obesity, smoking and family history of coronary artery disease (CAD). Previously he had inferoposterior and anterior STEMI in 1999 and 2000. In the following year, the patient had undergone CABG surgery with implantation of two arterial grafts - left and right internal mammary artery (IMA) on both left anterior descending (LAD) and right coronary artery (RCA). He has been taking an aspirin (100 mg per os daily) for approximately 11 years, while earlier echocardiography showed severe left ventricular (LV) dysfunction (ejection fraction <40%).

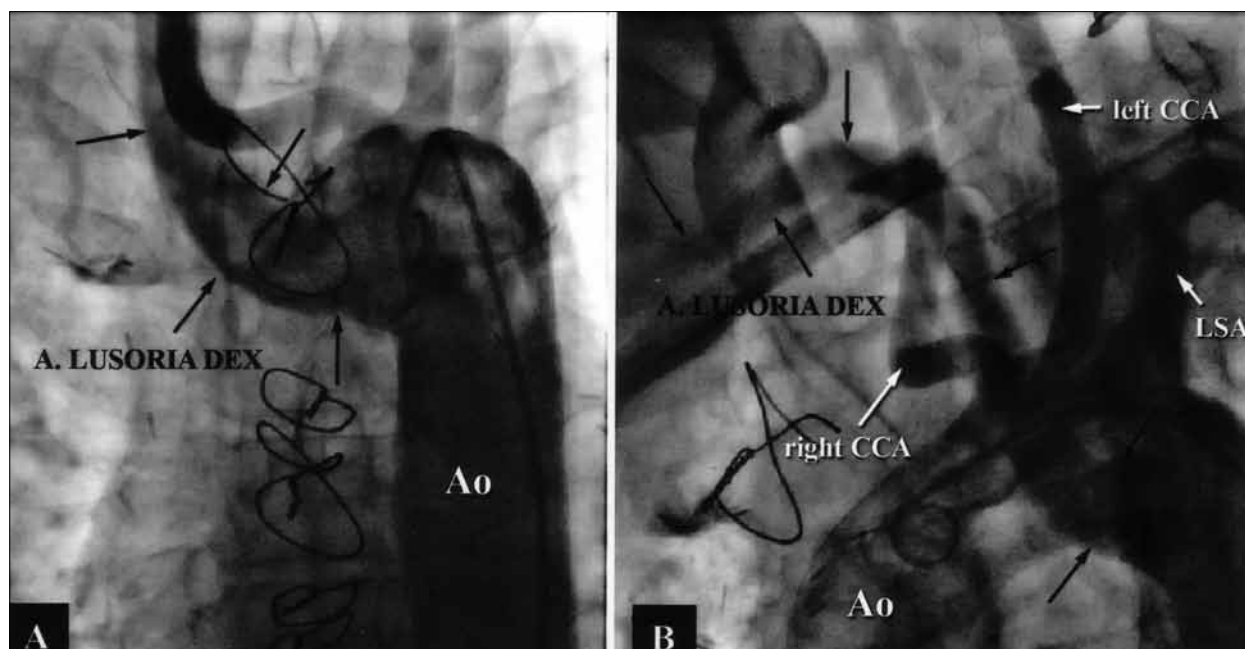
The patient was loaded with 600 mg of clopidogrel and then underwent emergency coronary angiography, with intended primary angioplasty. The obtained angiogram revealed significant stenosis of the distal left main (LM) extending into the ostium of left circumflex artery (LCx) and occlusion of both medial segments of LAD and RCA, without significant lesions of the left IMA graft or distal LAD.

Diagnostic catheter 6-Fr Judkins Right (JR4, Cordis, Johnson & Johnson, New Brunswick, NJ, USA) applied by femoral approach, after several attempts, could not be advanced into the right subclavian artery. We performed aortography of the aortic arch in two projections (posterior-anterior and left anterior oblique 45°) with a 6-Fr pigtail-shaped catheter (Cordis, Johnson & Johnson, New Brunswick, NJ, USA) placed in the upper part of the

ascending aorta using 50 ml of low osmolar non-ionic iodinated radiographic contrast media - iopromide 370 mg/mL (Bayer Schering Pharma AG, Berlin, Germany). The performed aortic arch aortography revealed the left aortic arch with ARSA (Figures 1A and 1B).

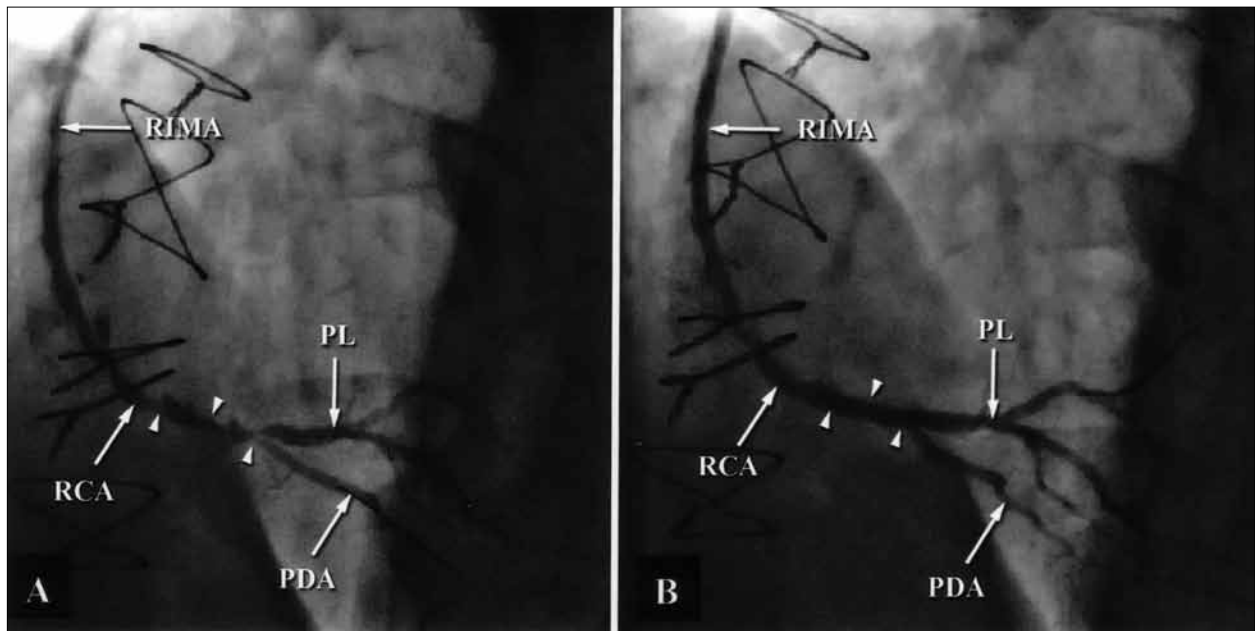
Diagnostic catheter 6-Fr JR4 (Cordis, Johnson & Johnson, New Brunswick, NJ, USA) was introduced into ARSA by femoral approach and then exchanged for 6-Fr internal mammary (IM) guiding catheter (Cordis, Johnson & Johnson, New Brunswick, NJ, USA) over an exchange 0.035-inch J-tipped guidewire (Terumo Inc, Tokyo, Japan). The IM guiding catheter was preferred for cannulation of the right IMA because of the sharp angle between ARSA and right IMA. The angiogram revealed subocclusive lesion in the distal segment of RCA extending into both posterolateral (PL) and posterior descending artery (PDA) with thrombolysis in myocardial infarction (TIMI) grade 2 flow (Figure 2A). After pretreatment with 10,000 IU (100 IU/kg) of unfractionated heparin bolus, two Runthrough NS floppy (Terumo Inc, Tokyo, Japan) guidewires were inserted in the distal segment of both PL and PDA. Direct stenting with the TAXUS Liberté stent 3.0×28 mm (Boston Scientific Corp., Natick, MA, USA) was performed from the distal anastomosis of right IMA into PL with inflation pressure at 14 atm, jailing the side branch wire. The result was optimal, with no residual stenosis of infarct related artery (IRA) and TIMI 3 grade flow. Residual stenosis of the PDA ostium was less than 50% with TIMI 3 grade flow, which did not require kissing balloon dilatation (Figure 2B).

A few days later, 64-multidetector computed tomography (MDCT) showed normal position of the heart but confirmed existence of the left aortic arch with retroesophageal coursed ARSA (Figures 3A and 3B).



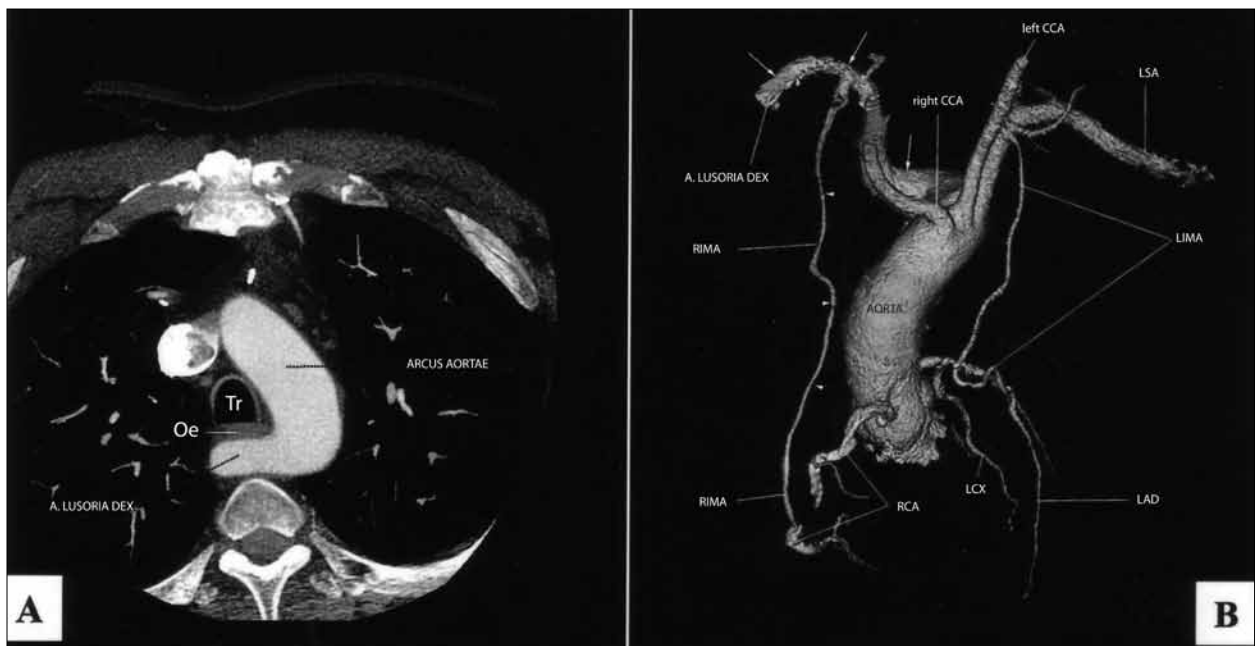**Figure 1.** PA and LAO 45° aortography of the aortic arch (panels A and B). Angiographic views showing left aortic arch with arteria lusoria dextra (black arrows).

A. lusoria dex. – aberrant right subclavian artery; CCA – common carotid artery; LSA – left subclavian artery; Ao – aorta



**Figure 2.** Angiogram of RIMA and RCA (panel A) showing “culprit” lesion in the distal segment of RCA (arrowshead). Angiogram after the stent implantation (panel B) showing optimal result, with no residual stenosis of “culprit” lesion (arrowshead) and residual stenosis of the PDA ostium less than 50%.

RIMA – right internal mammary artery; RCA – right coronary artery; PDA – posterior descending artery; PL – posterolateral artery



**Figure 3.** CT axial view (panel A) showing arteria lusoria dextra originating from the right wall of the posterior part of left aortic arch and runs to the right and behind the esophagus and trachea. 64-MDCT angiography, anterior-superior view (panel B) precisely showing arteria lusoria dextra (white arrows) arising from the right wall of the left aortic arch, just below the ostium of the left subclavian artery, runs upwards and to the right. It also shows RIMA (arrow head) which originates from the inferior wall of the arteria lusoria dextra and runs downward to the distal segment of RCA.

Tr – trachea; Oe – esophagus; LIMA – left internal mammary artery; LAD – left anterior descending artery; LCx – left circumflex coronary artery

## DISCUSSION

According to our knowledge, besides the scarce reports of elective PCI via ARSA [4, 5], this is the first case describing PPCI via ARSA and right IMA graft. Unrecognized left aortic arch with ARSA (which was not systematically analyzed before the CABG operation) at the first sight, signifi-

cantly prolonged time to reperfusion (>1 hour in this case) and, thus, total ischemic time in this high-risk patient. De Luca et al. [9] in a cohort of 1791 patients with STEMI treated by PPCI found that every minute of delay from symptom-onset-to-balloon time (total ischemic time) does affect 1-year mortality, especially in non-low-risk patients. In an earlier study, De Luca et al. [10] identified

a total ischemic time >4 hours as the independent predictor of 1-year mortality. After that period the risk of 1-year mortality is increased by 7.5% for each additional 30-minute delay [9]. According to Zijlstra et al. [11], patients treated with PPCI within 2 hours from the symptom onset not only have lower 30-day mortality, but also have a reduced myocardial infarct size and consequently a better-preserved left ventricular function.

The presence of ARSA may influence the choice of appropriate vascular access during diagnostics or interventional procedures. The aberrant course of the subclavian artery makes selective coronary cannulation by radial approach difficult and sometimes impossible [5]. The angiographic success rate of 60% by radial approach in this condition was recently reported [12], requiring cross-over to femoral approach. Although successful elective PCI procedures by radial approach in patients with ARSA have been recently reported [5, 12], this procedure demands patience, perseverance and technical skills, making it inappropriate for PPCI.

Moreover, our patient received a large amount of low osmolar non-ionic iodinated radiographic contrast agent ( $\approx 500$  ml, iopromide 370 mg/mL) before we recognized the left aortic arch with ARSA and implanted the stent in the IRA. Marenzi et al. [8] in a study population of 208 patients with STEMI treated by PPCI found that contrast agent volume >300 ml is one of the independent predictors for contrast-induced nephropathy (CIN) development after PPCI. This study showed that patients with STEMI undergoing PPCI are at higher risk for CIN, even with normal baseline renal function. CIN is associated with a higher in-hospital complication rate and mortality, prolonged hospitalization and poor long-term survival [8]. To prevent CIN, our patient received physiologic (0.9%) saline intravenously during PPCI at a rate of 0.5 ml/kg/h due to LV dysfunction and continued for 12 hours after the procedure. Fortunately, an increase in serum creatinine concentration was less than 25% and less than 0.5 mg/dl within 72 hours, compared to the baseline value.

In addition to anatomical situation presented, there are various congenital anomalies of the aortic arch reported in the literature [1, 2, 13-16]. ARSA has also been associated with an anomalous origin of the left CCA sharing a common trunk with the right CCA, also known as truncus bicaroticus or "bovine arch" [2, 13]. Another variation, the anomaly of the right aortic arch is extremely rare variation with normal left-side heart (situs solitus), but it always presents with right-side heart (situs inversus) [1, 2, 14, 15, 16]. In such cases, the descending aorta may be either on

the right or on the left side. In one form, the right aortic arch maintains a position to the right of the esophagus and descends on the right side of the spine. In the more common form, the right aortic arch passes to the left behind the esophagus and then usually descends on the left. This variation is named the circumflex retroesophageal right aortic arch [1, 14, 15]. The right aortic arch has also been associated with Tetralogia Fallot; this anomaly is named Syndrome Corvisart-Fallot [1, 15, 16].

In the right aortic arch anomaly the first branch arising from the aortic arch is the truncus brachiocephalicus which divides into the left subclavian artery and the left CCA; the second branch is the right CCA; and the third branch is the right subclavian artery. The right aortic arch with an aberrant left subclavian artery (ALSA) is the most common variation of the right aortic arch anomaly, occurring in about 0.05% of the population [1, 2, 14, 15, 16]. ALSA arises as fourth (last) branch of the right aortic arch or from the proximal descending aorta, distal to the origin of the right subclavian artery. ALSA is also called arteria lusoria sinistra and appears as a "mirror image" of the arteria lusoria dextra [1, 2, 14, 15, 16].

In double aortic arch anomaly, two aortic arches form a complete vascular ring that can compress the trachea and/or esophagus and then join to form the descending aorta [1].

We propose that the interventionalist should always have in mind congenital anomalies not only of the coronary arteries, but of the aortic arch as well. Usually, there are no routine angiographic or MDCT examinations of the aortic arch and its great vessels in patients planned for CABG surgery. In these patients, we believe that angiographic examination of the aortic arch and its great vessels during diagnostic coronarography is effective and reliable approach for recognizing its numerous congenital anomalies. It would significantly shorten the duration of eventual consecutive elective or urgent procedures and, more important, total ischemic time in patients with STEMI treated by the PPCI. Additionally, it would reduce the volume of used radiographic contrast agent and, thus, decrease the incidence of CIN, especially in high-risk patients such as ours. Awareness of this condition may influence the decision of appropriate arterial approach, as well. Finally, the reduction of radiation exposure time and consumable hardware is not negligible.

To our belief, the early recognition of congenital anomalies of aortic arch and its great vessels, even before CABG surgery, might be crucial for the urgent and successful treatment of patients with life-threatening conditions, such as STEMI.

## REFERENCES

- Edwards JE. Congenital malformations of the heart and great vessels. Section H. Malformations of the thoracic aorta. In: Gould SE, editor. 2nd ed. Pathology of the Heart. Springfield (IL): Charles Thomas; 1960. p.391-462.
- Myers PO, Fasel JHD, Kalangos A, Gailloud P. Arteria lusoria: Developmental anatomy, clinical, radiological and surgical aspects. *Annales de Cardiologie et d'Angéiologie*. 2010; 59:147-54.
- Kent PD, Poterucha TH. Aberrant right subclavian artery and dysphagia lusoria. *N Engl J Med*. 2002; 346:1637.
- Gunasekaran S, Kallarakkal JT, Ghanikachalam S. Percutaneous transluminal coronary angioplasty by right transradial approach in a patient with arteria lusoria. *Indian Heart J*. 2006; 58:365-7.
- Pillai MG, Hansra SS. Percutaneous intervention of right coronary artery through right radial approach in a patient with arteria lusoria. *J Mgims*. 2008; 13(II):53-5.
- Amoroso G, Kiemeneij F. Transradial access for primary percutaneous coronary intervention: the next standard of care? *Heart*. 2010; 96(17):1341-4.
- Arzamendi D, Ly HQ, Tanguay JF, Chan MY, Chevallereau P, Gallo R, et al. Effect on bleeding, time to revascularization, and one-year clinical outcomes of the radial approach during primary percutaneous coronary intervention in patients with ST-segment elevation myocardial infarction. *Am J Cardiol*. 2010; 106(2):148-54.
- Marenzi G, Lauri G, Assanelli E, Campodonico J, De Metrio M, Marana I, et al. Contrast-induced nephropathy in patients undergoing primary angioplasty for acute myocardial infarction. *J Am Coll Cardiol*. 2004; 44(9):1780-5.
- De Luca G, Suryapranata H, Ottervanger JP, Antman EM. Time delay to treatment and mortality in primary angioplasty for acute myocardial infarction: every minute of delay counts. *Circulation*. 2004; 109:1223-5.
- De Luca G, Suryapranata H, Zijlstra F, Van't Hof AVJ, Hoorntje JCA, Gosselink ATM, et al. Symptom-onset-to-balloon time and mortality in patients with acute myocardial infarction treated by primary angioplasty. *J Am Coll Cardiol*. 2003; 42(6):991-7.
- Zijlstra F, Patel A, Jones M, Grines CL, Ellis S, Garcia E, et al. Clinical characteristics and outcome of patients with early (<2 h), intermediate (2–4 h) and late (>4 h) presentation treated by primary coronary angioplasty or thrombolytic therapy for acute myocardial infarction. *Eur Heart J*. 2002; 23:550-7.
- Valsecchi O, Vassileva A, Musumeci G, Rossini R, Tespili M, Guagliumi L, et al. Failure of transradial approach during coronary interventions: anatomic considerations. *Catheter Cardiovasc Interv*. 2006; 67:870-8.
- Chahwan S, Miller MT, Kim KA, Mantell M, Kirksey L. Aberrant right subclavian artery associated with a common origin of carotid arteries. *Ann Vasc Surg*. 2006; 20:809-12.
- Shuford WH, Sybers RG, Gordon IJ, Baron MG, Carson GC. Circumflex retroesophageal right aortic arch simulating mediastinal tumor or dissecting aneurysm. *AJR*. 1986; 146:491-6.
- Blieden LC, Schneeweiss A, Deutsch V, Neufeld HN. Right aortic arch with left descending aorta (circumflex aorta). *Pediatr Radiol*. 1978; 6:208-10.
- Craatz S, Künzel E, Spanel-Borowski K. Right-sided aortic arch and tetralogy of Fallot in humans – a morphological study of 10 cases. *Cardiovasc Pathol*. 2003; 12:226-32.

## Примарна перкутана коронарна интервенција код болесника са графтом десне унутрашње грудне артерије која полази од аберантне десне поткључне артерије

Срђан Александрић<sup>1,2</sup>, Сениша Стојковић<sup>1,2</sup>, Милоје Томашевић<sup>3,4</sup>, Јелена Костић<sup>1,2</sup>, Марко Бановић<sup>1,2</sup>, Немања Менковић<sup>1,5</sup>, Миодраг Остојић<sup>1,2</sup>

<sup>1</sup>Медицински факултет, Универзитет у Београду, Београд, Србија;

<sup>2</sup>Клиника за кардиологију, Клинички центар Србије, Београд, Србија;

<sup>3</sup>Медицински факултет, Универзитет у Крагујевцу, Крагујевац, Србија;

<sup>4</sup>Клиника за кардиологију, Клинички центар Крагујевац, Крагујевац, Србија;

<sup>5</sup>Центар за радиологију и магнетну резонанцу, Клинички центар Србије, Београд, Србија

### КРАТАК САДРЖАЈ

**Увод** Конгениталне аномалије лука аорте, иако бројне и разноврсне, јављају се у мање од 1% случајева на обдукцијама. Најчешћа урођена аномалија лука аорте је левострани лук аорте с аберантном десном поткључном артеријом (*arteria lusoria dextra*), која се бележи код 0,5–2,5% болесника.

**Приказ болесника** Приказујемо 48-годишњег мушкарца који је два сата пре пријема у болницу добио акутни инфаркт миокарда с елевацијом ST сегмента инферопостериорне локализације, а затим успешно лечен примарном перкутаном коронарном интервенцијом. Болесник је десет година раније имао аорткоронарну бајпас-операцију када су му уграђена два артеријска графта – лева унутрашња грудна артерија на предњу десцендентну коронарну артерију и десна унутрашња грудна артерија на десну коронарну артерију. Након неколико неуспелих покушаја да се канулира брахиоцефалични трункус, урађена је аортографија лука аорте у два положаја (задње-предњи и предње леви коси под углом од 45°) на којој је откривен леви аортни

лук с аберантном десном поткључном артеријом, која, као четврта и последња бочна грана лука аорте, полази од његовог завршног дела. Према нашим сазнањима, ово је први приказ примарне перкутане коронарне интервенције преко аберантне десне поткључне артерије и десне унутрашње грудне артерије као артеријског графта, с уградњом стента на лезији одговорној за настанак инфаркта миокарда у дисталном сегменту десне коронарне артерије. Контролна 64-слајсна компјутеризована томографија је потврдила претходни ангиографски налаз.

**Закључак** Познавање и рано откривање урођених аномалија лука аорте и његових бочних грана, чак и пре аорткоронарне бајпас-операције, може бити од пресудног значаја за брзо и успешно лечење животну угрожене болесника с акутним инфарктом миокарда с елевацијом ST сегмента.

**Кључне речи:** *arteria lusoria dextra*; аберантна десна поткључна артерија; инфаркт миокарда с елевацијом ST сегмента; перкутана коронарна интервенција; конгениталне аномалије лука аорте