

EPIDEMIOLOGICAL RISK OF TOXOCAROSIS IN HUMAND AND ANIMALS IN IAȘI COUNTY

Larisa IVĂNESCU⁹, Simona MĂTIUȚ², Gabriela MARTINESCU¹, Liviu MIRON¹

e-mail (first author): livanescu@uaiasi.ro

Abstract

The increasing number of dogs is a determining factor in the occurrence of toxocarosis in humans, as they are the source of environmental contamination with *Toxocara sp.* eggs. During a single year, 2018-2019, the number of stray dogs increased from 0.068 to 0.0709 per capita. Contamination of dogs with *Toxocara canis* in the conditions of our country has increased in recent years from 21.4% to 50.2% and is identified as the most common parasitosis in these animals. For the study of *Toxocara spp.* infection in dogs, the period 2017-2020 was considered, representing cases present at the Faculty of Veterinary Medicine, Iasi. Thus, more than 75% of infections are recorded in young dogs under one year old, while 89% of them are males. The study on the prevalence of *Toxocara canis* cases at the Animal shelters in Tomești showed a prevalence of *Toxocara sp.* of 60% of the total samples analysed; the study on toxocarosis in humans was carried out during 2020, the information being provided by the Praxis medical tests laboratory. Result on the presence of specific IgG antibodies to *Toxocara canis/cati*. It included a group of 95 cases during one year, of which 3, namely 3.25% were under 3 years old and 14.8% were over 35 years old. Of the total samples, only 2 were positive in the male gender, which represents 2.1% of the total samples. Fifteen cases were positive in females, representing 15.8% of all samples analysed. Considering that we are talking about a parasite specific to dogs, the presence of such a large number of cases during a single year reveals a very high load of *Toxocara* eggs in the environment, which raises an alarm about the distribution of this parasite in nature and the high risk of human contamination.

Keys words: toxocarosis in humans, environmental contamination

Toxocara canis, Werner (1782), is an ascarid that parasitizes domestic dogs (*Canis familiaris*), its morphology being similar to that of the nematode *Ascaris lumbricoides* (parasite of man), adult males are 4-10 cm long and females are 6.5-18 cm long.

The disease caused by this parasite is called toxocariasis, and mainly affects dogs, but can also affect other animals. In humans, the parasite can also cause this disease, which, if not treated in time, can trigger very serious consequences.

Toxocariasis is a zoonotic disease of great importance in terms of the morbidity it can cause in humans and animals, but also in terms of the danger it poses to their health. Recent findings on its association with other pathologies, advances in diagnostic techniques and new therapeutic discoveries raise the concern to review a current topic that may be considered forgotten and neglected due to the lack of national and European studies. *Toxocara canis* can affect humans, causing the so-called *larva migrans visceralis* and *larva migrans ocularis* syndromes. Human illness is due to egg ingestion, with children being more susceptible due to poor hygiene.

Spaces shared by dogs and children, such as parks, can become sources of contamination; in this respect, it is essential that dog faeces are always collected.

The life cycle of the *Toxocara canis* parasite in humans is different from that in dogs, as the larvae cannot reach the adult stage. Furthermore, they pass through the intestinal wall and migrate to the liver, lungs and skin. In massive infestations, symptoms such as abdominal pain, coughing, itching or rashes occur and the larvae can spread to the heart, kidneys, spleen, brain or eyes.

Prevention in humans involves proper deworming of dogs and cats and educating children about basic hygiene. The main source of transmission is puppies shedding large amounts of eggs (Despommier, 2003; Manson et al., 2003). Infection is acquired mainly by children when playing on contaminated soil or in parks, similar to what happens in *A. lumbricoides* infection, and also occurs in association with the phenomenon of soil ingestion.

Direct infection by handling animals is not considered a major risk as *T. canis* eggs excreted into the environment require at least two weeks to become infested by the host (Manson et al., 2003;

⁹ Department of Clinics, Faculty of Veterinary Medicine, Iasi University of Life Sciences (IULS), 3 M. Sadoveanu, 700490 Iasi, Romania
²Praxis Medical Laboratory, Bulevardul Independenței nr. 33, Iași 700102

Overgaauw, 1997). In addition to dogs and cats, other animals, especially peridomestic animals such as squirrels, rabbits and other small and medium-sized mammals, can play an important role in the dispersal of embryonated eggs (Despommier, 2003; Dubinsky et al., 1995). Birds that feed primarily on the ground (such as pigeons or sparrows) may be paratenic hosts, but may also carry eggs from place to place on their feet or wings and may be responsible for laying eggs in distant locations (Hoffmeister et al., 2007; Morimatsu et al., 2006; Taira et al., 2003). Another mechanism of egg dispersal is the consumption of contaminated water (and food, especially vegetables), which has been demonstrated in some studies (Despommier, 2003; Doligalska & Donskow, 2003; Schwartzbrod & Banas, 2003; Vazquez Tsuji et al., 1997).

Larva migrans visceralis syndrome

In intense infections, especially in children (under 5 years of age), juvenile larvae, measuring on average 450 µm x 16-20 µm in diameter, occur mainly in the liver, where they may cause fewer or more miliary lesions, and foci of necrosis may even occur (Despommier, 2003; Manson et al., 2003).

The clinical picture accompanying this pathology includes fever and lower respiratory tract symptoms (especially bronchospasm, reminiscent of asthma) with eosinophilia (which may even reach figures close to 70% or greater than 10,000 cells/mm³) and hyperglobulinaemia (IgM, IgG and IgE) (Pinelli et al., 2007).

Macroscopically in the liver, lesions consisting of granulomas that can be described as white subcapsular nodules the size of millet seeds are observed, but an increase in liver volume can also be observed.

Depending on the organ parasitized, it can cause myocarditis, nephritis, central nervous system

damage, convulsions, neuropsychiatric symptoms and encephalopathy (Despommier, 2003). Experimental neuropathogenicity studies conducted more than 30 years ago identified that *T. canis* larvae move actively in the brain, penetrating directly through tissues as well as moving back and forth in the brain through the meninges and ventricular space (Innes & Saunders, 1962), being observed in some cases due to granuloma formation and producing both the pathologies described and manifested clinically and neurologically by their passage as well as by the latter.

The clinical manifestations of occult toxocariasis are variable and may present as a picture of pulmonary disease (asthma, bronchitis, pneumonitis), dermatological disorders (chronic urticaria or eczema), lymphadenopathy, myositis and pseudo-rheumatic syndromes such as arthralgia (2001).

Ocular larval migrans syndrome or ocular toxoplasmosis

In the eye, juvenile larval migrans can damage the retina by forming large subretinal masses and inducing granulomatous reactions, which can lead to decreased vision (Despommier, 2003; Manson et al., 2003). The ocular syndrome usually occurs in children aged 5 to 10 years and usually determines unilateral vision impairment, sometimes accompanied by strabismus (Molk, 1983; Taylor, 2001). In 2004, a premature infant was reported from a hospital neonatal intensive care unit, referred for treatment of retinopathy of prematurity, in whom a larval image in the retina of the left eye was found. These findings could be supported by previous studies postulating potential congenital transmission of intestinal nematodes (da Costa-Macedo and Rey, 1990).

MATERIAL AND METHOD

The study aimed to determine the prevalence of toxocariasis in humans and animals in Iasi County.

This study was prompted by the detection in the latest period in humans by practitioners, clinicians, specialists in various medical branches of an increasing number of patients with various clinical manifestations, in whom the presence of antibodies specific to the parasite *Toxocara canis* was detected by serological tests and a series of specific investigations.

At the same time, another category of people with subclinical or even absent signs of the disease has appeared, who, after a series of tests, approach the doctor with positive anti-*Toxocara* serological tests. As a rule, the vast majority of these people did not have a medical response to the

interpretation of the positive results and consulted several specialists several times.

There is a gap among clinicians with regard to the recognition of clinical manifestations but also with regard to the management of toxocariasis, as well as among the population with regard to prevention and control measures for this disease.

The research was carried out in two locations: Ion Ionescu de la Brad University of Life Sciences in Iasi, MV Parasitology Clinic, Animal Shelters Tomeşti and Praxis Human Medical Tests Laboratory.

In the last period, molecular biology and bioinformatics have developed more and more, but one thing has remained constant, namely the examination for the diagnosis of endoparasites,

which is based on the coproparasitological examination, namely the analysis of faecal samples to determine the presence of parasites or parasitic elements; this is the best known procedure to correctly and concretely diagnose an endoparasitosis.

For the diagnosis of toxocarasis in animals, the *Willis flotation method* has been used which is based on the principles of differentiating between the specific weight of parasite eggs and faecal

remaining. Salt or sugar at 30% concentration is used as flotation solution.

During 2020 at the Faculty of Veterinary Medicine 180 faecal samples were analysed, of which only 45 samples were positive for the presence of the parasite *Toxocara canis*. Of the positive cases 75% were identified in dogs aged between 2 months and 1 year, the remaining cases were identified in dogs over 14 years of age.

RESULTS AND DISCUSSIONS

Results of study at the Faculty of Veterinary Medicine

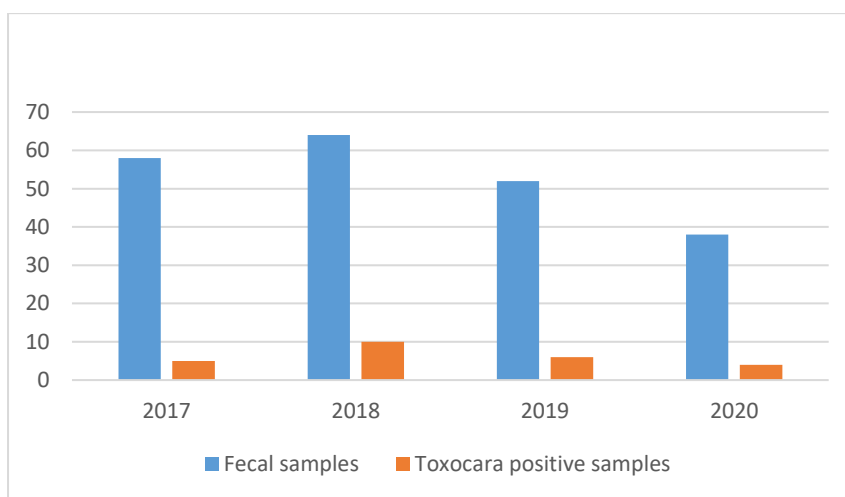


Figure 1 Positive results by Toxocara sp.

During the years 2017-2020 at the Faculty of Veterinary Medicine, 212 faecal samples were analysed, of which only 25 samples were positive

for the presence of the parasite *Toxocara canis* (figure 1).

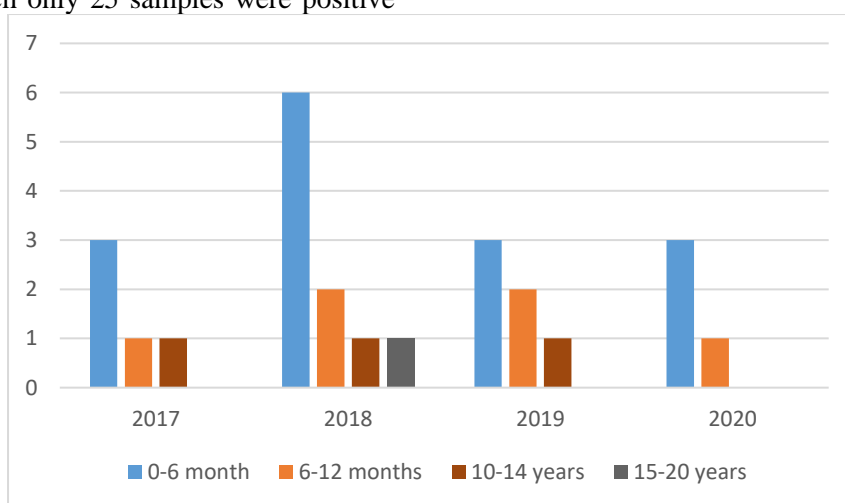


Figure 2 Distribution of Toxocara sp. by age groups

Of the positive cases 84% were identified in dogs aged between 2 months and 1 year, the remaining

cases were identified in dogs over 14 years of age (figure 2).
Results of study at the Animal Shelters Tomesti

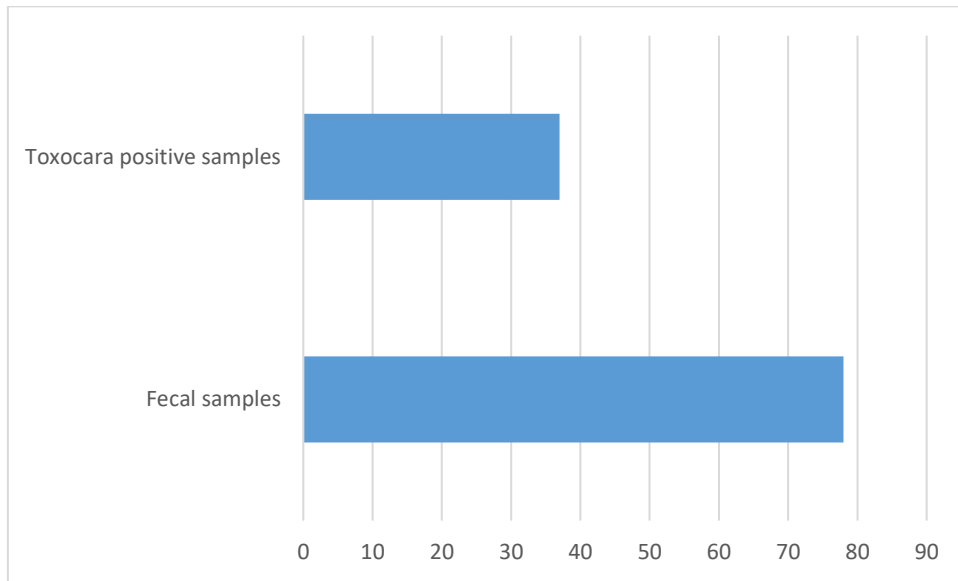


Figure 3 Positive results by toxocarosis at the Animal sheltet Tomesti

During 2020 from the Animal Shelters Tomesti, 78 faecal samples were analysed, of which 37 samples were positive for the presence of the parasite *Toxocara canis*. The faecal samples were collected without knowing the age of the animals (figure 3).

Table 1. Ig A antibody testing in the Praxis laboratory

Service Name/Category/Age Total Total negatives Total positives Positives Sex M Positives Sex F Total Sex M Total Sex F

Serviciu	DenumireCateg/Varsta	Total	Total negative	Total positive	Positive Sex M	Positive Sex F	Total Sex M	Total Sex F
Toxocara canis/bati - Anticorpi IgA	0-12 luni	0	0	0	0	0	0	0
	1 an	0	0	0	0	0	0	0
	2 ani	1	1	0	0	0	0	1
	3 ani	3	3	0	0	0	0	3
	4 ani	1	1	0	0	0	1	0
	5-9 ani	5	5	0	0	0	2	3
	10-14 ani	4	4	0	0	0	1	3
	15-19 ani	2	2	0	0	0	1	1
	20-24 ani	0	0	0	0	0	0	0
	25-34 ani	1	1	0	0	0	0	1
	35-44 ani	0	0	0	0	0	0	0
	45-54 ani	7	6	1	0	1	1	6
	55-64 ani	4	4	0	0	0	2	2
	65-74 ani	3	3	0	0	0	0	3
	75-84 ani	2	1	1	0	1	0	2
	85+ ani	0	0	0	0	0	0	0
		33	31	2	0	2	8	25

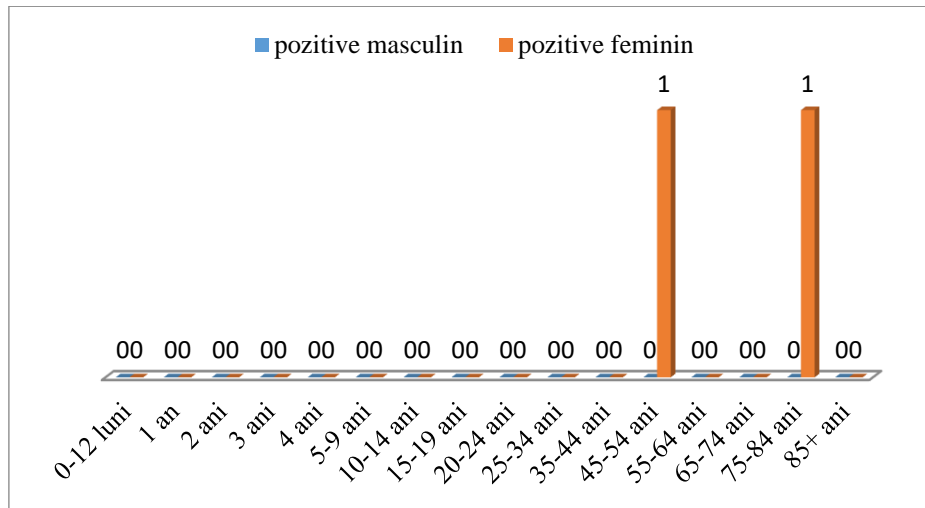


Figure 4 IgA antibodies -Toxocara canis(Positive males and Positive females)

Determination of *Toxocara canis* infection by IgA antibody study in the Praxis laboratory

Out of a total of 33 cases analysed, only 2 cases were positive, both in females, aged 45-54 years and 75-84 years respectively, representing 6.06% of the total cases studied. *Larva migrans* syndrome in humans is correlated with immunosuppression, the body being unable to stop the migration of larvae through the body, and thus the appearance of symptoms specific to the affected organ. Thus, in adults this disease is associated with chronic, immunosuppressive diseases such as AIDS or

various forms of cancer, which means that the detection of the presence of *Toxocara* larvae must be accompanied by other tests to discover the main cause of the disease (figure 4)

Table 2. IgG antibody detection samples at the Praxis unit

Service Name/Category/Age Total Total Positives Sex Positives Sex Total Sex F IgG antibodies

Serviciu	DenumireCatedVar	Total	Total	Total	Pozitive Sex	Pozitive Sex	Total Sex	Total Sex F
Toxocara canis/cati - Anticorpi IgG	0-12 luni	3	3	0	0	0	3	0
	1 an	1	1	0	0	0	1	0
	2 ani	2	1	1	0	1	1	1
	3 ani	4	2	2	0	2	0	4
	4 ani	1	1	0	0	0	1	0
	5-9 ani	8	8	0	0	0	5	3
	10-14 ani	13	13	0	0	0	6	7
	15-19 ani	4	4	0	0	0	0	4
	20-24 ani	4	4	0	0	0	1	3
	25-34 ani	6	6	0	0	0	1	5
	35-44 ani	10	9	1	0	1	2	8
	45-54 ani	18	14	4	2	2	5	13
	55-64 ani	11	9	2	0	2	5	6
	65-74 ani	6	2	4	0	4	1	5
	75-84 ani	4	1	3	0	3	0	4
	85+ ani	0	0	0	0	0	0	0
			95	78	17	2	15	32

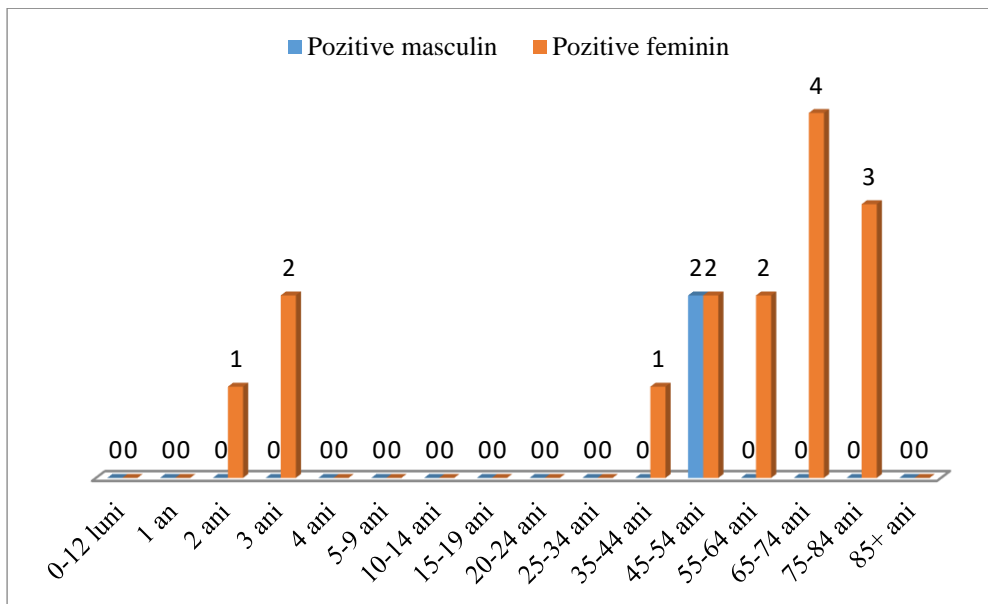


Figure 5 IgG antibodies-*Toxocara canis*(Positive males and Positive females)

Determination of *Toxocara canis*/cati infection by IgG antibody study in the Praxis laboratory

The above graph shows cases of *Toxocara canis* infestation detected by the presence of IgG antibodies to *Toxocara canis*. During a single year a total of 95 cases have been analysed, of which 3, namely 3.25% are under 3 years of age and 14.8% are over 35 years of age. Of the total samples, only 2 were positive in males, which represents 2.1% of the total samples. Fifteen cases were positive in females, representing 15.8% of all samples

analysed. Considering that we are talking about a parasite specific to dogs, the presence of such a large number of cases during a single year reveals a very high load of *Toxocara* eggs in the environment, which raises an alarm about the distribution of this parasite in nature and of the high risk of human contamination (fig.5).

CONCLUSIONS

1. The increasing number of puppies is a determining factor in the occurrence of Toxocariasis in humans, as they are the source of environmental contamination with *Toxocara* eggs. In a single year, namely 2018-2019, the number of stray dogs increased from 0.068 to 0.0709 per capita.
2. The number of dogs per 100,000 inhabitants in Iasi is 1.62 times higher than in Bucharest and 3.5 times higher than in Chisinau.
3. The contamination of dogs with *Toxocara canis* in our country has increased in recent years from 21.4% to 50.2% and is identified as the most frequent parasitosis in these animals.
4. For the study of infection with *Tococara spp.* in dogs, the year 2020 was considered, representing cases present at the Faculty of Veterinary Medicine in Iasi. Thus, more than 75% of the infections occur in young dogs under one year of age and 89% of them are males.

5. The study on the presence of specific IgG antibodies to *Toxocara canis* in humans was carried out during 2020, information provided by Praxis tests laboratory. It included a batch of 95 cases during one year, of which 3, namely 3.25% are under 3 years of age and 14.8% are over 35 years of age. Of the total samples, only 2 were positive in the male gender, which represents 2.1% of the total samples. Fifteen cases were positive in females, representing 15.8% of all samples analysed.

6. The study provides important information on the risk of *Toxocara canis* contamination in humans, contributing to public health, and the results obtained require prophylactic measures by controlling environmental infestation with *Toxocara* eggs.

7. The main source of contamination of children with *Toxocara* is the ingestion of embryonated eggs from the environment (parks, playgrounds); strict control of the access of ownerless dogs to such places for children is required.

8. In view of the presence of cases in adults, the risk of contamination with *Toxocara* eggs following the consumption of fruit and vegetables that have not been properly washed is highlighted, as the parasite's resistance in nature is high, of around 2 years.

9. The present study stresses the need to control stray dogs and to regularly deworm those

with owners, as well as to inform and educate the population on hygiene measures and on the ways of parasite contamination.

REFERENCES

Abe K., Skimokawa H., Kubota T., Naway Y., and Takeshita T., 2002-Myocarditis associated with visceral larva migrans due to *Toxocara canis*. *Internal Medicine* 41, 706–708.

Costa-Macedo L.M. Rey L. 1990- *Ascaris lumbricoides* in neonate: evidence of congenital transmission of intestinal nematodes, *Rev Inst Med Trop Sao Paulo* Sep-Oct 1990;32(5):351-4. doi:10.1590/s0036-46651990000500007.

Despommier D. 2003- *Toxocariasis: Clinical Aspects, Epidemiology, Medical Ecology and Molecular Aspects*. *Clinical Microbiology Reviews*, 16,265-272. ,<https://doi.org/10.1128/CMR.16.2.265-272.2003>.

Doligalska M., Donskow K. ,2003-Environmental contamination with helminth infective stages implicated in water and foodborne diseases, *Acta Microbiol Pol* 2003;52 Suppl:45-56.

Good, B., Holland, C.V., Taylor, M.R., Larragy, J., Moriarty, P. and Regan, M. (2004) Ocular toxocariasis in schoolchildren. *Clinical Infectious Diseases* 39, 173–178.

Peixoto, C.A., Rocha, A., Aguiar-Santos, A. and Florencio, M.S. (2004) The effects of diethylcarbamazine on the ultrastructure of microfilariae of *Wuchereria bancrofti* in vivo and in vitro. *Parasitology Research* 92, 513–517.

Robinson, A., Tannier, C. and Magnaval, J.-F. (2002) Méningo-radiculite à *Toxocara canis*. *Revue de Neurologie* 158, 351–353.

Schwartzbrod J., Banas A.,2003- Parasite contamination of liquid sludge from urban wastewater treatment plants, *Water Sci Technol* 2003;47(3):163-6.

Taira K., Isaeed A., Permin A., and .Kapel C.M,2004- Zoonotic risk of *Toxocara canis* infection through consumption of pig or poultry viscera. *Veterinary Parasitology*, 121, 115–124.

Xinou E., Lefkopoulos E, A., Gelagoti M., Drevelegas A., Diakou, Milona A., and .Dimitriadis A.S., 2003- CT and MR imaging findings in cerebral toxocaral disease. *American Journal of Neuroradiology* 24, 714–718