

EVALUATION OF A THERAPY PROTOCOL FOR THE TREATMENT OF CHRONIC DIGITAL DERMATITIS IN EUROPEAN BISON (*BISON BONASUS*)

u^b

UNIVERSITÄT
BERN

JUCKER S¹, ALSAOD M², GURTNER C³, BRANDT S⁴, STEINER A², HOBY S¹

¹ Berne Animal Park, Switzerland, sijucker@gmail.com, ² Clinic for Ruminants, Vetsuisse Faculty, University of Bern, Switzerland, ³ Institute of Animal Pathology, Vetsuisse Faculty, University of Bern, Switzerland, ⁴ Research Group Oncology, University of Veterinary Medicine, Austria



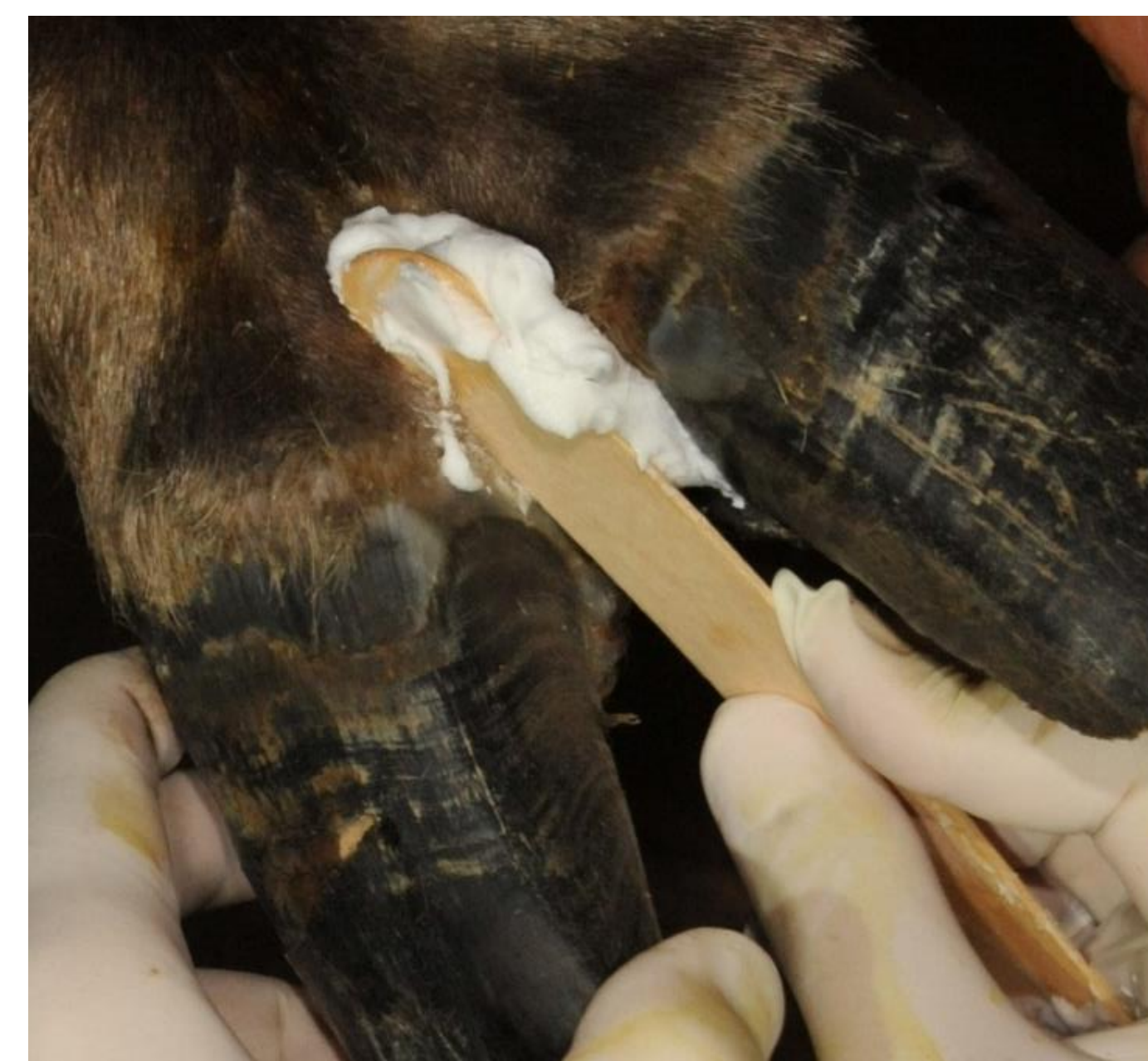
Introduction

Digital dermatitis (DD) is an infectious disease affecting various ungulates, which suffer from acute painful to persistent chronic dermatitis in the distal foot area¹. Bacteria of the genus *Treponema* are considered to play an important role in the aetiology of this multifactorial disease². In European bison (*Bison bonasus*) chronic DD lesions without associated lameness were first described in 2021³. Thereupon this study was initiated to test a nonantibiotic therapy protocol⁴ to cure the detected lesions.

Material and Methods

Five animals with DD were included in the study and all feet (n=40) were treated under general anesthesia according to this protocol:

- Day 1: Pre-treatment biopsy, followed by application of iodopovidone paste (Betadine ointment ad us. Vet., Covetrus AG, Switzerland) and a firm bandage.
 - Day 7: Salicylic acid (Novaderma ad us. vet., Paste, Streuli Tiergesundheit AG, Switzerland) application onto the DD lesion, followed by a firm bandage.
 - Day 14: Removal of necrotic skin tissue by hand and post-treatment biopsy.
- Biopsy samples (n=40) were examined histologically, by PCR and fluorescent in situ hybridization (FISH).



Application of salicylic acid paste onto the affected skin area.

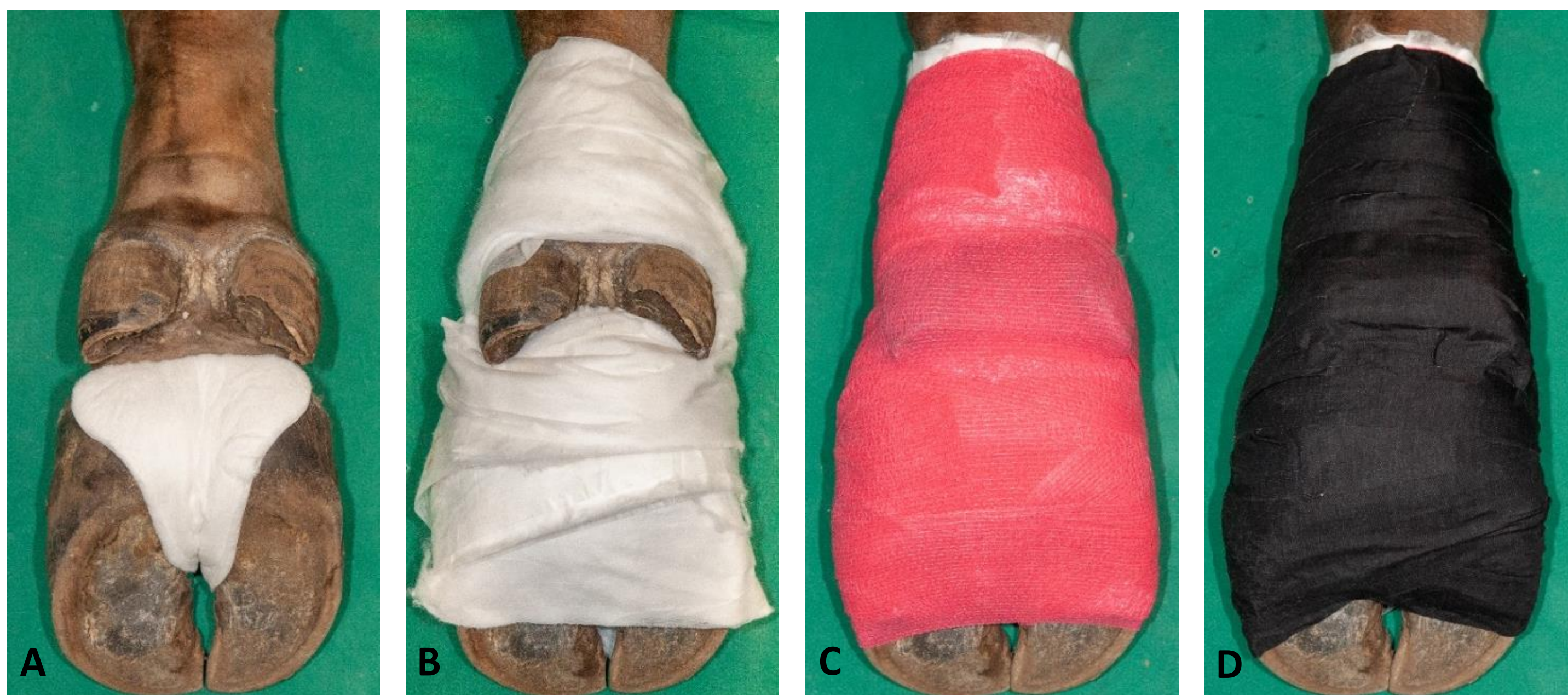

European bison with therapeutic bandages on all four feet.

Results

The percentages of positive feet (n=40) before and after the therapy are shown in the table:

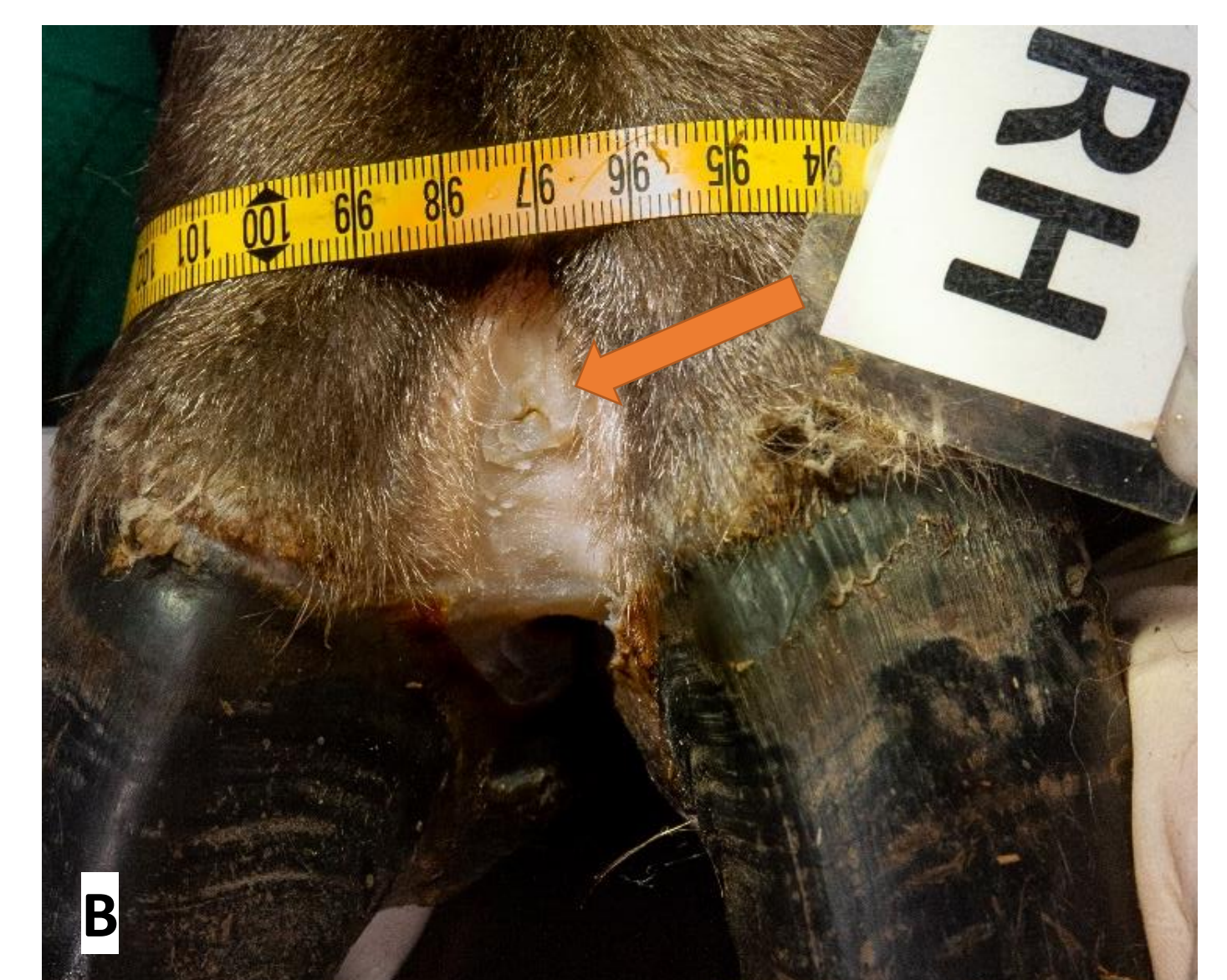
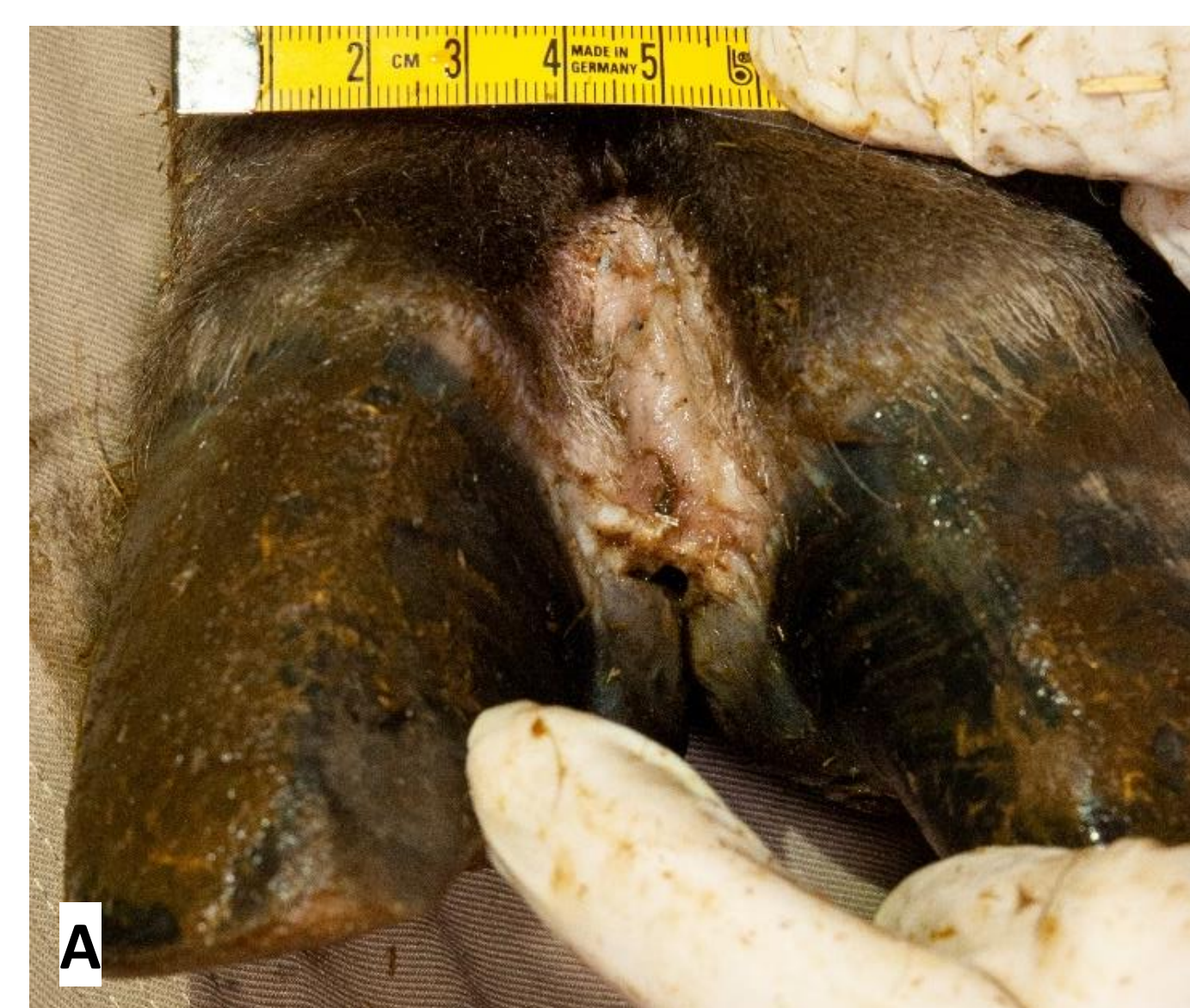	Macroscopic lesions	Histological dermatitis	<i>Treponema</i> spp. DNA by PCR	<i>Treponema</i> spp. in epidermis by FISH
Before therapy	80%	85%	85%	60%
After therapy	5%	60%	0%	0%



Application of a firm waterproof bandage after iodopovidone or salicylic acid application. (A) Padding of interdigital cleft with a water-repellent compress followed by (B) padding of the skin with absorbent cotton. (C) Fixation of the compress and cotton with cohesive tape, and (D) double wrapping of the foot with adhesive tape.

Conclusion

The described therapy can be considered as a standard regimen for affected European bison before transportation to reduce the chance of disease spread.



Dorsal interdigital space of the right hind leg of a European bison. (A) Before treatment, hyperkeratotic pale to slightly reddened skin with smelly plaques is present. (B) After the treatment, removal of hyperkeratotic skin reveals a smooth and dry skin surface. The arrow shows the biopsy site.

Literature

- Palmer MA, O'Connell NE (2015): Digital dermatitis in dairy cows: A review of risk factors and potential sources of between-animal variation in susceptibility. *Animals* 5, 512–35.
- Wilson-Welder JH, Alt DP, Nally JE (2015): Digital dermatitis in cattle: Current bacterial and immunological findings. *Animals* 5, 1114–35.
- Hoby S, Jensen TK, Brodard I, Gurtner C, Eicher R, Steiner A, Kuhnert P, Alsaod M (2021): Detection of treponemes in digital dermatitis lesions of captive European bison (*Bison bonasus*). *PLoS ONE* 16, 1–18.
- Kofler J, Innerebner C, Pesenhofer R, Hangl A, Tichy A (2015): Effectiveness of salicylic acid paste for treatment of digital dermatitis in dairy cows compared with tetracycline spray and hydrotherapy. *Berl Münch Tierärztl Wochenschr* 128, 326–34.