

## Journal Pre-proof

“Improving symmetry of nipple areola complex (NAC) position in reduction mammoplasty using laser level projection”

Thomas Holzbach , Sora Linder , Sebastian Leitsch ,  
Rafael Loucas , Marios Loucas , Riccardo Enzo Giunta ,  
Julius Mayer

PII: S1748-6815(22)00575-7  
DOI: <https://doi.org/10.1016/j.bjps.2022.10.023>  
Reference: PRAS 8003



To appear in: *Journal of Plastic, Reconstructive & Aesthetic Surgery*

Received date: 25 May 2022  
Accepted date: 11 October 2022

Please cite this article as: Thomas Holzbach , Sora Linder , Sebastian Leitsch , Rafael Loucas , Marios Loucas , Riccardo Enzo Giunta , Julius Mayer , “Improving symmetry of nipple areola complex (NAC) position in reduction mammoplasty using laser level projection”, *Journal of Plastic, Reconstructive & Aesthetic Surgery* (2022), doi: <https://doi.org/10.1016/j.bjps.2022.10.023>

This is a PDF file of an article that has undergone enhancements after acceptance, such as the addition of a cover page and metadata, and formatting for readability, but it is not yet the definitive version of record. This version will undergo additional copyediting, typesetting and review before it is published in its final form, but we are providing this version to give early visibility of the article. Please note that, during the production process, errors may be discovered which could affect the content, and all legal disclaimers that apply to the journal pertain.

© 2022 Published by Elsevier Ltd on behalf of British Association of Plastic, Reconstructive and Aesthetic Surgeons.

**“Improving symmetry of nipple areola complex (NAC) position in reduction mammoplasty using laser level projection”**

Holzbach, Thomas MD,<sup>1</sup> Linder, Sora MD,<sup>1</sup> Leitsch, Sebastian MD,<sup>1</sup> Loucas, Rafael MD,<sup>1</sup> Loucas, Marios MD,<sup>2</sup> Giunta, Riccardo Enzo MD,<sup>3</sup> Mayer, Julius MD<sup>4</sup>

- 1 Department of Hand and Plastic Surgery, Thurgau Hospital Group, Frauenfeld, Switzerland
- 2 Department of Hand, Plastic and Aesthetic Surgery, medius Hospital Group, Nuertingen, Germany
- 3 Division of Hand, Plastic and Aesthetic Surgery, University Hospital LMU Munich, Munich, Germany
- 4 Department of Plastic Surgery, Inselspital, University Hospital Bern, Bern, Switzerland

**Corresponding Author**

Mr. Thomas Holzbach

Department of Hand- and Plastic Surgery

Thurgau Hospital Group Department of Hand & Plastic Surgery

Pfaffenholzstrasse 4

8501 Frauenfeld

Switzerland

-mail: thomas.holzbach@stgag.ch

Financial Disclosure Statement:

The author has no financial interest in any of the products, devices, or drugs mentioned in this manuscript.

## **ABSTRACT**

### **Background:**

Symmetrical height of the nipple areola complex (NAC) is a key factor in the perception of breast symmetry. For preoperative markings, we mainly rely on conventional anthropometric measurements of distances in correlation to anatomical landmarks. In this study, we evaluated whether the use of a class-II laser projection water level would lead to better symmetry of nipple height in reduction mammoplasty procedures when used for preoperative planning.

### **Methods:**

We analysed 100 patients undergoing reduction mammoplasty with a supero-medial pedicle and wise pattern skin resection. We compared the bilateral differences in nipple height from the last 50 reduction mammoplasty procedures before using the laser projection water level (group A; *no-laser*) to the first 50 reduction mammoplasties after implementation of this device (group B; *laser*). The follow-up period was 12 months.

### **Results:**

48 patients were included in group A and 44 patients in group B. Patient demographics, mean resection weight and complications did not differ statistically significantly.

Nipple height differences were significantly lower in group B (*laser*), measuring  $0.22 \pm 0.20$  cm (0–0.9; n = 44) compared to  $0.61 \pm 0.28$  cm (0.2–1.2; n = 49) in group A (*no laser*;  $p < 0.001$ ).

**Conclusion:**

Using laser level projection helped to improve nipple height symmetry in reduction mammoplasty. We consider a difference of more than one centimetre in nipple height to be unacceptable in aesthetic reduction mammoplasty. This simple tool facilitates preoperative markings and we find it to be safe, quickly installed, and very helpful in daily practice.

**KEY WORDS:**

Laser level projection, reduction mammoplasty, breast reduction, breast symmetry

Journal Pre-proof

## BACKGROUND

Reduction mammoplasty is among the most frequent procedures in plastic surgery. In addition to volumetric symmetry and correct scar positioning, the symmetrical height of the nipple areola complex (NAC) is a key factor in the perception of breast symmetry.<sup>1-3</sup> Hence, precise preoperative markings are a key factor for optimising symmetry in breast reduction.<sup>4,5</sup> Here, we mainly rely on conventional anthropometric measurements of distances in correlation with anatomical landmarks.<sup>3,5-7</sup> For preoperative planning, the suprasternal notch (SSN)-to-nipple distance and the mid-clavicle (MC)-to-nipple distance is used to determine the correct nipple height.<sup>5-9</sup> However, both distances lack precision.<sup>10</sup> The width of the breast indicates the optimal nipple position in the centre of the breast.<sup>1</sup> Therefore, different breast widths affect the SSN-to-nipple distance, without providing a symmetrical height of the new nipple position. The MC-to-nipple distance accounts for different inaccuracies. Different breast widths may be levelled out to some degree, but the measurement may result in incorrect nipple positioning when there is an asymmetry of clavicle height or length. This finding is very common in patients undergoing breast reduction surgery. The prevalence of adolescent idiopathic scoliosis (AIS) with a Cobb angle  $>10^\circ$  is between 0.5 and 5.2% in the normal population,<sup>11</sup> but the prevalence of asymmetries of the spine and shoulder girdle in patients suffering from macromastia is significantly higher.<sup>12</sup>

Patients mainly evaluate the correct nipple position based on their reflection in the mirror rather than by tape-measuring distances; thus, focusing on the identical height of the NAC of both their breasts.<sup>10</sup>

To ensure optimal symmetry in reduction mammoplasties, many plastic surgeons—our team included—bring their patients into the upright or beach chair position intraoperatively. Despite this, the correct positioning of the patients is not without errors. When tilting the operating room (OR) table and flexing the patient, one often observes remote slipping of the patient towards one side. This may go unnoticed to some degree.<sup>10</sup> When examining the nipple position, a deviation of only a few degrees in the shoulder girdle may result in insufficient symmetry of nipple height.

Surprisingly, modern tools, as routinely used in other areas of precise planning, play a subsidiary role in plastic surgery practices.<sup>4,10,13-17</sup> In 2020, we started using a commercially-available laser projection water level device in our practice.<sup>10</sup> We evaluated whether the use of this tool has led to better symmetry of nipple height in reduction mammoplasty procedures when used for preoperative planning and intraoperative verification of correct NAC position.

## MATERIALS AND METHODS

We used a commercially-available class-II laser projection water level (SmartCross Laserliner®; Laserliner Schweiz AG, Herisau, Switzerland) with a wavelength of 650 nm, accuracy  $\pm 0.50$  mm/m, operating distance 0–10 m, and auto-levelling  $\pm 5^\circ$ , which was mounted on a conventional tripod.

For preoperative markings, patients were provided with a pair of conventional laser-safety goggles (P1L15, NIR-filter wavelength 650–665 nm; Laservision GmbH Fürth, Germany).<sup>18</sup>

The laser was placed within 1 m of the patient for preoperative markings and within 3 m for intraoperative measurements.

We analysed 100 patients undergoing reduction mammoplasty with a supero-medial pedicle and wise pattern skin resection. All surgical procedures were performed in our department by four senior board-certified plastic surgeons.

We compared the bilateral differences in nipple height of the last 50 reduction mammoplasty procedures before using the laser projection water level (group A; *no-laser*) to the first 50 reduction mammoplasties after implementation of this device (group B; *laser*).

The follow-up period in both groups was 12 months. We excluded all patients who were lost to follow-up, had another breast procedure in the meantime or underwent radiotherapy.



For preoperative markings in group B (*laser*), the laser projection water level was used to first mark a horizontal line 5 cm below the SSN in order to exclude asymmetries of clavicle height or length before further planning (Fig. 1). Then, the symmetrical height of NAC upper border markings was verified (Fig. 2).

Intraoperatively, all patients were brought into an upright beach chair position before skin closure to verify the symmetrical NAC position. In study group B (*laser*), the precise upright position of the patients was controlled by the correct alignment of two marker points in a horizontal line 5 cm below the SSN (Fig. 3). Then, the correct nipple height was verified (Fig. 4). The OR lights were dimmed for better visualisation of the projection lines.

Postoperative complications were classified as grade I (minor wound healing issues that needed no further intervention), grade II (wound healing disorders that required prolonged wound dressing, local wound debridements at regular post-op follow-up visits, local haematoma or seroma formation requiring release at regular post-op follow-up visits) or grade III (any complications requiring surgical intervention, including scar correction, surgical haematoma evacuation or secondary wound closure).

Standard follow-up measurements were obtained after 3 months, 6 months and 12 months using a standardized follow-up protocol, including standardised photography,<sup>19</sup> measurements of deviation of nipple height, SSN-to-nipple

distances,<sup>6,8</sup> MC-to-nipple distances, three-dimensional volumetric evaluations,<sup>20,21</sup> scar quality and patients satisfaction.

All photographic images were analysed using Synedra View® Software (Synedra Information Technologies GmbH, Innsbruck, Austria). Pictures were calibrated using a standard gauge within the image plane. Differences in nipple height were calculated in a blinded fashion by determining the sagittal axis, placing the horizontal axis at a 90° angle through the right nipple, and measuring the distance from the horizontal axis at a 90° angle to the left nipple.

### **Statistical Analysis**

The two cohorts (group A and group B) were compared using an independent-samples t-test for continuous variables and chi-square analyses for categorical variables to detect differences between the groups. A difference of  $p < 0.05$  was considered statistically significant. All statistical analyses were performed using IBM SPSS® statistics software (Version 28.0; Chicago, IL, USA).

## RESULTS

The time for correct installation of the laser level projection ranged from 20 s to 2 min (mean, 36.2 s; standard deviation [SD], 17.4 s), with a steep learning curve regarding the correct adjustment of the tripod.

Forty-eight patients were included in group A (*no laser*) and 44 patients in group B (*laser*). Patient demographics did not differ between the groups concerning age, body mass index or relevant co-morbidities (diabetes) (Table I). Mean resection weight was  $504.48 \pm 279.38$  g (90–1480 g; n = 49) in group A (*no laser*) and  $444.03 \pm 254.39$  g (120–1200 g; n = 44) in group B (*laser*). This difference was not statistically significant ( $p = 0.247$ ).

Complications did not differ significantly between the groups (Table II).

Surgical intervention was necessary in two cases in group A (*no laser*). Both patients suffered from diabetes and presented wound healing complications requiring secondary wound closure in the T zone of the inframammary fold. One haematoma evacuation was necessary in group B (*laser*).

The follow-up period in both groups was 12 (11–19) months. Nipple height differences between the two operated sides were  $0.61 \pm 0.28$  cm (0.2–1.2 cm; n = 49) in group A (*no laser*) and  $0.22 \pm 0.20$  cm (0–0.9 cm; n = 44) in group B (*laser*) at the 12 (11–19)-month follow-up. These differences were statistically significant ( $p < 0.001$ ) (Table 2).

## DISCUSSION

We must accept that there is no perfect symmetry in the human body and that differences in NAC height in the scope of millimetres are both acceptable and subject to measuring tolerances. Therefore, although statistical significance was obtained, these results must be analysed carefully.

Nevertheless, we can say that we did not see outliers in nipple height differences when using laser level projection (group B) when compared to controls (group A; Fig. 5a, b, Fig. 6a, b). Thus, we conclude that using laser level projection seems to prevent mistakes either in preoperative planning or in intraoperative verification of correct NAC position.

The outliers in the control group clearly demonstrate the need to optimize markings or implement an objective intraoperative control. We are happy that we could demonstrate that the use of laser level projection did improve nipple height symmetry. Yet, we cannot state whether patients' satisfaction did improve significantly, since we did not collect patient reported outcome measures via validated score sheets. In this study, we merely tried to analyse the effect of our small but significant modification of preoperative markings on nipple height symmetry. Patient satisfaction after reduction mammoplasty is generally very high,<sup>22-25</sup> we do not dare to believe that our modification would make any significant difference. However, as plastic surgeons, we are committed to perfectionism and must perpetually try to improve even the smallest step towards the optimal result.

We agree that NAC height is only one of several aspects that play a role in the perception of breast symmetry; breast shape and volumetric symmetry may be more important. Yet, mistakes in NAC-placement are easy to avoid with our technique. Generally, we find it relevant to refine and objectify every small step to improve the overall outcome. Especially in a teaching hospital, it is important to standardise and facilitate preoperative markings to achieve reproducible and aesthetically sufficient results throughout the entire team.

One can speculate whether the laser level projection-assisted intraoperative verification of correct nipple position alone led to the improved outcome in group B, or whether the laser level projection-assisted preoperative planning itself made for better results.

Patient satisfaction certainly is the most important indicator when evaluating a new technique or the modification of an existing one. However, patient satisfaction after reduction mammoplasty is generally very high. We do not dare to believe, that improved NAC symmetry will make a difference in PROM, but we do believe that laser level projection is an easy to use and reliable technique to prevent mistakes that lead to inferior results.

We are aware that the breast continues to undergo changes e.g. bottoming out or lower pole expansion after 12 months post-surgery. Regardless, a follow-up period of 12 months seems to be acceptable for determining the symmetry of the

nipple position. Although differences of a few millimetres are subject to measurement errors, incorrect patient placement in front of the photographic background, or slight movements before or while taking the picture, we consider a difference of more than one centimetre in nipple height to be unacceptable in aesthetic reduction mammoplasty. To expunge mistakes that lead to such inferior results, the laser projection water level seems to be beneficial.

Surprisingly, this technique does not seem to be in use by plastic surgeons, so far. We found only one article of a work group from Boston, using a laser projection grid to improve symmetry in two cases of breast reduction.<sup>26</sup> To assess symmetry, a fixed grid was projected intraoperatively. However, they did not use a water level, but a class 3B laser projection device.

We see the clear benefit of using a class 2 laser level device. It is affordable (approximate cost: 120–150 USD, including the tripod), safe, quickly to install and it both objectifies and simplifies the preoperative markings. We do not want to work without this simple and helpful tool in our clinic anymore.

However, one must be cautious when using this tool on an unevenly contoured body surface, e.g., when making preoperative markings on augmented breasts, especially when the implant position is different on each side. Although the irregular implant position as an aspect of asymmetry will be corrected in the operation, the skin envelope above the new nipple position remains unaltered. Hence, the new nipple position will be projected at a different distance from the upper breast border.<sup>10</sup> In such instances, we suggest relying on the conventional

measurement of distances at skin level to determine the correct neo-areola position.

## **CONCLUSIONS**

We do not want to work without this simple tool in our clinic anymore. It facilitates and objectively measures the preoperative markings and we find it to be safe, quickly installed and very helpful in daily practice.

Funding: None

Conflicts of interest: None declared

Ethical approval: Not required

## REFERENCES

1. Lewin R, Amoroso M, Plate N, Trogen C, Selvaggi G. The Aesthetically Ideal Position of the Nipple-Areola Complex on the Breast. *Aesthetic Plast Surg* 2016;40(5):724-32.
2. Mallucci P, Branford OA. Population analysis of the perfect breast: a morphometric analysis. *Plast Reconstr Surg* 2014;134(3):436-447.
3. Killaars RC, Preubeta MLG, de Vos NJP, van Berlo C, Lobbes MBI, van der Hulst R, Piatkowski AA. Clinical Assessment of Breast Volume: Can 3D Imaging Be the Gold Standard? *Plast Reconstr Surg Glob Open* 2020;8(11):e3236.
4. Guridi R, Rodriguez JR. A Step-by-Step Approach to a Successful Cosmetic Breast Reduction. *Plast Reconstr Surg Glob Open* 2019;7(4):e2117.
5. Tebbetts JB. A process for quantifying aesthetic and functional breast surgery: I. Quantifying optimal nipple position and vertical and horizontal skin excess for mastopexy and breast reduction. *Plast Reconstr Surg* 2013;132(1):65-73.
6. Bolletta E, McGoldrick C, Hall-Findlay E. Aesthetic Breast Surgery: What Do the Measurements Reveal? *Aesthet Surg J* 2020;40(7):742-752.
7. Hammond DC, Loffredo M. Breast reduction. *Plast Reconstr Surg* 2012;129(5):829e-839e.
8. Hall-Findlay EJ. The three breast dimensions: analysis and effecting change. *Plast Reconstr Surg* 2010;125(6):1632-1642.
9. Westreich M. Anthropomorphic breast measurement: protocol and results in 50 women with aesthetically perfect breasts and clinical application. *Plast Reconstr Surg* 1997;100(2):468-79.
10. Holzbach T. Laser Level Projection – a helpful tool for preoperative markings. *Plast Reconstr Surg* 2022;- accepted 2/2022 -
11. Belli G, Toselli S, Latessa PM, Mauro M. Evaluation of Self-Perceived Body Image in Adolescents with Mild Idiopathic Scoliosis. *Eur J Investig Health Psychol Educ* 2022;12(3):319-333.
12. Papanastasiou C, Ouellet JA, Lessard L. The Effects of Breast Reduction on Back Pain and Spine Measurements: A Systematic Review. *Plast Reconstr Surg Glob Open* 2019;7(8):e2324.
13. Tejos R, Navia A, Rojas MF, Cuadra A, Searle S. A Novel, Low-Cost Method for Teaching Breast Reduction Markings to Plastic Surgery Residents Amid the COVID-19 Pandemic. *Aesthet Surg J* 2021;4(5):NP245-NP246.
14. Koban KC, Leitsch S, Holzbach T, Volkmer E, Metz PM, Giunta RE. [3D-imaging and analysis for plastic surgery by smartphone and tablet: an alternative to professional systems?]. *Handchir Mikrochir Plast Chir* 2014;46(2):97-104.



15. Koban KC, Perko P, Etzel L, Li Z, Schenck TL, Giunta RE. Validation of two handheld devices against a non-portable three-dimensional surface scanner and assessment of potential use for intraoperative facial imaging. *J Plast Reconstr Aesthet Surg* 2020;73(1):141-148.
16. Schuster M, Lohscheller J, Kummer P, Eysholdt U, Hoppe U. Laser projection in high-speed glottography for high-precision measurements of laryngeal dimensions and dynamics. *Eur Arch Otorhinolaryngol* 2005;262(6):477-81.
17. Patel RR, Donohue KD, Lau D, Unnikrishnan H. In Vivo measurement of pediatric vocal fold motion using structured light laser projection. *J Voice* 2013;27(4):463-72.
18. Frederiksen A, Fiess R, Stork W, Bogatscher S, Heussner N. Eye safety for scanning laser projection systems. *Biomed Tech (Berl)* 2012;57(3):175-84.
19. DiBernardo BE, Adams RL, Krause J, Fiorillo MA, Gheradini G. Photographic standards in plastic surgery. *Plast Reconstr Surg* 1998;102(2):559-68.
20. Wood KL, Zoghbi Y, Margulies IG, Ashikari AY, Jacobs J, Salzberg CA. Is the Vectra 3D Imaging System a Reliable Tool for Predicting Breast Mass? *Ann Plast Surg* 2020;85(S1 Suppl 1):S109-S113.
21. O'Connell RL, Stevens RJ, Harris PA, Rusby JE. Review of three-dimensional (3D) surface imaging for oncoplastic, reconstructive and aesthetic breast surgery. *Breast* 2015;24(4):331-42.
22. Perez-Panzano E, Guemes-Sanchez A, Gascon-Catalan A. Quality of Life Following Symptomatic Macromastia Surgery: Short- and Long-term Evaluation. *Breast J* 2016;22(4):397-406.
23. Nuzzi LC, Firriolo JM, Pike CM, Cerrato FE, Webb ML, Faulkner HR, DiVasta AD, Labow BI. The Effect of Reduction Mammoplasty on Quality of Life in Adolescents With Macromastia. *Pediatrics* 2017;140(5)
24. Cerrato F, Webb ML, Rosen H, Nuzzi L, McCarty ER, DiVasta AD, Greene AK, Labow BI. The impact of macromastia on adolescents: a cross-sectional study. *Pediatrics* 2012;130(2):e339-46.
25. Elfanagely O, Othman S, Rios-Diaz AJ, Cuning JR, Whitely C, Butler P, Fischer JP. A Matched Comparison of the Benefits of Breast Reduction on Health-Related Quality of Life. *Plast Reconstr Surg* 2021;148(4):729-735.
26. Chen YE, Gerstle TL, Liang F, Lee BT. Use of a novel laser projection grid to assess symmetry in breast surgery. *Plast Reconstr Surg* 2012;130(1):231e-233e.

|                                      | <b>Group A</b><br><b>Mean ± Std (Min, Max)</b> | <b>Group B</b><br><b>Mean ± Std (Min, Max)</b> | <b>p-Value</b> | <b>Test</b> |
|--------------------------------------|--|--|----------------|-------------|
| <b>Age at surgery</b>                | 42.10 ± 13.98 (18; 69), n = 49                 | 42.27 ± 16.78 (17; 72), n = 44                 | 0.988          | MWU         |
| <b>Gender</b>                        | 49 Female                                      | 44 Female                                      | -              | Fisher      |
| <b>Side (Uni/Bilateral)</b>          | 49 Bilateral                                   | 44 Bilateral                                   | -              | Fisher      |
| <b>Body Mass Index</b>               | 26.94 ± 3.88 (20.8; 39.2), n = 49              | 25.13 ± 3.44 (20.5; 32.7), n = 44              | 0.224          | MWU         |
| <b>Diabetes</b>                      | 2/49   | 0/44   | -              | -           |
| <b>Primary reduction mammoplasty</b> | 49   | 44   | -              | -           |

**Table I:** Patients Demographics

|   | <b>Group A</b>                              | <b>Group B</b>                              | <b>p value</b> |
|---|---|---|----------------|
| <b>Resection Weight both Sides</b>                        | 504.48 ± 279.38<br>(90; 1480)<br>n = 49     | 444.03 ± 254.39<br>(120; 1200)<br>n = 44    | 0.247          |
| <b>Resection Weight Right Side</b>                        | 506.63 ± 293.03<br>(90; 1480)<br>n = 49     | 443.93 ± 262.65<br>(120; 1200)<br>n = 44    | 0.239          |
| <b>Resection Weight Left Side</b>                         | 502.34 ± 268.06<br>(120; 1290)<br>n = 49    | 444.13 ± 248.89<br>(120; 1200)<br>n = 44    | 0.256          |
| <b>Nipple Height Difference 12 months postoperatively</b> | 0.61 ± 0.28 (0.2; 1.2)<br>n = 49            | 0.22 ± 0.20 (0; 0.9)<br>n = 10              | <0.001         |
| <b>Complications (Grade I-III)</b>                        | Grade I : 4<br>Grade II : 2<br>Grade III: 2 | Grade I : 4<br>Grade II : 3<br>Grade III: 1 | 0.816          |

**Table II:** Intra- and postoperative results; values are given as mean ± SD [95% Confidence Interval] or (minimum; maximum).

**FIGURE LEGENDS**

Fig. 1

Laser level-assisted preoperative marking in Patient 1: first, a horizontal line 5 cm below the SSN was marked in order to exclude asymmetries of clavicle height or length before further planning (a recognisable tattoo below the left clavicle has been obscured).

Fig. 2

Laser level-assisted preoperative marking in Patient 1: Planning of symmetrical height of new NAC upper border.

Fig. 3

Intraoperative laser level projection in Patient 1: First, the precise upright beach chair position of the patient was verified by correct alignment of two marker points in a horizontal line 5 cm below the SSN.

Fig. 4

Intraoperative laser level projection in Patient 1: The symmetrical height of the nipple position was verified.

Fig. 5

Mean Nipple Height Difference 12 months postoperatively. Differences in nipple height were significantly lower ( $p < 0.001$ ) in group B using laser level projection (mean 0.22, range 0-0.9, SD 0.20) compared to group A (mean 0.61, range 0.2-1.2, SD 0.28)

Fig. 6a + b

Preoperative (5a) and postoperative (5b; 12 months postoperatively) photographs of Patient 1 (group B; *laser*): Resection weight was 470 g (right) and 360 g (left). The postoperative difference in nipple height was 2.3 mm. Note the difference in clavicle height preoperatively, which could possibly have led to asymmetric marking of the new NAC position. The difference in clavicle height is still present 12 months postoperatively, despite the symmetrising reduction mammoplasty, indicating a fixed rather than compensatory asymmetry.

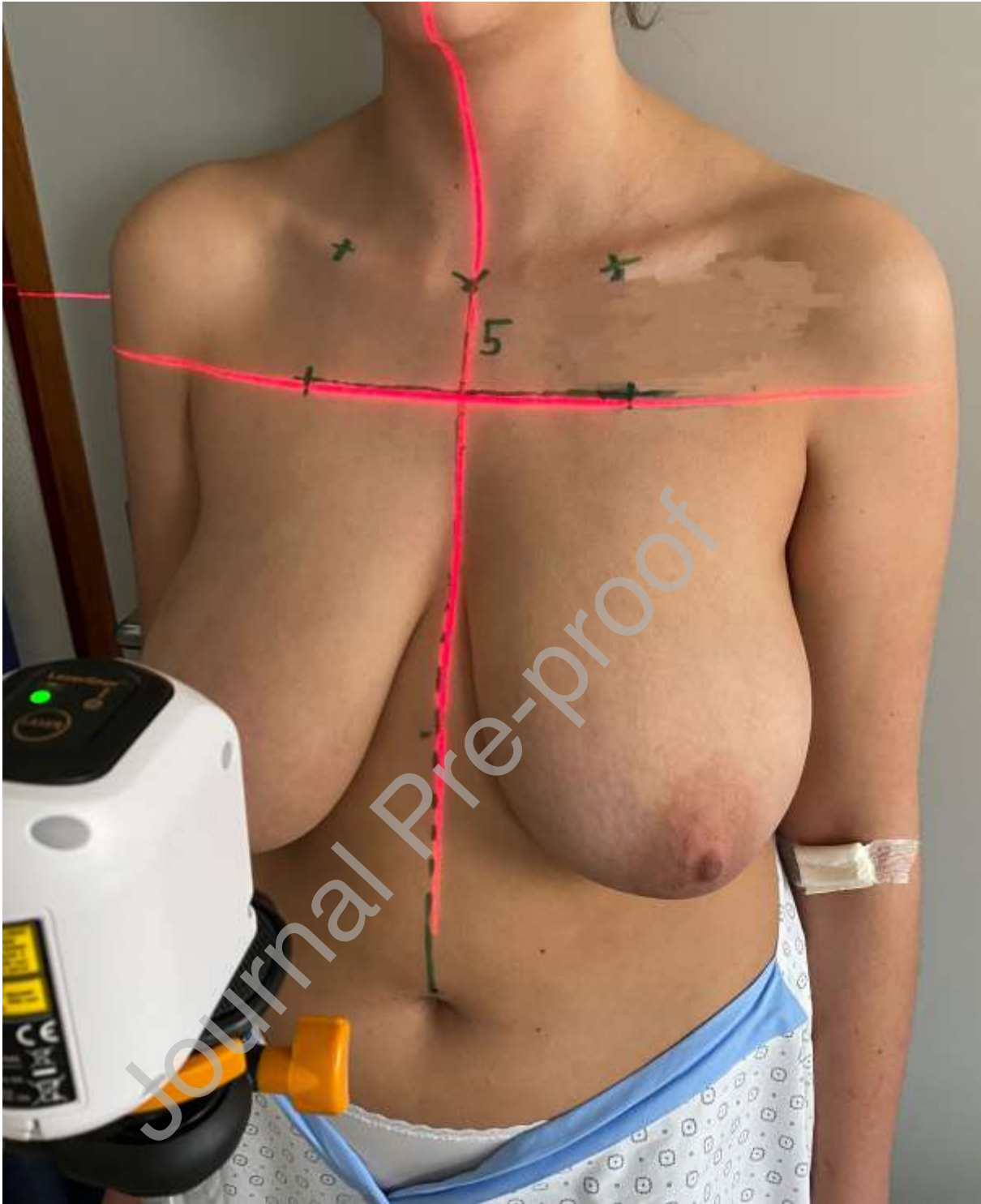
Fig. 7a + b

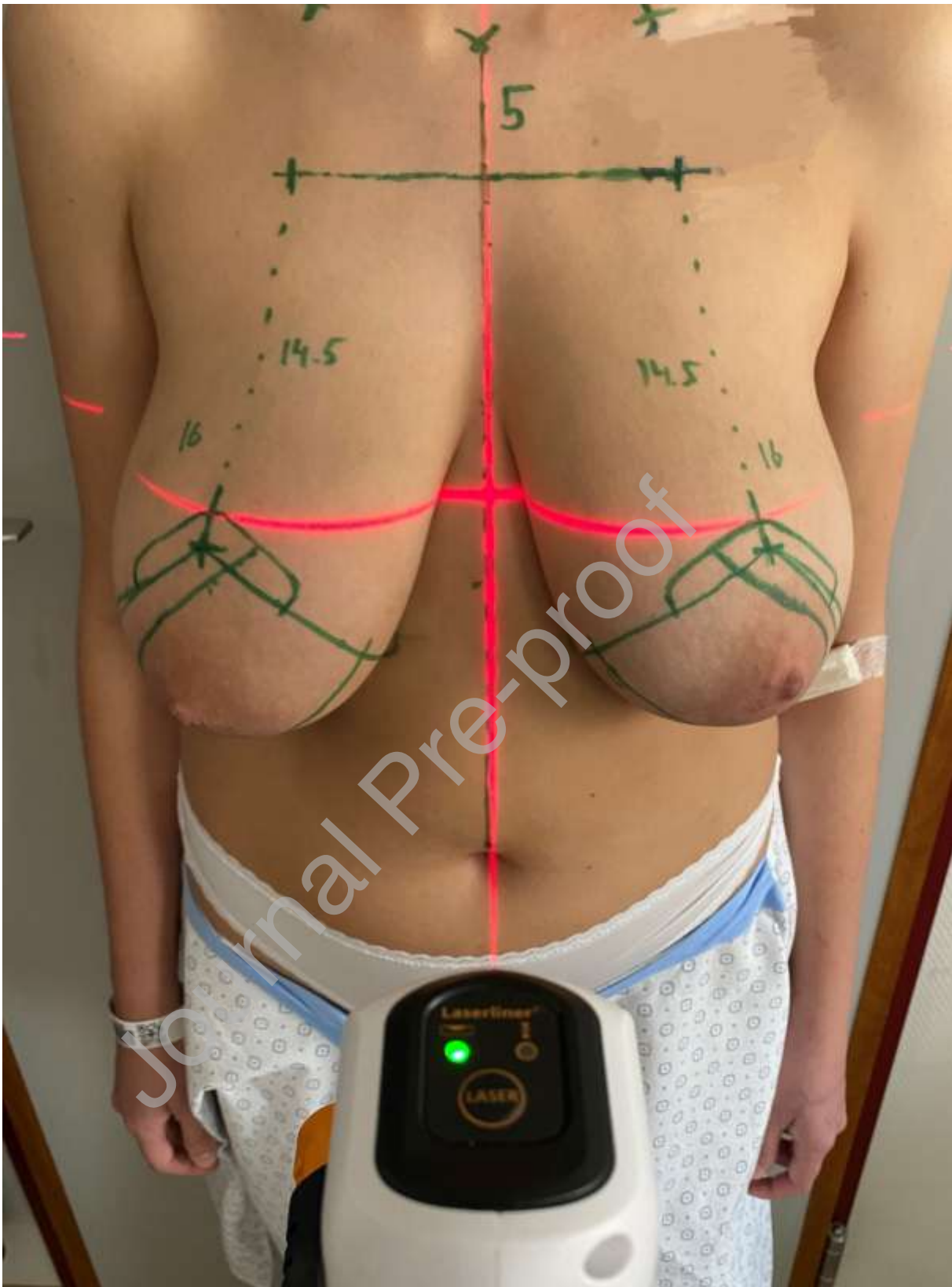
Preoperative (6a) and postoperative (6b; 12 months postoperatively)

photographs of Patient 2 (group A; *no-laser*): Resection weight was 490 g (right) and 550 g (left). The postoperative difference in nipple height was 10.7 mm. This outlier in nipple height symmetry is considered unacceptable.

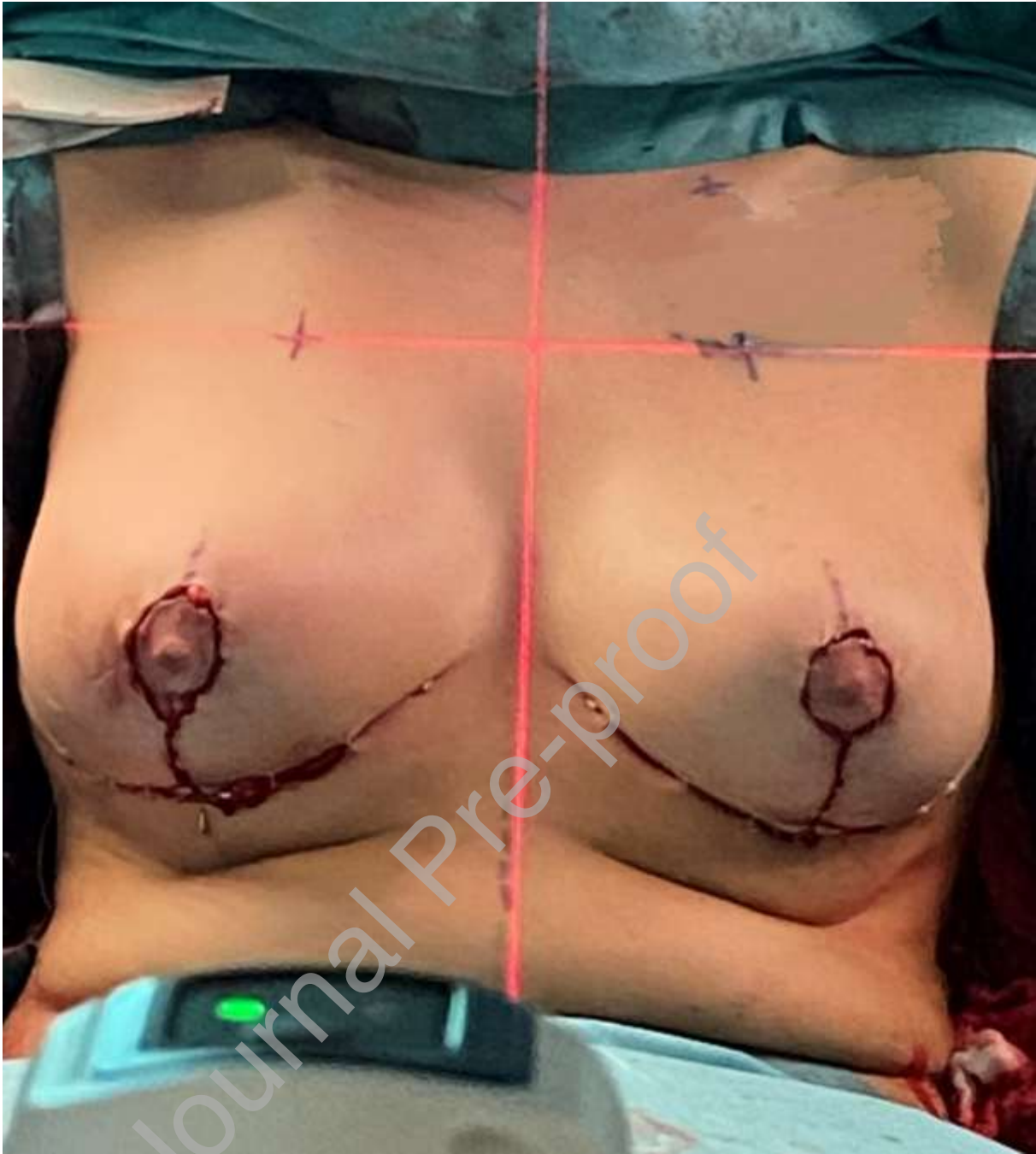Note the difference in clavicle height preoperatively, which could have led to asymmetric marking of the new NAC position. The difference in clavicle height is still present 12 months postoperatively, despite the symmetrising reduction mammoplasty, indicating a fixed rather than compensatory asymmetry.

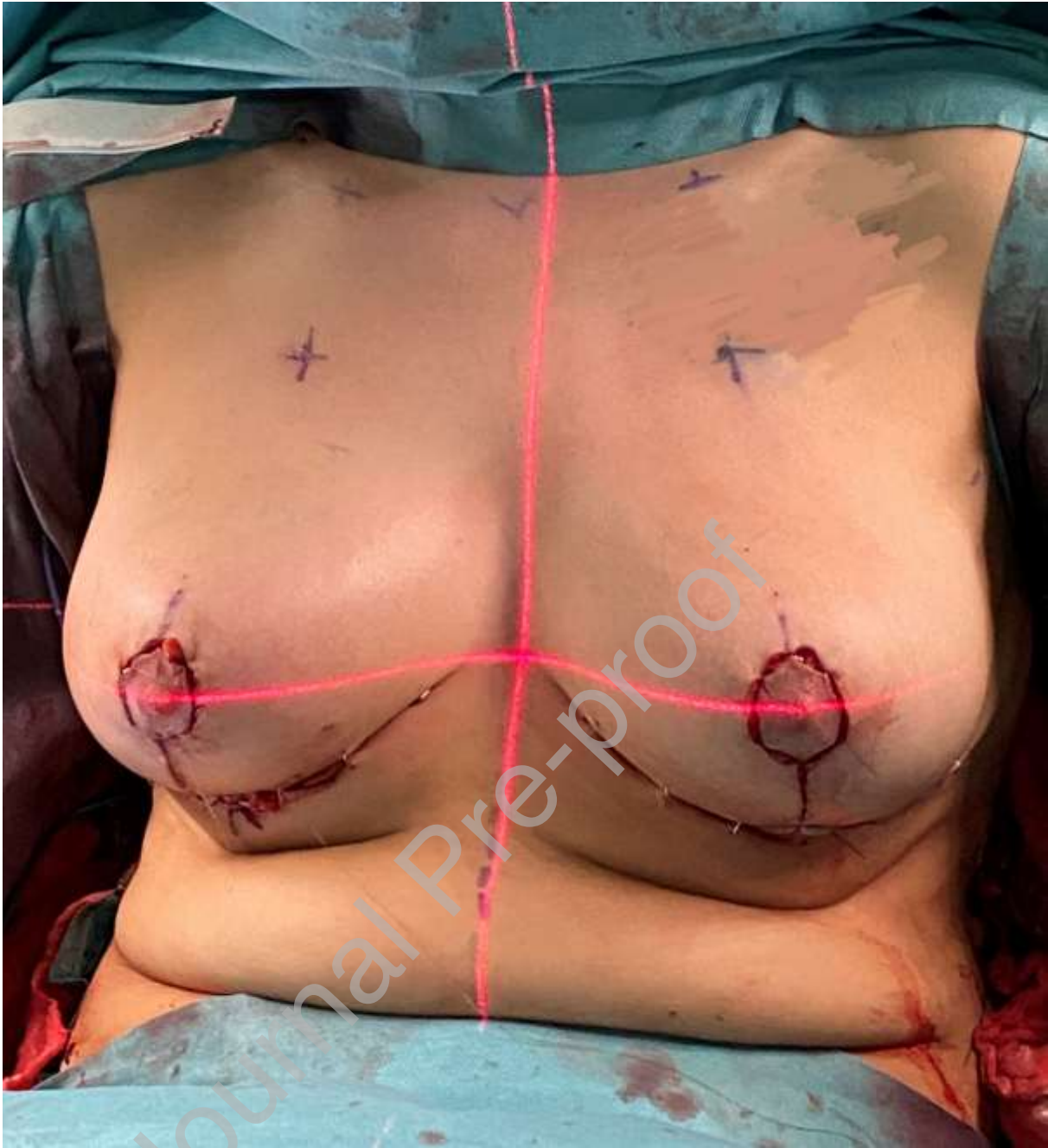Journal Pre-proof











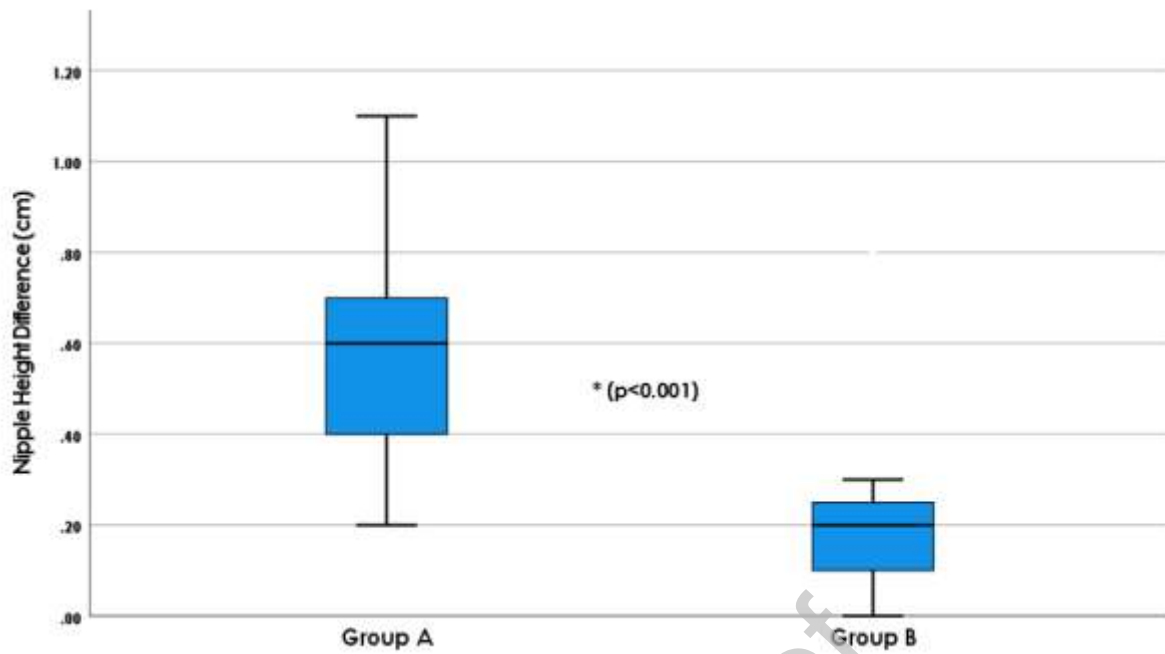


Fig. 5

Mean Nipple Height Difference 12 months postoperatively. Differences in nipple height were significantly lower ( $p < 0.001$ ) in group B using laser level projection (mean 0.22, range 0-0.9, SD 0.20) compared to group A (mean 0.61, range 0.2-1.2, SD 0.28)

