

Technical Note Reconstructive Surgery

Use of suborbicularis oculi fat flap to cover peri-orbital bone exposure

A. Di Martino¹, P. Bonavolontà²,
 G. Dell'Aversana Orabona²,
 F. Schönauer¹

¹Unit of Plastic Surgery, University of Naples "Federico II", Naples, Italy; ²Department of Maxillofacial Surgery, University of Naples "Federico II", Naples, Italy

A. Di Martino, P. Bonavolontà, G. Dell'Aversana Orabona, F. Schönauer: Use of suborbicularis oculi fat flap to cover peri-orbital bone exposure. *Int. J. Oral Maxillofac. Surg.* 2016; xxx: xxx–xxx. © 2016 International Association of Oral and Maxillofacial Surgeons. Published by Elsevier Ltd. All rights reserved.

Abstract. Wide resection of recurrent basal cell carcinoma (BCC) in the peri-orbital–infraorbital–nasal area may include periosteum resection with maxillary or nasal bone exposure. The absence of vascularized periosteum makes the defect ungraftable and local flaps are often required. As an alternative to a large single flap or a combination of flaps, it is possible to turn the ungraftable portion of the defect into a graftable one. The suborbicularis oculi fat (SOOF) flap is an advancement flap that is used in aesthetic surgery for midface rejuvenation. The use of the SOOF flap along with a full-thickness skin graft, as an alternative to the use of other standardized flaps to cover defects in the peri-orbital–infraorbital–nasal area with avascularized tissue or noble structure exposure, is reported herein. As an immediate single-stage reconstruction, this procedure leaves other flap options intact in the event of re-operation for a recurrent tumour.

Keywords: SOOF flap; facial reconstruction; fat flap; bone exposure; skin graft.

Accepted for publication 16 September 2016

Wide resection of malignant skin tumours in the peri-orbital–infraorbital–nasal area may include periosteal resection and can result in soft tissue defects with maxillary or nasal bone exposure (dual tissue defect). Maxillary or nasal bone exposure without periosteal cover represents an avascularized site. The absence of vascularization makes it ungraftable and local flaps are often required. If a large dual tissue defect is present, one alternative to the use of a large single flap or a combination of flaps is to turn the ungraftable portion of the defect into a graftable one.

As described for aesthetic surgery techniques in midface rejuvenation,^{1,2} where central and medial compartments of the suborbicularis oculi fat (SOOF) have been used to resurface the orbital crease, these fat compartments have been used at the authors' institution as an advancement flap to cover the exposed bone portion of the defect, making it readily graftable.

The cases of two patients with basal cell carcinoma (BCC) of the peri-orbital–infraorbital–nasal region infiltrating the underlying periosteum, treated with a SOOF flap and full-thickness skin graft following tumour resection, are presented herein.

Case reports

Case 1

A 71-year-old female patient was admitted to the clinic with an extensive recurrent BCC of the right peri-orbital–infraorbital–nasal area. After complete ophthalmological examination to exclude ocular involvement, wide resection of the lesion with a 1-cm tumour-free margin was performed under local anaesthesia. The resection, in its central portion, included the underlying periosteum of the maxillary bone. Bipolar haemostasis was achieved. The result was a defect

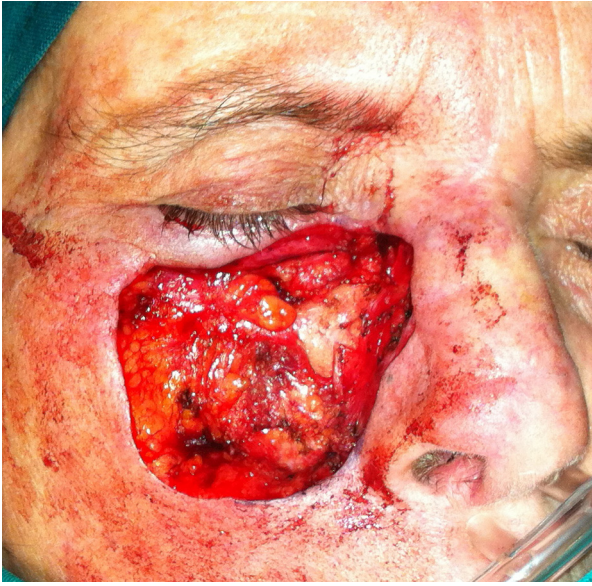

Fig. 1. Defect resulting from the resection of a long-standing basal cell carcinoma of the right peri-orbital–infraorbital–nasal area, with partial exposure of the right maxillary bone.

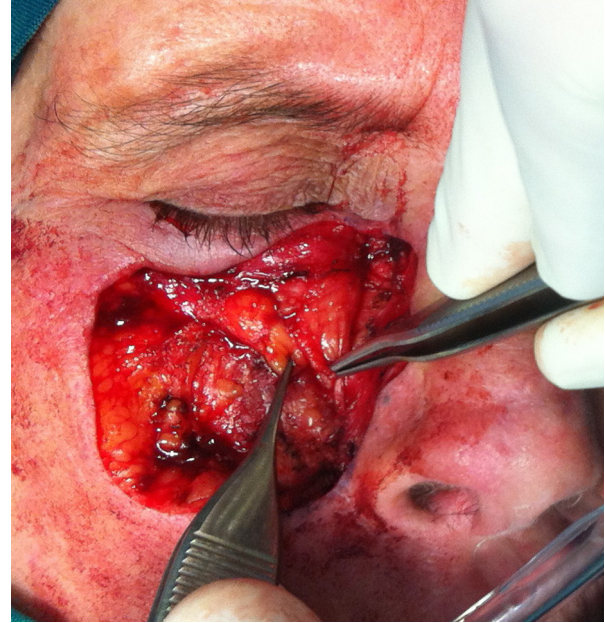

Fig. 2. Suborbicularis oculi fat flap advanced to cover the exposed right maxillary bone.

measuring $3.7\text{ cm} \times 2.1\text{ cm}$ with a portion of exposed maxillary bone measuring $1.5\text{ cm} \times 1.6\text{ cm}$ (Fig. 1). Intraoperative histology identified an aggressive BCC with tumour-free margins.

Beneath the pretarsal segment of the orbicularis oculi muscle, the orbital septum was released at the arcus marginalis. The medial and central fat compartments were mobilized inferiorly as a sliding pad

(SOOF flap) to cover the exposed bone. This was secured to the superficial musculoaponeurotic system at the zygomatic arch below the exposed bone area with a few 5–0 Vicryl sutures (Fig. 2).

A full-thickness skin graft, harvested from the pre-auricular region, was positioned over the vascularized fat flap for wound closure. Quilting sutures and a tie-over dressing were used to guarantee ad-

herence of the skin graft to the defect bed. Graft take was optimal on day 6 postoperative (Fig. 3).

Definitive histology confirmed an aggressive BCC, which had been completely excised. At the 18-month follow-up there was no sign of local recurrence and the patient was satisfied with the result, despite the presence of a mild medial scleral show (Fig. 4).

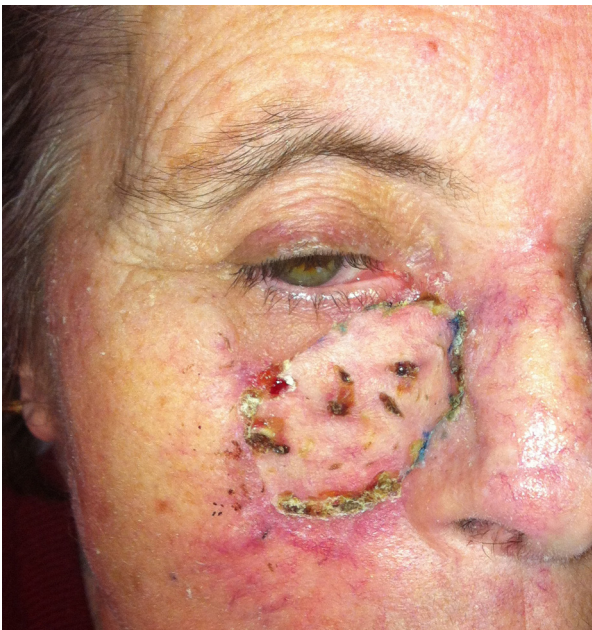

Fig. 3. Skin graft take in the peri-orbital–infraorbital–nasal area on day 6 postoperative.

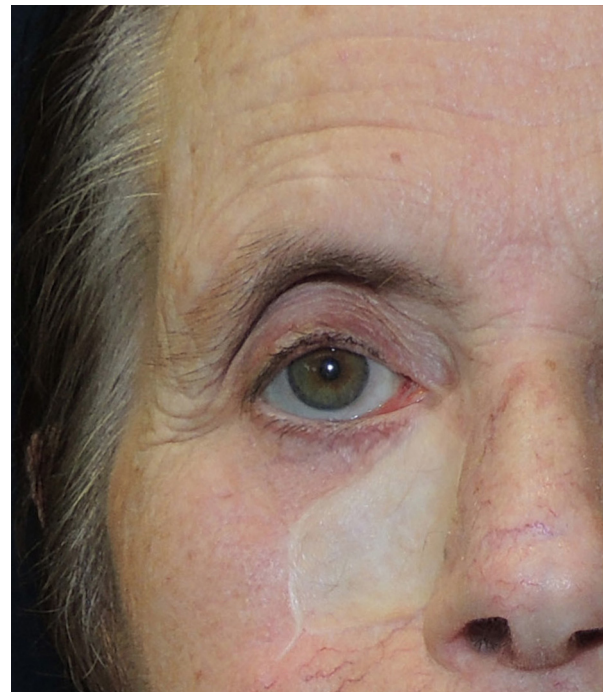

Fig. 4. No sign of local recurrence at 18 months of follow-up; a mild medial scleral show is present.

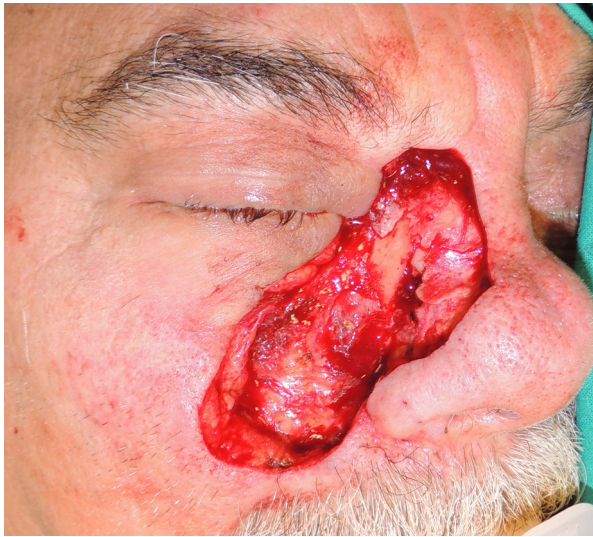

Fig. 5. Defect resulting from wide resection of a basal cell carcinoma of the right peri-orbital–nasal area, with exposure of a portion of the right nasal bone.

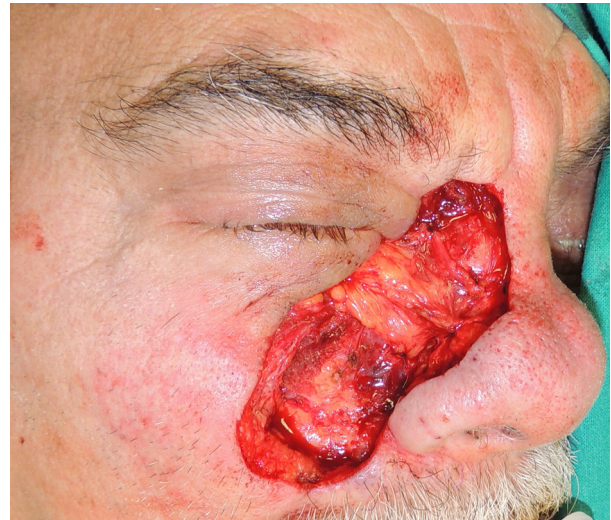

Fig. 6. Suborbicularis oculi fat flap advanced to cover the right nasal bone exposure.

Case 2

A 68-year-old male patient was admitted to the clinic with a skin lesion located in the nasal–peri-orbital area. He reported that the lesion had first appeared 7 years earlier as a nodule and had progressively enlarged. On examination the lesion extended from the right nasal dorsum to the right internal canthus, without ocular involvement, and inferiorly towards the upper lip along the nasolabial crease. An excisional biopsy was performed.

Histology showed an aggressive micronodular BCC extensively infiltrating the underlying dermis. A larger and deeper excision of the primary tumour site was performed, including the nasal bone periosteum. This resulted in a 5.5 cm × 3 cm defect in the nasal–peri-orbital area with a portion of exposed nasal bone measuring 1.9 cm × 1.1 cm (Fig. 5). Intraoperative histology identified a BCC with tumour-free margins. Thereafter, reconstruction was performed at the same stage: a SOOF flap was harvested and advanced medially and inferiorly to cover the nasal bone exposure (Fig. 6). A full-thickness skin graft was harvested from the left supraclavicular region and was placed on top of the vascularized fat for wound closure. A tie-over dressing was added.

There were no postoperative complications and the graft take on day 6 postoperative was 100%. Definitive histology confirmed an aggressive BCC; the sample margins were tumour-free.

At the 18-month follow-up the patient presented no recurrence and the result was

satisfactory to the patient and to the surgeon (Fig. 7).

Discussion

BCC is by far the most common non-melanoma skin cancer worldwide and perhaps the most common human cancer, with a constantly increasing incidence of 3–10% per year.³ BCC tends to arise in sun-exposed areas of the

body, most commonly in the upper region of the face.³

Selecting the appropriate technique for surgical incision and the restoration of facial defects has always been one of the surgeon's greatest concerns. The technique used depends on the nature, extent, depth, and position of the tissue loss, on donor site availability and morbidity, and on the patient's age, condition, and expectations.

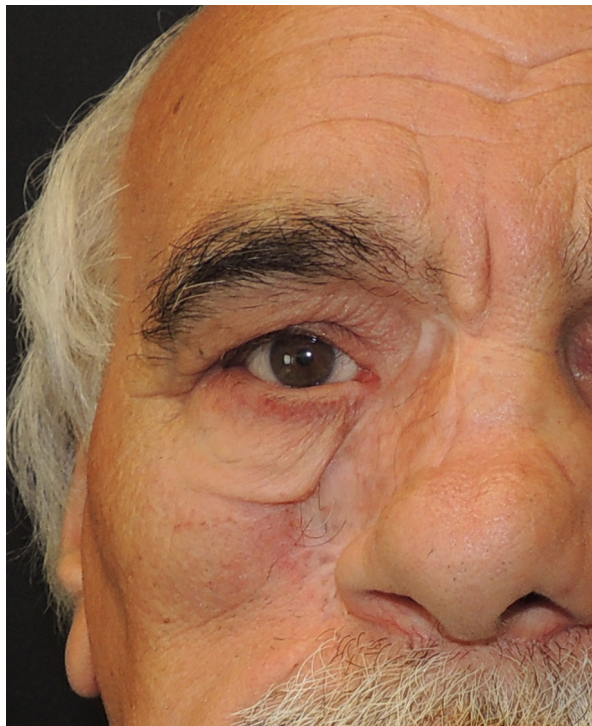

Fig. 7. No sign of local recurrence and a satisfactory result at 18 months of follow-up.

In the case of periosteal resection and bone exposure, the use of a skin graft is not possible, as an avascularized bed does not allow graft take. Secondary granulation on free bone surfaces can solve the problem, but this is a lengthy process and turns a single-stage reconstruction into a two-stage procedure.

Combined nasal–infraorbital–peri-orbital defects with bone exposure can be restored with the use of local or loco-regional flaps that bring an adequate vascular supply to the non-vascularized tissue. Various surgical options include the advancement V–Y flap, Mustardé cheek rotation flap, paramedian forehead flap,⁴ nasal superficial musculoaponeurotic system pedicled island skin flap,⁵ or orbicularis oculi myocutaneous flap.⁶

The SOOF lies in the lower eyelid, between the orbital orbicularis muscle and the maxillary periosteum. This fat pad is protected and separated anteriorly from the orbicularis muscle by the orbital septum, which extends from the arcus marginalis of the orbital rim to the capsulopalpebral fascia before its insertion onto the tarsal Plates.⁷ The SOOF is composed of three fat regions: the medial, central, and lateral compartments. Another fat compartment just above the lateral compartment has been described, and is referred to as ‘pretarsal fat’.⁸

In facial rejuvenation procedures, SOOF can be removed or repositioned. In lower blepharoplasties aimed at removing the bulges just below the eyelashes, the lateral and pretarsal fat compartments have traditionally been removed and any excess of the central and medial compartments has been reduced.

Loeb, and later Hamra, popularized a new technique for midface rejuvenation: instead of removing the excess lower lid fat, they stretched the fat tissue from the central and medial compartments of the SOOF, using it to redrape the inferior orbital crease.^{1,2} Loeb used it for the nasojugal groove,¹ and Hamra addressed the procedure to avoid the sunken eyelid resulting from ageing.² With the same purposes, Goldberg described the use of the orbital fat as a random, pedicled, but pivotal flap and its repositioning in a subperiosteal pocket.⁹

In facial reconstruction, fat pads can be used as free grafts or as flaps. The Bichat buccal fat pad is the most frequently used fat flap, especially to close maxillary defects after tumour excision.¹⁰

The use of the SOOF flap as a random, pedicled, advancement fat flap, consisting of the medial and/or central compartments of SOOF, has not been described before for reconstructive purposes (Fig. 8).

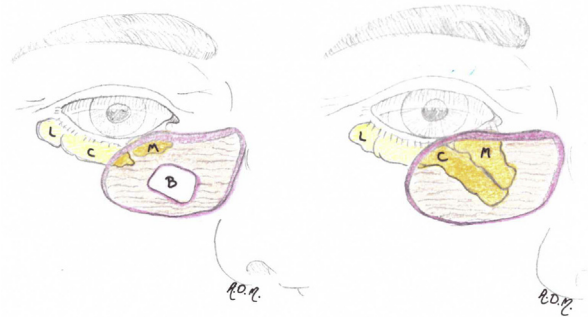


Fig. 8. Illustration of the suborbicularis oculi fat flap. B: bone exposure; M: medial compartment of suborbicularis oculi fat; C: central compartment of suborbicularis oculi fat; L: lateral compartment of suborbicularis oculi fat.

As stated, small-sized bone exposure can be covered with a SOOF flap, transforming an ungraftable bed into a graftable one. The limitations of this technique are those related to the use of a skin graft instead of a skin flap, such as colour mismatch and skin retraction. The latter disadvantage must be taken into consideration, especially in the context of eyelid reconstruction. However, the preliminary use of this single-stage reconstructive technique leaves other surgical alternatives open in the event of re-operation for a recurrent tumour.⁴

The authors recommend the use of the SOOF flap as an alternative to the use of other standardized flaps to cover defects in the peri-orbital–infraorbital–nasal area with avascularized tissue or noble structure exposure. The use of the SOOF flap in achieving skin graft take on exposed facial bone does not exclude its suitability for other reconstructive purposes.

Funding

We wish to confirm that there was no significant financial support for this work that could have influenced the outcome.

Competing interests

We wish to confirm that there are no known conflicts of interest associated with this publication.

Ethical approval

The Ethics Committee of the University of Naples ‘‘Federico II’’ notes that at the time of the programming of this clinical study, there was neither the obligation nor the express opportunity to submit in advance the research project to the ethics committee in order to obtain formal approval for the realization of the same (reference no. 805/16).

Patient consent

Written patient consent was obtained to publish the clinical photographs.

References

- Loeb R. Fat pad sliding and fat grafting for leveling lid depressions. *Clin Plast Surg* 1981;**8**:757–76.
- Hamra ST. Arcus marginalis release and orbital fat preservation in midface rejuvenation. *Plast Reconstr Surg* 1995;**96**:354–62.
- Renaud-Vilmer C, Basset-Seguin N. Basal cell carcinomas. *Rev Prat* 2014;**64**:37–44.
- Cogrel O, Ofaiche J. Reconstruction of the medial nasal canthus using a single-stage paramedian forehead flap. *Ann Dermatol Venereol* 2015;**142**:220–1.
- Doğan F, Özyazgan I. New flap for the reconstruction of the perinasal region. *Facial Plast Surg* 2014;**30**:676–80.
- Tirone L, Schonauer F, Sposato G, Molea G. Reconstruction of lower eyelid and periorbital district: an orbicularis oculi myocutaneous flap. *J Plast Reconstr Aesthet Surg* 2009;**62**:1384–8.
- Fante G, Hawes M. Reconstruction of the eyelids. In: Baker SR, editor. *Local flaps in facial reconstruction*. 3rd ed. Elsevier Saunders; 2014. p. 388.
- Hwang K, Kim DJ, Chung RS. Pretarsal fat compartment in the lower eyelid. *Clin Anat* 2001;**14**:179–83.
- Goldberg RA. Transconjunctival orbital fat repositioning: transposition of orbital fat pedicles into a subperiosteal pocket. *Plast Reconstr Surg* 2000;**105**:743–8.
- Tostevin PM, Ellis H. The buccal pad of fat: a review. *Clin Anat* 1995;**8**:403–6.

Address:

Annalena Di Martino

Via Pansini 5

80131 Naples

Italy

E-mail: annalena.dimartino@gmail.com