



Orbital atherectomy for heavily calcified coronary lesions in a patient with heart failure and severely impaired left ventricular ejection fraction

Authors: Mateusz Tajstra, Krzysztof Wilczek, Łukasz Pyka, Mariusz Gąsior

Article type: Clinical vignette

Received: July 6, 2022

Accepted: October 21, 2022

Early publication date: December 12, 2022

This article is available in open access under Creative Common Attribution-Non-Commercial-No Derivatives 4.0 International (CC BY-NC-ND 4.0) license, allowing to download articles and share them with others as long as they credit the authors and the publisher, but without permission to change them in any way or use them commercially.

Orbital atherectomy for heavily calcified coronary lesions in a patient with heart failure and severely impaired left ventricular ejection fraction

Mateusz Tajstra, Krzysztof Wilczek, Łukasz Pyka, Mariusz Gąsior

3rd Department of Cardiology, Medical University of Silesia in Katowice, Silesian Center for Heart Diseases, Zabrze, Poland

Short title: Orbital atherectomy in a patient with heart failure

Conflict of interest: None declared.

Correspondence to:

Mateusz Tajstra, MD, PhD,
Silesian Center for Heart Diseases,
Szpitalna 2, 41–800 Zabrze, Poland
phone: +48 32 373 36 74,
fax: +48 32 273 26 79,
e-mail: mateusztajstra@wp.pl

Percutaneous coronary interventions (PCI) of calcified lesions strongly and independently affects early angiographic and long-term clinical outcomes [1, 2]. Currently, the Diamondback 360 Coronary Orbital Atherectomy (COA) System (Cardiovascular Systems) is one of the few allowing optimal immediate and long-term PCI outcome. Although the safety and efficacy of COA in PCI have been reported earlier, the current evidence of its use in patients with severe impaired left ventricular ejection fraction (LVEF) is limited [3, 4]. Moreover, recently published case proofed effectiveness and safety of the use of rotational atherectomy in high-risk PCI in patients with low LVEF [5]. This report describes a PCI with COA in a patient with heart failure (HF) and severely impaired LVEF.

A 72-year-old male with arterial hypertension and hyperlipidemia, after an anterior ST-segment elevation myocardial infarction (2011), was diagnosed in March 2022 with multivessel coronary artery disease. He underwent a surgical revascularization in April 2022 with the use of left internal mammary artery to left anterior descendent coronary artery (LIMA-LAD), with no possibility to sew grafts in severely calcified strong obtuse marginal 2 (OM 2) and a chronically occluded right coronary artery. The patient was admitted to our

center for elective PCI of the left main and OM 2. On admission, the patient presented with stable coronary syndrome — in Canadian Cardiovascular Society scale: 2 and stable HF — in New York Heart Association scale: II. The LVEF was 22% with anterior wall akinesia and inferior wall hypokinesia. Coronary angiography revealed good LIMA-LAD graft function, with collaterals to right coronary artery and significant, calcified narrowing of the distal left main, ostial circumflex and OM 2 (Figure 1A; Supplementary material, Video S1)

The left coronary artery was engaged via femoral approach with a 45 cm armored arterial sheath and intubated with 7 Fr extra-backup 3.75 guiding catheter. A ViperWire Advance guidewire to distal part of the OM 2 was introduced. The intravascular ultrasound probe did not pass through the target lesion (Figure 1B). Coronary Orbital Atherectomy using Diamondback 360TM with Classic Crown 1.25 mm (Figure 1C, Supplementary material, Video S2) with five runs was performed without any hemodynamic, rhythm, and conduction disturbances. Intravascular ultrasonography after COA revealed calcium fractures (Figure 1D).

A pre-dilatation using non-compliant balloons, and guide extension catheter (Figure 1E), followed by two drug-eluting stents implantation yielded excellent angiographic outcome (Figure 1F; Supplementary material, Video S3). Final intravascular ultrasound imaging confirmed good apposition/expansion of implanted stents without any complications (Supplementary material, Video S4). Due to a slow flow in small OM 1 and distal circumflex artery, IIb/IIIa blocker (eptifibatide) was administered. One hour later after the procedure, an episode of ventricular fibrillation successfully defibrillated was recorded. Thereafter, no chest pain or new electrocardiogram changes were observed. The patient was discharged home eight days later.

Orbital atherectomy appears to be safe and effective in patients with HF and severely impaired LVEF.

References

1. Généreux P, Madhavan MV, Mintz GS, et al. Ischemic outcomes after coronary intervention of calcified vessels in acute coronary syndromes. Pooled analysis from the HORIZONS-AMI (Harmonizing Outcomes With Revascularization and Stents in Acute Myocardial Infarction) and ACUITY (Acute Catheterization and Urgent Intervention Triage Strategy) TRIALS. *J Am Coll Cardiol.* 2014; 63(18): 1845–1854, doi: 10.1016/j.jacc.2014.01.034, indexed in Pubmed: 24561145.
2. Généreux P, Redfors B, Witzenbichler B, et al. Two-year outcomes after percutaneous coronary intervention of calcified lesions with drug-eluting stents. *Int J Cardiol.* 2017; 231: 61–67, doi: 10.1016/j.ijcard.2016.12.150, indexed in Pubmed: 28040289.

3. Chambers JW, Feldman RL, Himmelstein SI, et al. Pivotal trial to evaluate the safety and efficacy of the orbital atherectomy system in treating de novo, severely calcified coronary lesions (ORBIT II). *JACC Cardiovasc Interv.* 2014; 7(5): 510–518, doi: 10.1016/j.jcin.2014.01.158, indexed in Pubmed: 24852804.
4. Lee MS, Shlofmitz E, Kaplan B, et al. Real-World multicenter registry of patients with severe coronary artery calcification undergoing orbital atherectomy. *J Interv Cardiol.* 2016; 29(4): 357–362, doi: 10.1111/joic.12310, indexed in Pubmed: 27358246.
5. Pawlik A, Januszek R, Rzeszutko Ł, et al. High-risk percutaneous coronary angioplasty with rotational atherectomy and left ventricular assist device of chronically occluded left ascending artery in an obese patient with very low ejection fraction. *Kardiol Pol.* 2022; 80(4): 491–492, doi: 10.33963/KP.a2022.0034, indexed in Pubmed: 35113999.

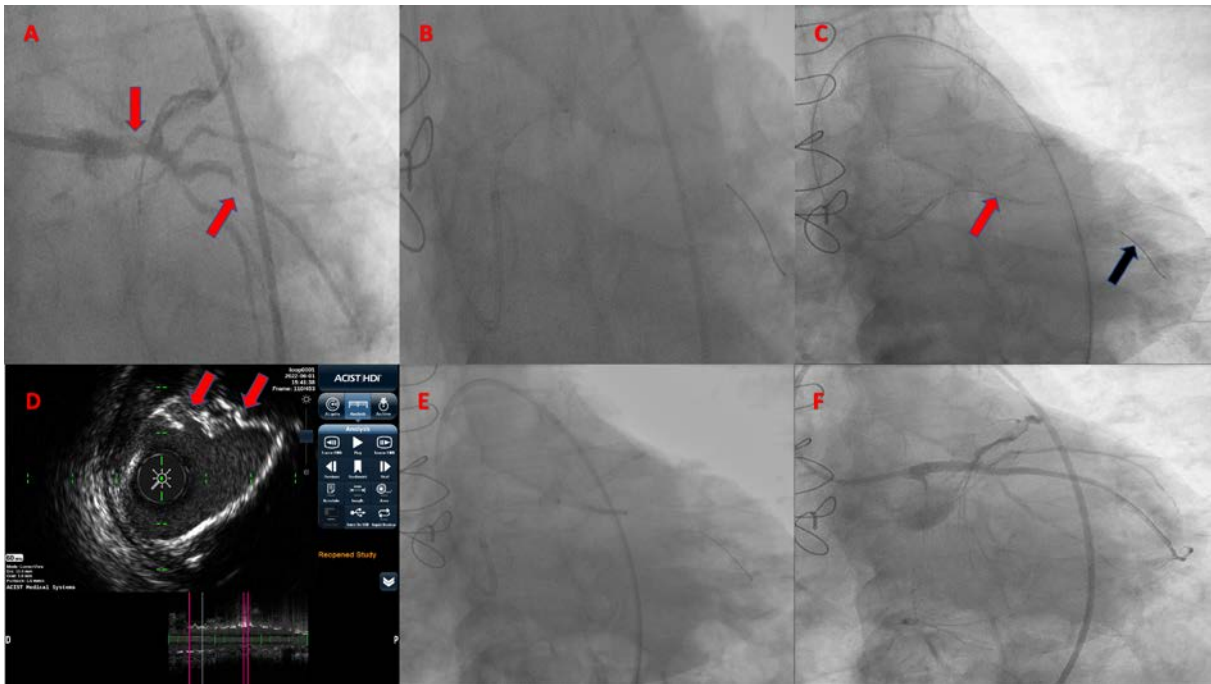


Figure 1. **A.** Initial coronary angiography with severely calcified lesions in left main and obtuse marginal 2 (red arrows); **B.** An unsuccessful attempt to pass the intravascular ultrasound probe through the lesion; **C.** Coronary Orbital Atherectomy using Diamondback 360™ with Classic Crown 1.25 mm (Cardiovascular Systems) (Corona Crown — red arrow, ViperWire Advance™ Coronary Guide Wire — black arrow); **D.** Intravascular ultrasonography using Acist High Definition Catheter after Coronary Orbital Atherectomy (calcium fractures — red arrows); **E.** Post-dilatation using non-compliant balloon and guide extension (GuideLiner V3); **F.** Final angiographic result