



Contents lists available at ScienceDirect

International Journal of Surgery

journal homepage: www.journal-surgery.net

Original research

Submental flap as an alternative to microsurgical flap in intraoral post-oncological reconstruction in the elderly

Fabrizio Schonauer^{a, *}, Annalena Di Martino^a, Gisella Nele^a, Mariangela Santoro^a, Giovanni Dell'Aversana Orabona^b, Luigi Califano^b

^a Unit of Plastic Surgery, University of Naples "Federico II", Via Pansini, 5, 80131, Naples, Italy

^b Department of Maxillofacial Surgery, University of Naples "Federico II", Via Pansini, 5, 80131, Naples, Italy

ARTICLE INFO

Article history:

Available online xxx

Keywords:

Submental flap
Intraoral reconstruction
Submental vessels
Elderly
Squamous cell carcinoma

ABSTRACT

Oral and oropharyngeal squamous cell carcinoma (Scc) occur most commonly in middle-aged and elderly individuals.

Free flaps are commonly used for reconstruction of extensive tumor resection defects in the oral cavity. Age alone is not an independent variable for increased risk in microvascular reconstruction; however operative time and ASA risk score correlated with medical complications but not with surgical complications.

The submental island flap has proven to be a reliable alternative in reconstruction of composite oral cavity defects for its thinness, pliability and versatility in design, shared by the radial forearm free flap, and its advantageous donor site. The submental flap can be easily raised and involves shorter operative time and hospital stay compared to the free-flap procedure. It can be an excellent choice in patients with a high ASA risk score, moreover in elderly patients, where the potential complications linked to microsurgical procedures are avoided.

© 2016 IJS Publishing Group Ltd. Published by Elsevier Ltd. All rights reserved.

1. Introduction

Oral and oropharyngeal squamous cell carcinoma (Scc) represents the sixth most common cancer worldwide and occurs most commonly in middle-aged and elderly individuals [1]. This tumor may affect the mucosa of the floor of the mouth, cheek, tongue and inner lip surface, with the tongue being the most common oral site [2].

Surgery is the main method of managing oral cavity cancer [3]. The excision entails removal of the tumor with a margin of at least 1–1.5 cm. Simultaneously neck dissection is performed for clinically evident nodal disease, for large primary tumors or for tumors with a depth of invasion greater than 4 mm [3].

Free flaps are commonly used for reconstruction of extensive tumor resection defects in the oral cavity [4]. The radial forearm flap is the most frequent reconstructive technique. Free tissue

transfer is nowadays more often performed in the elderly with the increase in geriatric patient population compared to the past [5]. Age alone is not an independent variable for increased risk in microvascular reconstruction; however operative time and ASA risk score correlated with medical complications but not with surgical complications [6].

Pedicled flaps have a vital role in reconstruction of medium to large sized defect of oral cavity [7] [8].

Over the last few years, the submental island flap has proven to be a reliable reconstructive option in head and neck surgery [9]. Moreover, the operative time and hospital stay are shorter than using the gold standard radial forearm free flap [10].

The purpose of this paper is to present a series of 12 patients, aged over 64, affected by intra-oral Scc in whom reconstruction has been performed with submental flap. Surgical technique with its advantages and disadvantages are discussed.

2. Patients and methods

A total of 12 patients, 8 males and 4 females, with intra-oral Scc (Fig. 1) were treated by the Maxillo Facial Surgery Unit in collaboration with the Plastic Surgery Unit from January 2014 to December

* Corresponding author.

E-mail addresses: fschona@libero.it (F. Schonauer), annalena.dimartino@gmail.com (A. Di Martino), gisenele@gmail.com (G. Nele), mariangela_santoro@msn.com (M. Santoro), gdoorabon@yahoo.it (G. Dell'Aversana Orabona), califano@unina.it (L. Califano).

2014. The patients' age ranged from 64 to 82 years. This patient population was part of a series of 41 patients operated for intraoral tumor excision and reconstruction with a two teams approach (Maxillo Facial Surgery team for resection and Plastic Surgery team for reconstruction).

Primary sites involved the floor of the mouth, the buccal mucosa, and a portion of the tongue.

All patients underwent one-stage procedure for tumor resection, neck lymph node dissection and reconstruction with ortho-grade submental island flap (Figs. 1–6).

3. Surgical technique

A pinch test was performed to delineate the maximum width of the flap. An elliptical island was designed in the submental area (Fig. 7). The upper incision was made 1.5 cm below the mandible at

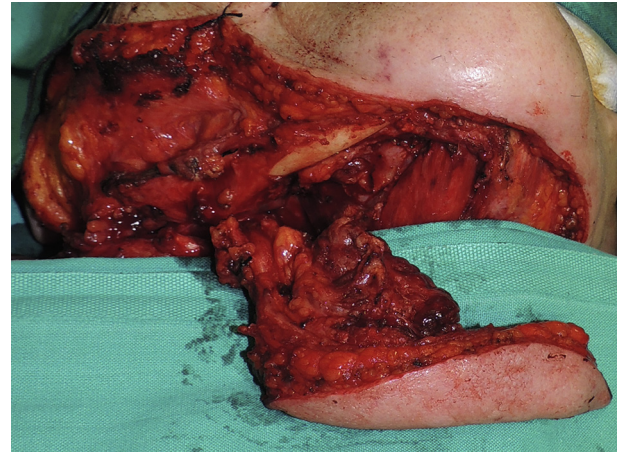


Fig. 3. Right pedicled submental flap.

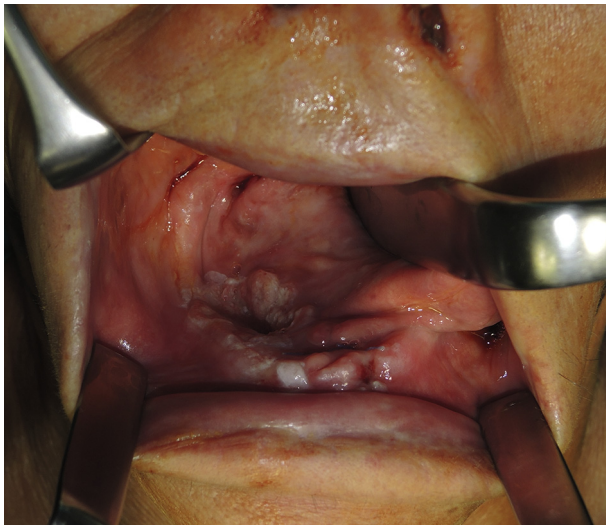


Fig. 1. Scc of the right portion of the tongue.

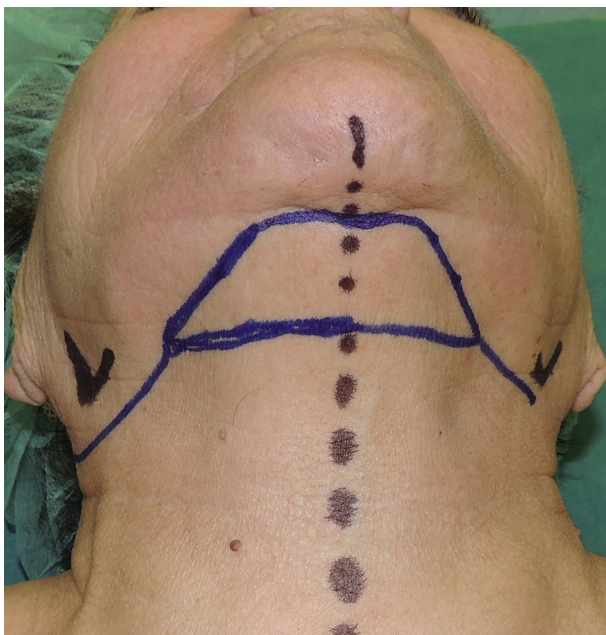


Fig. 2. Pre-operative planning.

the midline and 3.5 cm below the angles of the mandible bilaterally. The length of the ellipse was outlined related to the expected size of the defect and to accommodate unilateral or bilateral neck dissection. Hence the dissection of the neck started, taking care to preserve both the facial artery and vein on that side (Fig. 8). The vascular tributaries to the submandibular gland were ligated as close as possible to the gland and dissected away from it, preserving the submental vessels. In case bilateral neck dissection was needed, the flap was harvested on the less involved side of the neck.

Flap dissection began from the contralateral side of the pedicle, in the subplatysmal plane. On the opposite side, the anterior belly of the ipsilateral digastric muscle was sectioned from its common tendon and it was elevated with the skin paddle. The mandible insertion of the anterior belly of the digastric muscle was then sectioned. Occasionally a strip of the mylohyoid muscle was included in the flap.

The flap was always moved toward the oral cavity passing medially to the mandible either if the defect involved the floor of the mouth, the base of the tongue, the tonsillar fossa, the retro-molar trigone or the buccal mucosa. Lastly the flap was inset and sutured in place (Fig. 9) and neck drains were placed.

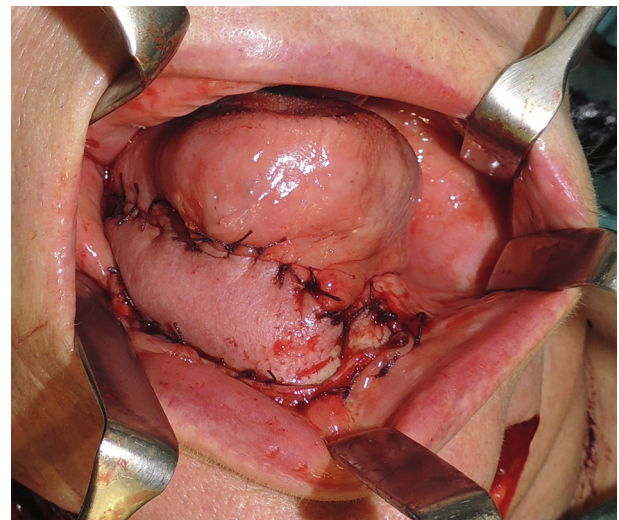


Fig. 4. Submental flap inseting at the right side of the tongue, to correct post-oncological resection.

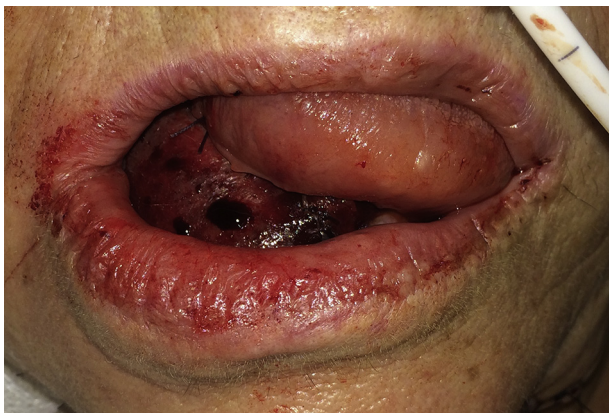

Fig. 5. 2nd post-operative day: venous congestion of the flap; it spontaneously solved.

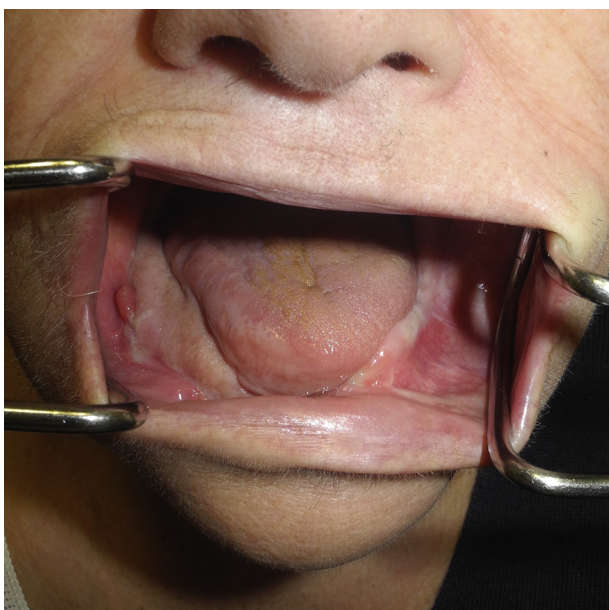

Fig. 6. At 6 month follow-up the patient was happy with the result.

4. Results

Patients' ASA risk score ranged from 2 to 4.

All patients underwent one-stage surgical resection, neck lymph node dissection and immediate reconstruction with the orthograde submental flap. Primary sites involved the floor of mouth in 4 patients, the floor of the mouth and the right inferior alveolar crease in 1 patient, the buccal mucosa in 3 patients, the tongue in 3 patients (in 2 of them was involved the right portion of the tongue and in 1 the left portion of it) and the anterior portion of the floor of mouth and the base of the tongue in 1 patient. The width of the defects ranged from 2.6 cm to 6.4 cm, the length from 1.9 cm to 4.1 cm.

Neck dissection was bilateral in 8 patients, unilateral right in 3 patients and unilateral left in 1 patient.

The flap width ranged between 3.7 cm and 5.1 cm. In all the patients reconstruction was performed with orthograde submental island flap, with left pedicle in 7 patients and right pedicle in the remaining 5. In 4 patients the flap pedicle was contralateral (left submental artery) to the primary tumor site, in 3 of whom the pedicle was even contralateral to the neck dissection and in 1

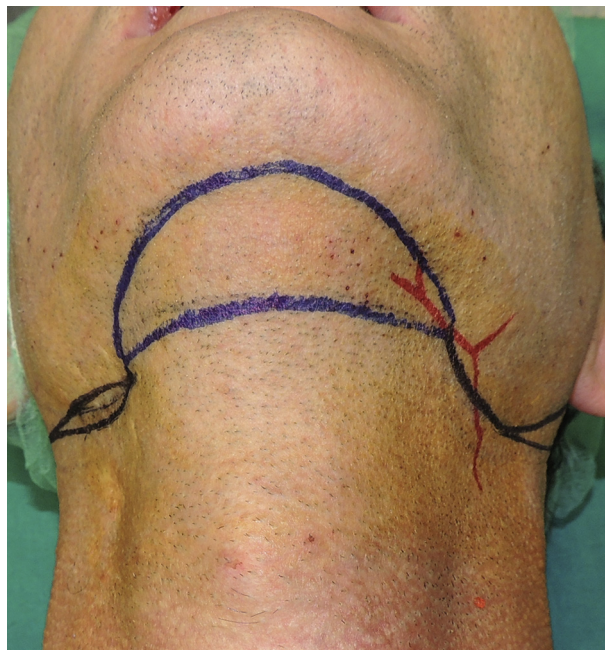

Fig. 7. Flap design in the submental area, 1.5 cm below the mandible on the midline and 3.5 cm below the angles of the mandible laterally.

patient was omolateral to it. In 8 patients the tumor extension was across the midline, neck dissection was bilateral and the flap was just harvested on the less involved side of the neck (5 on the right submental artery and 3 on the left one).

The average operative time for resection, neck dissection and reconstruction was 3 h and 12 min. Post-operative hospital stay

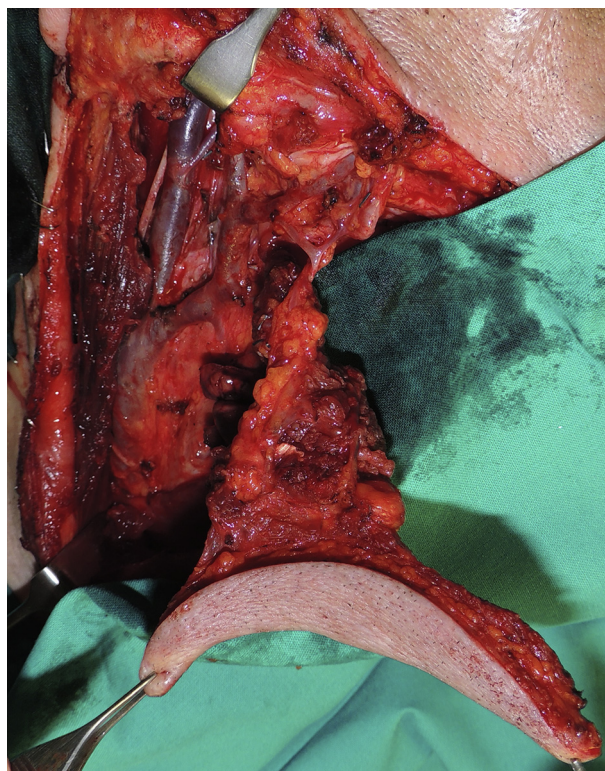


Fig. 8. A right submental flap pedicle and vascular anatomy of the neck.

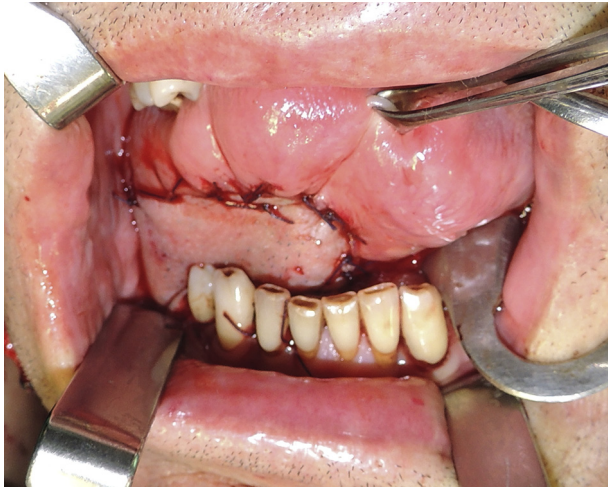

Fig. 9. Submental flap sutured in place at the right portion of the tongue.

ranged from 3 to 12 days.

The flaps were successful in all patients. Venous congestion was observed in 2 patients and it spontaneously solved. Superficial necrosis was observed in one patient but the flap recovered gradually. One patient experienced neck hematoma, which was subsequently drained in the theatre. No patients developed a total flap loss nor infections. No medical complication occurred.

In all patients histology showed infiltrating squamous cell carcinoma: in 11 of them SCCs were well differentiated (G1-G2), in one patient it presented warty appearance. Absence of metastatic cells in cervical lymph nodes was observed in all patients: 7 patients were staged T3N0M0 and 5 T2N0M0.

At 1 month follow-up the flap was successful in all patients. At 6 months in all patient was observed absence of recurrence; 4 patients complained of hair growth in the oral cavity.

5. Discussion

The submental island flap was first reported in 1993 by Martin et al. for soft-tissue head and neck reconstruction [11]. It is based on the submental artery, a constant branch of the facial artery, which originates 27.5 mm distal from the origin of facial artery from the external carotid artery. This artery has five main branches along its course toward the midline and anastomoses in 92% of cases with contralateral artery [12]. It is located medially to the mandibular inferior border [13] and represents the main blood supply of the floor of the mouth in 60% of cases [14].

The submental artery island flap could be classified according to blood supply, as pedicled flap, free flap or perforator flap and according to the composition of the flap paddle, as myocutaneous or osteocutaneous flap [15]. The submental pedicled flap can be pedicled inferiorly, i.e. orthograde variant, which depends on facial artery integrity, or superiorly, i.e. reverse flow variant, which relies on anastomosis between the external and the internal carotid arteries via the angular artery [16]. A pedicled submental flap with orthograde blood supply is used for reconstruction of the retro-molar pad, the tongue, the floor of mouth and buccal mucosa. The major mobility of the retrograde variant allows reconstruction of the palate and the maxillary alveolar ridge, such as facial skin in midface, the periorbital area, the inferior temple area, auricle and oropharynx [15]. The myocutaneous flap can have the same thickness in the distal half (thin flap) or may include the anterior belly of the digastric and the mylohyoid muscles (thick flap), increasing the

blood supply to the flap [15].

The submental island pedicled myocutaneous flap has a wide arc of rotation, a constant axial vessel, appropriate pedicle length, large skin paddle and wide pivotal movement [17]. It is mainly used for reconstruction of oral cavity defects after cancer surgery, particularly after Scc ablation [3].

There has been some concerns in the literature about the oncological safety of this flap. Harvesting this flap in the management of intraoral Sccs could transfer metastatic tissue to the recipient area or leading to cancer recurrence in the flap base. Chow et al. recommended that dissection in the subplatysmal plane would minimize the chances of tumor spread and inadequate clearance [18]. Amin et al. prescribed the complete lymph node dissection before flap harvesting and recommend that this flap should be avoided in those patients with clinically advanced nodal disease in the neck (>N0) [3]. The use of this flap is contraindicated in patients with metastasis and in patients with a history of neck dissection, because for the success of this technique the integrity of the facial artery/vein is necessary [19]. Ultrasound colour Doppler with facial artery/vein and skin perforators localization dramatically reduce the failure rate [20].

Free flaps have been the primary option for post-oncological reconstruction of tissue defects in oral cancer patients because this tissue transfer provides an adequate donor tissue volume and adequate blood supply for most cases [21,22]. This free flap technique is not recommended in patients with vessel-depleted irradiated neck and in patients with a high ASA risk score. Operative surgery time is longer compared with the submental flap and consequently hospital stay, costs and medical post-operative complications are superior [6,10,23].

The use of pedicled myocutaneous flaps, such as the pectoralis major flap, is another classic surgical option, characterized by technical simplicity and good blood supply [24,25]. The disadvantages of these flaps are bulky volume, requirement of secondary revisional surgeries and a higher rate of complications especially in female patients [26,27].

Among these flaps, the submental artery flap showed many potential advantages. It is an ideal flap for soft-tissue head and neck reconstruction for its thinness, pliability and versatility in design shared by the radial forearm free flap. It also presents an excellent colour match for the head and neck region and it can be easily raised [11,28].

It can be an excellent choice in patients with limited physiologic reserve in which operative trauma and delayed postoperative recovery are the most complicated issues. Moreover, in elderly patients, this flap avoids the potential complications linked to microsurgical procedures [11,25] and, reducing the submental fullness, has a satisfactory donor result [29].

Possible complications of submental flap include facial palsy, in the range of 0–17%, caused by the damage to the facial nerve during surgery [30] and the damage to the marginal mandibular nerve [20]. This damage to the marginal mandibular nerve is greatly lessened by the supraplatysmal dissection [31]. The use of nerve stimulators associated to a careful dissection decreases the possibility of damage to these nerves preventing the innervations of the supplied muscles [32–34].

In some individuals with very hairy neck skin, the hair bearing nature of this flap causes inconvenience for intraoral reconstructions. This problem has been managed using different techniques, such as laser ablation, second operations, mechanical depilation and electrolysis [35,36]. A deepithelialised variant of the submental flap was introduced to solve this problem in intraoral, oropharyngeal and laryngeal reconstruction in male patients [37,38].

6. Conclusion

The submental artery flap is a valid option for reconstruction of composite oral cavity defects. It represents an excellent alternative to free flaps, particularly in elderly patients or in high-ASA risk patients where the reduced operative time and the easily concealable donor-site incision make it a really neat solution.

Funding

All Authors have no source of funding.

Ethical approval

Ethical approval was requested and obtained from the “Azienda Universitaria Federico II” ethical committee.

Author contribution

Please specify the contribution of each author to the paper, e.g. study design, data collections, data analysis and writing.

Fabrizio Schonauer: Participated substantially in conception, design, and execution of the study and in the analysis and interpretation of data; also participated substantially in the drafting and editing of the manuscript.

Annalena Di Martino: Participated substantially in conception, design, and execution of the study and in the analysis and interpretation of data.

Gisella Nele: Participated substantially in conception, design, and execution of the study and in the analysis and interpretation of data.

Mariangela Santoro: Participated substantially in conception, design, and execution of the study and in the analysis and interpretation of data.

Giovanni Dell'Aversana Orabona: Participated substantially in conception, design, and execution of the study and in the analysis and interpretation of data.

Luigi Califano: Participated substantially in conception, design, and execution of the study and in the analysis and interpretation of data; also participated substantially in the drafting and editing of the manuscript.

Conflicts of interest

All Authors have no conflict of interests.

Guarantor

Prof Fabrizio Schönauer.

References

- [1] A. Jemal, R. Siegel, E. Ward, et al., Cancer statistics, 2006, *CA Cancer J. Clin.* 56 (2) (2006) 106–130.
- [2] M.J. Veness, G.J. Morgan, Y. Sathiyaseelan, V. Gebiski, Anterior tongue cancer and the incidence of cervical lymph node metastases with increasing tumour thickness: should elective treatment to the neck be standard practice in all patients, *ANZ J. Surg.* 75 (2005) 101–105.
- [3] A.A. Amin, M.A. Sakkary, A.A. Khalil, M.A. Rifaat, S.B. Zayed, The submental flap for oral cavity reconstruction: extended indications and technical refinements, *Head. Neck Oncol.* 3 (2011 Dec 20) 51.
- [4] F. Schonauer, S. Marlino, F. Turrà, P. Graziano, G. Dell'Aversana Orabona, Superficial ulnar artery perforator flap, *J. Craniofac Surg.* 25 (5) (2014).
- [5] F. Turrà, S. La Padula, S. Razzano, P. Bonavolontà, G. Nele, S. Marlino, L. Canta, P. Graziano, G. Dell'Aversana Orabona, F. Schonauer, Microvascular free-flap transfer for head and neck reconstruction in elderly patients, *BMC Surg.* 13 (Suppl 2) (2013) S27.
- [6] M.R. Kesting, F. Hölzle, C. Wales, L. Steinstraesser, S. Wagenpfeil, T. Mücke, N.H. Rohleder, K.D. Wolff, R.J. Hasler, Microsurgical reconstruction of the oral cavity with free flaps from the anterolateral thigh and the radial forearm: a comparison of perioperative data from 161 cases, *Ann. Surg. Oncol.* 18 (7) (2011 Jul) 1988–1994.
- [7] R. Squaquara, K.F. Kim Evans, S. Spanio di Spilimbergo, S. Mardini, Intraoral reconstruction using local and regional flaps, *Semin. Plast. Surg.* 24 (2010) 198–211.
- [8] P. Tosco, P. Garzino-Demo, G. Ramieri, G. Tanteri, G. Pecorari, C. Caldarelli, et al., The platysma myocutaneous flap (PMF) for head and neck reconstruction: a retrospective and multicentric analysis of 91 T1–T2 patients, *J. Craniofac Surg.* 40 (2012) e415–418.
- [9] P. Sebastian, S. Thomas, B.T. Varghese, E.M. Iype, P.G. Balagopal, P.C. Mathew, The submental island flap for reconstruction of intraoral defects in oral cancer patients, *Oral Oncol.* 44 (11) (2008) 1014–1018.
- [10] J.A. Paydarfar, U.A. Patel, Submental island pedicled flap vs radial forearm free flap for oral reconstruction, *Arch. Otolaryngol. Head. Neck Surg.* 137 (2011) 82–87.
- [11] D. Martin, J.F. Pascal, J. Baudet, J.M. Mondie, J.B. Farhat, A. Athoum, P. Le Gaillard, G. Peri, The submental island flap: a new donor site. Anatomy and clinical applications as a free or pedicled flap, *Plast. Reconstr. Surg.* 92 (5) (1993 Oct) 867–873.
- [12] O. Magden, M. Edizer, V. Tayfur, A. Atabey, Anatomic study of the vasculature of the submental artery flap, *Plast. Reconstr. Surg.* 114 (2004) 1719–1723.
- [13] D.H. Kim, S.Y. Won, D.Y. Choi, H.S. Kim, U.W. Jung, H.J. Kim, et al., Topography of the submental artery that should be considered in bleeding during dentoalveolar surgery, *J. Craniofac Surg.* 23 (2012) 1453e1456.
- [14] J.B. Bavitz, S.D. Harn, E.J. Homze, Arterial supply to the floor of the mouth and lingual gingiva, *Oral Surg. Oral Med. Oral Pathol.* 77 (1994) 232e235.
- [15] A. Rahpeyma, S. Khajehahmadi, Submental artery island flap in intraoral reconstruction: a review, *J. Cranio-Maxillo-Facial Surg.* 42 (2014) 983–989.
- [16] W.L. Chen, M. Zhou, J.T. Ye, Z.H. Yang, D.M. Zhang, Maxillary functional reconstruction using a reverse facial artery-submental artery mandibular osteomuscular flap with dental implants, *J. Oral Maxillofac. Surg.* 69 (2011) 2909–2914.
- [17] O. Tan, A.F. Kiroglu, B. Atik, K. Yuca, Reconstruction of the columella using the prefabricated reverse flow submental flap: a case report, *Head. Neck* 28 (7) (2006 Jul) 653–657.
- [18] T.L. Chow, T.T. Chan, T.K. Chow, S.C. Fung, S.H. Lam, Reconstruction with submental flap for aggressive orofacial cancer, *Plast. Reconstr. Surg.* 120 (2007) 431e436.
- [19] B. Jiang, Y. Gu, W. Chen, Submental island flaps for reconstruction of hypopharyngeal non-circumferential defects after hypopharyngeal carcinoma removal, *Zhongguo Xiu Fu Chong Jian Wai Ke Za Zhi* 20 (2006) 1183e1185.
- [20] M. Yamauchi, T. Yotsuyanagi, K. Ezoe, T. Saito, K. Ikeda, K. Arai, Reverse facial artery flap from the submental region, *J. Plast. Reconstr. Aesthet. Surg.* 63 (2010) 583e588.
- [21] C. Cinar, S. Ogur, H. Arslan, A. Kilic, Adding versatility to the reconstruction of intraoral lining: opened pocket method, *J. Craniofac Surg.* 18 (1) (2007) 198–202.
- [22] V. Valentini, A. Saltarel, A. Cassoni, A. Battisti, S. Egidi, One-stage reconstruction of a defect of the oral commissure and of the cheek with a radial forearm free flap, *J. Craniofac Surg.* 19 (6) (2008) 1508–1511.
- [23] U.A. Patel, S.W. Bayles, R.E. Hayden, The submental flap: a modified technique resident training, *Laryngoscope* 117 (2007) 186–189.
- [24] K.T. Chavan, B.P. Reddy, R. Desai, S. Manjunath, S. Shubhalakshmi, K.V. Umashankar, Versatility of pectoralis major myocutaneous flap, *Int. J. Oral Maxillofac. Surg.* 36 (11) (2007) 1055.
- [25] J.N. McLean, G.W. Carlson, A. Losken, The pectoralis major myocutaneous flap revisited: a reliable technique for head and neck reconstruction, *Ann. Plast. Surg.* 64 (5) (2010) 570–573.
- [26] A.L. Mehrhof, A. Rosenstock, J.P. Neifeld, W.H. Merritt, S.D. Theogaraj, I.K. Cohen, The pectoralis major myocutaneous flap in head and neck reconstruction: an analysis of complications, *Am. J. Surg.* 146 (1983) 478.
- [27] H.H. El-Marakby, The reliability of pectoralis major myocutaneous flap in head and neck reconstruction, *J. Egypt Natl. Canc. Inst.* 18 (1) (2006) 41–50.
- [28] B.T. Varghese, Optimal design of a submental artery island flap, *J. Plast. Reconstr. Aesthet. Surg.* 64 (2011) e183e184.
- [29] P. Pelissier, V. Casoli, D. Martin, E. Demiri, J. Baudet, Submental island flaps. Surgical technique and possible variations in facial reconstruction, *Rev. Laryngol. Otol. Rhinol. Bord.* 118 (1997) 39e42.
- [30] Sarah R MD, James N MD: Submental Myocutaneous Flap Reconstruction for Oral Defect (Poster Presentation).
- [31] R.Y. Kannan, Supraplatysmal submental artery perforator flap: minimizing risk to the marginal mandibular nerve, *Ann. Plast. Surg.* 72 (2014) 131.
- [32] M. Yilmaz, A. Menderes, A. Barutcu, Submental artery island flap for reconstruction of the lower and mid face, *Ann. Plast. Surg.* 39 (1997) 30–35.
- [33] A.H. Taghnia, K.D. Movassaghi, A.X. Wang, J.J. Pribaz, Reconstruction of the upper aerodigestive tract with the submental artery flap, *Plast. Reconstr. Surg.* 123 (2) (2009) 562–570.
- [34] A. Abouchadi, N. Capon-Degardin, P. Paten'Otre, et al., The submental flap in facial reconstruction: advantages and limitations, *J. Oral Maxillofac. Surg.* 65 (2007) 863–869.
- [35] F.J. Conroy, P.J. Mahaffey, Intraoral flap depilation using the long-pulsed alexandrite laser, *J. Plast. Reconstr. Aesthet. Surg.* 62 (11) (2009 Nov) e421–e423.
- [36] R.R. Hall, D.J. Pearce, T. Brown, A.J. McMichael, Unwanted palatal hair: a

- consequence of complex oropharyngeal reconstruction, *J. Dermatol. Treat.* 20 (3) (2009) 149–151.
- [37] E. Vural, J.Y. Suen, The submental island flap in head and neck reconstruction, *Head. Neck* 22 (2000) 572e578.
- [38] J.C. Lee, Y.H. Chu, Y.S. Lin, C.H. Kao, Reconstruction of hypopharyngeal defects with submental flap after laryngopharyngectomy, *Eur. Arch. Otorhinolaryngol.* 270 (2013) 319e323.