

## Scientific Article

# A Retrospective Analysis of 287 Patients Undergoing Prophylactic Radiation Therapy for the Prevention of Heterotopic Ossification



Samantha L. Freije, MD,<sup>a</sup> Michael V. Kushdilian, MD,<sup>b</sup> Heather N. Burney, MS,<sup>c</sup> Yong Zang, PhD,<sup>c</sup> and Naoyuki G. Saito, MD, PhD<sup>a,\*</sup>

Departments of <sup>a</sup>Radiation Oncology, <sup>b</sup>Radiology, and <sup>c</sup>Biostatistics, Indiana University School of Medicine, Indianapolis, Indiana

Received 15 October 2020; revised 30 October 2020; accepted 11 November 2020

## Abstract

**Purpose:** Heterotopic ossification (HO) is a potentially disabling disorder of ectopic bone formation secondary to orthopedic surgery or trauma. In this retrospective analysis we evaluated the outcomes of patients who received radiation therapy (RT) for HO prophylaxis.

**Methods and Materials:** A total of 287 patients who received RT for HO prophylaxis at a major trauma center from 2007 to 2018 were analyzed. Data collected included types of injury, surgery, time intervals between key events, development of postprophylaxis HO, and secondary malignancies. Associations between various factors and the risk of developing HO were analyzed. Kaplan-Meier analysis was used to estimate failure rates.

**Results:** The most common indication for RT was traumatic acetabular fracture (83.3%). Twelve patients (4.2%) developed post-prophylaxis HO with a median time to failure of 8.6 months (2.8-24.5). Kaplan-Meier 1-, 2-, and 5-year failure rates were 3.7%, 4.4%, and 7.4%, respectively. Injury type and timing of RT were not associated with the risk of failure, but we observed a trend of increased risk of failure in patients with longer time between surgery and RT (odd ration [OR] 1.68,  $P = .056$ ). Current or former smokers (51.7%) were less likely to fail (OR 0.10,  $P = .03$ ). There was no incidence of in-field secondary malignancy.

**Conclusions:** There was no significant association between injury and fracture type, surgical approach, or timing of RT and development of HO, contrary to published reports of increased HO risk with certain surgical approaches and longer time intervals between injury and surgery, suggesting that prophylactic RT might play a role in mitigating these effects. Decreased risk of postprophylaxis HO among former or current smokers was unexpected. No secondary malignancy in the RT field was identified, although the median follow-up was only 17 months. Compared with published HO incidences (17%-39%) in patients who receive no prophylaxis after traumatic acetabular fractures, our results are highly suggestive of the efficacy of prophylactic RT.

© 2020 The Authors. Published by Elsevier Inc. on behalf of American Society for Radiation Oncology. This is an open access article under the CC BY-NC-ND license (<http://creativecommons.org/licenses/by-nc-nd/4.0/>).

## Introduction

Heterotopic ossification (HO) is a benign disorder characterized by ectopic bone formation in soft tissues usually secondary to orthopedic trauma or surgery. Common sites of HO include large joints such as the hip, elbow, and knee, especially after open reduction and internal fixation for traumatic injuries. The extent of HO in the hip joint is graded 1 to 4 by Brooker classification.<sup>1</sup>

Sources of support: This work had no specific funding.

Disclosures: none.

Research data are stored in an institutional repository and will be shared upon request to the corresponding author.

\* Corresponding author. Naoyuki G Saito, MD, PhD; E-mail: [nsaito@iuhealth.org](mailto:nsaito@iuhealth.org)

<https://doi.org/10.1016/j.adro.2020.11.010>

2452-1094/© 2020 The Authors. Published by Elsevier Inc. on behalf of American Society for Radiation Oncology. This is an open access article under the CC BY-NC-ND license (<http://creativecommons.org/licenses/by-nc-nd/4.0/>).

Grade 1 is defined as bony islands within the soft tissue. Grade 2 is defined as bony spurs growing from bony surfaces but with at least 1 cm of space between opposing ends. Grade 3 is defined as bony spurs with less than 1 cm of space between opposing ends. Grade 4 is defined as complete bridging ossification between ectopic bony spurs causing joint ankylosis. Milder cases of HO, or those with grades 1 and 2, are typically asymptomatic and detected only incidentally, usually on radiographs. On the other hand, clinically relevant grades 3 to 4 can result in greatly restricted joint movement, which often leads to profound disability secondary to ankylosis.<sup>2</sup> The incidence of HO development after open reduction and internal fixation for traumatic acetabular fracture without any method of prophylaxis has been reported to be between 17% to 39%.<sup>3,4</sup>

Nonsteroidal antiinflammatory drug (NSAID) therapy and radiation therapy (RT) are 2 commonly used methods of HO prophylaxis. NSAID therapy is typically achieved with 2 to 6 weeks of 75 mg daily indomethacin,<sup>5,6</sup> whereas RT is usually administered in a single dose (typically 7-8 Gy) to the surgical site, typically within 3 days of surgery.<sup>7</sup> Although it is cost effective and widely available, the use of NSAIDs for this indication also comes with disadvantages, including the decreased likelihood of patient compliance, risks of gastrointestinal side effects (reflux, dyspepsia, and peptic ulcer disease), risk of bleeding complications, risks of long-bone nonunion, and risks of nephrotoxicity. On the other hand, RT also carries its own disadvantages including a concern for secondary malignancies in the RT field,<sup>8,9</sup> and increased risk of fracture nonunion.<sup>10-13</sup>

To our knowledge, outcomes of those who undergo RT for HO prophylaxis have not been studied in particularly large patient cohorts. Therefore, currently available published guidelines regarding the appropriate use of RT for HO prophylaxis are based on a few small studies.<sup>13-17</sup> The patients in this series were seen at a level one trauma center covering a large geographic area, with a long history of administering prophylactic RT for the prevention of HO after orthopedic trauma surgery. Here we report on a retrospective analysis of patients deemed at high risk of HO who received prophylactic RT in our institution. Primarily, we sought to determine the proportion of patients who failed therapy (ie, went on to develop HO after prophylactic RT) and which injury or treatment-specific factors were associated with failure. Secondarily, we wanted to identify the acute and chronic complications occurring from RT prophylaxis. We also sought to identify any in-field secondary malignancies in this cohort.

## Methods and Materials

This retrospective analysis was granted institutional review board protocol exemption by the academic

institution. A total of 302 consecutive patients who, between 2007 and 2018, received prophylactic RT for the prevention of HO after orthopedic surgery in our institution were identified. Individual review of both electronic medical records, both general and radiation therapy, was conducted to collect demographic data, type of injury, type of orthopedic surgery, surgical approach, dates of injury, surgery, and RT, time intervals between these key events, timing and dose of RT, incidence of any acute or chronic complications, incidence of any cancer diagnosis after RT, and development and severity of HO. For the purpose of this analysis, acute complications were defined as any complication at site of surgery within and up to 3 months after RT. Chronic complications were defined as any complication at site of surgery greater than 3 months after RT. HO severity was graded per Brooker criteria.<sup>1</sup> It is important to note that Brooker criteria was developed specifically for grading HO in the hip; we applied the basic definition of the Brooker grading to other (elbow, shoulder, and knee) joints as well since, to the best of our knowledge there is no widely accepted grading system for joints other than the hip. Relevant radiographs were examined by a diagnostic radiologist who assigned Brooker grading to each patient.

A total of 15 patients were discovered to have taken NSAIDs (in all cases indomethacin) simultaneously at time of RT and were thus excluded for this analysis. This resulted in a final analytical cohort of 287 patients. Logistic regression models were used to determine the associations between patient demographic factors and time intervals between key events and the risk of developing postprophylaxis HO.  $\chi^2$  tests were used to determine the associations between fracture type and the risk of acute and chronic complications. All other associations were tested using Fisher exact test and included the associations between fracture type, accident type, surgical approach, time intervals, and timing of RT with development and severity of HO. Kaplan-Meier analysis was used to estimate 1-, 2-, and 5-year failure rates of prophylactic RT in prevention of HO.

Follow-up was defined as any office visit within our hospital system (up until 2018 when data gathering took place) from which information about their treatment could be gleaned, namely Radiation Oncology, Orthopedic Surgery, primary care visits, or the availability of diagnostic imaging. All cases were additionally evaluated for the availability of any non-HO related Medical or Radiation Oncology documentation; if present, these were assessed to determine whether any diagnosed malignancy was found in the radiation field.

## Results

The majority (64.8%,  $n = 186$ ) of patients were male and median age was 42 years (range, 15-79 years). Median

**Table 1** Patient demographics

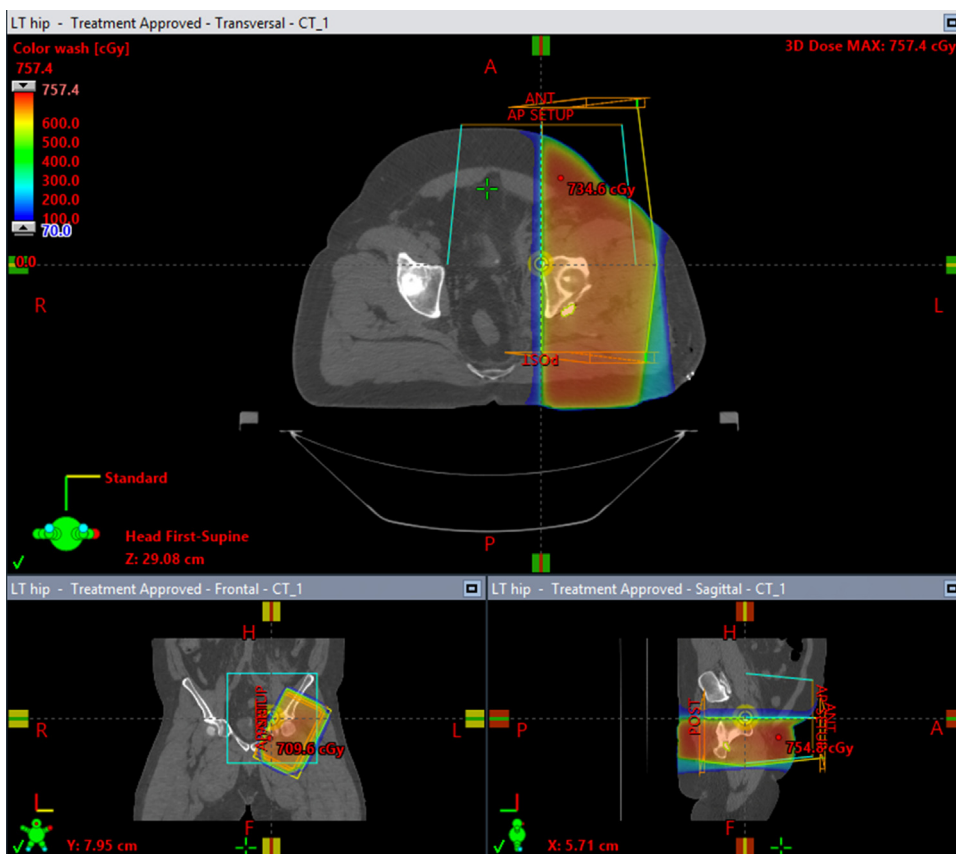	No. of patients (% of total cohort)
Age	Range, 15-79 y Median, 42 y
Follow-up time	Range, 0-133 mo Median, 17.2 mo
Sex	
Female	101 (35.2%)
Male	186 (64.8%)
Smoking status	
Never smoker	130 (45.3%)
Current or former smoker	139 (48.4%)
Unknown	18 (6.3%)

Patient demographics showing median age and follow-up time as well as sex and smoking status.

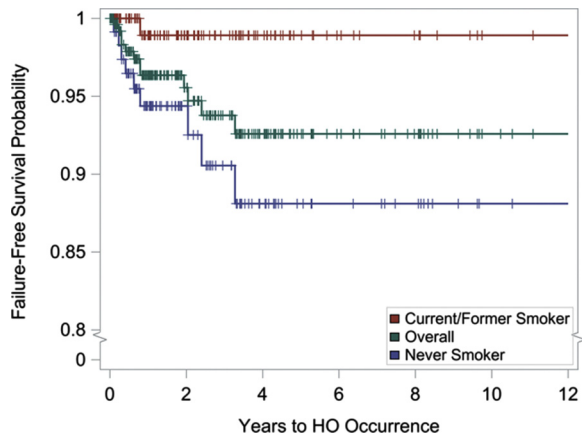
follow-up was 17 months (range, 0-133 months). Just less than half of all patients (48.4%, n = 139) were documented to be current or former smokers at time of RT

(Table 1). The most common (83.3%, n = 239) injury was traumatic acetabular fracture requiring surgical open reduction and internal fixation of the acetabulum, most often due to motor vehicle accident. Other orthopedic surgeries leading to prophylactic RT included excision of existing HO (8.0%, n = 23), femoroplasty (3.8%, n = 11), open reduction and internal fixation of the elbow or proximal humeral fracture (2.4%, n = 7), and total hip arthroplasty (1.4%, n = 4; Table E1). Of patients undergoing open reduction and internal fixation of the acetabulum, the most commonly fractured parts of the acetabulum were the posterior wall (41.8%) and the transverse posterior wall (33.8%), and the most common surgical approach was a posterior Kocher-Langenbeck approach (91.6%; Table E2).

All patients underwent CT simulation in supine position with legs slightly frog-legged before radiation therapy. Virtually all patients received 7 Gy prescribed to midplane in a single fraction, with the exception of one patient who received 8 Gy. Treatments were delivered with opposing AP and PA 6 MV or 18 MV photon beams. An example of a typical treatment plan is shown in Figure 1.



**Figure 1** Sample radiation treatment plan. An example of a radiation treatment plan for a patient who received prophylactic radiation therapy after open reduction and internal fixation of the acetabulum following motor vehicle accident.



**Figure 2** A Kaplan-Meier curve showing failure-free survival probability. Current and former smokers (red) were less likely to fail while never smokers (blue) were more likely fail (ie, develop postprophylaxis HO). Abbreviation: HO = heterotopic ossification. (A color version of this figure is available at <https://doi.org/10.1016/j.adro.2020.11.010>.)

The majority of patients (96.2%,  $n = 276$ ) received RT postoperatively (range, 0-6 days postop) with just 11 patients (3.8%) receiving RT preoperatively (<48 hours before surgery). The most common site of RT was the hip (93.7%,  $n = 269$ ) followed by the elbow (4.2%,  $n = 12$ ). Median time intervals from injury to surgery, surgery to RT, and injury to RT were 2 days (range, 0-31), 1 day (range, -2 to 6), and 3 days (range, 0-32), respectively. Only 4 patients (1.4%) had a time interval between surgery and RT longer than 3 days (Table 2).

**Table 2** Sites and time intervals between key events of prophylactic radiation therapy (RT) for the prevention of heterotopic ossification

	No. of patients (% of total cohort)
Site	
Hip	269 (93.7%)
Elbow	12 (4.2%)
Forearm	2 (0.7%)
Shoulder	2 (0.7%)
Knee	1 (0.3%)
Wrist	1 (0.3%)
Time interval between key events	
Injury to surgery	Range, 0-31 d Median, 2 d
Surgery to RT	Range, -2-6 d Median, 1 d
Injury to RT	Range, 0-32 d Median, 3 d

Abbreviations: RT = radiation therapy.

The most common site of RT was the hip. The median time from surgery to RT was 1 day.

A total of 74 patients (25.7%) experienced acute or chronic complications (Table 3). Acute complications were seen in 29 patients (10.1%). Chronic complications were seen in 58 patients (20.2%). Both complications were seen in 12 patients (4.2%). Complications included infection, posttraumatic osteoarthritis, surgical failure (nonunion, fracture, wound dehiscence), and nerve deficits. Although there was no statistically significant association between fracture type and acute complications, there was a significant association between fracture type and chronic complications ( $P = .0230$ ; Table E3).

We did not observe any convincing case of radiation-induced secondary malignancies. However, 2 patients received a diagnosis of cancer after RT. One male, at age 62, received a diagnosis of stage IIA esophageal cancer about 3 years after RT to the left hip. One female, at age 54, received a diagnosis of stage 0 ductal carcinoma in situ of the right breast also about 3 years after RT to the right hip. In both cases, the locations of the primary malignancies were entirely outside and distant from the region irradiated for HO prophylaxis.

Twelve patients (4.2%) developed postprophylaxis HO with a median time to failure of 8.6 months (range, 2.8-24.5 months). Ten patients developed HO in the hip, and 2 developed HO in the elbow. Eight of these patients (2.8% of the total cohort) developed asymptomatic HO detected radiographically (Brooker grade 1 and 2); 2 patients with Brooker grade I and 6 patients with Brooker grade 2. Four of these patients (1.4%) developed clinically relevant HO (Brooker grade 3 and 4); 3 with

**Table 3** Acute and chronic complications after prophylactic radiation therapy (RT) for the prevention of heterotopic ossification

Complication	No. of patients (% of total cohort)
Acute (within 3 mo of RT)	
Failure	6 (2.1)
Infection	16 (5.6)
Sensory deficit	7 (2.4)
Trochanteric bursitis	1 (0.3)
Chronic (>3 mo from RT)	
Failure	6 (2.1)
Infection	6 (2.1)
Posttraumatic osteoarthritis	36 (12.5)
Sensory deficit	8 (2.8)
Trochanteric bursitis	1 (0.3)
Both acute and chronic	12 (4.2)

Abbreviations: RT = radiation therapy.

The most common type of acute complication occurring after prophylactic RT was infection occurring in 5.6% of the cohort. The most common type of chronic complication was development of posttraumatic osteoarthritis.

**Table 4** Association between time variables and heterotopic ossification occurrence

	OR	95% CI	P value
Surgery to RT	1.68	0.99-2.85	.0559
Accident to RT	1.00	0.96-1.04	.9657
Accident to surgery	1.00	0.95-1.05	.9461

Abbreviations: CI = confidence interval; OR = odds ratio; RT = radiation therapy.

Although not statistically significant, we observed a trend of increased risk for HO with longer time interval between surgery and RT with a *P* value of .0559.

Brooker grade 3, and 1 with Brooker grade 4. Kaplan-Meier 1-, 2-, and 5-year failure rates of HO prophylaxis were 3.7%, 4.4%, and 7.4%, respectively (Fig. 2).

There was no statistically significant association between accident type, injury type, fracture type, surgery, surgical approach, and timing of RT and development of postprophylaxis HO (Tables E4 and E5). Time intervals between key events were not associated with an increased risk for developing HO (Table 4), but we did observe a trend of increased risk of HO in those patients with longer time intervals between surgery and RT (odds ratio [OR] 1.68; 95% confidence interval [CI], 0.99%-2.85%; *P* = .056). There was no difference in the incidence of acute or chronic complications between pre- versus postoperative RT. Current and former smoking status was found to be associated with a decreased incidence of HO (OR 0.10; 95% CI, 0.01%-0.78%; *P* = .03).

## Discussion

Here we report a retrospective analysis of a cohort of 287 patients who received RT for the prevention of HO after orthopedic trauma and surgery. Our current understanding of HO pathogenesis is believed to be the inappropriate transformation of pluripotent stem cells into osteoblasts, possibly induced by demineralized bone substance in muscle and fascia.<sup>18-20</sup> Radiation therapy for the HO prophylaxis, 20 Gy given in 10 fractions to the hip, was first reported in the 1980s.<sup>10</sup> Since that time, the dose and fractionation of treatments have been reduced to typically 7 to 8 Gy, given in a single treatment. The number of studies looking at this modern regimen are very limited and thus our literature review only yielded only a few relevant studies. Burnet et al in 2014 reported on a cohort of 34 patients who underwent RT in a single fraction of 8 Gy for the prevention of HO after traumatic acetabular fracture; 28 (82%) developed no HO, 6 (17.6%) developed clinically Brooker grade I HO, and none developed Brooker grade 2 to 4 HO.<sup>21</sup>

In the present study, there was no statistically significant association between injury or accident type, fracture type, surgical approach, time intervals between accident,

surgery, and RT, or the timing of RT (pre- vs post-operative) and postprophylactic development of HO in this cohort of 287 patients. This is contrary to multiple published reports of increased risk of HO after certain surgical approaches and increased time interval between injury and surgery,<sup>3,22</sup> suggesting that RT might play a role in mitigating these adverse effects.

Furthermore, we observed that former or current smokers were 10 times less likely to develop HO after RT prophylaxis (OR 0.1, *P* = .0282). This effect is hypothesized to be due to the antiosteogenic effects of smoking, which are known to result in delayed chondrogenesis, angiogenesis, and collagen synthesis, as well as slower overall fracture healing and weaker bone union after healing, with a generalized decrease in bone density.<sup>23-26</sup> In fact, delays in fracture healing have been reported in both current and former smokers.<sup>27</sup> However, in contrast to our findings, Lewis et al found that among service members with traumatic amputations, smokers were actually at an increased risk for developing heterotopic ossification at the site of traumatic amputation.<sup>28</sup> We believe further investigations into the mechanism of this surprising observation is needed to potentially develop another HO prophylaxis modality.

We did not see a statistically significant association between time intervals between the key events and the development of postprophylactic HO, but we did observe a nonsignificant trend in increased risk of HO in patients with longer time to RT after surgery (*P* = .0559). As only 4 patients in this cohort had delayed RT greater than 3 days from surgery, we were most likely limited in our ability to observe a statistically significant association between delayed RT and the development of postprophylactic HO.

No in-field secondary malignancy was identified in this cohort, although we do acknowledge a relatively short median follow-up time of just 17 months. Two patients did go on to be diagnosed with cancer at some points after treatment, but no malignancy was reported in the RT field. This is consistent with other published studies which did not report incidence of in-field secondary malignancies.<sup>21,29</sup>

Compared with multiple published estimates of HO incidence of 17% to 39% in patients who receive no prophylaxis after traumatic acetabular fractures of the hip,<sup>3,4,30</sup> our failure rate of 4.2% is highly suggestive of the efficacy of prophylactic RT. To our knowledge, at 287 patients we have studied is the largest contemporary cohort of patients receiving RT with CT simulation and 3-dimensional planning for the prevention of HO after orthopedic trauma or surgery. Mourad et al reported a retrospective study analyzing the incidence of postprophylactic HO after RT with a total of 532 patients with an overall failure rate of 21.6%.<sup>31</sup> However, the majority (*n* = 442) of those patients in this study underwent clinical simulation before adoption of CT based

simulation in their facility. The failure rate of those who underwent clinical simulation ( $n = 442$ ) was significantly ( $P < .001$ ) higher at 24.6% compared with 6.6% among those who underwent CT ( $n = 90$ ), which is much more consistent with our failure rate of 4.2% in the present study.

Our study was retrospective and was not designed to compare the efficacy of RT versus NSAIDs for HO prophylaxis. However, there have been at least 2 studies suggesting RT to be more effective in preventing HO than indomethacin and with RT failure rates similar to our findings. Burd et al reported in a prospective trial reported the HO incidence of 11% in the indomethacin group ( $n = 72$ ), 4% in the RT group ( $n = 78$ ), and 100% in the observation group ( $n = 16$ ), though these differences were not statistically significant.<sup>32</sup> A systemic review by Blokhuis et al of 384 patients (224 received indomethacin, 160 received RT) from 5 published studies demonstrated a statistically higher ( $P = .034$ ) postprophylaxis failure rate of 8.9% among the indomethacin cohort only 3.1% among the RT cohort.<sup>33</sup> The discussions regarding the risks and benefits of RT versus NSAIDs for HO prophylaxis is outside the scope of this report but this topic warrants individualized clinical consideration and discussion with the patient, when possible, as treatment with RT appears to be more effective at preventing heterotopic ossification, which can be debilitating.

## Conclusions

There are several weaknesses of this study, namely its retrospective nature and dependence on the quality of available documentation. Therefore, we were unable to evaluate the relative efficacy of RT prophylaxis (compared with those who undergo observation, with or without NSAIDs). Additionally, because our institution is a one of the few level one trauma centers in the region, many of the patients in this cohort who were initially treated in our institution but chose to receive their follow-up care close to their homes far from us, thus limiting the duration of the follow-up in some cases. Furthermore, due to technical and informational limitations involved in chart review and paucity of follow-up visits in some cases, we were unable to collect certain types of data, such as future fertility, in patients who received radiation to the hip and undocumented over-the-counter concomitant use of NSAIDs with RT, among others. Although we did not identify any in-field secondary malignancies, the short follow-up time is a major limitation to making this conclusion.

On the other hand, our study has several strengths. Most importantly, to our knowledge, it is the analysis of the outcome of largest cohort of patients who received RT using contemporary treatment techniques for HO prophylaxis after orthopedic trauma surgery. Additionally, it is important to note that we did not observe any

in-field secondary malignancy in this large cohort, even though this risk has been cited, though anecdotally, by many as a possible contraindication of prophylactic RT. Our observations, although limited by relatively short follow-up, are consistent with previously reported data that radiation therapy for prevention of HO does not increase the risk of malignancy compared with no radiation therapy.<sup>8</sup>

In conclusion, RT appears to be a safe and effective method of HO prophylaxis in this high-risk population.

## Supplementary Materials

Supplementary material for this article can be found at <https://doi.org/10.1016/j.adro.2020.11.010>.

## References

1. Brooker AF, Bowerman JW, Robinson RA, Riley LJ. Ectopic ossification following total hip replacement. Incidence and a method of classification. *J Bone Jt Surg Am.* 1973;55:1629-1632.
2. Balboni TA, Gobeze R, Mamon HJ. Heterotopic ossification: Pathophysiology, clinical features, and the role of radiotherapy for prophylaxis. *Int J Radiat Oncol Biol Phys.* 2006;65:1289-1299.
3. Elhassan Y, Abdelhaq A, Piggott RP, Osman M, McElwain JP, Leonard M. Heterotopic Ossification following acetabular fixation: Incidence and risk factors: 10-year experience of a tertiary centre. *Injury.* 2016;47:1332-1336.
4. Murphy D, Kalischer M, Rice J, McElwain JP. Outcome after acetabular fracture: Prognostic factors and their inter-relationships. *Injury.* 2003;34:512-517.
5. Schmidt SA, Kjærsgaard-Andersen P, Pedersen NW, et al. The use of indomethacin to prevent the formation of heterotopic bone after total hip replacement. A randomized, double-blind clinical trial. *J Bone Jt Surg.* 1988;70:834-838.
6. Kjærsgaard-Andersen P, Nafei A, Teichert G, et al. Indomethacin for prevention of heterotopic ossification: A randomized controlled study in 41 hip arthroplasties. *Acta Orthop Scand.* 1993;64:639-642.
7. Łęgosz P, Otworowski M, Sibilska A, et al. Heterotopic ossification: A challenging complication of total hip arthroplasty: Risk factors, diagnosis, prophylaxis, and treatment. *Biomed Res Int.* 2019;2019, 3860142.
8. Sheybani A, TenNapel MJ, Lack WD, et al. Risk of radiation-induced malignancy with heterotopic ossification prophylaxis: A case-control analysis. *Int J Radiat Oncol Biol Phys.* 2014;89:584-589.
9. Jansen JTM, Broerse JJ, Zoetelief J, Klein C, Seegenschmiedt HM. Estimation of the carcinogenic risk of radiotherapy of benign diseases from shoulder to heel. *Radiother Oncol.* 2005;76:270-277.
10. Coventry MB, Scanlon PW. The use of radiation to discourage ectopic bone. A nine-year study in surgery about the hip. *J Bone Joint Surg Am.* 1981;63:201-208.
11. Lo TC, Healy WL, Covall DJ, et al. Heterotopic bone formation after hip surgery: Prevention with single-dose postoperative hip irradiation. *Radiology.* 1988;168:851-854.
12. Pellegrini VD, Kanski AA, Gastel JA, Rubin P, Evarts CM. Prevention of heterotopic ossification with irradiation after total hip arthroplasty. Radiation therapy with a single dose of eight hundred centigray administered to a limited field. *J Bone Joint Surg Am.* 1992;74:186-200.

13. Hamid N, Ashraf N, Bosse MJ, et al. Radiation therapy for heterotopic ossification prophylaxis acutely after elbow trauma: A prospective randomized study. *J Bone Joint Surg Am.* 2010;92:2032-2038.
14. Gregoritch SJ, Chadha M, Pelligrini VD, Rubin P, Kantorowitz DA. Randomized trial comparing preoperative versus postoperative irradiation for prevention of heterotopic ossification following prosthetic total hip replacement: Preliminary results. *Int J Radiat Oncol Biol Phys.* 1994;30:55-62.
15. Padgett DE, Holley KG, Cummings M, et al. The efficacy of 500 centigray radiation in the prevention of heterotopic ossification after total hip arthroplasty: A prospective, randomized, pilot study. *J Arthroplasty.* 2003;18:677-686.
16. Sylvester JE, Greenberg P, Selch MT, Thomas BJ, Amstutz H. The use of postoperative irradiation for the prevention of heterotopic bone formation after total hip replacement. *Int J Radiat Oncol Biol Phys.* 1988;14:471-476.
17. Anglen JO, Moore KD. Prevention of heterotopic bone formation after acetabular fracture fixation by single-dose radiation therapy: A preliminary report. *J Orthop Trauma.* 1996;10:258-263.
18. Naraghi FF, DeCoster TA, Moneim MS, Miller RA, Rivero D. Heterotopic ossification. *Orthopedics.* 1996;19:145-151.
19. Urist MR. Bone: Formation by autoinduction. *Science.* 1965;150:893-899.
20. Chalmers J, Gray DH, Rush J. Observations on the induction of bone in soft tissues. *J Bone Jt Surg.* 1975;57:36-45.
21. Burnet NG, Nasr P, Yip G, et al. Prophylactic radiotherapy against heterotopic ossification following internal fixation of acetabular fractures: A comparative estimate of risk. *Br J Radiol.* 2014;87:20140398.
22. Firoozabadi R, Alton T, Sagi HC. Heterotopic ossification in acetabular fracture surgery. *J Am Acad Orthop Surg.* 2017;25:117-124.
23. Gullihorn L, Karpman R, Lippiello L. Differential effects of nicotine and smoke condensate on bone cell metabolic activity. *J Orthop Trauma.* 2005;19:17-22.
24. El-Zawawy HB, Gill CS, Wright RW, Sandell LJ. Smoking delays chondrogenesis in a mouse model of closed tibial fracture healing. *J Orthop Res.* 2006;24:2150-2158.
25. Ueng SW, Lin SS, Wang CR, Liu SJ, Tai CL, Shih CH. Bone healing of tibial lengthening is delayed by cigarette smoking: Study of bone mineral density and torsional strength on rabbits. *J Trauma.* 1999;46:110-115.
26. Ueng SW, Lee SS, Lin SS, et al. Hyperbaric oxygen therapy mitigates the adverse effect of cigarette smoking on the bone healing of tibial lengthening: An experimental study on rabbits. *J Trauma.* 1999;47:752-759.
27. Harvey EJ, Agel J, Selznick HS, Chapman JR, Henley MB. Deleterious effect of smoking on healing of open tibia-shaft fractures. *Am J Orthop (Belle Mead NJ).* 2002;31:518-521.
28. Lewis PC, Camou E, Wofford K. The impact of cigarette smoking on the formation of heterotopic ossification among service members with a traumatic amputation. *Mil Med.* 2017;182:e1742-e1748.
29. Ruo Redda MG, De Colle C, Bianco L, et al. Heterotopic ossifications: Role of radiotherapy as prophylactic treatment. *Radiol Med.* 2018;123:463-468.
30. Baschera D, Rad H, Collopy D, Zellweger R. Incidence and clinical relevance of heterotopic ossification after internal fixation of acetabular fractures: Retrospective cohort and case control study. *J Orthop Surg Res.* 2015;10:60.
31. Mourad WF, Packianathan S, Ma JK, et al. Computerized tomography-based radiotherapy improves heterotopic ossification outcomes. *Bone.* 2013;57:132-136.
32. Burd TA, Lowry KJ, Anglen JO. Indomethacin compared with localized irradiation for the prevention of heterotopic ossification following surgical treatment of acetabular fractures. *J Bone Joint Surg Am.* 2001;83:1783-1788.
33. Blokhuis TJ, Frölke JPM. Is radiation superior to indomethacin to prevent heterotopic ossification in acetabular fractures? A systematic review. *Clin Orthop Relat Res.* 2009;467:526-530.