

5-1-1933

Treatment of hemorrhoids

Harald N. Johnson
University of Nebraska Medical Center

This manuscript is historical in nature and may not reflect current medical research and practice. Search [PubMed](#) for current research.

Follow this and additional works at: <https://digitalcommons.unmc.edu/mdtheses>

Recommended Citation

Johnson, Harald N., "Treatment of hemorrhoids" (1933). *MD Theses*. 971.
<https://digitalcommons.unmc.edu/mdtheses/971>

This Thesis is brought to you for free and open access by the Special Collections at DigitalCommons@UNMC. It has been accepted for inclusion in MD Theses by an authorized administrator of DigitalCommons@UNMC. For more information, please contact digitalcommons@unmc.edu.

THE TREATMENT OF HEMORRHOIDS

by

Harald Norlin Johnson B.Sc. M.A.

Presented to the Faculty
of the University of Nebraska in
partial fulfillment of the requirements
for the Degree of Doctor of Medicine

From the Medical College

University of Nebraska

Omaha, Nebraska

April 1933

THE TREATMENT OF HEMORRHOIDS

TABLE OF CONTENTS

Introduction	1
Review of the literature	2
Surgical anatomy	7
Definition and classification	11
Etiology	13
External hemorrhoids	17
Internal hemorrhoids	22
The injection treatment	31
Pre-operative treatment and anesthesia	36
The clamp and cautery operation	40
The ligature method	42
The clamp and suture method	44
The high frequency current	46
Post-operative dressing and treatment	49
Post-operative complications	52
Summary	55
Case reports	56
Bibliography	67

INTRODUCTION

The idea that the treatment of hemorrhoids must of necessity be a somewhat embarrassing and decidedly painful proceeding is prevalent in the minds of most of the laymen and not a few doctors. The reasons for its bad reputation is probably to some measure due to the lack of education of the profession in regard to treatment of the condition and partly to the patients attitude in not doing anything about the condition until the symptoms become severe enough to make the treatment more hazardous than necessary.

In a series of general medical cases, Kantor, noted the presence of piles in 26.3% of the patients. Of these 9% had actual varices, and 17% had skin tags as evidence of involuted varices. This goes to show that a considerable percentage of the general run of patients have piles and that they are for the most part incident, often unmentioned in the history and are discovered only in the course of a physical examination or questioning in regard to rectal symptoms such as constipation, pruritis or bleeding.

I have chosen this subject so as to familiarize myself with a very common condition; one which may apparently be treated quite easily and with good results.

REVIEW OF THE LITERATURE

The word hemorrhoid is derived from the two greek words *aima*, meaning blood and *peiv*, meaning to flow. This is really not a descriptive term for the condition and the more lay term, pile, from the latin word *pila*, a ball or swelling, carries a more accurate meaning. By common consent the term hemorrhoid means varicose swellings of the lower rectum and anus.

The history of this ailment is rather interesting. Descriptions are noted in the old testament where they are referred to as "emrods", or the plague. In the Talmud it is noted that a sedentary life is one of the etiological factors.

In the writings of Hippocrates a special treatise of nine chapters is devoted to hemorrhoids and in this book (translation of Robert Fuchs, vol. III, p. 301) there is an excellent clinical description of the condition, and methods of treatment such as cauterizing by hot iron, excision and drying by caustics, are mentioned. He used a sort of rectal speculum and described the hemorrhoids as grape-like in appearance. They were apparently considered benign and even useful by the people of that time and it was considered a good omen if hemorrhoids appeared. Treatment was deferred until severe symptoms ensued.

There is an equally good description in the work of Celsus, who considered hemorrhoids a means of purification and maintained that they should not be suppressed lest the unsound matters of the body be carried to the cardiac region and to the viscera. He suggested

hip baths, regulated mode of life, and care as to soft stools. Like Hippocrates he tried to obliterate the nodes by applying caustics and puncturing with needles when they became painful and bothersome.

In the writings of Galen hemorrhoids are considered an important means of eliminating unsound juices of the body. Treatment consisted of venesection and cuping. He noted that in certain abdominal affections bleeding from the hemorrhoidal veins often gave relief. Hemorrhoids at that time were designated as golden veins.

Bartholinus of Padua considered them as having a physiological effect, possibly in carrying the melancholic blood from the spleen.

Martin Luther (1483 - 1546), suffered from melancholic distemper associated with hemorrhoids and in a letter to a Justus Jonas describes his condition and attributes a medical value to them. He believed that the bad excretions of the body were removed thru them.

Jan de Waal (Walaeus) (1604 - 49), was the first to describe the condition as varices venarum ani.

At the beginning of the 19th century up to the 50s, the development of the humeral pathology led to the view that hemorrhoids were but a symptom of a general affection and that the malady was caused by a toxin. This led to a period of non-treatment as they feared to suppress the flow of blood. Then again such works as that of Nauman (1839), connecting the flow of blood from the rectum with menstruation and regarding it as a natural excretion of toxic material had much to do with this view. There was also a continuance of the idea of the golden vein.

Of especial interest is the development of the injection

treatment following this period of non-intervention. There is a record of a Mr. Morgan of Dublin who in 1869 used iron persulphate as an injection medium in the treatment of a case of hemorrhoids. This mode of treatment had been used as early as 1836 in the treatment of naevi. However the real origin of the injection treatment dates to 1871, when Mitchell of Clinton, Ill., first used carbolic acid as the injecting agent in the treatment of uncomplicated internal hemorrhoids. The method was for a time kept secret but knowledge of it soon spread. The secret was sold to various unqualified people who became known as traveling pile doctors. Professor E. Andrews of Chicago in 1876 discovered the secret from one of the quacks and carried out an investigation of 3,300 cases. He found that Mitchell used one part of carbolic to two parts of olive oil. Most of the quacks used strong solutions of carbolic ranging from 27 to 95%. Once the secret was bared many qualified practitioners took up the method and out of this came three schools of thought. The first, headed by Allingham senior, Mathews and the Andrews, considered the method unsafe and dangerous. The second headed by Agnew, Shuford, Adler and the Martins believed in injecting strong solutions of carbolic (20 to 95%) aiming at removing the piles by sloughing them off. The third and the one that is now to the fore, had as its early advocates Hoyt, Yount, Wright, Gladbacher, Gabriel and others. Many solutions have been developed for use in injecting hemorrhoids but only three have had any general acceptance. One of these is quinin and urea hydrochloride in a 5% aqueous solution. This method was first used by E.H. Terrell of Richmond Virginia in 1913. In 1924

he reported the results of its use in 3000 cases in which he had no deaths and comparatively few complications. Another solution is alcohol. This has been advocated by Boas of Germany. He previously advocated 96% alcohol but has now reduced this to 70% because of complications. The third solution is carbolic acid, which has seen the most general acceptance and the use of which will be taken up later in this paper.

The injection treatment has not been enthusiastically accepted by the American medical profession, largely because of its support by irregular practitioners such as the osteopaths, plus the lack of standardization of technique. However at present it is approved by such men as Hirschman, Yeoman, Terrell, Buie of America, and Perrin, Gabriel, Miles, Sir Charles Watson and Lockhart Mummery of England. More radical enthusiasts are Boldbacher, Pruitt and Morley.

As noted previously, the operative method has been tried since ancient times. In 1846 Cusack of Dublin devised the clamp and cautery method. H. Lee introduced it into London and H. Smith brought it into prominence in England. This has been a very popular method of operative treatment ever since. Many changes have been made, most of which have had to do with the type of clamp used, the latest being the electro-coagulating clamp.

In 1882, Walter Whitehead of Manchester England introduced total excision of the hemorrhoidal zone, namely the lower one and one-half inches of the rectal mucosa. This operation was widely used for some time but has lately become in bad repute and is rarely used any more.

The other surgical procedure of note is the ligature method. Tuttle was probably the first to make a report of this operation. This is now a standard method and is very popular in England.

SURGICAL ANATOMY

The rectum is some six inches long and in its upper part has a structure similar to the intestine in general, that is; mucous membrane, submucosa, muscular coat, and serous coat (peritoneum). The lower portion, however, has no peritoneal covering.

The rectum is generally divided into a lower and upper portion, the dividing point being the lowest valve of Houston. The lower ~~part~~ ^{part} is further subdivided into the anal canal and the ampulla.

The anus is the dilatible slit-like external opening of the anal canal. The surrounding skin is usually somewhat pigmented and contains hair follicles, sweat, oil and sudoriferous glands.

The canal itself is directed upward and forward and varies in length from one to one and one-half inches. It extends from the anal aperture to the ampulla, that is, to the level of the upper surface of the pelvic floor. It is surrounded at its lower end by the external sphincter ani and at its upper end by the internal sphincter ani and levator ani muscles. The anal canal is lined with modified skin below and modified mucous membrane above. These merge in the region of Hilton's line; a term which is a misnomer at the line is a depression occurring in the space between the two sphincters and is neither white nor linear. The title, Hilton's circular sulcus might be employed. Some eighty percent of ano-rectal affections occur in the anal canal and lower ampulla (Goldbacher).

The papillary (pectinate or dentate) line is an irregular line extending around the inner surface of the upper anal canal, just over

the internal sphincter muscle. On it are located five to ten projections known as anal papillae. These are supposedly organs of special tactile sense, possibly distinguishing between gaseous, liquid and solid feces. These may become enlarged and even extend through the anal orifice.

The crypts of Morgagni (rectal crypts) are small depressions or sulci behind the anal papillae and at the base of the columns of Morgagni. They probably function in the secretion of a lubricant to aid in the passage of feces.

The columns of Morgagni (rectal columns) are longitudinal pleats or folds of mucousa, six to ten in number, which start at the papillary line and extend upward for about three-fourths of an inch, then disappearing in the surrounding tissue. They apparently help guide the feces into the anal canal. They are not always well defined.

The ampulla is the dilatable portion of the lower rectum, extending from the anal canal to the lowest valve of Houston.

Houston's valves are permanent transverse folds of mucousa and submucousa containing a few muscular fibers. They are crescentic in shape and are situated in the upper rectum. They are usually three in number although there may be four or more. Rarely, there may be only two. The lowest valve is about four inches above the anal aperture, about level with the fundus of the bladder and approximately marks the level of the peritoneal reflexion. The middle valve is about one inch above the lowest one or approximately five inches above the anus and nearly opposite the middle of the sacrum. The highest valve is situated near the recto-sigmoidal junction. These valves function

in supporting the weight of the fecal column.

The blood supply of the rectum is by three main channels. The superior hemorrhoidal from the inferior mesenteric artery, the middle hemorrhoidal from the internal iliac artery and the inferior hemorrhoidal from the internal pudic artery (see figures 1 and 2).

The hemorrhoidal veins are described by most modern anatomists as forming two plexuses; an internal lying in the rectal submucosa and anal subcutaneous tissues and an external lying in the peri-rectal fat between the muscular wall of the bowel and the fascia recti. The external plexus is drained by the middle hemorrhoidal veins into the internal iliacs. This plexus plays a very small role in the development of hemorrhoids because its communications with the submucous plexus are insignificant. The internal plexus which is the site of hemorrhoidal formation consists of two groups of veins in which the circulation normally diverges from the sulcus of Hilton. The inferior group passes between the anal sphincters to form the inferior hemorrhoidal veins going through the ischio-rectal fossae into the internal pudental veins. Dilation of this group is evidenced as external hemorrhoids. The superior group passes upward in the submucosa and pierces the muscular wall about four inches above the muco-cutaneous junction. These vessels after receiving communicating branches from the external plexus form the superior hemorrhoidal vein which courses upward on the posterior surface of the rectum and terminates in the inferior mesenteric vein (see figures 3 and 4).

The veins of the internal hemorrhoidal plexus pass through two openings surrounded by muscle tissue, that is, the space between the

external and internal sphincters and through the rectal wall above. The normal tonus of these muscles has a valvular action. Reflux from the superior hemorrhoidal into the internal plexus is so prohibited under normal conditions. When internal hemorrhoids are present the circulation is reversed. This shows why external hemorrhoids are often associated with internal hemorrhoids. It is this circulation that is involved in portal obstruction. This reversal is accentuated by any pressure which flattens the lumbo-sacral angle and so obstructs the normal return flow. A physiological condition such as sitting and slumping postures are examples of this, then there are also any other phenomena that might obstruct the portal return flow.

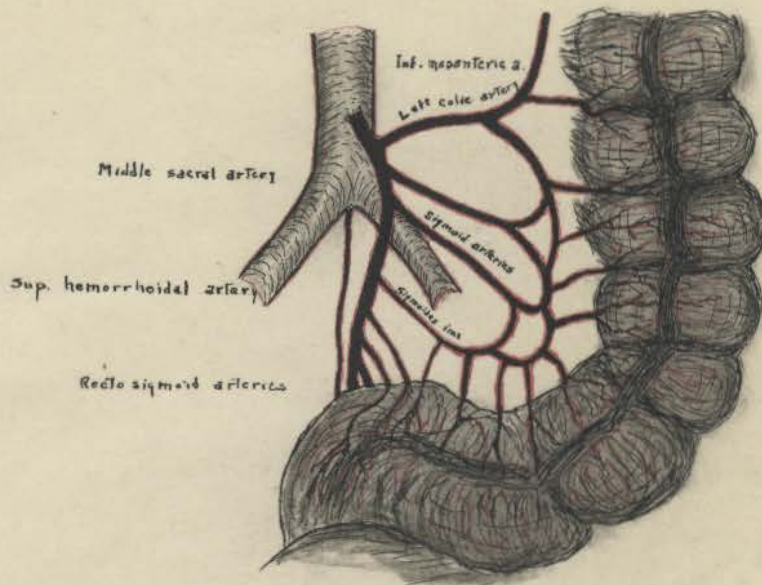


Fig. 1 Blood supply of the sigmoid and recto-sigmoid

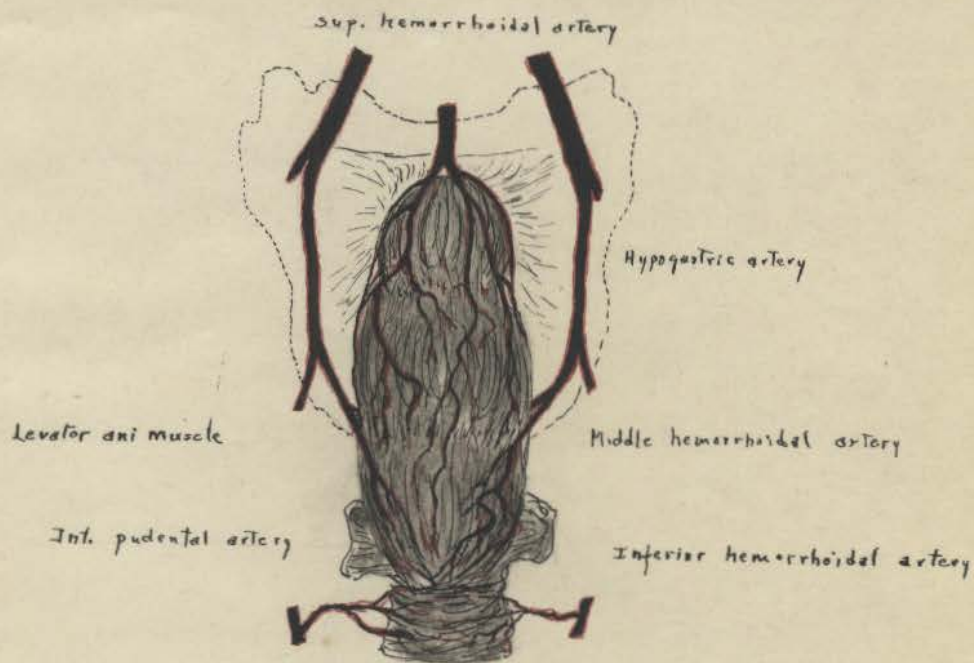


Fig. 2 Blood supply of the rectum and anus

(From text by Ball)

DEFINITION AND CLASSIFICATION

Hemorrhoids are varicose tumors involving the radicals of one or more hemorrhoidal veins, characterized by hemorrhage or prolapse and tendency to interstitial fibrosis and spontaneous cure or thrombosis and ulceration.

Classification is usually according to location and covering membrane, and includes three general groups.

The first group is the external hemorrhoid which is external to the ano-rectal line, covered with skin, and involves the vessels of the inferior venous plexus and is therefore connected with the general circulation. This group is further subdivided into external thrombotic hemorrhoids, skin tabs or tags (connective tissue piles) and external varicose hemorrhoids.

The second group is the internal hemorrhoid, which is internal to the ano-rectal line, covered with mucous membrane and involves vessels of the superior venous plexus and is connected with the portal circulation. This group is further subdivided as to the type of vessels in the tumor, that is, whether the venous sinuses are large or of capillary type. Then there is a subdivision as to the amount of fibrous tissue in the tumor. Lastly, there is the classification as to the degree of prolapse. First degree designates the class where the hemorrhoids remain above the sphincter muscles. Second degree, where they protrude or descend below the external sphincter during defecation or straining, returning spontaneously. Third degree, where they are

prolapsed and remain outside unless returned by external pressure and then with difficulty or not at all.

The third general group is the muco-cutaneous variety which is nothing but a combination of the two previous groups.

ETIOLOGY

Internal are much more common than external hemorrhoids.

Various authors placing the incidence from four to one to seven to one. External hemorrhoids rarely occur alone, that is, without associated internal hemorrhoids, with or without symptoms.

The causative factors are generally divided into two main groups:

1. Predisposing and 2. Exciting.

First under the predisposing causes one might mention heredity. It is well known that varicocele, varicose veins and esophageal varices, often tend to be familial. This is also true of hemorrhoids and to be sure these affections are similar, being all due to some weakness in the venous system. There is also the factor of stature, which is generally considered with heredity. It seems that people of the stocky diathesis are more prone to develop hemorrhoids than the asthenic type of individual. There is also the mental makeup of the individual, which, if he is of the driving type may lead to physical and mental strain with resultant changes in the vascular tree such as sclerosis and hypertension.

Another factor in the predisposing element is age. The average age of cases requiring treatment is about 45 years, and most of the cases vary between 20 and 70 years of age. Rare cases have been recorded in the literature of children such as the one of Ashton; a case of external hemorrhoids in a child of two, and Ogston and Vincent; a case of thrombotic external hemorrhoids in a child of three.

Then there are reports of operation of quite old individuals, notably the case of Landsman who successfully operated on a case 107 years of age for large internal hemorrhoids. Hemorrhoids are, however, generally acquired in later life as a part of the degenerative change affecting all the tissues of the body. The sphincters become thin and atonic and adequate muscular support is lacking. Then there is a general weakening of the veins associated with sclerotic changes in the vascular system.

Sex does not at present seem to be significant. It used to be considered that the affection was more common among men but at present it seems that it is somewhat more so in women. The previous statistics were possibly inaccurate because women being used to a menstrual flow of blood did not regard bleeding from the rectum with much alarm, and also the element of modesty possibly kept many from seeing anyone about the affliction. Recent statistics taken from the general run of hospital cases where this factor is eliminated shows a slightly higher percentage among women.

The fons et origo mali is to be sought in the circulatory mechanism and here there are several anatomical factors. The basic anatomic fact is that the veins from the hemorrhoidal zone drain, through the superior hemorrhoidal, directly into the portal vein, which has no valves. Quadripeds seldom develop a hemorrhoidal condition so the erect posture has often been blamed, that is, the distribution of the column of blood places the weight of the column on the most dependant portion. The loose connection of the rectal mucosa and the muscularis in the hemorrhoidal zone is also significant.

The passage of the veins directly through the muscle, subjecting them to constriction with straining such as coughing, lifting and defecation is a factor. The connection with the portal system, which is frequently congested and the anastomosis with the general circulation is also important.

Of the exciting causes the most common one seems to be the irritation factor. Cathartics, especially the resinous variety, act by direct stimulation of and irritation of the mucosa and this is a marked factor in the production of hemorrhoids. Enemas act in a similar manner. Any irritation in the rectum such as fecal matter, infection, and any irritating discharges from above, notably colitis, especially of the ulcerative variety are important etiological factors.

Under mechanical causes may be noted intrinsic factors such as stricture or tumors of the rectum, especially of the upper portion in which the primary condition overwhelms the hemorrhoids, meaning of course cancerous growths. In the lower rectum may be polyps, elongated papillae, and redundant mucosa. Extrinsic factors would be abdominal and pelvic tumors, pregnancy, childbirth and retroversion of the uterus.

Under physiological factors may be noted any condition which tends to engorge the portal and hemorrhoidal veins. Among these are a congested liver as in uncompensated heart disease and cirrhosis and neoplasms of the liver. Overeating, especially of highly seasoned foods to which irritating condiments are added, increases congestion. Alcoholic beverages in excess often precipitate the development of hemorrhoids.

Occupation may be a factor in that policemen, letter carriers, pedestrians and people who must spend much of their time on their feet,

seem prone to develop varicose veins and hemorrhoids.

Constipation has long been blamed in the production of hemorrhoids. It acts in two ways; that is, in increased intra-abdominal tension at stool and irritation of the hardened feces in the rectum plus pressure on the venous return.

Low grade infection must be considered in the changes that lead to thrombosis. Hemorrhoids may follow a low grade infection, producing inflammation without pus. The usual entrance of the infection is thru the bottom of the anal crypts. From here the infection passes beneath the covering of the anal canal and forms small sinuses. The process is very slow and usually the first indication of such an infection is spasm of the external sphincter muscle. When the infection extends to the veins their walls become brittle and anelastic. Then the sudden muscular exertion, especially in the external variety, may cause rupture and consequent hematoma. This is probably an important mechanism in the hemorrhoids associated with fissure, fistula, ulcer or other infection of the rectum.

EXTERNAL HEMORRHOIDS

As previously noted there are three main categories; that is, the cutaneous variety, the varicosities, and the thrombotic hemorrhoids.

Skin tags or connective tissue piles may be single or multiple, varying from one-eighth to three-fourths of an inch in length. Histologically they are composed of connective tissue covered with perianal skin, a small artery and vein usually entering at the base. These are usually the remains of untreated or improperly treated external thrombotic hemorrhoids, but they may result from any condition which causes perianal irritation. A good example of the latter is the sentinel pile or pylet tab occurring with fissure in ano. Numerous elongated tabs indicate more serious disease within the rectum. If not complicated by other anal inflammation they seldom give symptoms, however, if they become tender, tense, painful or itchy as the result of infection or trauma they should be removed. They sometimes can be made to shrink by local application of lead lotion. If present at the posterior margin of the anus they are often associated with fissure and this condition must be treated first. Skin tags associated with internal hemorrhoids generally disappear following injection or operative removal of the hemorrhoids.

In the operative removal, the skin over the tag is injected with 2% novocaine solution, using as little anesthetic as possible to prevent undue distortion; or they may be frozen with ethyl chloride.

If the skin tag is small it is picked up with a tissue forceps and cut off near its base with a pair of strong scissors. If the tag is large care must be exercised to prevent bleeding. Excision of the tag is made parallel to the long axis of the bowel, at a sufficient distance within the base-line to permit the cut edges of the skin to nearly approximate. If too much tissue is removed, a large cicatrix may result and its contraction cause partial stenosis. Any bleeding points are picked up with a hemostat and ligated. The bleeding surface may be touched with electro-cautery or with a styptic such as tannic acid, tincture of iodine or pure phenol. Carbolyzed petroleum (1 $\frac{1}{2}$ %) and sterile dressings applied and the patient advised to refrain from defecation until the next day. After the first bowel movement cleanse the parts with boric solution and cotton and no further dressing or application is needed.

External varicosities about the anus are rare and if present are usually compensating in an anastomotic circulation and should not be bothered.

When thromboses occurs in the external hemorrhoidal group, examination usually discloses beneath the smooth, shiny skin, at one side of the anal margin, an ovoid, livid, firm, tender swelling, the size of a grape or smaller. Usually no internal swelling is present but rarely a bluish tender ridge is felt extending upward beneath the muco-cutaneous lining of the anal canal. At other times marked edema may obscure the clot which may nevertheless be felt by deep firm compression between the thumb and index finger.

The thrombosis is usually due to a strain or traumatism of the

engorged hemorrhoidal veins. Occasionally the clot may form in a radical of the varicose vein but usually the vein ruptures and the blood accumulates as a single large clot; as several clots or as many smaller ones infiltrating the connective tissue. Histological study shows that in a small minority of cases clotting occurs within the vessel: in some cases only the intima and media are ruptured and the adventitia of the vein forms the limiting wall of the clot. In the vast majority of cases all the coats of the vessel are ruptured and clotting occurs in the connective tissue external to the vein. The exciting cause is always a strain, as lifting heavy weights, effort at stool, violent exercise, coughing or sneezing. Usually the patient has a feeling that something has given away. Immediately there is local swelling and discomfort, which in a few hours becomes a severe, constant pain, often throbbing in character and aggravated by sitting, pressure or bowel action. The pain is due to the tension and pressure of the clot on the numerous sensory nerve endings in the peri-anal skin, and is much aggravated when the sphincter is tight and spasmodic. After forty-eight hours or so, the pain usually subsides to a marked degree even without any treatment.

The subsequent course varies with the size of and location of the clot. In the case of the small clot, resolution may occur in ten days to a fortnight, but usually a shot-like irritating residue persists beneath the skin, or there results from the irritation of the extravasated blood a local production of subcutaneous tissue and this is the usual method of formation of the peri-rectal skin tags or piles previously mentioned. When the clot is large and especially if it extends

up beneath the anal lining, pressure necrosis frequently occurs, followed by bleeding. The clot may be retained or expelled. Infection may follow and an ulcer or superficial fistula result. Rarely infection of the blood clots produces a marginal abscess.

Palliative treatment consists of rest in bed, mineral oil to promote soft stool, a soothing antiseptic ointment, and hot packs or hot sitz baths twice a day. Compresses of lead and opium wash may be applied continuously. The pain usually subsides in two to three days. Some cases respond favorably, resolution occurring or a shot-like subcutaneous induration or skin tag only, remaining; other cases are not relieved and the uncertain outcome and suffering associated makes palliative treatment a poor substitute for the operative treatment.

For the operative procedure have the patient in the Sim's position, affected side downward. Cleanse the field and prepare the field with some antiseptic such as iodine or picric acid. Infiltration anesthesia may be used, that is, an intra-dermal wheal over the pile, of one to two cubic centimeters of 2% novocaine, or the pile may be frozen with ethyl chloride. The pile is now grasped near its center with a pair of Allis or rat-tooth forceps and an elliptical excision is made, from within out, parallel with the long axis of the bowel, using a pair of strong curved scissors. The clot usually delivers itself spontaneously, but, if retained by its connective tissue envelope the scissors are insinuated on each side snipping slightly if necessary till it is freed and evacuated intact. Neither the finger nor any instrument other than the sterile scissors enters the wound. A sterile compress applied firmly to the wound controls the slight bleeding.

Occasionally it may be necessary to ligate a small vessel. An astringent solution may now be used, however this seldom applied, and a small compress applied to the wound and held firmly in place by a fifteen inch strip of one-inch adhesive, running from the inner side of the thigh close to the anus and upward over the buttock to the loin. Some patients have no pain subsequently, others experience a smarting or burning sensation for an hour or two after the anesthetic wears off. The bowels are confined for twenty-four hours. The dressing is removed at that time and the wound cleansed after each bowel movement by sponging with hot boric solution and absorbent cotton. After drying, a small pledget of cotton dusted with antiseptic powder may be left in situ. No further bandage is required. This treatment usually results in complete healing. There is no detention from business and in a week the scar is barely visible.

As previously mentioned and as will be noted under internal piles, a thorough search should be made for any causative pathology and if found it should be treated.

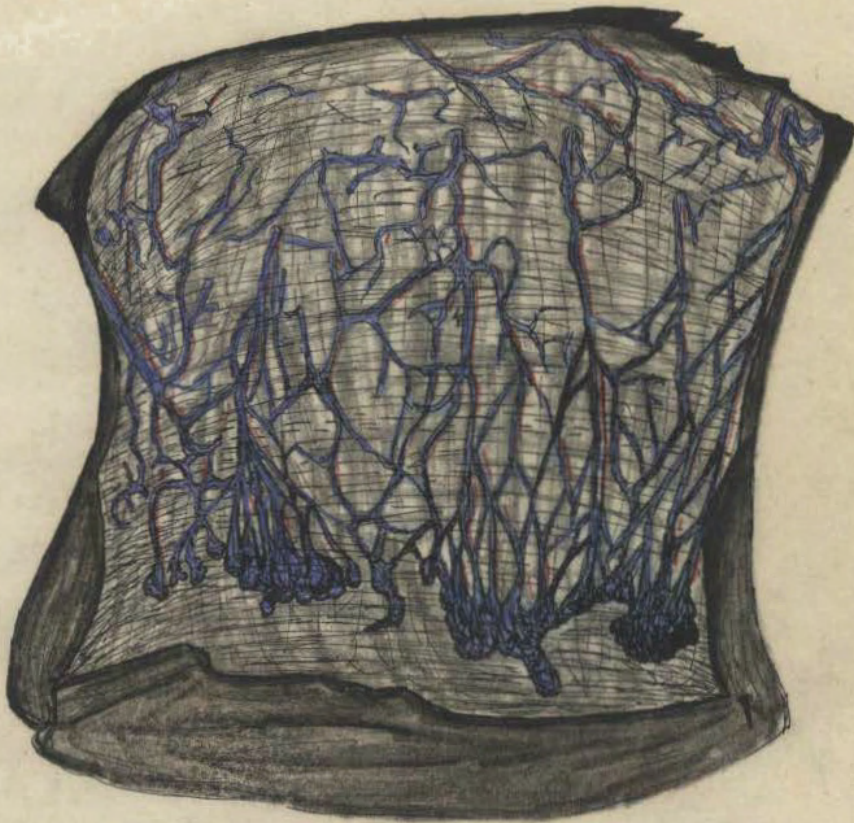

Fig. 3 Dilatation of venules - the origin of hemorrhoids

(Goldbacher)

INTERNAL HEMORRHOIDS

Internal hemorrhoids grossly appear as longitudinal folds of mucosa within the rectum, beginning at the pectinate line or true mucosa and extending upward a distance varying from two to four centimeters, where they flatten out and blend into the rectal mucosa. The hemorrhoid encroaches on the bowel lumen and the straining effort of passing hard fecal masses exerts traction of the mucosa which is thus protruded. Should the prolapsed hemorrhoid be grasped by a spasmodic sphincter and not replaced, strangulation may ensue. Superficial gangrene often follows strangulation. Rarely, infection and abscess formation occurs.

A typical hemorrhoid consists of a conglomerate mass of dilated venules (see figure 3), a few unchanged arterioles, a connective tissue stroma which shows chronic inflammatory changes, and a covering of rectal mucosa, more or less diseased. Portal congestion and increased intra-abdominal pressure produce an abnormally high blood pressure in the venous radicles, which causes them to dilate. Fecal traumatism injures and often ruptures the vessels. Histological study shows that the muscular and elastic tissue in the vessel wall is replaced to varying degrees by fibrous tissue.

The final product is a vessel, the thin wall of which is made up largely of fibrous tissue with an endothelial lining, very vulnerable and prone to rupture. Rupture is usually due to fecal trauma but may result from extension of ulceration from the mucosa. Occasionally

circumscribed thrombosis occurs in the diseased veins under the same conditions as produce it in varicose veins in other situations. The arterioles undergo no important histological changes. The interstitial connective tissue shows inflammation of a chronic, productive character, due to chronic congestion, irritation by blood extravasated from the veins, and infection through the ulcerated mucosa. In its contraction, the fibrous tissue thus formed tends to obliterate the venules and so produce a spontaneous cure of the hemorrhoid, or to transform it into a fibrous mass. The mucosa, in chronic cases, may be intact and thickened. More usually it shows degenerative changes and is thinner than normal and its surface granular. Traumatism of the mucosa by hard feces causes abrasions and fissures, which are infected by the omnipresent bacterial flora of the intestine, resulting in erosions and ulcers.

Degenerative changes in hemorrhoids may be simple or malignant. As the result of thrombosis may get a fibroma, which in turn due to frequent extrusion becomes elongated into a fibrous polypus. Carcinoma as a result of malignant degeneration is evidently a rarity.

Bleeding and protrusion are the characteristic symptoms of uncomplicated hemorrhoids. The congested mucous membrane covering the pile soon becomes granular and vulnerable, so that bleeding is commonly the first symptom noted. The blood, of red color, accompanies the stool and is usually of less quantity than the patient estimates, or it may be admixed with the stool and escape notice. Exceptionally at defecation a stream of blood will spurt from an ulcerated vein, resulting in a massive hemorrhage. About 85% of the cases of internal

hemorrhoids have bleeding as a symptom and there may develop a profound anemia, the hemoglobin going as low as 30 to 40%, and the blood picture becoming that of a primary anemia associated with such symptoms as pallor, vertigo, and palpitation. Deaths have been reported from exsanguination. Bleeding from the rectum in children should warrant examination for polypus and prolapse; and in the aged it should suggest malignancy. "Concealed hemorrhage", occurs in some cases, that is, the blood accumulates in the rectum and is evacuated as large tarry clots, together with or independent of stools. There should always be a question of malignancy with this latter symptom.

Protrusion is present in about 95% of the cases that are symptomatic. It may be absent or be the chief complaint. It does not occur early in the formation of hemorrhoids, but as they enlarge, they are dragged down with bowel movement and eventually they elongate and are protruded thru the anus with defecation, later as they become larger they may remain outside till replaced; if not replaced an irritable sphincter may cause inflammation, strangulation, edema, and at times gangrene. In cases of long duration the sphincters may become relaxed, and the mass protrudes and will stay in only with the recumbent position. The chronically protruded mucosa becomes irritated and is prone to abrasion and superficial ulceration, and, consequently, irritation of the skin with resultant pruritis. With trauma and infection many cases of hemorrhoids undergo varying stages of fibrous change, obliterating the vessels in part; as a consequence, bleeding, which was the chief feature at the onset may be slight or absent when protrusion has developed.

Pain, although it occurs in some 85% of hemorrhoidal patients

is not a characteristic symptom of simple internal hemorrhoids, and seldom occurs until they protrude. It is severe with external trauma and intense with strangulation. With the hemorrhoids above the sphincter muscles there may be only a dull heavy ache or a sensation of weight, or there may be referred pains to other regions. Transient smarting or throbbing may occur at defecation but subsides soon after the protrusion has retracted into the rectum. A feeling of fullness in the rectum, obstruction of the outlet, and incomplete evacuation are frequent symptoms, especially in women with large internal hemorrhoids. The severe cutting pain, occurring at defecation denotes complicating anal fissure. Inflamed, thrombosed, or strangulated hemorrhoids are excruciatingly painful and very tender. The pain is throbbing in character and the patient's efforts to assuage it are usually futile.

Pruritis either from reflex irritation or an associated dermatitis, is present in about 25% of the symptomatic cases.

Constipation although mentioned an etiology may also be a symptom, as fear of bleeding and protrusion with resultant discomfort leads to postponement of the act of defecation.

There may be reflex symptoms such as headaches, neuritis, sciatica, backache, urinary tenesmus and dull pain over the sacrum. In men there may be pain in the testicle and in women dysmenorrhea has been noted. Referred pain is usually limited to the skin areas supplied by the upper four sacral nerves, but this is not always the case, as effacement of internal hemorrhoids may cause the disappearance of back pains, shoulder pains and headaches (see cases).

after stool, more or less tenesmus of the sphincter, bleeding after stool, plus evidence of a break in the mucosa upon rotating the anoscope. Ulcer with its associated hemorrhage and diarrhea is also noted upon examination. Cancer may be suspected by hemorrhage from higher up, digestive disturbances and diarrhea alternating with constipation. If a growth is not visible with the use of the anoscope, and symptoms are present which suggest pathology higher up, a proctoscopic and sigmoidoscopic should be done, and this supplemented by x-ray studies and observation of the patients stools. Peri-anal abscess is easily differentiated by the sudden onset, intense pain, swelling, redness and rise in temperature, plus the findings on examination. Prolapsus ani or recti may consist of a simple eversion of the anal mucous membrane, descent outside of the rectum of more or less of all coats of the rectum or descent of the entire rectum with more or less sigmoid. The mucous membrane in this case evidences no varicose veins; but is of a smooth velvety, reddish color, and there is also a distinct sulcus between the anus and the protrusion.

Many factors enter into the choice of treatment of internal hemorrhoids. The clinical condition of the piles must be ascertained, as to whether they are soft or indurated, reducible or irreducible, clean or septic and whether there is other associated pathology. Any important complication must be treated first or if both may be done operatively, they should be done at the same time. There is also the general condition of the patient to be considered. It must be determined whether there is heart, liver or abdominal pathology. In summary it may be said that treatment involves two things: that is,

treatment of the underlying condition and care of the acute manifestation.

Regarding the choice of treatment; at the present time the consensus of opinion is that about fifty percent of the cases of internal hemorrhoids are suitable for injection treatment. (Pennington, Gabriel, Best etc). Most suitable for injection treatment are the soft, prolapsing or vascular piles; patients with these can be promised rapid relief from symptoms and a cure quite as satisfactory and permanent as with the operative procedure. This method of treatment is not to be used for external piles or internal piles complicated by fissure, fistula, large external skin tags, thrombosis, ulceration or gangrene. These should be submitted to some operative procedure. Also, where the piles are very large and numerous, of old standing and with much fibrotic change it may sometimes be better to use the operative procedure. Uncomplicated internal piles are the only ones suitable for injection and as Allbright says, " The idea of universal applicability should never have been advanced for the injection treatment". Other factors that may influence the choice of the injection treatment are: age, old people not being such good operative risks, and where disease contraindicates operation that is severe cardio-vascular disease, liver pathology, renal disease, bedridden patients (paralysis), pregnancy and where the patient cannot spare the time or has not the economic means for hospitalization, or where the patient fears operative procedures and will not submit to that type of therapy. Taking all these things into consideration it will mean that the practitioner may inject from 70 to 80% of his patients

There are other secondary symptoms such as anemia, flatulence, and mental depression which often confuse the picture and lead to various forms of medical treatment..

There is a considerable variation in different patients: symptoms may be constant or intermitant, more or less severe, and many have well marked hemorrhoids without any symptoms.

The diagnosis of internal hemorrhoids is by three procedures: inspection, digital palpation, and instrumental examination. The patient is placed in the left lateral (Sim's) position and instructed to hold up his right buttock with his right hand. If hemorrhoids are not visable have the patient strain and this often brings the hemorrhoids into view. With external inspection it may be determined whether there is peri-anal irritation, bleeding, fissure or condylomata. By digital, and in doing this it should be remembered that hemorrhoids, if present are in the first two to two and one-half inches of the anal canal, so deep palpation is not necessary; it will be possible to feel polypa and some forms of hemorrhoids, then on palpation farther up, other forms of obstruction, such as carcinoma, may be noted. The reaction of the sphincter should be noted and any peri-anal swelling investigated. The anoscope is very important in diagnosis and with its use it is possible to determine the type of hemorrhoids present and to differentiate polypi, papillae, and hemorrhoids. Examination should include a study of the rectal wall for evidence of malignancy, ulceration, and any inflammation such as cryptitis and papillitis.

In the differential diagnosis; fissure is easily ruled out by the pain it occasions with bowel movement, which persists for several hours

complaining of hemorrhoids.

Before taking up the various procedures used in the active treatment of hemorrhoids it might be well to discuss the palliative method of treatment. When hemorrhoids are acutely inflamed, palliative measures are often indicated and radical measures left until inflammation has subsided. Early cases in constipated subjects having slight bleeding as the main symptom, should be treated by palliation. The bowels should be regulated by limiting proteins and adding green vegetables and fruit; mild laxatives and non-irritating cathartics to be used sparingly, agar agar and mineral oil being the most useful. Pure ichthyol on a glass rod, applied thru the anal canal, frequently will promptly check superficial oozing of blood, this may be repeated at intervals of three days. Ointments are often useful and are best dispensed in a collapsible tube with a special perforated tip (rectal nozzle). A good astringent ointment is

Rx

Ung. Acid. Tann. ℥ iv

Ung. Stramon.

Ung. Bellad.

au ℥ i

There are also the post-partem and postoperative cases and patients with severe constitutional disease, necessitating palliative treatment. The general treatment is rest in bed, hot wet dressings of mild astringents or sitz baths; and regulation of the diet and bowels. Prolapsed and thrombosed and sloughing internal hemorrhoids must be treated expectantly. It is a bad practice to operate on those cases as post operative ulceration is very liable to occur. The patient should be put to bed and an attempt should then be made to reduce the

prolapsed piles. This is usually effected by placing the patient on his left side, bathing the parts with cold water and applying vaseline. Then with the finger pushing up on the apex of the mass, the other hand returns the marginal swelling, first one side, then on the other. A firm antiseptic compress, with a pad of wool and T bandage, should then be applied. If there is too much sphincter spasm to allow reduction it may be necessary to apply locally a 10% cocaine solution or the injection of five cubic centimeters of benacoin into the posterior portion of the anal muscle. If the piles cannot be reduced, they, and the inevitable external edema should be treated with a compress soaked in a solution of 1-2000 perchloride of mercury, boric solution or lead and opium wash, that is,

Liq. Plumb. Subacet ℥ iv
 Tr. Opii ℥ iiss
 Aq. Dist. qs ad ℥ iv

The moist compresses should be applied at three to four hourly intervals, together with irrigation with hydrogen peroxide solution morning and evening. Rapid improvement generally results and a most appalling mass of sloughing piles will often completely disappear in the course of a few weeks. Spontaneous cure may follow or more active treatment may be resorted to. Some patients who absolutely refuse more radical measures will submit to injection or cauterization. Irritants such as glacial acetic acid, chromic acid, and saturated silver nitrate have been used. The puncture of the mass in various places by means of an electric needle as advocated by Kelsey will temporarily relieve the symptoms.

THE INJECTION TREATMENT

The advantages of the injection method are that it can be used as an office procedure, it is practically painless and requires no anesthesia, there is not disability or loss from work, no hospitalization expense and with proper selection of cases and good technique the results are excellent.

The solution usually used is a five percent solution of phenol in cottonseed oil or almond oil. The latter is advocated because it can be used through a finer needle and appears to be more completely absorbed. Others prefer the cottonseed oil because it seems to keep better.

In preparing the stock solution, one pound of dry phenol crystals (C.P.), is placed in a clean dry laboratory flask and to this is added one pint of chemically pure oil. The flask is then placed in a water bath, heated to boiling and stirred gently with a glass rod until the crystals dissolve. This is now labeled, " Stock solution, 50% phenolized oil - poison ". The injection solution is then made up as required by measuring out two ounces of the stock solution into a glass graduate and adding to this eighteen ounces of (C.P.) oil. This is stirred well and labeled, " Injection solution - 5% phenolized oil". If there are any crystals in the stock solution, it should be heated before making up the injection solution. The bottle of injection solution should be shaken before use to be sure that the phenol is equally distributed. It should be remembered that this is an

anhydrous solution and all vessels and syringes used must be free from moisture as the water will take up the phenol and make a more concentrated solution.

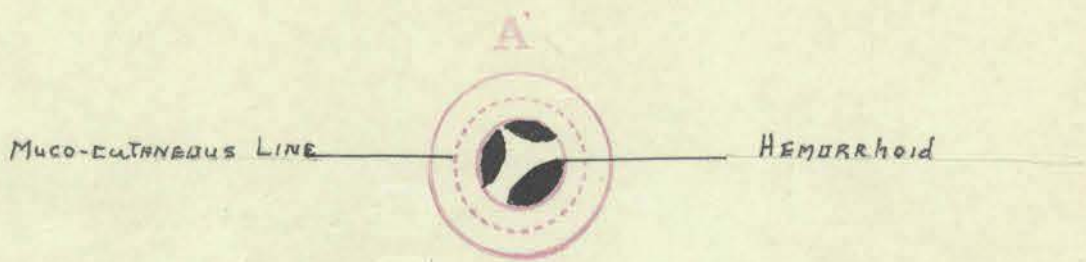
Dukes studied microscopically the pathological changes provoked by carbolic acid injection into ten patients. In each of these patients one hemorrhoid was injected in the usual way. The injected hemorrhoid and a control not injected were removed by operation; in one patient one day after injecting and in the remaining patients, from two to twenty-one days subsequent. He concluded that carbolic acid, being a powerful irritant to the tissues, initiates an aseptic inflammation, characterized by dilatation of the vessels, emigration of leukocytes and transudation of lymph. By these means the alien liquid is diluted and removed, therefore the inflammation quickly subsides. The early inflammatory changes which occur in the first three days do not play any important part in the cure; it is the secondary changes, in particular the intravascular clotting, and subsequent fibrosis, to which any beneficial effect must be ascribed.

The standard equipage for injection consists of a tubular speculum of the Kelly type, a suitable syringe and needle, a pair of long Spencer-Wells forceps, a small bowl with cotton wool swabs, a bowl for used swabs, a small medicine glass for the injection solution, a tube of K.Y. jelly and a good form of illumination. It is best to use a ten c.c. Luer Lok syringe and a special needle such as the B & D hemorrhoid needle, setting the guard for about one-fourth inch. The Down Brothers needle is a straight needle, five and one-half inches in length, with a wide bore as far as the terminal

portion. The terminal portion is of the usual bore, made of nickel, and fitted with a guard. There is a bayonet catch on the syringe to prevent the needle from slipping off. When the needle becomes blocked, screw the guard on as far as possible, reverse the needle, insert the nickel or gold portion in the nozzle of the syringe and forcibly squirt water from the syringe. Some of the water goes through the needle in the reverse direction and displaces the particles in the bore. The Goldbacher needle consists of a strong winged hub and shaft of rustless metal, three and three-fourths inches long with about one-sixteenth inch inside diameter. At the end of this shaft is fixed a number twenty gauge gold needle, one inch long. The sheath, also of rustless steel is made to fit snugly and slide easily over the shaft. A thumb screw on the sheath determines the length of needle exposed. The greater portion of the shaft is of wider caliber, offering less resistance to the flow of the injecting fluid.

Before beginning injection treatment any associated pathology should be treated. The bowels should be regulated and any acute manifestations treated by palliative methods.

The patient is placed in the Sims position and if the hemorrhoids are prolapsed they are returned into the rectum. The mucous membrane is usually painted with acetone-mercurychrome. The syringe is then filled with solution before putting on the needle and the most prolapsing and vascular pile is injected first. It is quite necessary to have accurate record as to the site of the hemorrhoids and of the place of injection. Gabriel has developed a good diagram for this. Three c.c. of 5% phenolized oil is injected under the mucous membrane



above the pile area; the solution can be seen spreading in the submucous layer and forms a swelling perhaps an inch or more in diameter. The solution is injected between the blood vessels and the plunger of the syringe should always be pulled back to see if the needle is in a vein before injecting. If a pure white spot appears at the site of injection the needle is too superficial; if no bulging appears, it is too deep. A further injection of two c.c. is made a little lower but in the same quadrant, however, still not into the main pile substance, the idea being to get the tributaries of the hemorrhoidal varicosities, and also to stay above the anal valves and papillae; the mucous membrane being very sensitive there. After injection the instruments are quickly withdrawn to relieve internal tension and prevent escape of oil. This completes the first treatment and the patient is instructed to take mineral oil once a day, and to reduce any prolapse immediately after defecation. The patient might also be instructed to inject Hamamelis water into the rectum following defecation for ten days to two weeks after the first treatment to reduce the chance of infection. Goldbacher believes in injecting large rather than small doses of phenolized oil, his usual

dose for a first treatment being eight to ten c.c. Care should be exercised and not too much oil should be injected in one place as oil tumors or prolapsing nodules may result.

Subsequent injections may be given twice a week; many prefer to have the patient return once a week until the treatment is finished. If the patient returns a week after the first injection the examining finger will detect a firm induration at the site of injection and a notable improvement. The changes in the hemorrhoid are illustrated in figure four. The second injection is into the most noticeable remaining pile and four to eight injections are usually given before satisfactory results are obtained. The patient is told to return for checkup in one month and three months. The only complaint following an injection is a feeling of fullness in the rectum due to local swelling which persists for from twenty-four to forty-eight hours; this rapidly subsides. Slight itching sometimes occurs and if so may be the result of too superficial an injection, too much solution being injected in one place or to associated infection. No particular harm results in the majority of such cases but they should be avoided. Usually there are no complications and recession takes place in from three to five days. As inflammation subsides, fibrosis takes place and the tumor diminished in size. In two to three weeks there is only an indurated ridge which by microscopic ~~shows~~ would show fibrous tissue.

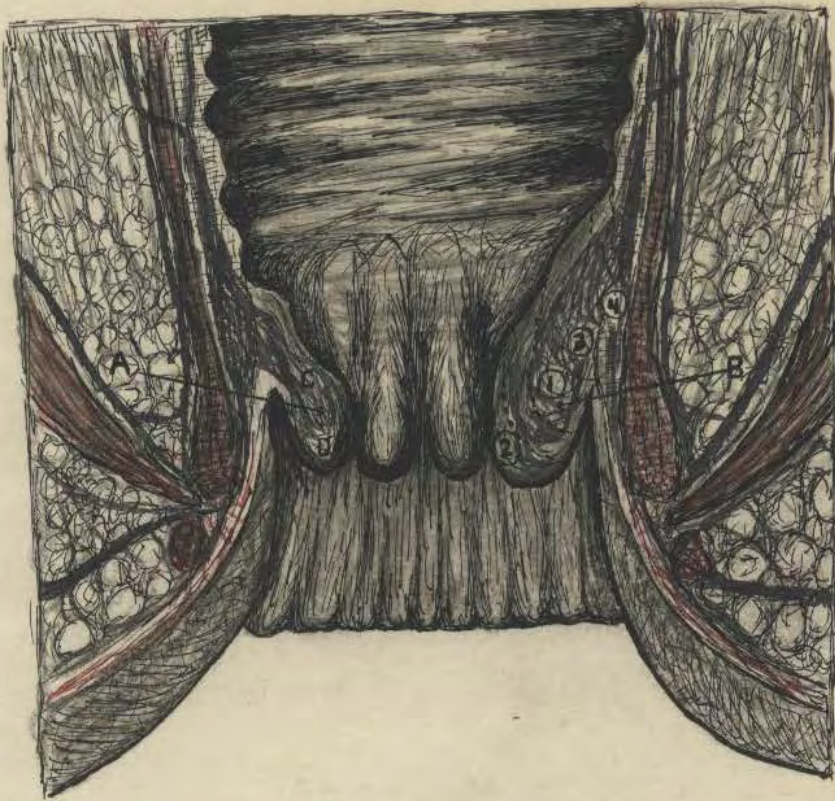


Fig. 4 Longitudinal section of the interior of the rectum showing internal varicose hemorrhoids:

A. Hemorrhoid untreated

B. Showing the successive stages through which the hemorrhoid passes after injection:

B 1. Hemorrhoid before injection

B 2. Hemorrhoid dilated, immediately after injection
of phenolized oil

B 3. Injected hemorrhoid shrunken until it has almost
disappeared

B 4. Injected hemorrhoid completely gone. The mucous
membrane is firmly adherent to the muscular layer of the
rectum

C. Proper site for injection of solution

D. Improper site for injection of solution

(From Goldbacher)

PRE-OPERATIVE TREATMENT AND ANESTHESIA

Local anesthesia is used by the majority of operators in the surgical treatment of hemorrhoids. Some prefer the sacral anesthesia in that they get better relaxation and an absolutely painless operation. In the local, the needling carries with it some pain and discomfort as the anal region is very sensitive to pain. Both of these methods will be discussed. Other methods used are: that of Gabriel, using a low spinal, injecting into the lumbar theca with the patient in the upright position; and Lockhart Mummery, who prefers a combination of avertin and local or gas and oxygen.

Preparation of the patient: The patient should be instructed to eat lightly the day before operation and some surgeons advocate a mild laxative thirty-six to forty-eight hours before operation. The evening before operation, the patient is given colonic irrigation with warm normal salt solution until it returns clear. If the operation is scheduled for mid-morning it may be best to give the colonic irrigation early the same morning. The peri-anal and gluteal regions are then shaved and the operative region scrubbed with soap and water. No preliminary sedative is necessary but most operators use a quarter grain of morphine by hypo or six grains of sodium amytol by mouth. Just before operation the rectum and surrounding areas are washed with a one percent lysol solution; this is done after the anesthetic has been given. The operative field is then painted with some antiseptic such as acetone-alcohol-mercurochrome.

Position of patient: The patient is placed in the lithotomy position, with the legs in stirrups and the hips well down, if one desires to give a local. This may also be used for the operative position, or the patient may be placed in the left lateral or Sims position.

Material for local injection: Three needles are used; a small one for the skin, and five and ten centimeter ones for the deeper structures. One-half percent (0.5%) novocaine with adrenalin is used as the injecting solution.

Anatomy: The practical point is that the internal pudic nerve breaks up into many fibers before entering the field and the most sensitive area is the region of the muco-cutaneous line in the anus.

Technique: With the finest needle, intradermal wheals are raised about two finger-breadths from the anus on the right and left side. The patient is to be warned of the introduction of the needle. The five centimeter needle is now put on the filled syringe and introduced by way of one of the lateral wheals through the skin in the subcutaneous tissue. Novocaine is then injected under the skin with the needle advanced first toward the perineum and then toward the coccyx. This is repeated on the other side. Thirty cubic centimeters are used for complete subcutaneous circular injection. The plunger of the syringe must be kept in constant motion to avoid pain. About five minutes is consumed in this infiltration. The ten centimeter needle is now put on the filled syringe and the left index finger introduced into the anal canal until the tip of the finger can be gently hooked around the upper border of the internal sphincter muscle. Keep on injecting

till the end of the needle is opposite the end of the finger in the rectum. The needle is not palpated by the finger in the rectum as it is about half an inch away from the bowel. The same process is then repeated except the point of the needle inclines first anterior, then posterior, so the wall of anaesthesia is complete on each side. About one ounce of one-half percent novocaine-adrenalin solution is injected on each side.

The skin over the perineum is now insensitive to pain so the long needle is now introduced just in front of the anus and about five cubic centimeters of solution is injected between the sphincter and perineal muscles anteriorly. A posterior puncture is also made, and about ten cubic centimeters solution injected just outside the sphincter muscles. This anaesthetic will last about two and one-half hours and gives a fair degree of relaxation.

For sacral anesthesia, from one to three ounces of one, two or three percent novocaine solution is introduced into the sacral canal, through the sacral hiatus. Lewis, recommends forty cubic centimeters of two percent (2%) novocaine with adrenalin, slightly warmed, injected slowly into the sacral canal. Complete relaxation occurs in about eleven minutes and the anesthesia last forty-five minutes or better. This method because of the complete anesthesia and good relaxation seems to be an excellent one.

As to the type of operation there is a considerable variation of opinion as regards the most suitable method. However, that the best operation in the world may be poorly done, and the poorest give excellent results if proper after care is exercised, is certainly true of hemorrhoidectomy. Apparently the standard methods of operation are; the clamp and cautery, ligature, and the clamp and suture procedures. These will be discussed and a resume will also be given of the use of the high frequency current in the treatment of hemorrhoids.

The clamp and cautery method is held in high favor in some places, notably in America; being advocated by such men as Syms, Babcock, and Yeoman. The ligature method is in higher favor in England, especially at the St. Mark's of London, where such men as Graeme Anderson and Gabriel sponsor this method.

THE CLAMP AND CAUTERY OPERATION

With the patient preferably in the lithotomy position, the legs being held in stirrups and the hips well over the end of the table; each hemorrhoid is grasped with an Allis forceps at its lower pole. Each hemorrhoid is thus secured before beginning operation. Now all forceps except the one on the most dependant pile are held up by an assistant. The pile to be treated is then grasped by a second forceps, near its inner pole, bringing the entire tumor under perfect control of the surgeon. If no redundant anal skin is present, the tissues at the muco-cutaneous line are divided with scissors and the pile elevated. Only the hemorrhoid is to be removed, and, if present, any redundant anal skin immediately external to it. A v shaped section of skin is dissected up to the outer pole of the pile. The base of the hemorrhoid is then snipped for a distance of about a centimeter and a Henry Smith or Gowlland hemorrhoid clamp is then applied tightly to the base of the pile and always in the long axis of the gut. The heel of the clamp is toward the lumen to place greatest pressure over the blood supply, and the thumb screw set. Care should be exercised not to get any skin in the clamp. A split compress wet in saline is placed beneath the clamp to protect the underlying tissues. The pile is cut off about one-fourth inch superficial to the clamp and the stump charred slowly by an electric or paquelin cautery, heated to a dull red. The clamp is released slowly to detect any bleeding points. There is seldom any but slight oozing at the anal margin where the skin

was divided. Any bleeding vessels there are clamped and touched with cautery or tied with fine catgut. Each pile in turn is treated in the same way. A strip of mucous membrane should always be left intact between pile areas.

THE LIGATURE METHOD

In removal by ligature, the Salmon operation, the lateral or lithotomy position may be used, the former with local and the latter with general anesthesia. If the sphincter is hypertonic it is gently dilated. Some surgeons advocate division of the sphincter just ~~to~~ on one side of the posterior commissure. A clip is then applied to the outer end of each hemorrhoid, and fanwise traction on them exposes all of the piles for their entire length. The Allis forceps seem to be the most useful as holding clips, in that they are light but still hold firmly with a minimum of tissue injury. While an assistant holds the remaining forceps, the operator elevates the lower-most pile and divides with scissors the muco-cutaneous margin (Salmon's scissors are useful for this procedure). The hemorrhoid is dissected up and the mucous membrane divided part way on each side until only a pedicle remains at the inner margin of the hemorrhoid, which contains the central artery and vein. A stout ten inch ligature of celloidin linen or a number ten plaited silk is then placed around the pedicle, and, while an assistant makes traction downward the ligature is tied very tightly, in a surgeons knot, as high up as possible. The knot is toward the lumen. ^{*Herosch*} Some advocate ~~ablating~~ ablating the pile at this point, others snip off the apex of the pile, and still others, such as Lewis, say to leave the pile to sluff off as this prevents slipping of ligatures and grave secondary hemorrhage. The ligature is usually knotted about three inches from the anus and

and left protruding and the pile ablated, making certain that sufficient stump remains to hold the ligature. The ligatures usually sluff away on the eighth to twelfth day. Each hemorrhoid is removed in turn, the most dependant first and so on. When two hemorrhoids have coalesced they are treated as a single pile, but are transfixed with a double ligature. It is seldom necessary to treat more than three areas, namely, the right and left posterior, and right anterior quadrants. This is the usual distribution of internal hemorrhoids.

An added precaution is to place the ligatures at different levels to avoid narrowing of the lumen. After ligating the internal hemorrhoids any external ones present are cut off and redundant anal skin treated. After removal the tissues beneath the operative wounds may be infiltrated to a moderate degree with 0.03% quinin and urea hydrochloride solution (Hirschman - Yeoman), the prolonged anesthetic effect of this drug minimizing after pains; however, it may retard healing.

THE CLAMP AND SUTURE METHOD

The anal margins are pulled apart with retracting clamps and the first hemorrhoid to be removed is grasped with a straight clamp, after which ^{the} a retracting triangular clamp attached to the external margin of this internal hemorrhoid is replaced by a straight clamp. This clamp draws the marginal varicosities together in such a way as to make it easier to estimate the amount of tissue to be removed as well as to facilitate removal. With a pair of curved scissors the external deformity is dissected up along the subcutaneous veins. This dissection is carried just beyond the pectinate line and cleans out all the varicosities under the anal margin on that side. Following this, a crushing clamp is applied to the hemorrhoid at sufficient depth to eliminate the possibility that any hemorrhoid tissue or redundant skin and mucosa may be left beneath the clamp. A ligature on a round curved needle is carried through and tied above the clamp with number one plain catgut, after which the hemorrhoid is cut away. Two loops are carried through this strip of mucosa and over the jaws of the clamp in such a way that the clamp may be slipped out and the sutures drawn tightly together and tied. The clamp is in position until the first loop is tied above it. Then the hemorrhoidal tissues, skin etc. are cut away along the upper surface of the clamp. Unless bleeding noted, further suturing is unnecessary.

After each hemorrhoid and adjacent margin has been treated in this manner, the operation is completed by suturing the stumps into

the wound margins. There are no sutures into the edges of the wound, all sutures being buried.

THE HIGH FREQUENCY CURRENT

There are four distinct variations of the application of the high frequency current in the destruction of hemorrhoids,

Most authors govern the type of current used by the amount of redundant tissue. If but a small varicose area, the Oudin type of current is used, until a complete dehydration of the area occurs. The action of this type of current may be intensified by grounding. This is done by placing the patient upon a large metal electrode which is connected to a stem radiator or to a water pipe. This is electro-dessication. The destructive action here is not as intense as in electro-coagulation.

Fulguration is the showering of sparks from the tip of a pointed electrode held a short distance away from the tissue. The action of this procedure is a superficial carbonization, and therefore little employed.

The electric cutting current does not have sufficient coagulating power to seal the severed vein ends. It must therefore only be employed after the base of the hemorrhoid about to be removed, has been coagulated.

The procedure generally used of these is electrocoagulation. A bi-terminal current is used, with the same hookup as the usual medical diathermy, except the current concentration is much greater producing an actually destructive action. When a high frequency current is passed through tissues, its electrical energy is converted into heat energy. The heat developed in the tissues varies directly as

their resistance to the current, and is easily raised to the point of coagulation. The principle involved, therefore, differs from burning with the actual cautery by which the heat is applied from an external source and penetrates only slightly. The bi-polar current (d'Arsonval) used should be of low voltage, high amperage and very high frequency.

An indifferent electrode of block tin, about eight inches square is so placed that the patient's hips rest upon it, and it is connected to one pole of the machine. To the other pole is connected a Bierman clamp, which is, in effect, two parallel, active, insulated electrodes. This special clamp limits the coagulation to the tissues between its metallic edges. A foot switch control is used. Each hemorrhoid is grasped in turn by forceps and the pile clamp so held as to slightly compress its base in the long axis of the bowel. The current is turned on until the base of the pile is coagulated to a thin long pedicle of light grey color. Then, with an electric knife, attached to one end of the clamp, the pile superficial to the clamp is cut off. Histologic examination of tissue destroyed by means of electro-coagulation shows hyalinization with complete loss of cellular outline.

The pointed active electrode is used where the tissues cannot be grasped by the electrosurgical clamp, or where the operator does not wish to remove the hemorrhoid, but wishes to cause coagulation of the blood in the hemorrhoid and consequent absorption and fibrosis. The needle is inserted into the summit of the pile and the foot switch

pressed for twenty seconds. Release the switch before withdrawing the needle. While the current flowed through the mass the fluid therein was heated to boiling, causing injury to the wall, coagulation of the blood and resultant absorption.

POST-OPERATIVE DRESSING AND TREATMENT

Immediately after operation, one to two ounces of warm sterile vaseline or some medicated petroleum dressing should be injected into the rectum by means of a metal syringe or grease gun. This prevents irritation of the raw bowel surfaces and prevents dry crust formation. Much credit should be due to such men as Best and Hill in doing away with the old idea of the necessity of inserting stiff rubber tubes and other sorts of irritating drains following operation. These were very painful and did nothing but harm in that reflex peristalsis was soon set up with resultant discomfort and as far as acting as drains, they were unnecessary with proper pre-operative treatment.

It is desirable to have the first bowel evacuation on the morning of the third post-operative day and at that time six to eight ounces of warm cottonseed oil should be injected into the rectum. If no results are obtained within the hour, a further injection of a pint of normal salt should be given. There is no indication for sedative drugs in the intestinal tract during the first three days as peristalsis usually subsides following operation due to reflex shock.

After injecting the vaseline dressing a V shaped piece of sterile gauze is placed over the anal orifice . Several layers of gauze are placed on top of this and a cottonflannel T bandage is then applied over this. The dressing may be changed five to six hours after operation, removing the pad and placing a smaller piece of fluffy gauze over the anus and applying the bandage loosely.

After the operation the patient rests in bed upon the back with pillows beneath the thighs and buttocks, or may lie on either side as is most comfortable. A hypo of a quarter of morphine is administered as soon as any pain is complained of. Repetition of this is seldom necessary. Codein phosphate in half grain doses suffices for later pain, but aspirin, ten grains, or pyramidon, five grains, is often preferable. Pressure of a distended Bladder aggravates the patients discomfort and if the patient cannot urinate in the restricted position; if the patient is a man, allow him to stand by the bed; and, if a female, let her get in the kneeling position in bed and they can usually void. If twelve to eighteen hours pass without voiding and other methods fail it may be necessary to catheterize. Care should then be exercised to prevent cystitis, and urinary antiseptics should be used. Post-operative irritation about the anus may be relieved by the application of nupercaine ointment. Hot packs over the anal region are also comforting. The diet should be restricted till the bowels move. Water is given freely, clear tea, coffee, chicken and lamb broth with rice or noodles, toast, crackers and gelatin jellies are suitable. Milk should be avoided as it has a high residue. On the third post-operative day the patient receives a soft diet and on the fifth day is on a regular diet.

The patient usually leaves the hospital on the fifth to the seventh day and may usually resume an ordinary occupation one week later. On the tenth post-operative day the gloved index finger, lubricated with ten percent ichthyol ointment is passed into the

rectum to smooth out granulating surfaces and to guard against stricture; this is repeated once a week for four to five weeks. During convalescence some tonic, such as iron, quinin and strychnine, may be prescribed.

POST-OPERATIVE COMPLICATIONS

After properly performed operations, post-operative complications are trivial, but they do occur.

Probably the most frequent is difficulty in micturation. This is greatly reduced in cases where no rectal packing or tubes are used. Spinal anesthesia also seems to be an etiological factor. The most important factor here is the reflex shock. If methods mentioned under post-operative treatment do not cause the patient to urinate and one wishes to avoid catheterization, it may be found advantageous to administer five grains of urotropin. If the operation has been performed in the morning and the patient is uncomfortable in the afternoon, the urotropin should be administered; and in about an hour, in a large number of cases, the patient will be able to void. A catheter should be used only as a last resort.

Secondary hemorrhage usually results from slipping or too early separation of a ligature or the opening of a vessel when the slough comes away. All of these but the latter are avoidable by proper technique, non-absorbable ligatures tied tightly in a square knot, and, for large pedicles, transfixion and double ligature. With the clamp and cautery method, severe hemorrhage may occur immediately after operation unless the operator makes certain that all actually bleeding points are controlled. Later hemorrhage after the clamp and cautery method is rare, but may occur when the slough separates on the seventh to eighth post-operative day. If there is considerable hemorrhage

the best plan seems to be to pack the bowel. Firm packing and the gauze moistened with some styptic such as alum, adrenalin or glycerite of tannic acid usually suffices to control this complication. Any bleeding points should be ligated and if the area is not definite a suture may be taken into the surrounding tissue en masse.

Painful defecation when the bowel is first opened may be mediated by having the patient sit in a sitz bath before attempting the act. This relaxes the sphincter which is usually in the state of tonic contraction at this time. This is usually unnecessary, however, if the procedure is carried out as described under post-operative treatment.

Peri-anal edema and skin tags occur in a small fraction of cases and are usually relieved by hot packs. Small inflamed tags usually shrink of their own accord. If quite large they should be removed under local about ten days post-operative, snipping them off with a pair of strong scissors, flush with the skin.

Fissure may develop due to the passage of large masses of feces, and this is prevented by careful post-operative treatment, that is, vaseline per rectum and mineral oil per mouth.

Infection and sepsis should not occur with proper operation and proper pre-operative and post-operative care.

Stricture occurred quite frequently following the Whitehead operation, and mild degrees of stenosis may occur in the other operations if too great an area of the anal canal is denuded or if strips of mucous membrane are not left between pile areas. Digital dilatation as described under post-operative treatment will prevent

this complication.

Incontinence is a rare complication and may result from divulsion of the sphincter by too rapid manual dilatation or following resection of too much tissue as in the Whitehead operation.

SUMMARY

In a resume it may be stated that external and internal hemorrhoids will be seen in a considerable proportion of the cases in general office practice.

The etiology should always be investigated and any causitive or associated pathology treated. Should there be any doubt as to the presence of malignancy or other pathology higher in the colon, proctoscopic, sigmoidoscopic, and x-ray studies should be made.

External hemorrhoids are to be treated by operative means only.

Uncomplicated internal hemorrhoids may be treated very satisfactorily, in office practice, by the injection of five percent phenol in almond oil.

Complicated internal hemorrhoids may be submitted to hospitalization and operation with good results.

Hemorrhoids are very amenable to treatment and with proper technique the procedure should occasion little discomfort to the patient, whether with injection or operative methods.

Recurrences occur, but only in a very small percent of the cases if the etiology is corrected and the treatment is properly done.

CASE RECORDS

+ Case I. Miss N. S. aged 50 a teacher

Symptoms: Bleeding, protrusion, constipation and "weakness". Some bleeding after defecation for the past ten years. Recently worse, with occasional bleeding between bowel movements,

Protrusion constantly present. Patient has tried to replace protrusion at times, but found that it soon returned, so that she "does not touch it much", at present. Worse after defecation. Pain, not severe, but more or less constant.

Has been constipated all her life. Takes Epsom salt every morning. Feels weak and nervous, and complains of indigestion. There is a constant "yellowish pink" discharge and some itching. Fistula operation seven years ago under local anesthesia. Was advised that an operation for hemorrhoids was unavoidable.

Examination: Externally there is seen a large prolapsed internal hemorrhoid. It is deep red in color, about the size of a cherry, and it is covered with mucous membrane. It may be returned into the rectum with some difficulty. Straining downward causes its return to the outside.

Internal examination: reveals large internal hemorrhoids. They are bluish red, and bleed easily when touched. When viewed through the anoscope-speculum, with the slide open to the pectinate line, hemorrhoids protrude through the window of the instrument at any point at which it may be placed. No evidence of fistula seen.

Treatment: Eight injections of phenolized oil were given, at five day intervals, where indicated, mineral oil, one tablespoonful each night, was advised to relieve constipation.

Results: Bleeding ceased and protrusion was less after the second treatment, protrusion was entirely gone and it did not recur after the fourth treatment.

Inspected, three months, six months, and one year after discharge. The hemorrhoids, as well as the symptoms, have entirely disappeared. The anoscope-speculum may be rotated in a complete circle with the slide with drawn and the mucous membrane is noted to be pink and firm. There is no bulging through the window of the instrument at any point.

Diagnosis: Internal hemorrhoids - third degree

Comment: This was a mild type of third degree hemorrhoids. It is particularly interesting to note that the digestive and nervous symptoms disappeared, and there was a general improvement in the patients health.

† Case 2. Dr. M. P. aged 40, physician

Symptoms: Protrusion and bleeding for more than ten years. Constipated all his life.

Protrusion occurs after each bowel movement and is not easily replaced. In order to reduce the protrusion it is necessary for the patient first to assume a dorsal position, with hips elevated. He then anoints the hemorrhoids with petrolatum and slowly replaces them. Bleeding occurs only after defecation and is not severe. There is no pain or discharge.

E Examination: Externally negative, except when the patient bears

down. This action causes protrusion.

Internally, marked hemorrhoids are noted. The mucous membrane is of a fairly healthy appearance.

Treatment: As it was necessary for the doctor to return to his home in a distant city as soon as possible, large injections of phenolized oil were used at short intervals.

Five treatments were given over a period of seventeen days as follows:

First injection: Eight c.c., right anterior quadrant; seven c.c., right posterior quadrant.

Second injection: Ten c.c., right posterior quadrant; nine c.c., left posterior quadrant.

Third injection: Ten c.c., right side; ten c.c., left side.

Fourth injection: Ten c.c., right side; seven c.c., left side.

Fifth injection: Five c.c., anteriorly; three c.c., right side; two c.c., left side.

Results: Bleeding ceased after the first treatment. There was no protrusion after the second treatment. Hemorrhoids nearly gone when inspected before the fifth treatment.

Diagnosis: Internal hemorrhoids, second degree.

Comment: This case illustrates the "large dose method" of injection. It will be noted that this patient received eight-one c.c. of phenolized oil in seventeen days. There were no untoward effects of any kind, although the writer believes it advisable to make injections at weekly intervals if possible, rather than as closely as above.

† Case 3. Mrs. N. W., aged 35, housekeeper

Symptoms: Pain, constant, but much worse after defecation.

Duration, more than three years. Bleeding after defecation at times.

No protrusion or discharge.

Examination: External examination shows a posterior fissure in ano about three-eighths of an inch in length, leading into a sentinel pile.

Novocaine, 2% solution, was injected into the base of the fissure to permit insertion of the anoscope-speculum. Hemorrhoids are visible internally.

Treatment: Division and incision of the fissure under nitrous oxide-oxygen anesthesia, with removal of the sentinel pile. This was followed in one week by a series of five injections of the internal hemorrhoids, at weekly intervals.

Results: Symptom free. Hemorrhoids have disappeared.

Diagnosis: Fissure in ano. Internal hemorrhoids, first degree.

Comment: The presence of fissure in ano does not contra-indicate the use of the injection method, as stated by some writers.

† Case 4. Mrs. F.T., aged 36, housewife

Symptoms: Constipation, backache. Bleeding, protrusion and rectal pain are absent. The pain across the lower part of the back is of about two years duration. It has not responded to any previous medication or treatment.

Examination: Large internal hemorrhoids are noted.

Treatment: Eight injections of phenolized oil were given at weekly

intervals, in the following doses: 8, 10, 10, 8, 6, 2, 3, c.c., plus 2 c.c. mineral oil per diem for constipation.

Results: Backache somewhat relieved after the second treatment. Gradually improved, and has been absent since the fifth treatment. Bowel movements are also normal and regular without laxatives.

Diagnosis: Internal hemorrhoids, first degree.

Comment: This patient had received treatment for nearly two years without results. She had never had a rectal examination. As her backache has now been absent for six months, and as there had been no remission during the two previous years, we may infer that this was referred pain caused by the internal hemorrhoids.

† Case 5. Mrs. B. T., aged 58, housewife

Symptoms: Pain in the rectum and across the back. Bleeding only occasionally and not severe. No protrusion. Itching not constant, but very annoying at times.

Examination: Three large skin tags. Internal hemorrhoids.

Treatment: Eight injections of phenolized oil. Skin tags removed under local anesthesia.

Results: Symptom free. Hemorrhoids gone.

Diagnosis: Internal hemorrhoids. External cutaneous hemorrhoids.

Comment: In this case, hemorrhoids were evidently the cause of the itching, as this ceased with the disappearance of the hemorrhoids.

† Case 6. Mrs. B. W., aged 60, housewife

Symptoms: Patient consulted the writer "for the relief of piles". Bleeding only after defecation. Duration over one year and recently

more severe. " Has had piles for about twenty-eight years, since her second child was born". Had " Inflammation of the bowels", several times. No protrusion or discharge at any time, no appetite. Feels weak and ill. Has headaches.

Bowel movements, about twenty daily. These are thin, scant and pinkish. Takes mineral oil and other laxatives every night. Has no movements unless she takes some laxative nightly. Pain, more or less constant, situated in the lower rectum. Pain is worse just before bowel movements.

The patient had visited several physicians and had received medication, internal and local. She had a series of x-rays taken. The reports of which were entirely negative, except for " chronic constipation". Report reads: " This examination definitely rules out any lesion of the descending colon, sigmoid and rectum".

Examination: The patient appears pallid, emaciated, weak, depressed and cachectic. Local external examination negative.

Internally, digital examination negative. Anoscope-speculum reveals large purplish hemorrhoids with several eroded spots, which bleed when touched. As the field is cleansed with cotton, it is noticed that a pinkish, serous fluid appears from above the hemorrhoidal area.

Proctoscopic examination negative, except for the pinkish fluid from above.

Sigmoidoscopic: Sigmoidoscope passed easily to the rectosigmoidal junction, where there is an apparent obstruction, although nothing definite is visible. The pinkish fluid appears to be more abundant here. The instrument cannot be made to pass this obstruction.

Patient was referred to another x-ray laboratory from which was received the following report of radiogram following barium enema:

" Obstruction at rectosigmoidal junction which barely permits passage of barium through a narrow channel. Probably malignancy.

Results: Patient was operated upon and carcinoma removed from the rectosigmoid junction. Colostomy performed and patient comfortable at present time (eight months after operation).

Diagnosis: Rectosigmoidal carcinoma associated with internal hemorrhoids.

Comment: The above case is described in detail to show the necessity for complete examination. As the patient stated, she had hemorrhoids (due at least in part to constipation and straining caused by the obstruction above). Treatment of her hemorrhoids would, of course been useless. It shows how important are the observations, that "The presence of one rectal condition (hemorrhoids in this case) does not preclude the presence of another", and " A patients self-diagnosis must never be accepted without complete examination.

† Case 7. Miss F. S., aged 48, nurse

Symptoms: Patient consulted the writer for relief of " sticking piles"; said that she had not visited a physician before because she feared an operation. No bleeding, protrusion, discharge, or itching. Her sole symptom was occasional sticking pains in the rectum.

Examination: Hemorrhoids were absent, although the mucosa was somewhat relaxed. There was one greatly elongated and inflamed papilla

and one smaller one.

Treatment: These were removed by crushing, ligature, and excision under local anesthesia.

Results: Symptom free.

Diagnosis: Papillitis.

Comment: This case again shows erroneous diagnosis made by the patient, and the relief obtained by proper treatment.

†Case 8. Mrs. H. K., aged 29, housewife

Symptoms: Bleeding and protrusion for over three years. Soreness, but little pain. Is constipated. No discharge or itching. Two years ago had a series of injections of quinine and urea hydrochloride. These gave her some relief for about six months, especially from the bleeding. She does not believe that the treatment affected the protrusion, as this has been present constantly and returns almost immediately when replaced.

Examination: A ring of prolapsed internal hemorrhoids, and external connective tissue hemorrhoids, completely encircle the anus.

Internally there are large hemorrhoids rather lobulated in appearance, evidently due to connective tissue stroma within. Some of the hemorrhoids are continuous with those situated externally.

Treatment: Eight injections of phenolized oil were given, totaling 64 c.c. Injection was difficult, due to the connective tissue present, the result of the previous injections. It was noticed that the hemorrhoid resisted admission of oil until unusual pressure was exerted upon the piston, after which it would be seen to "Give", suddenly and fill with oil. It was evidently necessary to break old adhesions

to admit the oil.

Results: Bleeding ceased after the second treatment. Protrusion gradually decreased and was gone after the sixth treatment. The skin tags were permitted to remain.

Diagnosis: Mixed hemorrhoids, internal hemorrhoids third degree, and skin tags.

Comment: This case was selected to show the efficiency of the oil injection treatment in a very severe case of hemorrhoids, after the failure of quinine and urea hydrochloride.

† Case 9. Mr. T. C., aged 50, clerk

Symptoms: Severe pain and large swelling about the anus. Onset was sudden. Duration, two days. No other symptoms.

Examination: There is a large, tender swelling to the left of the anus. Interior of rectum is normal.

Treatment: Uncapped the external thrombotic hemorrhoid, and removed several blood clots under local anesthesia.

Results: Symptom free.

Diagnosis: External thrombotic hemorrhoid.

Comment: An uncomplicated case with no ascertainable etiology

† Case 10. Mrs. B. T., aged 43, housewife

Symptoms: Protrusion, bleeding, pain and constipation. Duration of over six years. Recently symptoms have become worse. Requires laxatives daily. Also used enemata frequently. Believes that she has cancer.

Examination: Externally negative.

Internal examination: Internal hemorrhoids. On the posterior rectal wall about two inches from the anal opening is a pedunculated polyp about three-fourths inch in diameter.

Treatment: The base of the polyp was injected with 2% novocaine solution, ligated and excised. Eight injections of phenolized oil at five day intervals were used in the treatment of the hemorrhoids.

Results: The patient is symptom free. Rectal pathology is apparently gone.

Diagnosis: Rectal polype. Internal hemorrhoids, second degree.

Comment: Apparently constipation was due to mechanical obstruction by the polyp and to the hemorrhoids, as the bowels became normal following treatment and have remained so. The patient required no laxative since discharge. The hemorrhoids were perhaps due to the straining occasioned by obstruction of the polyp

Case 11. H. P., aged 32

Always in good health but constipated, during the three months before consulting me had passed fresh blood and tarry clots from four to five times daily. Colicky pains in the lower abdomen preceded the evacuation of the clots. He had lost 27 pounds in weight and weakness was progressive. Hemoglobin was 60%. His history and general appearance were strongly suggestive of malignancy. No masses or points of tenderness were found in the abdomen. The area of liver dulness was normal to percussion. Large and apparently bleeding internal hemorrhoids were present. A wasserman was negative as was also a gastro-intestinal series of x-rays. Hemorrhoidectomy promptly checked the bleeding and the patient rapidly regained his weight and strength. Over a year has

elapsed without recurrence of bleeding. This type of case requires a thorough examination to detect any other pathology that may be present

(+) Goldbacher

(≠) Yeoman

BIBLIOGRAPHY

- Anderson, H.G., and Dukes, C., " Treatment of hemorrhoids by submucous injection of chemicals",
Brit. Med. Jour., 2:100, '24.
- Best, R.R., " Principles underlying reduction of pain in the post-operative phase of anorectal disease",
Nebr. State Med. Jour., 17:115, Mar. '32.
- Bierman, W., " Hemorrhoidectomy by means of high frequency current",
Amer. Jour. Surg., 14:626-30, Dec. '31.
- Brooke, B.R., " Nonsurgical treatment - a simple office procedure",
Northwest Med., 30:32-33, Jan. '31.
- Burghard, F.F., and Kanavel, A.B., " Oxford Surgery",
Oxford University Press, New York City, 1919.
- Deutsch, W.F., " Electrocoagulation of hemorrhoids",
Amer. Jour. of Physical Therapy, 3:500-501, Febr. '27.
- Ebstein, E., " Contributions to the history of hemorrhoids and their treatment from the time of Hippocrates to the modern bacteriological era",
Med. Life, 35:5-18, Jan. '28.
- Elsner, H., " The treatment of hemorrhoids with injections of alcohol",
Deutsche Med. Wochenschr., 53:657-58, Apr. '27.

- Fansler, W.A., " The injection treatment of hemorrhoids:
Some fallacies and complications",
Minn. Med., 15:98-100, Feb. '32.
- Ibid " Some fundamental considerations in the injection
treatment of hemorrhoids",
Jour. Iowa State Med. Soc., 22:27-29, Jan. '32.
- Gabriel, W.B., " Therapy of hemorrhoids",
Practitioner, 126:114-20, Jan. '31.
- Goldbacher, L., " Hemorrhoids: The injection treatment and
pruritis ani",
F.A. Davis Co., Philadelphia, 1931.
- Gorsch, R.V., " The injection treatment of hemorrhoids",
Med. Jour. and Rec., 135:216-19, Mar. '32.
- Hayes, H.T., " The removal of hemorrhoids by the ligature
method",
Texas State Jour. Med., 25:210-13, July '29.
- Hirschman, L.J., " Hemorrhoidectomy",
Internat. Clin., 2:263-69, June '31.
- Ibid " Handbook of diseases of the rectum",
C.V. Mosby Co., St. Louis, 1920.
- Hiller, R.I., " Internal hemorrhoids (pathogenesis) and
rationale of injection therapy",
Amer. Jour. Surg., 16:64-67, April '32.
- Hullsiek, H.E., " The care of hemorrhoid patients",
Minn. Med., 10:377-79, June '27.

- Kantor, J.L., " Medical aspect of hemorrhoids",
Amer. Jour. Surg., 14:620-23, Dec. '31.
- Lewis, D., " Practice of Surgery",
W.F. Prior Co. Inc., Hagerstown Md., 1928.
- Lynch, J.M., " Surgical treatment",
Amer. Jour. Surg., 14:624-25, Dec. '31.
- McEvedy, P.G., " The injection treatment of hemorrhoids",
Lancet, 222:17-19, Jan. '32.
- Moon, L.E., " Therapy by both operative and injections",
Nebr. Med. Jour., 17:289-92, July '32.
- Mumery, J.P. Lockhart, " The treatment of internal piles",
Practitioner, 126:495-500, May '31.
- Sarafoff, D., " Operative treatment of hemorrhoids",
Archiv fur Klin. Chir., 168:486-532, '32.
- Secor, W.L., " Observations with recommendation of improved
operation",
Amer. Jour. Surg., 10:344-48, Nov. '30.
- Smith, D., " Whitehead deformity",
Jour. Amer. Med. Assoc., 91:879-80, Sept. '28.
- Smith, F.C., " Thrombosis of the hemorrhoidal veins",
Amer. Jour. Surg., 6:352-53, Mar. '29.
- Spiesman, Manuel G., " The injections of hemorrhoids and rectal
prolapse",
Clinical Med. and Surg., 36:547-552, Aug. '29.