

Henry Ford Health

## Henry Ford Health Scholarly Commons

---

Cardiology Articles

Cardiology/Cardiovascular Research

---

11-1-2022

### **Left Atrial-Veno-Arterial Extracorporeal Membrane Oxygenation: Step-By-Step Procedure and Case Example**

Alejandro Lemor

Mir B. Basir

Brian P. O'Neill

Jennifer A. Cowger

Tiberio Frisoli

*See next page for additional authors*


Follow this and additional works at: [https://scholarlycommons.henryford.com/cardiology\\_articles](https://scholarlycommons.henryford.com/cardiology_articles)

---

---

**Authors**










Alejandro Lemor, Mir B. Basir, Brian P. O'Neill, Jennifer A. Cowger, Tiberio Frisoli, James Lee, Dee Dee Wang, Khaldoon Alaswad, William O'Neill, and Pedro Villablanca



## Review Article

## Left Atrial-Veno-Arterial Extracorporeal Membrane Oxygenation: Step-By-Step Procedure and Case Example



Alejandro Lemor, MD, MS<sup>a,\*</sup> , Mir B. Basir, DO<sup>b</sup> , Brian P. O'Neill, MD<sup>b</sup> , Jennifer Cowger, MD<sup>b</sup> , Tiberio Frisoli, MD<sup>b</sup> , James C. Lee, MD<sup>b</sup> , Dee Dee Wang, MD<sup>b</sup> , Khaldoon Alaswad, MD<sup>b</sup> , William O'Neill, MD<sup>b</sup> , Pedro A. Villablanca, MD, MS<sup>b</sup>

<sup>a</sup> Division of Cardiology, The University of Mississippi Medical Center, Jackson, Mississippi, USA

<sup>b</sup> Division of Cardiology, Henry Ford Hospital, Detroit, Michigan, USA

## ARTICLE INFO

## Article history:

Submitted 16 April 2022

Revised 26 September 2022

Accepted 27 September 2022

Available online 31 October 2022

## ABSTRACT

Veno-arterial extracorporeal membrane oxygenation is used in patients requiring biventricular support; however, its use increases the afterload. In patients with severe aortic insufficiency or severe left ventricular dysfunction, it will increase left-side filling pressures, hence the need for left ventricle unloading with an additional mechanical circulatory support device. We present a case of a patient with cardiogenic shock and severe aortic insufficiency who underwent left atrial veno-arterial extracorporeal membrane oxygenation and provide a step-by-step explanation of the technique.

## Introduction

Veno-arterial extracorporeal membrane oxygenation (VA-ECMO) is frequently utilized in patients who require biventricular support. Unfortunately, VA-ECMO can result in a significant increase in afterload which may require the use of additional mechanical circulatory support (MCS) devices for left ventricular unloading. VA-ECMO is also contraindicated in cases of severe aortic insufficiency (AI). The use of left atrial-VA-ECMO (LAVA-ECMO) using a fenestrated cannula to drain the left and right atria can provide biventricular support without the need for an additional MCS device.<sup>1,2</sup> We present a case of a patient with cardiogenic shock who underwent LAVA-ECMO and provide a step-by-step explanation of the technique.

## Case Description

A 63-year-old male with a past medical history of severe AI, atrial fibrillation, diabetes, hypertension, and pulmonary hypertension (World Health Organisation group II) presented to an outside hospital with acute decompensated heart failure. He had a blood pressure of 90/20 mmHg (mean 37 mmHg), heart rate of 90 bpm, creatinine of 2.1 mg/dL, pro-brain natriuretic peptide of 1345 pg/mL, and a lactic acid level of 2.1 mg/dL. His echocardiogram demonstrated an ejection

fraction of 56% and severe AI (Supplemental Videos 1 and 2 in the Data Supplement). He underwent a right-heart catheterization that demonstrated elevated filling pressures and a low cardiac output (Table 1). Based on his hemodynamics, severe AI, and evidence of end-organ hypoperfusion, he underwent LAVA-ECMO implantation via the right femoral vein and the left femoral artery for Society for Cardiovascular Angiography and Interventions class C/D cardiogenic shock (Figures 1 and 2). The patient remained on LAVA-ECMO for 4 days; his case was

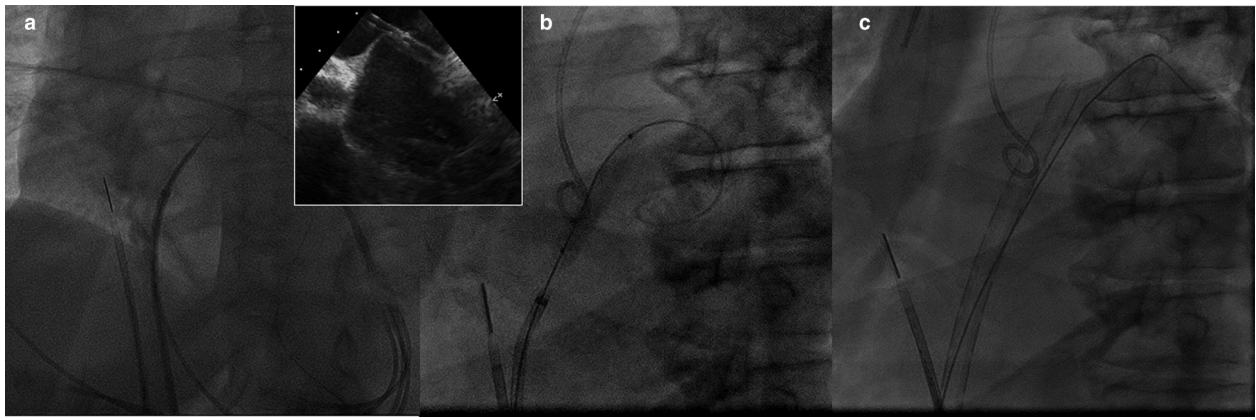
**Table 1**  
Hemodynamics pre- and post-LAVA-ECMO

Hemodynamics	Pre-LAVA-ECMO	Post-LAVA-ECMO
Cardiac output (by Fick)	4.0 l/min	9.1 l/min
Cardiac index	1.9 l/min/m <sup>2</sup>	4.0 l/min/m <sup>2</sup>
Cardiac power output	0.4 Watts	1.08 Watts
Left atrium (mean)	30 mmHg	16 mmHg
Left ventricle end diastolic pressure	42 mmHg	13 mmHg
Right atrium (mean)	17 mmHg	8 mmHg
Right ventricle end-diastolic pressure	20 mmHg	8 mmHg
Pulmonary artery (mean)	81/21 (42) mmHg	32/12 (21) mmHg
Pulmonary capillary wedge pressure	33 mmHg	16 mmHg
Systemic blood pressure	97/35 mmHg	95/50 mmHg

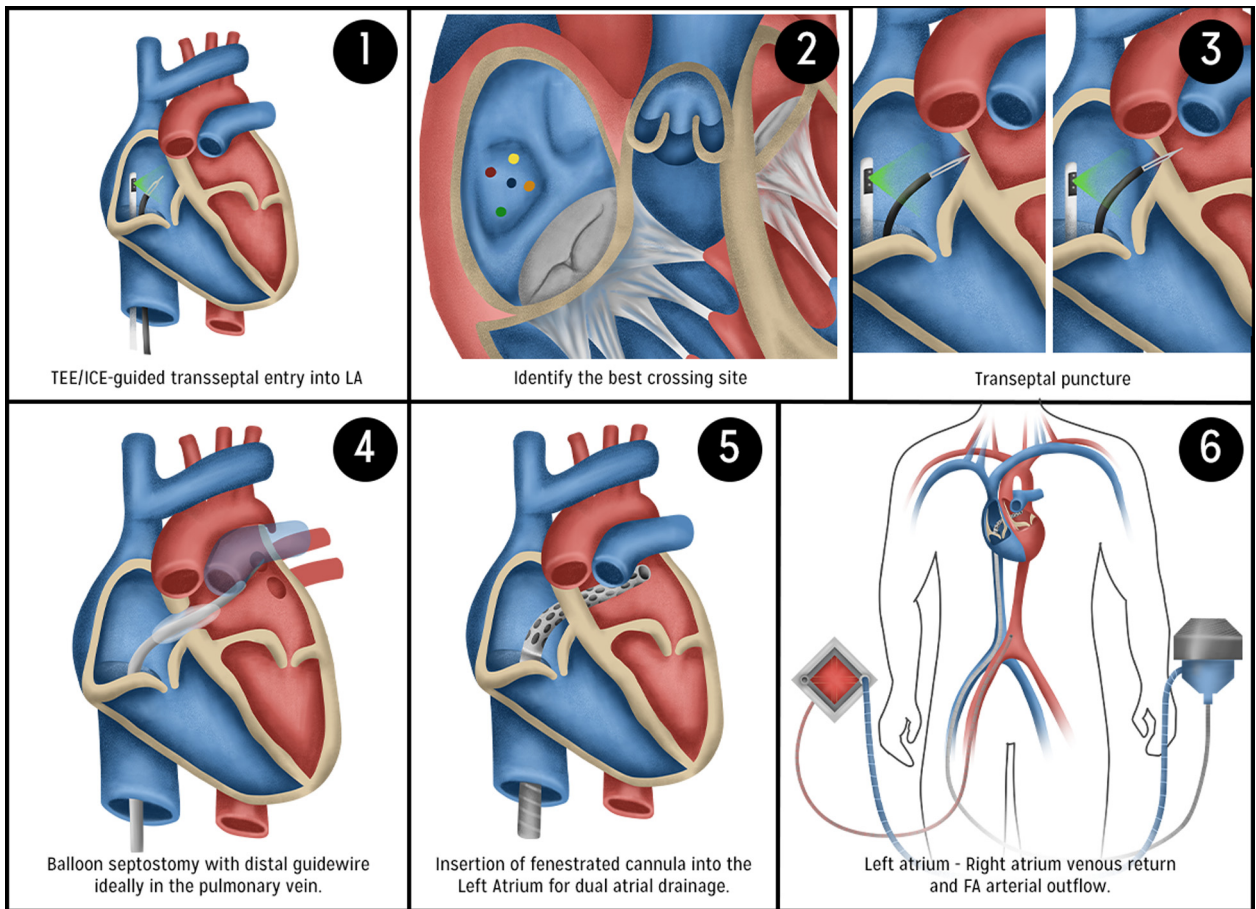
LAVA-ECMO, left atrial veno-arterial extracorporeal membrane oxygenation.

\* Address correspondence to: Alejandro Lemor, MD, MS, The University of Mississippi Medical Center, Cardiovascular Medicine, 2500 North State Street, Jackson, MS 39201.

E-mail address: [alejandrolemor@hotmail.com](mailto:alejandrolemor@hotmail.com) (A. Lemor).



**Figure 1.** ICE-guided atrial septostomy and fenestrated cannula insertion into the left atrium. (a) ICE-guided transeptal puncture using an SL sheath and a Brockenbrough needle. (b) Balloon septostomy performed to facilitate advancement of the cannula. (c) Fenestrated cannula in place draining from both right and left atria. Abbreviation: ICE, intra-cardiac ultrasound.



**Figure 2.** Procedural steps of LAVA-ECMO. (1) Using intracardiac ultrasound (ICE)/transesophageal echocardiogram (TEE) to guide the transeptal puncture (TSP) for left atrial (LA) access. (2) Identify the ideal TSP at the mid-portion of the fossa ovale (blue dot). If unachievable due to a challenging anatomy or emergent scenario, crossing at other locations in the fossa ovale (other colors dots) or even via a patent foramen ovale may be necessary. (3) A steerable catheter or a preshaped sheath, introducer, and the needle are used to obtain LA access and to advance an 0.035" guidewire into the left superior pulmonary vein (LSPV) or the left atrial appendage if unable to reach using a preshaped guidewire. (4) Consider intraatrial balloon septostomy with an 8.0-mm balloon to facilitate advancement of the LA cannula, especially for patients with a prior surgical patch of the interatrial septum. This also identifies on fluoroscopy the intraatrial septum for positioning of the fenestrated cannula. (5) Under fluoroscopic guidance, the fenestrated cannula VFEM024 (Edwards Lifesciences, Irvine, CA) is advanced over a stiff wire into the LA up to the proximal portion of the LSPV. (6) Insert arterial cannula and connect the circuit to LAVA-ECMO for biventricular mechanical support. Abbreviation: FA, femoral artery; LAVA-ECMO, left atrial veno-arterial extracorporeal membrane oxygenation.

discussed in a multidisciplinary heart team meeting, and he was deemed high risk for surgery. He, therefore, underwent successful transcatheter aortic valve replacement with an Evolut PRO+ (Medtronic, MN) 34-mm valve. The LAVA-ECMO was removed the following day without any complications using an 18Fr Manta device (Teleflex, PA) for the arterial access. The patient was discharged home 7 days later.

### Step-by-Step Explanation of LAVA-ECMO

Patient selection is key when utilizing this form of MCS. Those with cardiogenic shock and valvular heart disease are great candidates for this MCS; however, in patients with moderate to severe aortic stenosis, the aortic valve could potentially remain closed (as the left ventricle [LV] is unloaded), and there will be a risk of aortic root thrombosis. Transeptal puncture for left atrial (LA) access is done using intracardiac ultrasound or transesophageal echocardiogram based on the operator experience and the availability of transesophageal echocardiogram on each center. The ideal transeptal puncture is at the mid-portion of the fossa ovale, but crossing at other locations in the fossa ovale or even via a patent foramen ovale is also a suitable (but not preferred) option. Either a steerable catheter or a preshaped sheath with a needle is used to obtain LA access, followed by advancement of a 0.035" guidewire into the left superior pulmonary vein; the LA appendage can also be used to park the guidewire. Intraatrial balloon septostomy with an 8.0-mm balloon can be considered to facilitate advancement of the LA cannula, particularly in patients with a prior surgical patch of the interatrial septum. This also helps to identify the intraatrial septum under fluoroscopy for precise positioning of the fenestrated cannula. Under fluoroscopic guidance, a fenestrated cannula (the one used in our center is VFEM024 from Edwards Lifesciences, Irvine, CA) is advanced over the 0.035" stiff guidewire into the LA up to the proximal portion of the left superior pulmonary vein. Using an ultrasound- and fluoroscopy-guided micropuncture access, the femoral artery is cannulated with the arterial ECMO cannula, and the circuit is connected.

### Discussion

Choosing the right MCS device for patients in cardiogenic shock with severe AI is challenging. Intraaortic balloon pump, Impella (Abiomed, Danvers, MA), and VA-ECMO worsen the regurgitant volume and are contraindicated in severe AI. Central ECMO can be utilized, but the complications associated with central cannulation can be significant, and not every patient will be a suitable candidate for central cannulation. Herein, we present a case of cardiogenic shock with severe AI in which the decision was made to utilize LAVA-ECMO. LAVA-ECMO can indirectly unload the LV by decreasing LA pressure. Our patient, however, required biventricular support given his history of pulmonary hypertension and right ventricular dysfunction, and LAVA-ECMO was able to provide biventricular support with an output of 4-6 L/min. Other percutaneous options for biventricular MCS support include performing regular cannulation of VA-ECMO and adding an intraaortic balloon pump or Impella for LV unloading; however, this increases the risk of vascular complications by adding an additional arterial large-bore access.<sup>3</sup> LAVA-ECMO provides biventricular support with adequate LV unloading using only 1 arterial large-bore access. De-escalation of support with LAVA-ECMO should be done similar to other MCS devices using invasive hemodynamic parameters and, if available, echocardiographic assessment of both ventricles. The decision of closing the iatrogenic atrial septal defect will depend on each patient, and the indications will be the

same as those of any other patient with an ASD, but closure of the iatrogenic atrial septal defect is not routinely done.

### Conclusion

The best MCS device for patients with cardiogenic shock and valvular heart disease remains a subject of debate. LAVA-ECMO is a safe and feasible method to provide biventricular support with adequate LV unloading in patients with cardiogenic shock and valvular heart disease using 1 arterial and 1 venous large-bore access, particularly in those with severe AI. We presented a case in which LAVA-ECMO was successfully used as a bridge to transcatheter aortic valve replacement.

### Disclosure statement

Dr M. B. Basir receives consultant fees/honoraria from Abbott Vascular, Abiomed, Chiesi, Cardiovascular Systems, Saranas, and Zoll. Dr B. P. O'Neill is a consultant to and receives research support from Edwards Lifesciences. Dr T. Frisoli is a proctor for Edwards Lifesciences, Abbott, Boston Scientific, and Medtronic. Dr D. D. Wang is a consultant for Edwards Lifesciences, Abbott, Neochord, and Boston Scientific and receives research grant support from Boston Scientific assigned to employer Henry Ford Health System. Dr W. O'Neill has served as a consultant for Abiomed, Edwards Lifesciences, Medtronic, Boston Scientific, Abbott Vascular, and St. Jude Medical and serves on the Board of Directors of Neovasc Inc. Dr P. A. Villablanca is a consultant for Edwards Lifesciences and Teleflex. The other authors had no conflicts to declare.

### ORCIDiDs

Alejandro Lemor  <https://orcid.org/0000-0002-4649-8479>  
 Jennifer Cowger  <https://orcid.org/0000-0002-0791-6594>  
 James C. Lee  <https://orcid.org/0000-0003-4917-4012>  
 Dee Dee Wang  <https://orcid.org/0000-0002-5784-9924>  
 Khaldoon Alaswad  <https://orcid.org/0000-0003-1368-5320>

### Consent Statement

Informed consent was obtained from the patient for publication of this article and accompanying images.

### Funding

The authors have no funding to report.

### Supplementary Material

Supplemental data for this article can be accessed on the [publisher's website](#).

### References

- Eng M, Al-Darzi W, Villablanca P, et al. TCT-308 cardiogenic shock-associated cardiorenal syndrome improves with the use of left atrial venous arterial extracorporeal membrane oxygenation (LAVA-ECMO). *J Am Coll Cardiol*. 2021;78: B126.
- Chiang M, Gonzalez PE, Basir B, et al. Left atrial venoarterial extracorporeal membrane oxygenation for acute aortic regurgitation and cardiogenic shock. *JACC Case Rep*. 2022;4:276-279.
- Lemor A, Dabbagh MF, Cohen D, et al. Rates and impact of vascular complications in mechanical circulatory support. *Catheter Cardiovasc Interv*. 2022;99(5):1702-1711.