

Emergency endovascular management of the common femoral artery rupture due to radiotherapy for scrotal carcinoma

Umberto Marcello Bracale¹, Giovanni Merola²,
Luca del Guercio¹, Maurizio Sodo², Anna Maria Giribono¹
and Umberto Bracale²

Acta Radiologica Short Reports
4(1) 1–3

© The Foundation Acta Radiologica
2015

Reprints and permissions:
sagepub.co.uk/journalsPermissions.nav
DOI: 10.1177/2047981614545154
arr.sagepub.com



Abstract

We describe the case of a 72-year-old man with massive hemorrhage and shock resulting from rupture of the left common femoral artery as a complication of radiotherapy in the groin for cancer of the scrotum. This complication is extremely rare, presents dramatically, and is usually fatal. The patient was successfully treated with a stent graft deployment in order to achieve immediate hemostasis maintaining blood flow to the leg. Open surgery is not ideal in those cases especially when there is extensive tumor involvement of the groin causing altered anatomy and increasing the risk of re-bleeding.

Keywords

Stents, angiography, vascular, radiation effects, primary neoplasms, scrotum

Date received: 6 May 2014; accepted: 4 July 2014

Introduction

Common femoral artery (CFA) rupture following radiotherapy for urogenital cancer is extremely rare in current literature. Open surgery in this irradiated field can be challenging because of difficulty in dissection of connective tissue and suturing the injured artery. We herein describe the endovascular management of CFA rupture that as induced by radiotherapy for squamous cell carcinoma of the scrotum.

Case report

A 72-year-old man was admitted to our institution for uncontrollable hemorrhage from the left groin. The patient was severely hypotensive (70/40 mmHg) presenting with loss of consciousness. Manual compression in the bleeding region was immediately applied while he was resuscitated, intubated, and transferred to the operating theater.

The patient had 12 months earlier been treated for an infiltrating squamous cell scrotal carcinoma with non-resectable regional lymph nodes metastasis

(Pathological Stage C according to the Ray and Withmore classification) (1), with surgical treatment of the primary tumor and was then submitted to fractionated adjuvant radiotherapy in two sessions (performed the first time bilaterally in the groin with technical opposing camps and on the scrotum with direct technique for a total of 50.40 Gy for 2 months, the second time only in the left groin with technical opposing camps for a total of 30.40 Gy). After the last session, the patient developed multiple skin lesions in the left groin and a complete, paraneoplastic, iliofemoral deep vein thrombosis with severe edema of the left leg.

¹Department of Vascular and Endovascular Surgery, University Federico II of Naples, Naples, Italy

²Department of General Surgery, University Federico II of Naples, Naples, Italy

Corresponding author:

Umberto Marcello Bracale, Department of Vascular and Endovascular Surgery, University Federico II of Naples, Naples, Italy.
Email: umbertomarcello.bracale@unina.it



After resuscitation and transfer to the theater, an urgent endovascular approach was planned, as the left CFA was thought to be very frail with high risk of re-bleeding in case of an open surgical repair. A 6 Fr sheath was, therefore, placed in the left common iliac artery from the right groin with a cross-over maneuver and an angiogram was carried out revealing a ruptured left CFA with large extravasation of contrast medium despite manual pressure (Fig. 1a). Hemostasis was then immediately achieved by inflating a 10 mm balloon (Advance balloon; Cook, Bloomington, IN, USA) in the external iliac artery. The subsequent angiography

through the balloon catheter showed clearly the eroded CFA and the feasibility to repair it deploying a covered stent (Fig. 1b). The 6 Fr sheath was then exchanged for a 12 Fr 45 cm sheath (Flexor sheath, Cook Bloomington, IN, USA) and a 10 mm × 4 cm Fluency stent graft (Bard Peripheral Vascular Inc., Tempe, AZ, USA) was advanced over a hydrophilic stiff guidewire and placed covering the erosion. After post-dilatation, completion angiography demonstrated a patent CFA without any leak (Fig. 1c). The patient received 4 units of blood during the procedure and was transferred to the ICU where he recovered well within

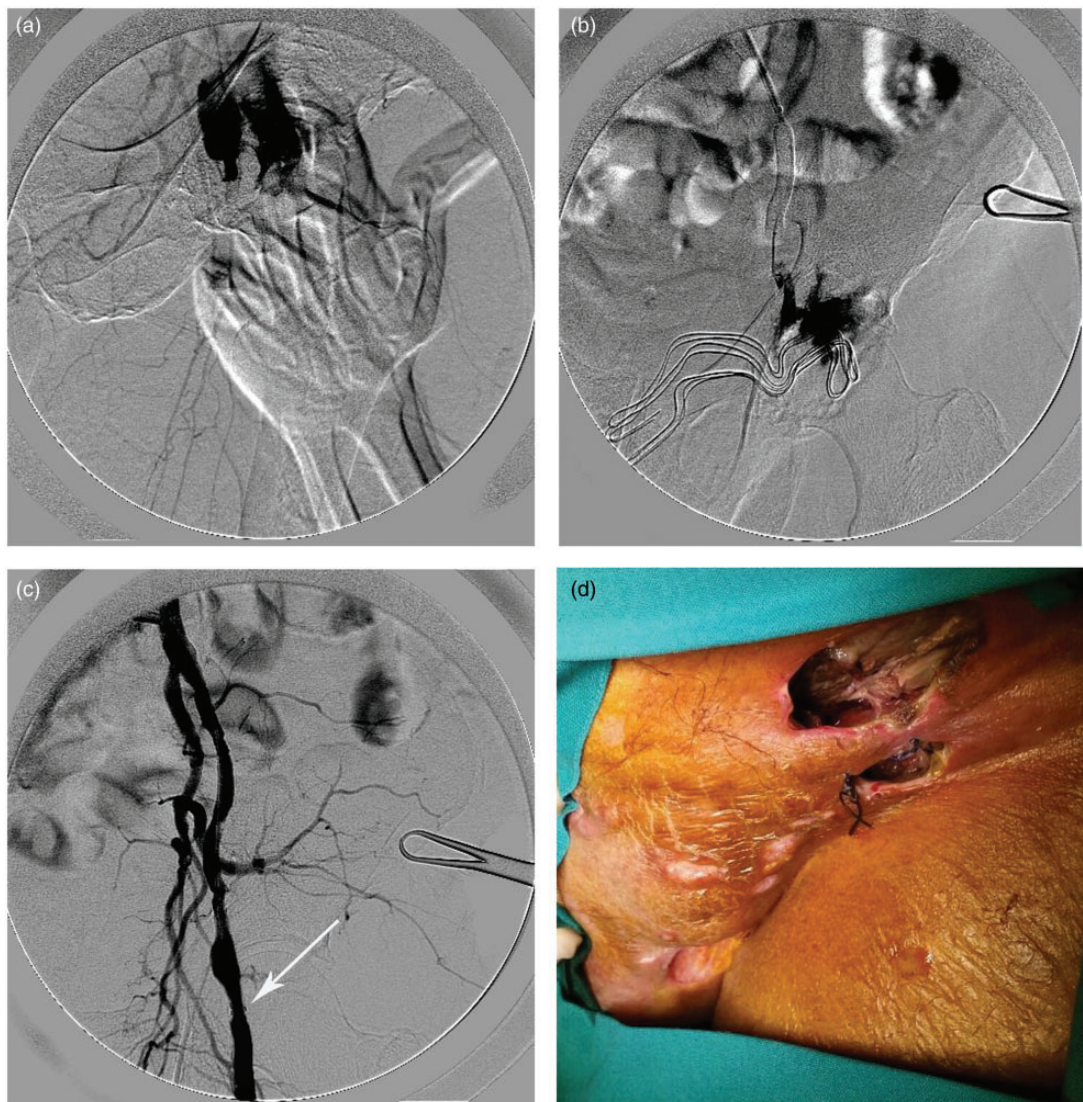


Fig. 1. (a) Urgent angiogram through contralateral access showing ruptured left CFA with large extravasation of contrast medium despite manual pressure. (b) After 10 mm balloon inflation in the left external iliac artery, an angiogram via the inner lumen of the balloon catheter highlights the feasibility to treat the erosion by placing a stent-graft. (c) Completion angiogram after deployment and post-dilatation of the stent-graft (arrow) showing maintained flow and no sign of leak. (d) Infected necrotic left groin cavity caused by radiotherapy after 2 weeks from the endovascular procedure.

24 h. Treatment with subcutaneous fondaparinux injections in a daily dose of 2.5 mg was commenced 48 h after this uncomplicated procedure. After 1 month the necrotic infected cavity was stable without recurrent bleeding (Fig. 1d); a Duplex scan showed patency of the stent graft but no recanalization of the iliofemoral deep vein thrombosis.

Discussion

Scrotal cancer occurs predominantly in men aged older than 50 years. In Europe, the age-standardized incidence rate is around 1.5 per 1,000,000 person-years and do not seem to change over time. Squamous cell carcinomas is the most frequent histological type, followed by basal cell carcinomas (2). Radiotherapy has little effect in the treatment of this type of carcinoma but has been used in non-resectable lesions or for local recurrences and metastasis (3). As large populations of cancer patients survive longer, radiation-induced peripheral arterial disease is increasingly being recognized, even if it is a problem that is often under-reported (4). However, arterial rupture is a rare but devastating complication of radiotherapy commonly reported for supra-aortic vessels during therapy for head and neck cancers (5) or due to tumor involvement (6). Surgical management can be technically challenging because exploration and repair of the previously irradiated field is complicated. Endovascular therapy with balloon occlusion and stent graft deployment is indeed a good alternative to surgery. In fact, when an occlusive balloon is placed at, or above, the level of the active bleeding, time is gained to plan different therapeutic options (7). At the best of our knowledge we report the first case of CFA rupture following irradiation therapy for scrotal squamous cell carcinoma managed with a stent-graft deployment. The safety of placing an endovascular stent graft, like the Fluency stent-graft, in an infected field or across an area subject to such movement is debated due to the risk of contamination and impaired patency with subsequent limb- and life-threatening sequelae (8). However, our patient presented in severe conditions with acute and copious bleeding from his infected and necrotic wound and surgical

reconstruction through either a transperitoneal or a retroperitoneal approach was considered too dangerous while a percutaneous contralateral procedure achieved immediate hemostasis maintaining blood flow to the leg.

In conclusion, this short report aims to remind clinicians about the rare but potentially fatal risk of arterial rupture following radiotherapy. Moreover, endovascular stent graft placement after temporary proximal balloon occlusion is an efficient and safe method to stabilize critical patients with life-threatening bleeding.

Conflict of interest

None declared. Written informed consent was obtained from the patient for publication of this short report and accompanying images.

References

1. Ray B, Whitmore WF Jr. Experience with carcinoma of the scrotum. *J Urol* 1977;117:741–745.
2. Verhoeven RH, Louwman WJ, Koldewijn EL, et al. Scrotal cancer: incidence, survival and second primary tumours in the Netherlands since 1989. *Br J Cancer* 2010;103:1462–1466.
3. Casasola Chamorro J, Gutiérrez García S, de Blas Gómez V. Scrotal carcinoma. *Arch Esp Urol* 2011;64:541–543.
4. Jurado JA, Bashir R, Burket MW. Radiation-induced peripheral artery disease. *Catheter Cardiovasc Interv* 2008;72:563–568.
5. Chang FC, Lirng JF, Luo CB, et al. Carotid blowout syndrome in patients with head-and-neck cancers: reconstructive management by selfexpandable stent-grafts. *Am J Neuroradiol* 2007;28:181–188.
6. Unlü Y, Tekin SB, Ceviz M, et al. A successful right axillary artery graft to repair a ruptured axillary artery due to the involvement of lymphoma: report of a case. *Surg Today* 2003;33:72–74.
7. Leonhardt H, Mellander S, Snygg J, Lönn L. Endovascular management of acute bleeding arterioenteric fistulas. *Cardiovasc Intervent Radiol* 2008;31:542–549.
8. Bracale UM, Porcellini M, Bracale G. How should I treat concomitant post-endarterectomy carotid pseudoaneurysm and contralateral symptomatic stenosis? *EuroIntervention* 2010;6:283–287.