

A novel nonsense mutation in the *TITF-1* gene in a Japanese family with
benign hereditary chorea

Katsuya Nakamura, MD, PhD¹, Yoshiki Sekijima, MD, PhD^{1,2}, Kiyoshiro Nagamatsu, MD¹,

Kunihiro Yoshida, MD, PhD¹, Shu-ichi Ikeda, MD, PhD¹

¹ Department of Medicine (Neurology and Rheumatology), Shinshu University School of Medicine

² Division of Clinical and Molecular Genetics, Shinshu University Hospital

Corresponding author: Yoshiki Sekijima

Department of Medicine (Neurology and Rheumatology), Shinshu University School of Medicine,

3-1-1 Asahi, Matsumoto 390-8621, Japan

TEL: +81-263-37-2673 FAX: +81-263-37-3427 e-mail: sekijima@shinshu-u.ac.jp

Key words: benign hereditary chorea (BHC), Brain-Thyroid-Lung syndrome, *thyroid transcription*

factor-1 (TITF-1), chorea, hypothyroidism, Nkx2.1

Abstract

A Japanese family with a novel nonsense mutation in the *TITF-1* gene (p.Y98X) is described.

The proband showed severe generalized chorea, delayed motor development, subnormal intelligence, congenital hypothyroidism, bronchial asthma, and a history of pulmonary infection, all of which are characteristic features of Brain-Thyroid-Lung syndrome. On the other hand, her brother and mother showed a mild benign hereditary chorea (BHC) phenotype with congenital hypothyroidism.

Intrafamilial phenotypic variation is common in BHC/Brain-Thyroid-Lung syndrome and suggests the existence of other genetic or environmental factors regulating TITF-1 function. Although choreic movement in BHC/Brain-Thyroid-Lung syndrome is recognized as non-progressive, the proband showed re-exacerbation of choreic movement at puberty. The dopamine agonist, ropinirole hydrochloride, reduced her choreic movements, suggesting that levodopa and/or dopamine agonists may compensate for underdeveloped dopaminergic pathways in this disorder.

1. Introduction

Benign hereditary chorea (BHC) (MIM 118700) is a rare autosomal dominant choreic disorder with onset in childhood [1-5]. In contrast to Huntington disease, choreic movement in BHC is recognized as non-progressive and patients have normal or slightly below normal intelligence. Choreic movements tend to be attenuated in adolescence or early adulthood in some families [6]. In addition to chorea, some patients exhibit other neurological features, such as dystonia, myoclonic jerks, intentional tremor, dysarthria, and gait disturbance [7].

Recently, mutations in the gene encoding thyroid transcription factor-1, *TITF-1*, a member of the *NK2* gene family, have been identified in BHC pedigrees [3]. TITF-1 is a homeodomain-containing transcription factor essential for organogenesis of the lung, thyroid, and basal ganglia. Since the discovery of *TITF-1* gene mutations in this disorder, the clinical presentation and the phenotype have expanded with variable combinations of lung, thyroid, and neurological abnormalities [3, 4].

Willemsen *et al.* [8] recently introduced the term “Brain-Thyroid-Lung syndrome” (MIM 610978) to emphasize the widespread involvement of multiple organ systems that can be present with *TITF-1* mutations. At present, Brain-Thyroid-Lung syndrome is recognized as an allelic disorder of BHC with a more severe phenotype.

Here, we report a Japanese family with a novel nonsense mutation in the *TITF-1* gene (p.Y98X).

The clinical phenotype of the proband was Brain-Thyroid-Lung syndrome, whereas those of her brother and mother were mild BHC with congenital hypothyroidism.

2. Case report

2.1. Patient 1

The proband (patient 1, III-4), a 19-year-old Japanese girl, was the second child of non-consanguineous parents (Fig. 1A). She was born at term after a normal pregnancy and presented with an elevated thyroid stimulating hormone (TSH) level detected by neonatal screening. At the age of 12 months, she developed pneumonia. Thyroid function was compensated at the age of 18 months, with an elevated TSH level of 28.77 μ IU/mL (normal range: 0.2–4.0), and a normal free T4 (fT4) level of 1.22 ng/dL (normal range: 1.0–2.0) and free T3 (fT3) level of 5.80 pg/mL (normal range: 3.5–5.9). The thyroid was of normal size on ultrasound and 123 I scintigraphy showed normal uptake. A diagnosis of mild congenital hypothyroidism was made and treatment with levothyroxine was begun. Although her mental development was compatible with normal milestones, her motor development was markedly delayed with standing up at 24 months. She showed rapid choreic movements of the limbs at 35 months. Although her choreic movement showed gradual attenuation on reaching school age, she was admitted to our hospital at age 16 because of re-exacerbation of choreic movement.

On admission, general examination of the patient was unremarkable. Neurologically, she had severe rapid choreic involuntary movements involving the neck, trunk, and all four limbs. Choreic movements were more common with intentional movements and induced frequent falls while walking (supplementary video, segment 1-3). She showed neither muscle atrophy nor weakness, although muscle tone was decreased. Her intelligence assessed by Wechsler Adult Intelligence Scale,

3rd edition (WAIS-III), showed Full Scale IQ 58, Verbal IQ 66, Performance IQ 54, Verbal Comprehension Index 66, Perceptual Organization Index 59, Working Memory Index 67, and Processing Speed Index 52. Findings of routine blood examination, cerebrospinal fluid, chest roentgenography, electrocardiography, electroencephalography, nerve conduction studies, and brain MRI were all normal. She was initially treated with levodopa 600 mg per day and then with olanzapine at 5 mg per day, which did not improve choreic movement. Administration of propranolol hydrochloride at a dosage of 60 mg per day partly reduced her chorea, but was discontinued due to induction of asthma attack. Ropinirole hydrochloride at 2 mg per day reduced choreic movement (supplementary video, segment 4). At age 18, she completed a special classes at high school and started a job working at a clothing store in an outlet mall. She also qualified for a driving license at age 18.

2.2. Patient 2

Patient 2 (III-3) was the older brother of patient 1. He was born at term without signs of respiratory distress. Mild congenital hypothyroidism was detected at neonatal screening (TSH 12.6 μ IU/mL, fT4 1.14 ng/dL) and levothyroxine replacement therapy was started at 6 months of age. His motor development was markedly delayed with standing up at 30 months, whereas his mental development was compatible with normal milestones. He developed mild choreic movement at 6 years old, which gradually disappeared in adolescence. Brain MRI examined at 5 years old showed no abnormal findings. He graduated from a regular community high school and began working as a

child-minder.

2.3 Patient 3

Patient 3 (II-4) was the mother of patient 1 and 2. She also showed motor developmental delay and developed mild choreic movement of the extremities at around 6 years old. Her involuntary movements gradually disappeared in adolescence. She graduated from a regular community high school and worked as a sales clerk at a supermarket. Although her thyroid function was not analyzed in childhood, blood test performed at 47 years old showed elevated TSH level of 13.2 μ IU/mL, and normal fT4 level of 0.85 ng/dL (normal range: 1.0–2.0) and fT3 level of 2.84 pg/mL (normal range: 2.3–4.0). Neurological examination of the patient performed at 47 years old showed no abnormal findings, including involuntary movement, muscle atrophy, and weakness. She had no history of episodes of pulmonary disease (Table 1).

2.4. DNA analysis

As clinical findings in this family were suggestive of BHC/Brain-Thyroid-Lung syndrome, genetic analysis for this disorder was performed with informed consent. DNA was extracted from peripheral leukocytes of patient 1 (III-4) and patient 3 (II-4) according to the standard protocol. All 3 exons of the *TITF-1* gene were amplified by polymerase chain reaction (PCR) as described previously.[9] Direct sequence analysis of the PCR-amplified DNA revealed that both patients were heterozygous for C to G substitution at position 294 of the coding sequence (c.294C>G) in exon 1 (Fig. 1B). This

mutation is predicted to lead to a premature stop at codon 98 (p.Y98X), and is located before the homeodomain of TITF-1. Huntington disease was excluded by genetic testing.

3. Discussion

We reported a Japanese family with BHC/Brain-Thyroid-Lung syndrome confirmed to possess a novel heterozygous mutation (p.Y98X) in the *TITF-1* gene. To date, more than 20 mutations within the *TITF-1* gene have been identified in BHC and Brain-Thyroid-Lung syndrome families (Table 1) [4, 8, 10-27]. Most of the mutations are large deletions [4, 10-13], splice site mutations [13-15], frameshift mutations [8, 16-19], or nonsense mutations [4, 20-25], which lie before or involve the homeodomain. Furthermore, most of missense mutations also lie in the homeodomain [13, 18, 27], suggesting that the pathogenesis of this disorder involves haploinsufficiency of TITF-1 protein. The detected novel heterozygous nonsense mutation in the present family (p.Y98X) would truncate the encoded protein before the homeodomain, affecting its DNA binding properties. Alternatively, loss of TITF-1 function may be induced by mRNA nonsense-mediated decay in this family.

The clinical manifestations of our patients were highly variable even within the same family. The proband (patient 1, III-4) showed severe generalized chorea, delayed motor development, subnormal intelligence, congenital hypothyroidism, bronchial asthma, and a history of pulmonary infection, all of which are characteristic features of the Brain-Thyroid-Lung syndrome phenotype. On the other hand, her brother (patient 2, III-3) and mother (patient 3, II-4) showed mild BHC phenotype with congenital hypothyroidism. Similar to this family, considerable intrafamilial phenotypic variation

has been observed in families with this disorder (Table 1), in addition to interfamilial phenotypic variation due to different mutations within the *TITF-1* gene.

There are 48 cases in the literature with documented genetic analysis and thyroid function tests from 30 families, including the present family [4, 8, 10-13, 15-23, 25-27]. Fourteen of the 48 patients (29.2%) showed BHC with congenital hypothyroidism and 25 (52.1%) developed the complete triad of Brain-Thyroid-Lung syndrome, whereas only 3 patients (6.8%) showed classic BHC without hypothyroidism (Table 1). Three patients (6.3%) showed isolated congenital hypothyroidism and another 3 patients (6.3%) showed congenital hypothyroidism and lung disease without neurological abnormalities. Forty-five of the 48 patients (93.8%) with *TITF-1* gene mutations showed hypothyroidism (Table 1), indicating that thyroid function test is highly useful in diagnosing BHC/Brain-Thyroid-Lung syndrome. Although only 28 of the 48 patients (58.3%) with *TITF-1* gene mutations showed lung disease, pulmonary abnormalities may be overlooked if diagnosis is made in adulthood. Intrafamilial phenotypic variation was observed in 7 families, including the family reported here (Table 1) [12, 13, 19-22, 24], indicating that BHC and Brain-Thyroid-Lung syndrome are not entirely distinct but represent extreme points on a spectrum [28]. Intrafamilial phenotypic variation in this disorder may be explained by differences in modifier genes that produce a different genetic background in the same family. Indeed, the activity of TITF-1 is highly dependent on its interactions with other transcription factors and coactivators, including GATA-6, NF-1, RAR, CBP/p300, SRC-1, and TAZ [29-34]. In addition, deficient transcriptional activity of mutant TITF-1 (p.P202L) was completely rescued by cotransfection of wild-type PAX8 in HEK293 cells [13].

Environmental factors could also modify the disease phenotype, as monozygotic twins with a *TITF-1* mutation showed different phenotypes [13].

Although choreic movement in BHC/Brain-Thyroid-Lung syndrome is recognized as non-progressive, the proband (patient 1) showed re-exacerbation of choreic movement at puberty. Similar re-exacerbation was observed in two other patients [21, 24]. Glik et al. [24] reported a BHC patient with p.S145X mutation who showed mild worsening of chorea at the age of 30. Salvatore et al. [21] also reported a BHC patient with p.S217X mutation who showed worsening of choreic movement during puerperium at the age of 19. In terms of treatment for BHC, there have been two reports [14, 22] in which high doses of levodopa significantly improved gait and choreic movements. Although levodopa did not improve choreic movement, dopamine agonist was effective in patient 1, suggesting that levodopa and/or dopamine agonists may compensate for underdeveloped dopaminergic pathways in this disorder [14]. The results of brain MRI in our patients appeared normal; however, several abnormal findings, including ventricular dilatation, cystic mass in the posterior part of the sella, empty sella, and dysgenesis of the pallidum, have been reported in some patients with *TITF-1* mutation. Furthermore, advanced MRI analysis showed metabolic and volumetric abnormalities of the basal nuclei in this disorder [35]. Despite recent progress in molecular genetics of BHC/Brain-Thyroid-Lung syndrome, the pathophysiological mechanism of this disorder remains to be elucidated.

References

1. Haerer AF, Currier RD, Jackson JF. Hereditary nonprogressive chorea of early onset. *N Engl J Med* 1967;276:1220-4.
2. Breedveld GJ, Percy AK, MacDonald ME, de Vries BB, Yapijakis C, Dure LS, et al. Clinical and genetic heterogeneity in benign hereditary chorea. *Neurology* 2002;59:579-84.
3. Breedveld GJ, van Dongen JW, Danesino C, Guala A, Percy AK, Dure LS, et al. Mutations in TITF-1 are associated with benign hereditary chorea. *Hum Mol Genet* 2002;11:971-9.
4. Krude H, Schutz B, Biebermann H, von Moers A, Schnabel D, Neitzel H, et al. Choreoathetosis, hypothyroidism, and pulmonary alterations due to human NKX2-1 haploinsufficiency. *J Clin Invest* 2002;109:475-80.
5. Mahajnah M, Inbar D, Steinmetz A, Heutink P, Breedveld GJ, Straussberg R. Benign hereditary chorea: clinical, neuroimaging, and genetic findings. *J Child Neurol* 2007;22:1231-4.
6. Harper PS. Benign hereditary chorea. Clinical and genetic aspects. *Clin Genet* 1978;13:85-95.
7. Schrag A, Quinn NP, Bhatia KP, Marsden CD. Benign hereditary chorea--entity or syndrome? *Mov Disord* 2000;15:280-8.
8. Willemsen MA, Breedveld GJ, Wouda S, Otten BJ, Yntema JL, Lammens M, et al. Brain-Thyroid-Lung syndrome: a patient with a severe multi-system disorder due to a de

- novo mutation in the thyroid transcription factor 1 gene. *Eur J Pediatr* 2005;164:28-30.
9. Bauer P, Kreuz FR, Burk K, Saft C, Andrich J, Heilemann H, et al. Mutations in TITF1 are not relevant to sporadic and familial chorea of unknown cause. *Mov Disord* 2006;21:1734-7.
 10. Devriendt K, Vanhole C, Matthijs G, de Zegher F. Deletion of thyroid transcription factor-1 gene in an infant with neonatal thyroid dysfunction and respiratory failure. *N Engl J Med* 1998;338:1317-8.
 11. Iwatani N, Mabe H, Devriendt K, Kodama M, Miike T. Deletion of NKX2.1 gene encoding thyroid transcription factor-1 in two siblings with hypothyroidism and respiratory failure. *J Pediatr* 2000;137:272-6.
 12. Devos D, Vuillaume I, de Becdelievre A, de Martinville B, Dhaenens CM, Cuvellier JC, et al. New syndromic form of benign hereditary chorea is associated with a deletion of TITF-1 and PAX-9 contiguous genes. *Mov Disord* 2006;21:2237-40.
 13. Carre A, Szinnai G, Castanet M, Sura-Trueba S, Tron E, Broutin-L'Hermite I, et al. Five new TTF1/NKX2.1 mutations in brain-lung-thyroid syndrome: rescue by PAX8 synergism in one case. *Hum Mol Genet* 2009;18:2266-76.
 14. Fons C, Rizzu P, Garcia-Cazorla A, Martorell L, Ormazabal A, Artuch R, et al. TITF-1 gene mutation in a case of sporadic non-progressive chorea. Response to levodopa treatment. *Brain Dev* 2011.
 15. Doyle DA, Gonzalez I, Thomas B, Scavina M. Autosomal dominant transmission of congenital hypothyroidism, neonatal respiratory distress, and ataxia caused by a mutation of

- NKX2-1. *J Pediatr* 2004;145:190-3.
16. Pohlenz J, Dumitrescu A, Zundel D, Martine U, Schonberger W, Koo E, et al. Partial deficiency of thyroid transcription factor 1 produces predominantly neurological defects in humans and mice. *J Clin Invest* 2002;109:469-73.
 17. Nagasaki K, Narumi S, Asami T, Kikuchi T, Hasegawa T, Uchiyama M. Mutation of a gene for thyroid transcription factor-1 (TITF1) in a patient with clinical features of resistance to thyrotropin. *Endocr J* 2008;55:875-8.
 18. Guillot L, Carre A, Szinnai G, Castanet M, Tron E, Jaubert F, et al. NKX2-1 mutations leading to surfactant protein promoter dysregulation cause interstitial lung disease in "Brain-Lung-Thyroid Syndrome". *Hum Mutat* 2010;31:E1146-62.
 19. Moya CM, Perez de Nanclares G, Castano L, Potau N, Bilbao JR, Carrascosa A, et al. Functional study of a novel single deletion in the TITF1/NKX2.1 homeobox gene that produces congenital hypothyroidism and benign chorea but not pulmonary distress. *J Clin Endocrinol Metab* 2006;91:1832-41.
 20. Ferrara AM, De Michele G, Salvatore E, Di Maio L, Zampella E, Capuano S, et al. A novel NKX2.1 mutation in a family with hypothyroidism and benign hereditary chorea. *Thyroid* 2008;18:1005-9.
 21. Salvatore E, Di Maio L, Filla A, Ferrara AM, Rinaldi C, Sacca F, et al. Benign hereditary chorea: clinical and neuroimaging features in an Italian family. *Mov Disord* 2010;25:1491-6.
 22. Asmus F, Horber V, Pohlenz J, Schwabe D, Zimprich A, Munz M, et al. A novel TITF-1

- mutation causes benign hereditary chorea with response to levodopa. *Neurology* 2005;64:1952-4.
23. Provenzano C, Veneziano L, Appleton R, Frontali M, Civitareale D. Functional characterization of a novel mutation in TITF-1 in a patient with benign hereditary chorea. *J Neurol Sci* 2008;264:56-62.
 24. Glik A, Vuillaume I, Devos D, Inzelberg R. Psychosis, short stature in benign hereditary chorea: a novel thyroid transcription factor-1 mutation. *Mov Disord* 2008;23:1744-7.
 25. do Carmo Costa M, Costa C, Silva AP, Evangelista P, Santos L, Ferro A, et al. Nonsense mutation in TITF1 in a Portuguese family with benign hereditary chorea. *Neurogenetics* 2005;6:209-15.
 26. Narumi S, Muroya K, Asakura Y, Adachi M, Hasegawa T. Transcription factor mutations and congenital hypothyroidism: systematic genetic screening of a population-based cohort of Japanese patients. *J Clin Endocrinol Metab* 2010;95:1981-5.
 27. Maquet E, Costagliola S, Parma J, Christophe-Hobertus C, Oligny LL, Fournet JC, et al. Lethal respiratory failure and mild primary hypothyroidism in a term girl with a de novo heterozygous mutation in the TITF1/NKX2.1 gene. *J Clin Endocrinol Metab* 2009;94:197-203.
 28. Kleiner-Fisman G, Lang AE. Benign hereditary chorea revisited: a journey to understanding. *Mov Disord* 2007;22:2297-305; quiz 452.
 29. Yi M, Tong GX, Murry B, Mendelson CR. Role of CBP/p300 and SRC-1 in transcriptional

regulation of the pulmonary surfactant protein-A (SP-A) gene by thyroid transcription factor-1 (TTF-1). *J Biol Chem* 2002;277:2997-3005.

30. Yan C, Naltner A, Conkright J, Ghaffari M. Protein-protein interaction of retinoic acid receptor alpha and thyroid transcription factor-1 in respiratory epithelial cells. *J Biol Chem* 2001;276:21686-91.
31. Naltner A, Ghaffari M, Whitsett JA, Yan C. Retinoic acid stimulation of the human surfactant protein B promoter is thyroid transcription factor 1 site-dependent. *J Biol Chem* 2000;275:56-62.
32. Liu C, Glasser SW, Wan H, Whitsett JA. GATA-6 and thyroid transcription factor-1 directly interact and regulate surfactant protein-C gene expression. *J Biol Chem* 2002;277:4519-25.
33. Bachurski CJ, Yang GH, Currier TA, Gronostajski RM, Hong D. Nuclear factor I/thyroid transcription factor 1 interactions modulate surfactant protein C transcription. *Mol Cell Biol* 2003;23:9014-24.
34. Park KS, Whitsett JA, Di Palma T, Hong JH, Yaffe MB, Zannini M. TAZ interacts with TTF-1 and regulates expression of surfactant protein-C. *J Biol Chem* 2004;279:17384-90.
35. Maccabelli G, Pichiecchio A, Guala A, Ponzio M, Palesi F, Maranzana Rt D, et al. Advanced magnetic resonance imaging in benign hereditary chorea: study of two familial cases. *Mov Disord* 2010;25:2670-4.

Figure legends

Fig. 1. (A) Pedigree of the family. ■/● affected individuals; / deceased; → proband.

(B) Direct nucleotide sequencing of the PCR-amplified *TITF-1* gene DNA. The vertical arrow indicates nucleotide 294 (exon 1), where a C→G transversion resulted in an amino acid substitution (p.Y98X). Patient 1 (III-4) and patient 3 (II-4) were heterozygous for this mutation.

Legends to the supplementary data (Video)

Segment 1. Patient 1 (III-4) showed generalized choreic movements involving the neck, trunk, and limbs, both proximally and distally in the decubitus position.

Segment 2. Patient 1 (III-4) showed generalized marked choreic movements in the standing position.

Segment 3. Patient 1 (III-4) showed marked walking disability due to frequent choreic movements involving the lower limbs.

Segment 4. Ropinirole hydrochloride at 2 mg per day reduced choreic movement and improved walking disability of patient 1 (III-4).

Table 1. Mutations in the *TITF-1* gene and their implications at the protein and phenotypic level.

Changes in the DNA level	Consequence at the protein level	Phenotypes					Reference
		Classic BHC	Isolated CH	BHC with CH	CH with lung disease	BTLS	
large deletion						1	10
large deletion						2	11
large deletion						1	4
large deletion				1		2	12
large deletion						1	13
c.376-2A>G	splice site				1	1	13
c.463+1G>A	splice site					1	14
c.547-2A>G	splice site					4	15
c.255_256insG	p.Y86fs					1	16
c.470delGCG	p.P157fs					1	17
c.789delCC	p.L263fs					1	18
c.825delC	p.P276fs		2	1			19
c.859_860insC	p.Q287fs					1	8
2595insGG*	frameshift*			1			4
C1302A*	nonsense*					1	4
C2519A*	nonsense*			1			4
c.294C>G	p.Y98X			2		1	present study
609C>A*	p.S145X			2		1	20, 21
c.523G>T	p.E175X			1		3	22
c.532C>T	p.R178X	1					23
c.650C>A	p.S217X			2		1	24
c.745C>T	p.Q249X	2					25
G2626T*	missense*					1	4
c.178C>T	p.H60W		1				26
c.493C>T	p.R165W					1	18
C>G*	p.L176V			1			13
C>T*	p.P202L			1			13
c.619A>T	p.I207F					1	27
A>C*	p.Q210P			1			13
Total number of patients		3	3	14	3	25	

Descriptions of sequence variants in DNA and protein sequences follow the Human Genome Variation Society nomenclature guidelines (standard description). *Descriptions of sequence variants follow the original manuscripts as it was impossible to convert them into standard descriptions due to the lack of information. Numbers in the phenotype columns indicate numbers of patients reported. BHC, benign hereditary chorea; CH, congenital hypothyroidism; BTLS; Brain-Thyroid-Lung syndrome.

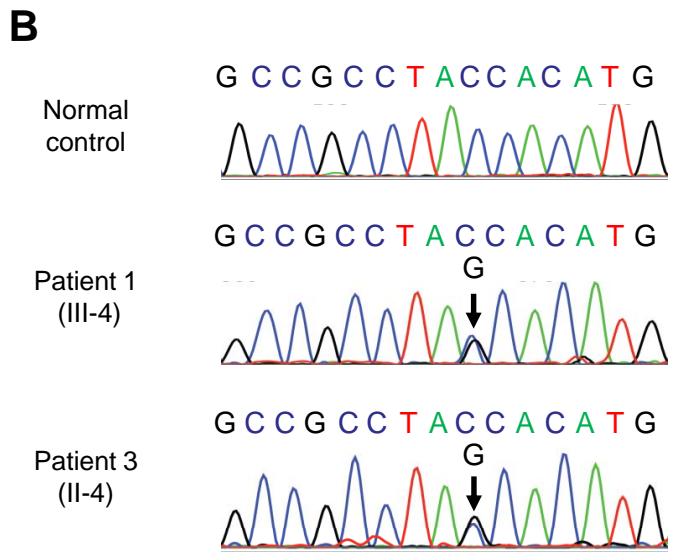
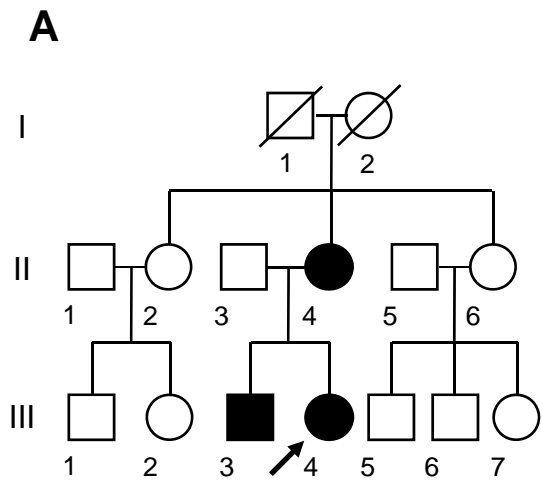


Figure 1

Nakamura et al.