

## **Key point in dermoscopic differentiation between early nail apparatus melanoma and benign longitudinal melanonychia**

Hiroshi KOGA,<sup>1,2</sup> Toshiaki SAIDA,<sup>1</sup> Hisashi UHARA<sup>1</sup>

<sup>1</sup>Department of Dermatology, Shinshu University School of Medicine, <sup>2</sup>Clinical Trial Center, Shinshu University Hospital, Matsumoto, Japan

### **Abstract**

Longitudinal melanonychia presents in various conditions including neoplastic and reactive disorders. It is much more frequently seen in non-Caucasians than Caucasians. While most cases of nail apparatus melanoma start as longitudinal melanonychia, melanocytic nevi of the nail apparatus also typically accompany longitudinal melanonychia. Identifying the suspicious longitudinal melanonychia is therefore an important task for dermatologists. Dermoscopy provides useful information for making this decision. The most suspicious dermoscopic feature of early nail apparatus melanoma is irregular lines on a brown background. Evaluation of the irregularity may be rather subjective, but through experience, dermatologists can improve their diagnostic skills of longitudinal melanonychia, including benign conditions showing regular lines. Other important dermoscopic features of early nail apparatus melanoma are micro-Hutchinson's sign, a wide pigmented band, and triangular pigmentation on the nail plate. Although there is as yet no solid evidence concerning the frequency of dermoscopic follow up, we recommend checking the suspicious longitudinal melanonychia every 6 months. Moreover, patients with longitudinal melanonychia should be asked to return to the clinic quickly if the lesion shows obvious changes. Diagnosis of amelanotic or hypomelanotic melanoma affecting the nail apparatus is also challenging, but melanoma should be highly suspected if remnants of melanin granules are detected dermoscopically.

### **Key words:**

Dermoscopy, longitudinal melanonychia, micro-Hutchinson's sign, nail apparatus melanoma, nail apparatus nevus

## **Introduction**

Longitudinal pigmented bands on the nail plate present in various kinds of conditions, including melanocytic nevus, malignant melanoma, lentigo, racial/ethnic melanonychia, pigmented onychomycosis, pigmented Bowen's disease, drug-induced hyperpigmentation, and subungual hematoma.<sup>1,2</sup> Among them is longitudinal melanonychia, nail pigmentation due to melanin deposit. Longitudinal melanonychia is rare in Caucasians, being seen in only 1.4% of the population and most frequently in the thumb, followed by the great toe and the index.<sup>3</sup> Racial/ethnic melanonychia is observed in persons with dark skin and usually involves more than one nail. The prevalence of longitudinal melanonychia in a Japanese general population was reported to be 20–23% in 1933 and 11.4% in 1958, and was 0.8% among Chinese living in Canada according to a recent study.<sup>4</sup>

## **Nail apparatus melanoma**

Nail apparatus melanoma, also called subungual melanoma, is a malignant melanoma of acral lentiginous type. It can involve any part of the nail apparatus, including the nail matrix, the nail bed, and/or the nail folds,<sup>5</sup> although it most often occurs in the nail matrix and is first seen as longitudinal melanonychia. The relative rate of nail apparatus melanoma among all cutaneous melanomas is 0.31% in Australia,<sup>6</sup> 1.4% in England<sup>7</sup> and 2.8% in Scotland.<sup>8</sup> In contrast, in non-Caucasians, the relative rate is much higher; 10% in Japanese<sup>9</sup> and 17% in Hong Kong Chinese.<sup>10</sup> It is noteworthy that the absolute incidence of nail apparatus melanoma per 100,000 persons per year is almost the same among all races, suggesting that the lower relative rates in Caucasians are due to higher incidence of other types of malignant melanoma involving hair-bearing skin.

Nail apparatus melanoma more often affects the fingers than the toes (finger:toe in the Japanese population=1.6:1). This is in contrast to a higher prevalence of melanoma in the plantar skin compared to the palmar skin (sole:palm in Japanese=3.5:1). The digits most commonly affected by nail apparatus melanoma are the thumb followed by the great toe.<sup>11</sup> The causes of nail apparatus melanoma is still unknown. While sun exposure may have no causative influence, mechanical trauma could be an important etiological factor as patients often report a history of trauma. However, the precise pathomechanism of nail apparatus melanoma remains to be elucidated.<sup>12</sup>

The most advanced lesions of nail apparatus melanoma are easy to diagnose, but in the advanced stages, amputation of the involved digit is necessary in most cases, and prognosis is generally poor. The prognosis for amelanotic/hypomelanotic nail apparatus

melanoma, accounting for 20% of all nail apparatus melanomas,<sup>10</sup> is also poor because of delayed detection in most cases. To improve the prognosis, accurate detection of nail apparatus melanoma in the early curable phases is essential. Early nail apparatus melanoma is typically seen as longitudinal melanonychia, which is also seen in various benign conditions, among which nail apparatus nevus is the most common. In 1989, one of the authors (T.S.) proposed the following clinical criteria for early detection of nail apparatus melanoma: it manifests as longitudinal melanonychia which is 1) brown in color with variegated shades or homogeneously black, 2) >6 mm in width, 3) noticed during adulthood, and 4) accompanied by periungual pigmentation (Hutchinson's sign).<sup>13</sup> These criteria have limitations, however, since evolving lesions of early nail apparatus melanoma may first appear as narrower longitudinal melanonychia with not so variegated shades of brown. Dermatologists face a dilemma when they see patients with a lesion of longitudinal melanonychia that is difficult to diagnose: differential diagnosis is a challenging but crucial task to improve the prognosis of patients with nail apparatus melanoma.

Histopathology is still the gold standard for diagnosis of nail apparatus melanoma. However, such diagnosis also presents challenges because the histopathologic features of early nail apparatus melanoma are sometimes subtle.<sup>14</sup> In spite of these difficulties, we dermatologists must make a best effort to identify suspicious lesions of nail apparatus melanoma, and dermoscopy could help us with early detection.

### **Dermoscopic criteria for nail apparatus melanoma**

In 2002, Ronger et al reported the dermoscopic features of various kinds of nail pigmentation.<sup>15</sup> They listed 7 distinct dermoscopic features of longitudinal pigmented bands of the nail plate: 1) blood spots, 2) brown coloration of the background, 3) regular lines, 4) irregular lines, 5) grayish background, 6) micro-Hutchinson's sign, and 7) microscopic grooves. Among these features, grayish background overlaid by thin regular gray lines was detected in 93.8% of cases of drug-induced pigmentation and in 87.5% of cases of ethnic-type pigmentation (Figure 1), but not in any lesions of nail apparatus melanoma or nail apparatus nevus. The blood spots were characterized by proximal well-circumscribed dots or blotches and by a somewhat linear pattern on distal portions, with the color varying from purple-blue to reddish black. While the blood spots were characteristic of subungual hemorrhage, their presence did not rule out melanoma. The microscopic grooves were an unspecific feature and were seen in many types of ungual diseases.

Brown background pigmentation of the nail plate is common in melanocytic nevus

and malignant melanoma of the nail apparatus. The most important point in the evaluation of longitudinal melanonychia is the regularity of pigmented lines laid on the background; regular lines occur in nevus and irregular lines in melanoma. Definitions of the regular and irregular patterns, originally reported by Ronger et al and then refined by Braun et al, are given in the Table.<sup>16</sup> Even using these criteria, evaluation of regularity of the pigmented lines is essentially subjective, and making a correct judgment is sometimes very difficult when trying to differentiate early evolving lesions of the nail apparatus melanoma from nail apparatus nevus. When the regularity of the pigmented lines is difficult to judge, periodic dermoscopic follow-up is recommended. When detecting any subtle irregularity of the lines during follow-up, the nail should be biopsied for histopathologic evaluation. As one example, in Figure 2, panel (a), the longitudinal melanonychia of the left thumb of a 58-year-old woman showed no distinct irregularity when we first saw her, but color density and width of the pigmented lines substantially changed over 2 years of follow-up (panels (b) and (c)). Therefore, we suspected early nail apparatus melanoma and biopsied the nail. Histopathologically, the lesion was diagnosed as melanoma in situ. This case indicates that very early lesions of nail apparatus melanoma may show rather regular lines on dermoscopy. In addition, histopathologic diagnosis of early evolving lesions of nail apparatus melanoma may be difficult because proliferation and nuclear atypia of melanocytes could be subtle.<sup>17</sup>

Hutchinson's sign, originally reported by Sir Jonathon Hutchinson in 1886, is macroscopic pigmentation on the periungual skin and is characteristic of nail apparatus melanoma (Figure 3(a)). Periungual pigmentation must be checked not only in the proximal and lateral nail folds but also in hyponychial skin. If pigmentation is detected in the hyponychium, dermoscopic findings at this site will be extremely helpful in determining the diagnosis; a parallel ridge pattern indicates melanoma, while a parallel furrow or regular fibrillar pattern suggests benign nevus. On the other hand, micro-Hutchinson's sign is defined by pigmentation of the cuticle seen on dermoscopy but not with the naked eye. Micro-Hutchinson's sign is a highly characteristic dermoscopic feature of early nail apparatus melanoma, although the sensitivity is not high (Figure 3(b)).<sup>15</sup> Other clinical and/or dermoscopic findings helpful in detecting early nail apparatus melanoma include broad brownish pigmentation covering most areas of the nail plate (Figure 4(a)) and a longitudinal pigmented band which is wider at the proximal portions compared to the distal portions, producing a triangular pigmentation on the nail plate (Figure 4(b)).<sup>2</sup>

In terms of the morphological characteristics of melanocytic nevus involving the nail apparatus of infants, the nevus occasionally shows broad pigmentation of the nail

plate with some variegation of the brown color, mimicking nail apparatus melanoma (Figure 5). Parents tend to be anxious about the prominent pigmentation not only due to biological reasons but also esthetic ones. Nail apparatus melanoma is extremely rare in infants,<sup>18</sup> and interestingly, although such pigmentation first shows a rather rapid increase in width and color density, after a variable period, the pigmentation stabilizes and typically regresses by adolescence. Even complete regression is possible.

### **Threshold between regular lines and irregular lines**

As mentioned above, the most important point in the dermoscopic differentiation between nail apparatus nevus and early malignant melanoma affecting the nail apparatus is the regularity of the pigmented lines composing the longitudinal pigmented bands, and judgment of the regularity may be rather subjective. Recently, we investigated the validity of the definitions of regular and irregular patterns proposed by Braun et al.<sup>16</sup> As shown in Figure 6, a total of 40 dermoscopic images of longitudinal melanonychia were prepared, in which only images of the nail plate portion were trimmed in order to exclude Hutchinson's sign on the periungual skin, which was observed in 5 lesions. Four residents with 1 year of experience in clinical dermatology were given the definitions of the regular and irregular patterns as shown in the Table and then they independently judged whether the lines in each case, as seen on a color monitor, were regular or irregular. They were not informed about the number of cases of nail apparatus melanoma included in this study. In fact, there were a total of 10 cases of nail apparatus melanoma including 8 lesions of in situ melanoma and the other 30 cases were nail apparatus nevus or melanocytic activation. The results are shown in Figure 7, in which melanomas are indicated by "in situ" or the tumor thickness. The 4 colored circles (denoting 4 different residents) shown on the images indicate which resident diagnosed the lesions as nail apparatus melanoma based on the presence of an irregular pattern. The correct answer rates are given in the bottom right of Figure 7. Two residents correctly diagnosed 8 of 10 melanomas and the remaining 2 residents 7 of 10 melanomas. The mean detection rate of melanoma was 75%, which was obtained only by judging the dermoscopic regularity of the pigmented lines. Hence, the diagnostic power of the regularity seems encouraging.

We are currently developing an automatic diagnostic method, which uses a novel objective index calculated from mathematical analysis of dermoscopy images of longitudinal melanonychia (Koga H, et al: unpublished data).

### **Management of longitudinal melanonychia**

Apparently invasive nail apparatus melanoma is surgically treated. When longitudinal melanonychia of adult onset shows irregular lines or micro-Hutchinson's sign, biopsy should be performed for histopathologic evaluation.<sup>19</sup> Management of ambiguous or suspicious longitudinal melanonychia, on the other hand, can be challenging. Longitudinal melanonychia with grayish background overlaid by thin gray lines generally suggests a benign lesion such as drug-induced or ethnic-type pigmentation. Even in lesions that are likely benign, it is important to examine carefully whether the lesions have irregular lines. Longitudinal melanonychia with regular lines should also be followed up if it shows somewhat variegated shades of brown or if the lines are broad. Excluding the stereotypical features of blood spots in subungual hemorrhage, the presence of blood spots does not rule out the possibility of melanoma since they can coexist with longitudinal melanonychia. Such suspicious lesions also should be followed periodically.

Although there is no solid evidence concerning adequate frequency of follow-up, we recommend checking suspicious lesions every 6 months. If dermoscopic changes are detected during the follow up, biopsy of the lesions should be performed for histopathologic examination. In addition, patients with longitudinal melanonychia should be asked to return to the clinic if the lesion shows obvious changes.

Amelanotic or hypomelanotic melanoma affecting the nail apparatus is very difficult to diagnose not only clinically but also dermoscopically.<sup>20</sup> When encountering a monodactylic nail lesion clinically mimicking lichen planus or pyogenic granuloma, malignant melanoma must be included in the differential diagnosis. Dermoscopy could be useful in such cases. Malignant melanoma should be highly suspected if remnants of melanin granules and/or characteristic polymorphous vessels are detected on dermoscopy.

## REFERENCES

1. Haneke E, Baran R. Longitudinal melanonychia. *Dermatol Surg.* 2001 ; **27**: 580-584
2. Tosti A, Piraccini BM, de Farias DC. Dealing with melanonychia. *Semin Cutan Med Surg.* 2009 ;**28**: 49-54
3. Duhard E, Calvet C, Mariotte N, Tichet J, Vaillant L. Prevalence of longitudinal melanonychia in the white population. *Ann Dermatol Venereol.* 1995;**122**:586-590.
4. Leung AK, Robson WL, Liu EK, *et al.* Melanonychia striata in Chinese children and adults. *Int J Dermatol.* 2007 ;**46**: 920-922.
5. Saida T. Heterogeneity of the site of origin of malignant melanoma in ungual areas:

- “subungual” malignant melanoma may be a misnomer. *Br J Dermatol* 1992;**126**:529
6. Quinn MJ, Thompson JE, Crotty K, McCarthy WH, Coates AS. Subungual melanoma of the hand. *J Hand Surg Am.* 1996 ;**21** :506-511.
  7. Banfield CC, Redburn JC, Dawber RP. The incidence and prognosis of nail apparatus melanoma. A retrospective study of 105 patients in four English regions. *Br J Dermatol.* 1998 ;**139**:276-279.
  8. Blessing K, Kernohan NM, Park KG. Subungual malignant melanoma: clinicopathological features of 100 cases. *Histopathology.* 1991 ;**19** :425-429.
  9. Ishihara K, Saida T, Otsuka F, Yamazaki N. The Prognosis and Statistical Investigation Committee of the Japanese Skin Cancer Society: Statistical profiles of malignant melanoma and other skin cancers in Japan: 2007 update. *Int J Clin Oncol.* 2008; **13**: 33-41,
  10. Collins RJ. Melanoma in the Chinese of Hong Kong. Emphasis on volar and subungual sites. *Cancer.* 1984 ;**54** :1482-1488.
  11. Thai KE, Young R, Sinclair RD. Nail apparatus melanoma. *Australas J Dermatol.* 2001 ;**42**:71-81
  12. Milton GW, Shaw HM, McCarthy WH. Subungual malignant melanoma: a disease entity separate from other forms of cutaneous melanoma. *Australas J Dermatol.* 1985 ;**26** :61-64.
  13. Saida T, Oshima Y. Clinical and histopathologic characteristics of early lesions of subungual malignant melanoma. *Cancer* 1989;**63** :556-560
  14. Husain S, Scher RK, Silvers DN, Ackerman AB. Melanotic macule of nail unit and its clinicopathologic spectrum. *J Am Acad Dermatol.* 2006 ;**54** :664-667.
  15. Ronger S, Touzet S, Ligeron C, *et al.* Dermoscopic examination of nail pigmentation. *Arch Dermatol.* 2002 ;**138**:1327-1333.
  16. Braun RP, Baran R, Le Gal FA, *et al.* Diagnosis and management of nail pigmentations. *J Am Acad Dermatol.* 2007 ;**56** :835-847.
  17. Amin B, Nehal KS, Jungbluth AA, *et al.* Histologic distinction between subungual lentigo and melanoma. *Am J Surg Pathol.* 2008 ;**32**:835-843.
  18. Goettmann-Bonvallet S, André J, Belaich S. Longitudinal melanonychia in children: a clinical and histopathologic study of 40 cases. *J Am Acad Dermatol.* 1999 ;**41**:17-22.
  19. Duarte AF, Correia O, Barros AM, Azevedo R, Haneke E. Nail matrix melanoma in situ: conservative surgical management. *Dermatology.* 2010;**220**:173-175.
  20. André J, Moulonguet I, Goettmann-Bonvallet S. In situ amelanotic melanoma of the nail unit mimicking lichen planus: report of 3 cases. *Arch Dermatol.* 2010 ;**146**:418-421.

## FIGURE LEGENDS

Figure 1. Ethnic-type melanonychia. (a) Nail of left thumb and index finger show grayish background and thin gray lines. (b) Histopathological examination of the lesion revealed increased melanin granule deposition without melanocyte proliferation.

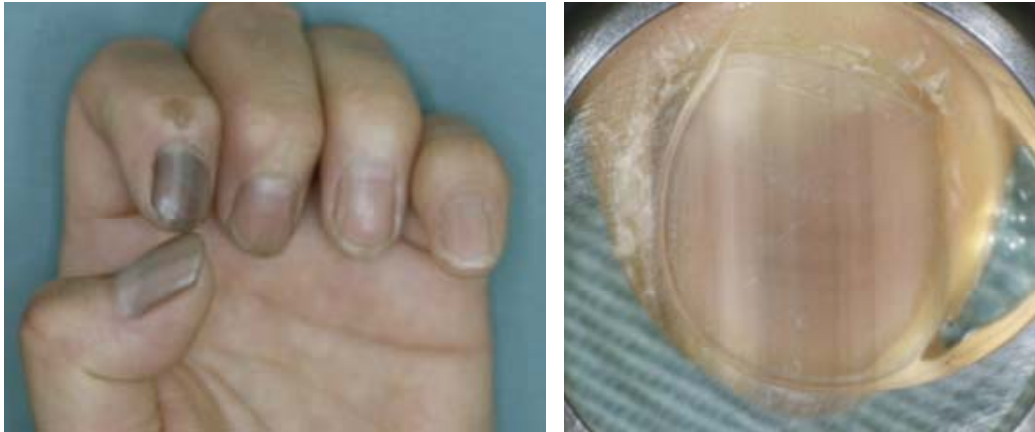

Figure 2. Longitudinal melanonychia affecting left thumb nail of a 58-year-old Japanese woman. Changes in width and color were detected during yearly follow up. Histopathological diagnosis was melanoma in situ. (a) Aug. 2008, (b) Oct. 2009, (c) Jan. 2010.

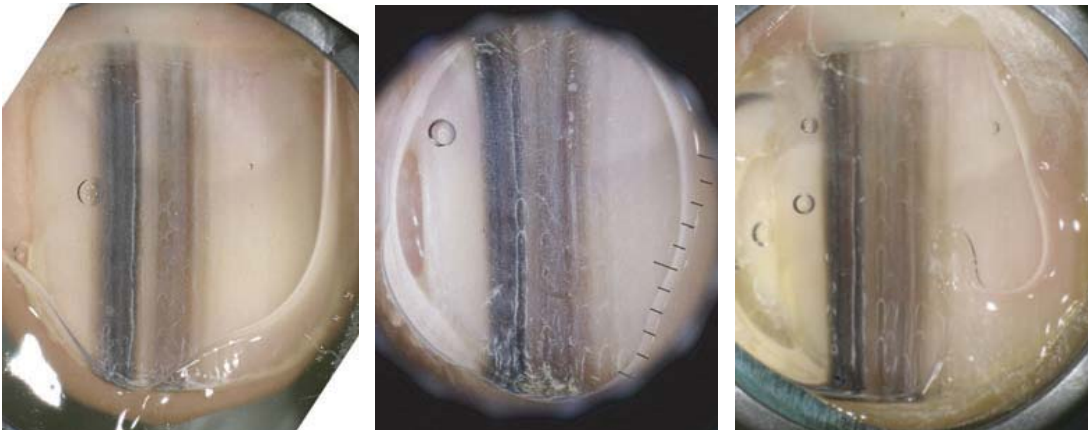




Figure 3. (a) Melanoma in situ in a 91-year-old man, showing broad irregular melanonychia accompanied by a prominent Hutchinson's sign. (b) Melanoma in situ in a 33-year-old woman. Although the lines of this melanonychia are not so irregular, micro-Hutchinson's sign is clearly apparent.

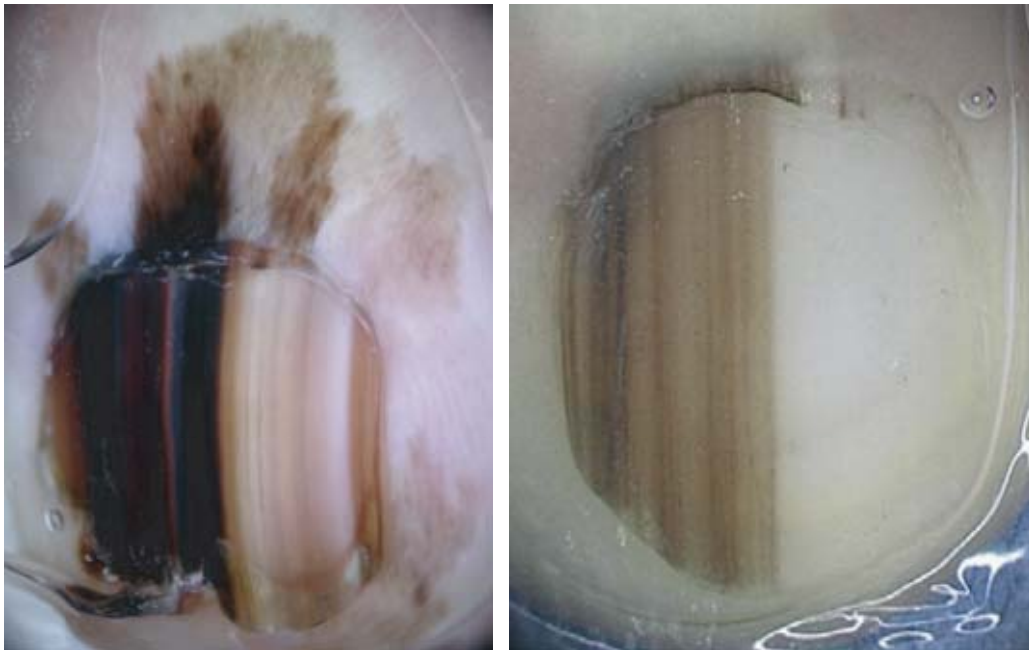


Figure 4. (a) Melanoma in situ in a 58-year-old woman showing wide, irregular pigmentation. (b) Melanoma in situ in a 28-year-old woman. In addition to Hutchinson's sign, the dark brown pigmentation is wider at the proximal portion than at the distal portion, showing a subtle triangular shape.



Figure 5. Nail apparatus nevus in infants and children showing broad longitudinal melanonychia. (a) Eight-year history of longitudinal melanonychia in 9-year-old girl on the right 5th finger. (b) Five-year history of longitudinal melanonychia in 13-year-old girl on the right 5th finger. (c) Eleven-year history of longitudinal melanonychia in 17-year-old boy on the left 4th finger.

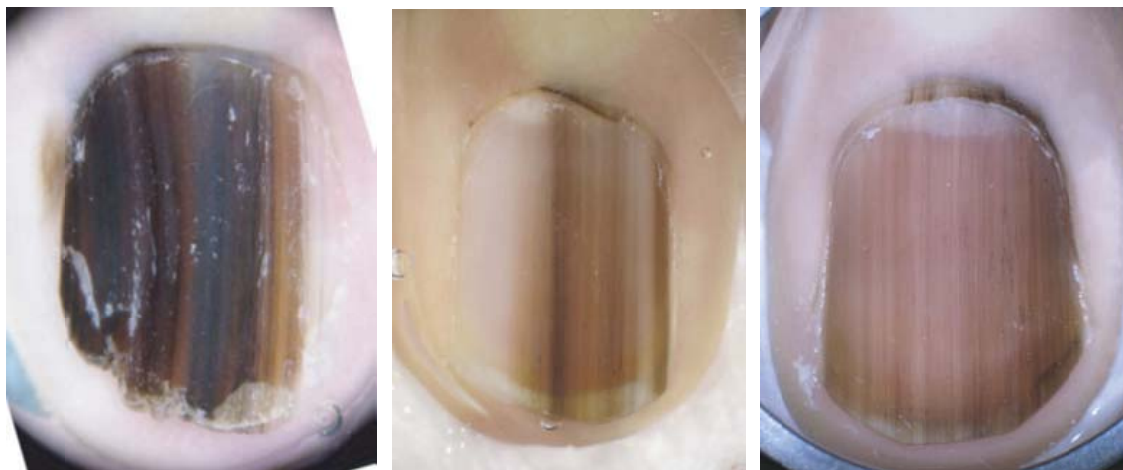


Figure 6. A total of 40 lesions of longitudinal melanonychia are used in examining differential diagnosis. Which images do you think fulfill the definition of the irregular pattern?




Figure 7. Ten of the 40 lesions were melanoma as indicated by “in situ” or tumor thickness on the images. Numbers in the right lower corner indicate the number of lesions judged as irregular by each resident. For example, the resident represented by the pink circle judged 14 images to show an irregular pattern, among which 7 were melanoma.

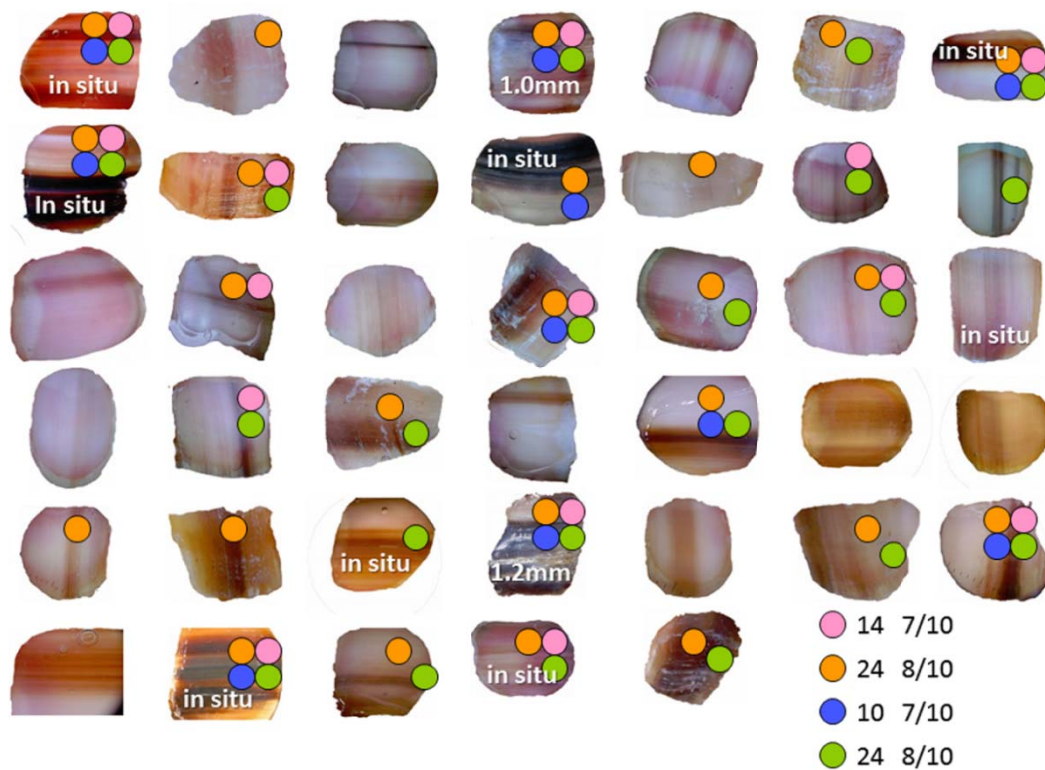


Table 1. Definition of regular pattern and irregular pattern by Brown et al. <sup>16</sup>

---

**Regular pattern:** *Brown longitudinal parallel lines with regular spacing and thickness.*

This pattern is usually associated with a brown homogenous color of the background band. The color of the individual lines within the band can vary from light brown to black. However, within any given band, the lines will be composed of similar shades of brown throughout the lesion. The spacing between the lines is regular and the thickness of the lines is relatively uniform throughout the band. The lines comprising the band are oriented parallel to each other.

**Irregular pattern:** *The band comprises multiple longitudinal brown to black lines with irregular spacing and thickness and disruption of parallelism.*

This pattern is also associated with a homogeneous brown pigmentation of the background nail band. However, the color of the individual lines varies from light brown to black. In fact it is common to observe many different colored lines within the nail band. The lines vary in their thickness and spacing. These lines, normally arranged parallel to each other, can lose their parallelism and cross into each other.

---

