

*Neurol Med Chir (Tokyo) 51, 163~167, 2011*

## **Three-Dimensional Magnetic Resonance Imaging Based on Time-of-Flight Magnetic Resonance Angiography for Superficial Cerebral Arteriovenous Malformation**

### **—Technical Note—**

Takahiro MURATA,<sup>1</sup> Tetsuyoshi HORIUCHI,<sup>1</sup> Nunung Nur RAHMAH,<sup>1</sup>  
Keiichi SAKAI,<sup>1</sup> and Kazuhiro HONGO<sup>1</sup>

<sup>1</sup>Department of Neurosurgery, Shinshu University School of Medicine, Matsumoto, Nagano

#### **Abstract**

Direct surgery remains important for the treatment of superficial cerebral arteriovenous malformation (AVM). Surgical planning on the basis of careful analysis from various neuroimaging modalities can aid in resection of superficial AVM with favorable outcome. Three-dimensional (3D) magnetic resonance (MR) imaging reconstructed from time-of-flight (TOF) MR angiography was developed as an adjunctive tool for surgical planning of superficial AVM. 3-T TOF MR imaging without contrast medium was performed preoperatively in patients with superficial AVM. The images were imported into OsiriX imaging software and the 3D reconstructed MR image was produced using the volume rendering method. This 3D MR image could clearly visualize the surface angioarchitecture of the AVM with the surrounding brain on a single image, and clarified feeding arteries including draining veins and the relationship with sulci or fissures surrounding the nidus. 3D MR image of the whole AVM angioarchitecture was also displayed by skeletonization of the surrounding brain. Preoperative 3D MR image corresponded to the intraoperative view. Feeders on the brain surface were easily confirmed and obliterated during surgery, with the aid of the 3D MR images. 3D MR imaging for surgical planning of superficial AVM is simple and noninvasive to perform, enhances intraoperative orientation, and is helpful for successful resection.

Key words: cerebral arteriovenous malformation, magnetic resonance imaging, surgical planning, three-dimensional image, time-of-flight magnetic resonance angiography

---

Received July 15, 2010; Accepted September 29, 2010

*Neurol Med Chir (Tokyo) 51, February, 2011*

## Introduction

Endovascular embolization and radiosurgery have been proposed as treatment options for the treatment of cerebral arteriovenous malformations (AVMs), but microsurgery remains an important treatment modality.<sup>9)</sup> However, surgical resection of a cerebral AVM often represents one of the most technically challenging procedures for neurosurgeons. Morbidity and mortality rates of microsurgical resection of AVM vary from 7.8–30% and 0–12.5%, respectively.<sup>1,4,8,14)</sup> Various factors affect the surgical outcome in cases of AVM, including Spetzler-Martin grade, compact or diffuse type of a nidus, presence of deep perforating arteries as feeders, and presentation with hemorrhage.<sup>5,12,16)</sup> One of the important factors for successful resection is a presurgical plan based on careful analysis of neuroimaging findings. Careful surgical planning will optimize operative exposure, reduce operative time, minimize blood loss, reduce potential complications, and improve overall outcomes.<sup>15)</sup> Contemporary planning can be carried out with two-dimensional imaging including conventional angiography, computed tomography (CT), and magnetic resonance (MR) imaging. However, methods of three-dimensional (3D) imaging including CT angiography, MR angiography, and rotational digital subtraction angiography (DSA) can be helpful in the surgical planning of AVM. 3D angiography can display the unique AVM angioarchitecture with spatial relationship to feeding arteries, nidus, and draining veins, but cannot demonstrate the details of the AVM components and surrounding brain on a single image. Recently, various 3D reconstructed images can be easily obtained using the volume rendering method.

Here, we describe 3D MR imaging for surgical planning of superficial AVM, based on time-of-flight (TOF) MR imaging without contrast medium using the volume rendering method, which allows concurrent display of the cerebral vasculature, AVM angioarchitecture, and the surrounding brain.

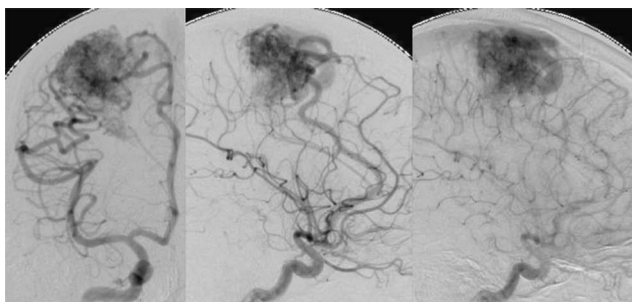
## Methods

3D TOF MR imaging without contrast medium was performed using a 3-T scanner (Magnetom TrioTim; Siemens Medical Solutions, Erlangen, Germany) and a standard head coil. Images were acquired using a gradient-echo sequence with the following parameters: repetition time 20 msec, echo time 3.69 msec, flip angle 16 degrees, field of view 200 × 171 mm, matrix 448 × 269, slice thickness 0.6 mm. Obtaining the images took approximately 8 minutes. Postprocessing was performed using an Apple

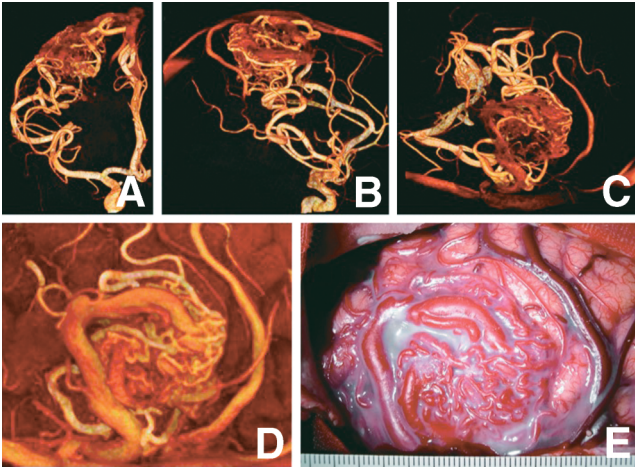
Macintosh laptop personal computer (Apple, Inc., Cupertino, California, USA) running OS X and open source OsiriX imaging software (version 3.2.1; OsiriX Foundation, Geneva, Switzerland; free download from <http://www.osirix-viewer.com/>). The Digital Imaging and Communications in Medicine (DICOM) images of TOF MR imaging were inverted. The OsiriX volume rendering algorithm was used to produce 3D reconstruction of the TOF MR images by selecting the color of the virtual reality muscles-bones and window level/width 200/300. Unneeded structures on the lesion, including the scalp, skull, and dura mater, were deleted using the scissors tool. Surfaces of the AVM angioarchitecture and the surrounding brain were visualized. The surrounding brain was skeletonized and a 3D image of the whole AVM angioarchitecture was displayed. This image could be rotated for viewing from various angles, including the expected surgical approach. These images were transformed into cine mode during change of the window level/width.

## Illustrative Case

A 15-year-old man presented with a 10-year history of recurrent seizure and was referred to our institution with a diagnosis of superficial AVM. DSA revealed a Spetzler-Martin grade III AVM in the right frontal lobe, fed by branches of the right anterior and middle cerebral arteries (Fig. 1). MR imaging demonstrated the nidus in the right precentral gyrus. Functional MR imaging showed left hand motor task activation located primarily in the right postcentral gyrus. 3D MR images reconstructed from DICOM images of TOF angiography displayed the whole AVM angioarchitecture during skeletoni-

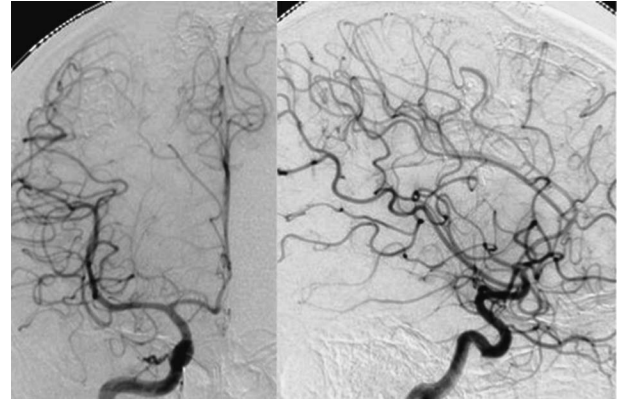


**Fig. 1** Representative case of a 15-year-old man with Spetzler-Martin grade III arteriovenous malformation in the right frontal lobe. Digital subtraction angiograms (right internal carotid artery injection) showing filling of the nidus fed by branches of the anterior and middle cerebral arteries, and the single drainer to the superior sagittal sinus.



**Fig. 2** A–C: Preoperative three-dimensional (3D) magnetic resonance (MR) images of the whole arteriovenous malformation (AVM) angioarchitecture, based on time-of-flight MR angiography without contrast medium, showing spatial orientation of the lesion (A: anteroposterior view, B: lateral view, C: expected operative view). D: Preoperative 3D MR image showing concurrent visualization of the surface of the AVM angioarchitecture and surrounding brain. The 3D images clarify the relationship between the AVM angioarchitecture and sulci or fissures surrounding the nidus; one of the main feeders from the middle cerebral artery running in a deep part of the nidus, and other feeding arteries on the brain surface from the sulcus, and a single drainer above the nidus running out to the superior sagittal sinus. E: Intraoperative photograph showing good correspondence to the preoperative 3D image.

zation of surrounding brain (Fig. 2A–C), and clearly visualized the surface of AVM angioarchitecture with the surrounding brain on a single image (Fig. 2D). 3D MR imaging demonstrated the feeding arteries including the draining veins, and the relationship with sulci or fissures surrounding the nidus. Treatment planning emphasized resection of the nidus under intraoperative monitoring. Intraoperative view of the brain surface including the lesion corresponded well to the preoperative 3D MR image (Fig. 2E). After the primary motor cortex of the left hand was mapped and confirmed on the right postcentral gyrus, motor evoked potential was monitored. During surgery, all feeders except one vessel feeding deep tissues of the nidus were easily confirmed and obliterated, and the nidus was totally resected. DSA obtained 1 month after surgery showed complete resection of the AVM (Fig. 3). He presented with transient left hemiparesis postoperatively, but had fully recovered 3 months after surgery.



**Fig. 3** Postoperative digital subtraction angiograms (right internal carotid artery injection) obtained at 1 month following resection showing complete resection of the nidus.

## Discussion

This study shows that 3D MR imaging of superficial AVM could visualize not only the surface of the AVM but also the surrounding brain on a single image, and corresponded well to the intraoperative finding. 3D MR imaging of the whole AVM angioarchitecture was also displayed during skeletonization of the surrounding brain. Surgical resection of AVM depends on obliteration of all feeders before the main drainer is sacrificed. Generally, the procedure expose and identify the feeding arteries early in the operation. The sulci and fissures surrounding the nidus are sharply dissected to allow identification of feeders at a distance from the nidus.<sup>7,10</sup> Therefore, the good correspondence between the 3D MR imaging and intraoperative findings is helpful to allow quick and easy confirmation of feeding arteries on the surrounding gyri and sulci.

Recently, 3D interactive imaging systems or virtual reality systems have been developed for presurgical visualization, planning, and simulation of many neurosurgical procedures.<sup>3,6,11,13</sup> However, these systems require several neuroimaging data sets with or without contrast medium, proprietary software, and computer workstations. The present 3D technique for visualizing complex angioarchitecture with the nearby brain surface in cases of superficial AVM uses only the DICOM data of TOF MR angiography without contrast medium. TOF MR angiography without contrast medium is noninvasive and effective, so is widely performed to evaluate cerebral vasculatures and related lesions.<sup>2,17</sup> The technique uses OsiriX imaging software, which is a free, open-source DICOM imaging software system, can be installed on any Macintosh personal com-

puter, and can be easily operated by a neurosurgeon in a clinical environment. This technique does not require proprietary software, workstation, contrast medium, special MR imaging, or special training.

TOF MR angiography with a 3-T unit can visualize small arteries with a diameter of larger than approximately 1 mm, especially distal cortical arteries, with excellent quality.<sup>6)</sup> TOF MR angiography generally does not demonstrate the cortical veins because velocity encoding selects for arterial flow. However, TOF MR angiography may depict the draining veins because flow velocity in the drainers is higher than in the normal cortical veins. Therefore, most information about the angioarchitecture including feeders, nidus, and drainers in AVM can be obtained with 3-T TOF MR imaging. However, this technique has a few limitations due to the nature of TOF MR angiography. Hyperintensity of flow in a small nidus, nidus or drainer with relatively low flow velocity, and tiny vessels including perforating arteries cannot be captured. Additionally, if the surrounding brain of the lesion is skeletonized for display of the whole AVM angioarchitecture, such tiny vasculatures and low flow velocity veins fade together with the surrounding brain and are not clearly depicted. Visualization of these vessels and the nidus may require MR angiography with contrast medium using the TOF or phase contrast method. TOF MR angiography without contrast medium also cannot provide hemodynamic information of the AVM. Therefore, our technique is not superior to DSA. DSA is currently the golden standard for diagnosis, surgical planning, and follow-up examination of AVM, and essential to understand the flow dynamics of the malformation and to ascertain its nidus nature. Various 3D imaging methods can also visualize the complex AVM angioarchitecture with spatial orientation. However, the precise topographical relationship with the surrounding brain is not always adequately shown on such neuroimaging methods. Therefore, 3D MR imaging may provide complementary spatial information for resection of AVM.

3D MR imaging for surgical planning of superficial AVM, based on TOF MR angiography without contrast medium, allowed concurrent visualization of the AVM angioarchitecture and surrounding brain. This technique is simple and noninvasive to perform, improves intraoperative orientation, and is helpful for successful resection.

## References

- 1) Albert P: Personal experience in the treatment of 178 cases of arterio-venous malformations of the brain. *Acta Neurochir (Wien)* 61: 207–226, 1982
- 2) Anzalone N, Scomazzoni F, Strada L, Patay Z, Scotti G: Intracranial vascular malformations. *Eur Radiol* 8: 685–690, 1998
- 3) Bernardo A, Preul MC, Zabramski JM, Spetzler RF: A three dimensional interactive virtual dissection model to simulate transpetrous surgical avenues. *Neurosurgery* 52: 499–505, 2003
- 4) Davis C, Simon L: The management of cerebral arteriovenous malformations. *Acta Neurochir (Wien)* 74: 4–11, 1985
- 5) Du R, Keyoung HM, Dowd CF, Young WL, Lawton MT: The effects of diffuseness and deep perforating artery supply on outcomes after microsurgical resection of brain arterio-venous malformations. *Neurosurgery* 60: 638–646, 2007
- 6) Fischer G, Stadie A, Schwandt E, Gawehn J, Boor S, Marx J, Oertel J: Minimally invasive superficial temporal artery to middle cerebral artery bypass through a minicraniotomy: benefit of three-dimensional virtual reality planning using magnetic resonance angiography. *Neurosurg Focus* 26(5): e20, 2009
- 7) Hashimoto N: Microsurgery for cerebral arteriovenous malformations: A dissection technique and its theoretical implications. *Neurosurgery* 48: 1278–1281, 2001
- 8) Heros RC, Korosue K, Diebold PM: Surgical excision of cerebral arteriovenous malformations: late results. *Neurosurgery* 26: 570–578, 1990
- 9) Heros RC, Morcos JJ: Cerebrovascular surgery: past, present, and future. *Neurosurgery* 47: 1007–1033, 2000
- 10) Kobayashi S, Goel A, Hongo K: *Neurosurgery of Complex Tumors and Vascular Lesions*. New York, Churchill Livingstone, 1977, pp 127–138
- 11) Kockro RA, Serra L, Tseng-Tsai Y, Chan C, Yih-Yian S, Gim-Guan C, Lee E, Hoe LY, Hern N, Nowinski WL: Planning and simulation of neurosurgery in a virtual reality environment. *Neurosurgery* 46: 118–137, 2000
- 12) Lawton MT, Du R, Tran MN, Achrol AS, McCulloch CE, Johnston SC, Quinnine NJ, Young WL: Effect of presenting haemorrhage on outcome after microsurgical resection of brain arterio-venous malformations. *Neurosurgery* 56: 485–493, 2005
- 13) Ng I, Hwang PY, Kumar D, Lee CK, Kockro RA, Sitoh YY: Surgical planning for microsurgical excision of cerebral arterio-venous malformations using virtual reality technology. *Acta Neurochir (Wien)* 151: 453–463, 2009
- 14) Parkinson D, Bachers G: Arterio-venous malformations. Summary of 100 consecutive supratentorial cases. *J Neurosurg* 53: 285–299, 1980
- 15) Russell SM, Woo HH, Joseffer SS, Jafar JJ: Role of frameless stereotaxy in the surgical treatment of cerebral arteriovenous malformations: techniques and outcomes in a controlled study of 44 consecutive patients. *Neurosurgery* 51: 1108–1118, 2002
- 16) Spetzler RF, Martin NA: A proposed grading system

- for arterio-venous malformations. *J Neurosurg* 65: 476-483, 1986
- 17) Wilms G, Demaerel P, Bosmans H, Marchal G: MRI of non-ischemic vascular disease: aneurysms and vascular malformations. *Eur Radiol* 9: 1055-1060, 1999

---

*Address reprint requests to:* Takahiro Murata, MD, Department of Neurosurgery, Shinshu University School of Medicine, 3-1-1 Asahi, Matsumoto 390-8621, Japan.