

# Azacitidine Treatment Following Intensive Chemotherapy with Daunorubicin and Cytarabin for Acute Transformation in Myelodysplastic/Myeloproliferative Neoplasms

Toru KAWAKAMI<sup>1)\*</sup>, Kaoko SAKAI<sup>2)</sup>, Sayaka NISHINA<sup>2)</sup>, Yuto MIMURA<sup>1)</sup>  
Takaaki MIYAHIRA<sup>1)</sup>, Yasushi SENOO<sup>1)</sup>, Hideyuki NAKAZAWA<sup>1)</sup> and Kiyoshi KITANO<sup>1)</sup>

1) *Department of Hematology, NHO Matsumoto Medical Center*

2) *Division of Hematology, Department of Internal Medicine, Shinshu University School of Medicine*

We report here a case of a 70-year-old male with myelodysplastic/myeloproliferative neoplasms (MDS/MPN) having hepatosplenomegaly, mild monocytosis, and normal karyotypes without JAK2 mutation. The patient developed an acute transformation and during the intensive therapy with daunorubicin and cytarabin, diffuse alveolar hemorrhage appeared due to disseminated intravascular coagulopathy. After induction, bone marrow blasts reduced to 5.1%, and the patient received two courses of azacitidine therapy. During these courses, blasts in the peripheral blood were not observed. Intensive chemotherapy consisting of daunorubicin and cytarabin followed by azacitidine therapy might be effective for acute transformation in MDS/MPN. *Shinshu Med J 62 : 167—172, 2014*

(Received for publication December 16, 2013 ; accepted in revised form January 30, 2014)

---

**Key words** : myelodysplastic–myeloproliferative diseases, azacitidine, acute transformation

---

## I Introduction

MDS/MPN include clonal myeloid neoplasms that at the time of initial presentation have some clinical, laboratory or morphologic findings that support myelodysplastic syndrome (MDS), and other findings more consistent with myeloproliferative neoplasms (MPN) according to the WHO classification 2008. This diagnostic category includes chronic myelomonocytic leukemia (CMML), atypical chronic myeloid leukemia (aCML), juvenile myelomonocytic leukemia (JMML) and myelodysplastic/myeloproliferative neoplasm, unclassifiable (MDS/MPN, U). The WHO classification defined CMML I and CMML II according to medullary and peripheral blast count. It is

well established that the blast percentage is correlated significantly with the outcome in a patient with clonal myeloid disease<sup>1)</sup>.

For those ineligible for stem cell transplantation, promising therapeutic options with long-term survival seem to be limited. Azacitidine (AZA) demonstrated significantly prolonged overall survival in patients with MDS<sup>2)</sup>. AZA is also used for patients who suffer from CMML and MPN<sup>3)4)</sup>. However, the usefulness of AZA in MDS/MPN has not been well determined. Here, we report a case of MDS/MPN transformed into acute myelomonocytic leukemia (AMML) who underwent AZA treatment after reduction of increased blasts by intensive chemotherapy with a combination of daunorubicin (DNR) and cytarabin (Ara-C).

## II Case Report

A 70-year-old male was referred to our hospital because of left flank pain in June 2011. Hepatosplenomegaly was found on physical examination

---

\* Correspondence author : Toru Kawakami

Department of Hematology, NHO Matsumoto Medical Center, 2-20-30 Muraimachi-minami, Matsumoto, Nagano 399-8701, Japan

E-mail : yfa74377@nifty.com

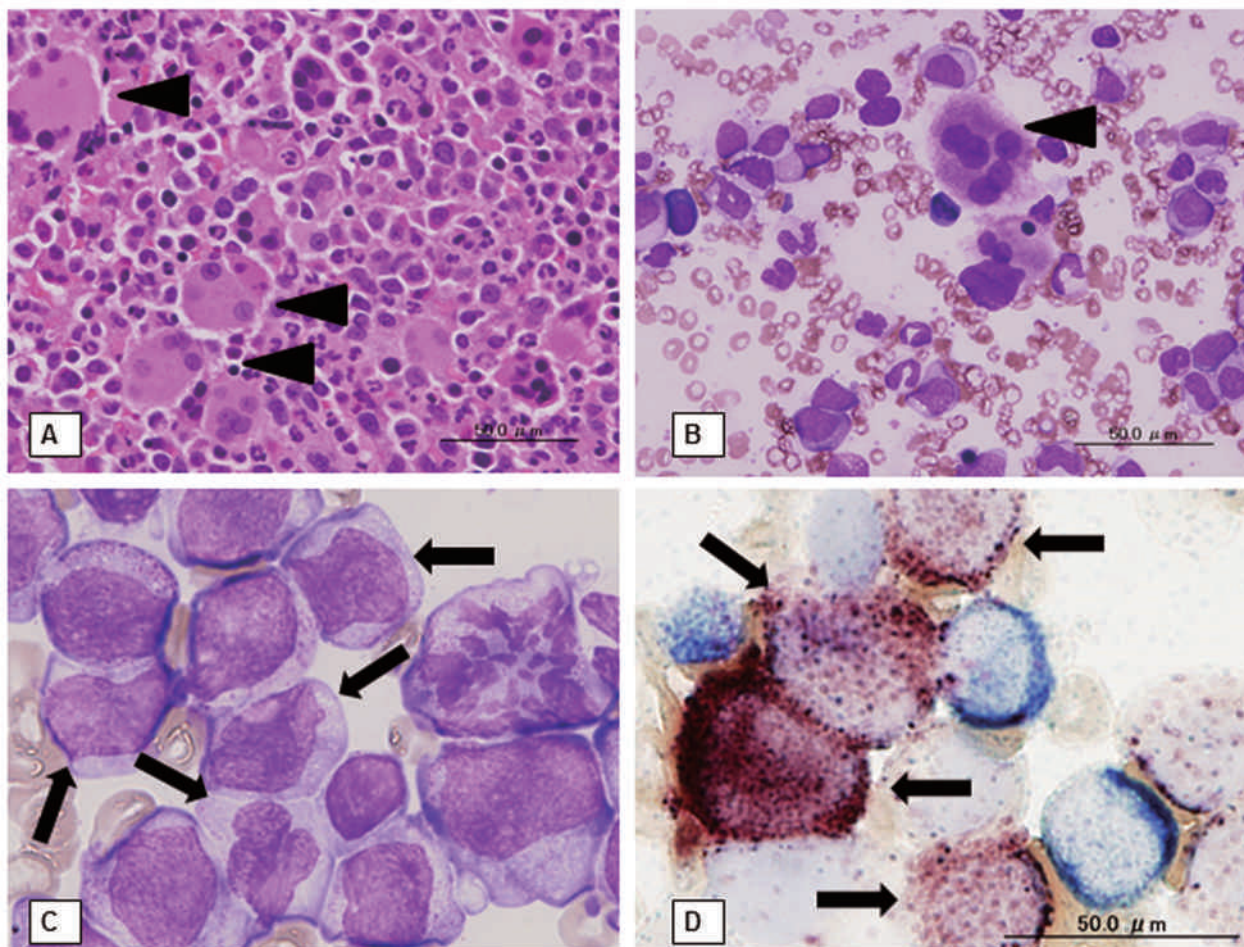


Fig. 1 Bone marrow examinations

**A** Bone marrow biopsy (hematoxylin-eosin,  $\times 400$ ) and **B** smear (Wright-Giemsa,  $\times 400$ ) in June 2011. Trilineage dysplastic features including multiple, widely-separated megakaryocytes (arrow head) were revealed.

**C**, **D** Bone marrow aspiration (**C** hematoxylin-eosin,  $\times 1,000$  and **D** double staining of naphthol AS-D chloroacetate esterase and  $\alpha$ -naphthyl butyrate esterase,  $\times 1,000$ ) in January 2012. Myeloblasts and monoblasts (arrow) are both seen.

and the laboratory data showed a white blood cell (WBC) count of  $43.16 \times 10^9/l$  (blasts 8 %, myelocytes 12 %, metamyelocytes 16 %, neutrophils 53 %, lymphocytes 6 %, atypical lymphocytes 2 %, monocytes 3 % ( $1.29 \times 10^9/l$ ), nucleated erythrocytes 49/100 WBC), hemoglobin concentration 8.0 g/dl, and platelet count  $476 \times 10^9/l$ . Neutrophil alkaline phosphatase score was decreased. The bone marrow examination revealed myeloid- and megakaryocytic - lineage hyperplasia with slight myelofibrosis and trilineage dysplastic features (Fig. 1A, B). The differential cell count on bone marrow showed 3.0 % myeloblasts, 6.4 % promyelocytes, 14.6 % myelocytes, 17.4 % neutrophils, 0.0 % eosinophils, 0.3 % basophils, 2.0 %

monocytes, 36.6 % erythroblasts, 0.8 % lymphocytes, 0.2 % plasma cells, and 0.6 % megakaryocytes. Karyotyping performed on the marrow aspirate revealed 46, XY (20/20). Fluorescence in situ hybridization using the BCR/ABL1 probe detected no fusion signals and JAK2 V617F mutation was negative. Monocytosis in the patient was fluctuating around  $1.0 \times 10^9/l$  and did not persist for 3 months. Therefore, the patient was given a diagnosis of aCML according to the WHO classification 2008. However, the differential diagnosis between aCML and CMML seemed to be difficult.

Although the patient was given oral hydroxyurea for two months, the number of WBC began to increase in the middle of December 2011 and rea-

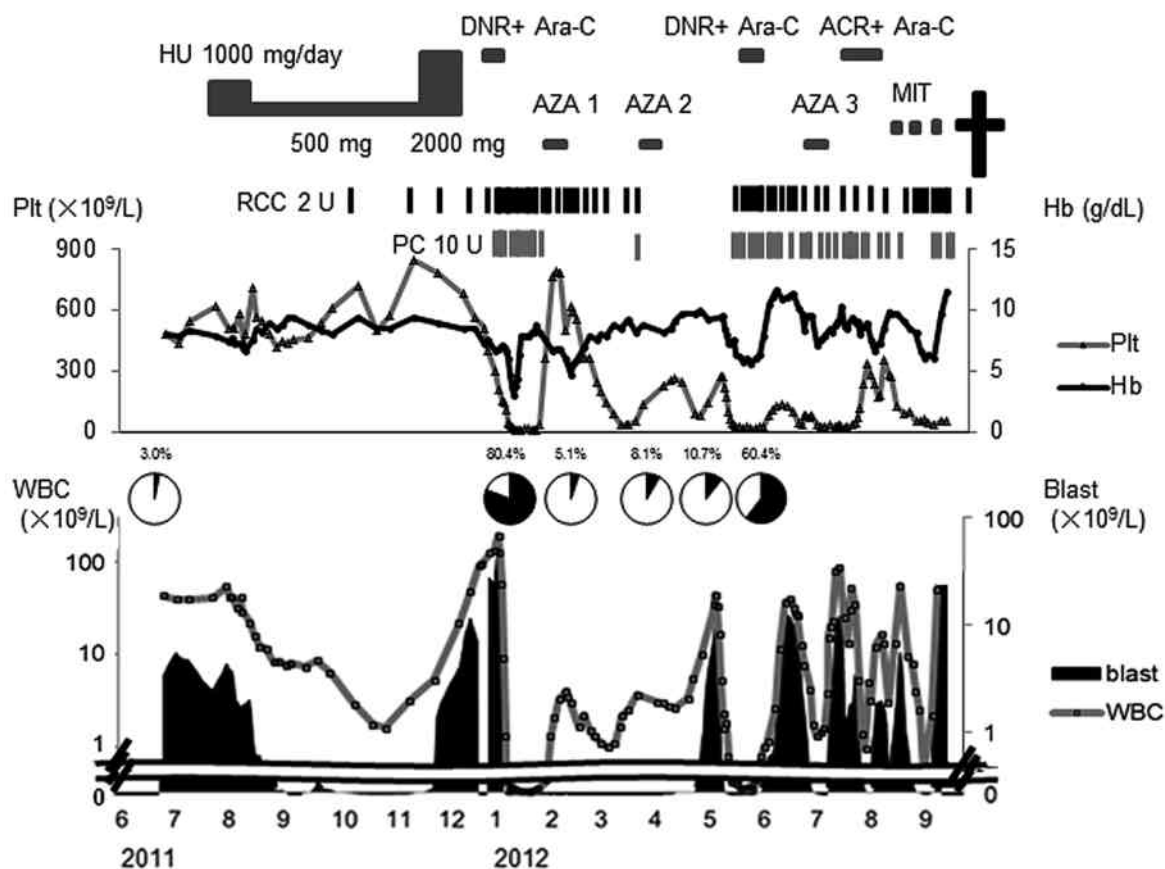


Fig. 2 Clinical course of this patient

Black portions of the circle graphs mean fractions of blasts in bone marrow. (HU ; hydroxyurea, DNR ; daunorubicin hydrochloride, Ara-C ; cytarabine, ACR ; aclarubicin hydrochloride, AZA ; azacitidine, Plt ; platelet, RCC ; red cell concentrates, PC ; platelet concentrates, MIT ; mitoxantrone)

ched  $134.74 \times 10^9/l$  (blasts 95 %) at the beginning of January 2012, when the diagnosis of acute transformation was made by bone marrow examination (Fig. 1C): blasts were positive for myeloperoxidase, either naphthol AS-D chloroacetate esterase or  $\alpha$ -naphthyl butyrate esterase (Fig. 1D), CD13, CD33, and CD34. Chromosomal analysis using the bone marrow aspirate revealed a normal karyotype (20/20). Induction therapy consisting of DNR at 35 mg/m<sup>2</sup> once daily i.v. for 5 consecutive days and Ara-C at 70 mg/m<sup>2</sup> c.i.v. for 7 days (DNR+Ara-C) was performed. It was complicated by disseminated intravascular coagulopathy (DIC) and diffuse alveolar hemorrhage, and the patient temporarily required intensive care. A month after induction therapy, the laboratory data showed a WBC count of  $4.01 \times 10^9/l$  (blasts 1 %, metamyelocytes 1 %, neutrophils 86 %, lymphocytes 6 %, monocytes 6 %

( $0.24 \times 10^9/l$ )), hemoglobin concentration 4.7 g/dl, and platelet count  $618 \times 10^9/l$ . The bone marrow aspiration showed reduced blast count (5.1 %) and trilineage dysplastic features. At this point, the patient experienced upper gastrointestinal bleeding and received intravenous therapy with a proton pump inhibitor. Performance status was 4.

Subsequently, the patient was treated with AZA (75 mg/m<sup>2</sup> once daily s.c. for 7 consecutive days) and the blasts in peripheral blood did not appear during the first two courses. During the treatment with AZA, the toxicity observed was only hematological, and the patient's general condition improved. However, a skin rash on the whole body appeared after the two courses of AZA. The skin biopsy revealed infiltration of leukemic cells. The WBC increased with blasts again in May 2012 (Fig. 2). Neither the combinations of chemotherapies, such as DNR+

Ara-C, aclarubicin hydrochloride+Ara-C, nor single-agent administration of mitoxantrone hydrochloride were effective. The patient developed DIC and central nervous system infiltration and died in September 2012.

### III Discussion

According to the WHO Classification 2008, mature myeloid neoplasms are stratified in line with their biological features (myeloproliferative, with effective hematopoiesis, versus myelodysplastic, with ineffective hematopoiesis, as well as by genetic features). In the present case of MDS/MPN, however, the differential diagnosis between aCML and CMML seemed to be difficult. When the patient was referred to our hospital, monocytosis was mild and did not persist for 3 months, leading to the diagnosis of aCML. On the other hand, the fact that the immature monocytes gradually increased during the clinical course suggests a diagnosis of CMML. In this case, it might be categorized into CMML II due to the percentage of peripheral blasts.

Both aCML and CMML have a poor prognosis because of the high probability of acute transformation. It has been reported that the median survival was 24 months and blastic transformation preceded death in 31 % of patients with *bcr/abl* negative CML<sup>5)</sup>. In this report, a prognostic scoring system which stratified patients into two groups based on age, hemoglobin level, and WBC count was suggested and the patients in the high risk group were said to have a median survival of only 9 months. With regard to prognostic factors in aCML, a case series study indicated that the risk of leukemic evolution is associated with palpable hepato- or splenomegaly, monocytosis, bone marrow blastosis, marked dyserythropoiesis, and the need for transfusion<sup>6)</sup>. In this case, the prognosis was predicted to be poor because the patient had several risk factors for leukemic evolution: palpable hepatosplenomegaly, marked dyserythropoiesis, and the need for transfusion. It has been reported that the median survival was 20 months for CMML I and 15 months for CMML II, and that the cumulative risk of AML

evolution in CMMLII was higher than that in CMML I<sup>7)</sup>. A retrospective analysis of 213 CMML patients revealed that a hemoglobin level below 12 g/dL, the presence of circulating immature cells, an absolute lymphocyte count above  $2.5 \times 10^9/L$ , and marrow blasts of 10 % or more were independently associated with shorter survival by multivariate analysis, and high risk patients who had four risk factors were estimated to have a median survival of 5 months<sup>8)</sup>. In summary, the prognosis of the present case was estimated to be less than 1 year.

AZA is a hypomethylating agent and the mainstay of therapy for patients with MDS<sup>9)</sup>, and it has received Food and Drug Administration (FDA) approval for the treatment of not only MDS and but also CMML. A retrospective analysis on CMML treated with AZA revealed that there was a statistically significant OS advantage in responders compared with nonresponders: 15.5 versus 9 months and treatment was found to be generally well tolerated<sup>3)</sup>. The efficacy of azacitidine were also reported among patients with Philadelphia (Ph)-negative MPN who had progressed to MDS or AML<sup>4)</sup>. According to the report, the overall response rate was 52 %, median response duration was 9 months, and the median OS was 11 months. A standard treatment for CMML with acute transformation is yet to be clarified. The optimal therapy for elderly aCML patients ineligible for hematopoietic stem cell transplantation is also unknown. JAK or SRC kinase inhibitors, which may have the potential to be effective in association with CSF3R mutations for aCML<sup>10)11)</sup>, cannot currently be used at the bedside. Hence, without a definitive diagnosis of CMML or aCML, the optimal therapeutic strategy for a patient with MDS/MPN, like the present case, remains unclear. AZA might be effective because of the pathophysiological similarity of CMML and aCML to MDS and accepted tolerance in elderly patients.

Our patient started to receive AZA after induction therapy for acute transformation. This was because the bone marrow examination after induction therapy revealed an MDS-like state, and his

compromised physical condition precluded such options as intensive chemotherapies or cytotoxic agents. Subsequently, blasts in the peripheral blood disappeared and did not increase for about 2 months. After he experienced a relapse of leukemic evolution, he became increasingly ill and died 15 months after the first visit. As only two cycles of AZA treatment were done in the present case, it is difficult to attribute the anti-leukemic effect solely to AZA treatment. There is also a possibility that the effect may be due to the induction chemotherapy consisting of DNR and Ara-C. However, the disease was expected to relapse earlier without any treatment because blasts remained even after intensive chemotherapy. In higher-risk MDS treated with

AZA, no previous treatment such as low-dose Ara-C is associated with a better response to AZA<sup>12)</sup>. In a phase III randomized trial, AZA significantly prolonged overall survival and improved several patient morbidity measures in elderly patients with low bone marrow blast count AML<sup>13)</sup>. We consider that AZA might possibly improve the prognosis in patients with a diagnosis of MDS/MPN but in a gray zone between CMML and aCML, if it is administered before acute transformation.

#### Conflict of Interest

The authors declare that they have no conflict of interest.

#### References

- 1) Lichtman MA, Liesveld JL : Related clonal myeloid diseases without the Ph chromosome. In : Lichtman MA, Beutler E, Kipps TJ, Seligsohn U, Kaushansky L, Prchal JT (eds), Williams Hematology. 7th ed, pp 1261-1267, McGraw-Hill Medical, New York, 2006
- 2) Fenaux P, Mufti GJ, Hellstrom-Lindberg E, Santini V, Finelli C, Giagounidis A, Schoch R, Gattermann N, Sanz G, List A, Gore SD, Seymour JF, Bennett JM, Byrd J, Backstrom J, Zimmerman L, McKenzie D, Beach C, Silverman LR : Efficacy of azacitidine compared with that of conventional care regimens in the treatment of higher-risk myelodysplastic syndromes : a randomised, open-label, phase III study. *Lancet Oncol* 10 : 223-232, 2009
- 3) Costa R, Abdulhaq H, Haq B, Shaddock RK, Latsko J, Zenati M, Atem FD, Rossetti JM, Sahovic EA, Lister J : Activity of azacitidine in chronic myelomonocytic leukemia. *Cancer* 117 : 2690-2696, 2011
- 4) Thepot S, Itzykson R, Seegers V, Raffoux E, Quesnel B, Chait Y, Sorin L, Dreyfus F, Cluzeau T, Delaunay J, Sanhes L, Eclache V, Dartigeas C, Turlure P, Harel S, Salanoubat C, Kiladjian JJ, Fenaux P, Adès L : Treatment of progression of Philadelphia-negative myeloproliferative neoplasms to myelodysplastic syndrome or acute myeloid leukemia by azacitidine : a report on 54 cases on the behalf of the Groupe Francophone des Myelodysplasies (GFM). *Blood* 116 : 3735-3742, 2010
- 5) Onida F, Ball G, Kantarjian HM, Smith TL, Glassman A, Albitar M, Scappini B, Rios MB, Keating MJ, Beran M : Characteristics and outcome of patients with Philadelphia chromosome negative, bcr/abl negative chronic myelogenous leukemia. *Cancer* 95 : 1673-1684, 2002
- 6) Breccia M, Biondo F, Latagliata R, Carmosino I, Mandelli F, Alimena G : Identification of risk factors in atypical chronic myeloid leukemia. *Haematologica* 91 : 1566-1568, 2006
- 7) Germing U, Strupp C, Knipp S, Kuendgen A, Giagounidis A, Hildebrandt B, Aul C, Haas R, Gattermann N, Bennett JM : Chronic myelomonocytic leukemia in the light of the WHO proposals. *Haematologica* 92 : 974-977, 2007
- 8) Onida F, Kantarjian HM, Smith TL, Ball G, Keating MJ, Estey EH, Glassman AB, Albitar M, Kwari MI, Beran M : Prognostic factors and scoring systems in chronic myelomonocytic leukemia : a retrospective analysis of 213 patients. *Blood* 99 : 840-949, 2002
- 9) Khan C, Pathe N, Fazal S, Lister J, Rossetti JM : Azacitidine in the management of patients with myelodysplastic syndromes. *Ther Adv Hematol* 3 : 355-373, 2012
- 10) Maxson JE, Gotlib J, Pollyea DA, Fleischman AG, Agarwal A, Eide CA, Bottomly D, Wilmot B, McWeeney SK,

Tognon CE, Pond JB, Collins RH, Goueli B, Oh ST, Deininger MW, Chang BH, Loriaux MM, Druker BJ, Tyner JW : Oncogenic CSF3R mutations in chronic neutrophilic leukemia and atypical CML. *N Engl J Med* 368 : 1781-1790, 2013

- 11) Gotlib J, Maxson JE, George TI, Tyner JW : The new genetics of chronic neutrophilic leukemia and atypical CML : implications for diagnosis and treatment. *Blood* 122 : 1707-1711, 2013
- 12) Itzykson R, Thépot S, Quesnel B, Dreyfus F, Beyne-Rauzy O, Turlure P, Vey N, Recher C, Dartigeas C, Legros L, Delaunay J, Salanoubat C, Visanica S, Stamatoullas A, Isnard F, Marfaing-Koka A, de Botton S, Chelghoum Y, Taksin AL, Plantier I, Ame S, Boehrer S, Gardin C, Beach CL, Adès L, Fenaux P : Prognostic factors for response and overall survival in 282 patients with higher-risk myelodysplastic syndromes treated with azacitidine. *Blood* 117 : 403-411, 2011
- 13) Fenaux P, Mufti GJ, Hellström-Lindberg E, Santini V, Gattermann N, Germing U, Sanz G, List AF, Gore S, Seymour JF, Dombret H, Backstrom J, Zimmerman L, McKenzie D, Beach CL, Silverman LR : Azacitidine prolongs overall survival compared with conventional care regimens in elderly patients with low bone marrow blast count acute myeloid leukemia. *J Clin Oncol* 28 : 549-556, 2010

(2013. 12. 16 received ; 2014. 1. 30 accepted)

---