

# Long-term Trial of Corticosteroid Therapy for the Recurrence of Cerebral Amyloid Angiopathy-related Hemorrhages : A Case Study Using [11C] BF-227 Amyloid-PET

Takuji YASUDE, Kazuko MACHIDA and Shu-ichi IKEDA\*

*Department of Medicine (Neurology and Rheumatology), Shinshu University School of Medicine*

**Aim :** To clarify a long-term preventive effect of corticosteroid therapy for the recurrence of cerebral amyloid angiopathy (CAA)-related hemorrhages.

**Subjects and methods :** Cases consisted of one male and two females, being consistent with the diagnosis of G3 to G4 in Boston validation criteria of CAA. To detect cerebral A $\beta$  amyloidosis, they underwent positron emission tomography combined with a novel amyloid specific tracer, BF-227, all showing positive brain shadow. A 66-year-old man (case 1) with a diagnosis of G3 was given an initial dose of prednisolone at 50 mg/day. The dose was gradually reduced and was tapered off 6 months later, but after the next 6 months cerebral hemorrhage recurred. He again received similar corticosteroid therapy. A 69-year-old woman (case 2) with a diagnosis of G3 was given dexamethasone 16 mg/day after suffering recurrent cerebral hemorrhages. A week later dexamethasone was switched to prednisolone 30 mg/day and the dose of this corticosteroid was gradually reduced, until being kept at 8 mg/day. Another 75-year-old woman (case 3) with a diagnosis of G4 was given an initial dose of prednisolone at 30 mg/day and the dose of this corticosteroid was gradually reduced and has been kept at 8 mg/day.

During the observation periods they were evaluated by clinical manifestations and T2\* MR images : the total area of microbleeds was assessed by computer-assisted morphometry. After treatment two cases received a second PET scan and the regional standard uptake value ratio (SUVR) of BF-227 at the occipital lobe was compared with the previous one.

**Results :** Case 1 suffered a small hemorrhage in the left frontal lobe at 20 months after receiving the corticosteroid therapy and steroid pulse therapy was added. During the remaining 33 months he has been free of cerebral hemorrhages. SUVR in his PET scan showed 2.0 to 2.2 in a 14-month follow-up period and the total area of microbleeds extended from 410.2 to 445.5 mm<sup>2</sup> during the 48-month observation period. Case 2 showed two simultaneous small hemorrhages at 29 months after starting the corticosteroid therapy and her dose of prednisolone was temporally increased. During the remaining 17 months she has not had any strokes and SUVR in her PET showed 1.5 to 1.4 in an 18-month follow-up period. The total area of microbleeds extended from 512.5 to 560.8 mm<sup>2</sup> during the 27-month observation period. Case 3 has been free of cerebral hemorrhages for 22 months after this corticosteroid therapy and the total area of microbleeds ranged from 152.5 to 154.1 mm<sup>2</sup> during the 13-month observation period.

**Conclusions :** Corticosteroid therapy seems to be clinically effective for the long-term prevention of recurrences of CAA-related hemorrhages but current brain image data are inadequate to lead to this conclusion. This is the first report showing that domestically developed BF227 PET scan is useful in visualizing CAA lesions. *Shinshu Med J 62 : 155–165, 2014*

(Received for publication February 3, 2014 ; accepted in revised form February 18, 2014)

---

**Key words :** cerebral amyloid angiopathy, cerebral hemorrhage, A $\beta$  amyloid, corticosteroid, amyloid-imaging, positron emission tomography

---

\* Corresponding author : Shu-ichi Ikeda  
 Department of Medicine (Neurology and Rheumatology),  
 Shinshu University School of Medicine, 3-1-1 Asahi,  
 Matsumoto, Nagano 390-8621, Japan  
 E-mail : ikedasi@shinshu-u.ac.jp

## I Introduction

Cerebral amyloid angiopathy (CAA) is caused by the accumulation of A $\beta$  amyloid fibrils on cere-

brovascular walls and is well known to be a cause of cerebral hemorrhages in the elderly<sup>12)</sup>. This disease manifests as recurrent or multiple simultaneous subcortical hematomas, occasionally leading to fatal lobar hemorrhages<sup>3)</sup>: in a cohort study of 71 consecutive survivors with CAA-related hemorrhages, the two-year cumulative recurrence rate of this hemorrhage was reported to be 21 percent, indicating a very high risk of recurrence<sup>4)</sup>. Additionally, it is noteworthy that CAA-related hemorrhages can develop in individuals aged around 50 years<sup>5)</sup>. For the prevention of the recurrence of CAA-related hemorrhages, the usefulness of corticosteroid was described in a number of reported cases<sup>6)7)</sup>. However, this therapy has not been widely accepted since there is limited evidence supporting this strategy.

A recent in vitro study has demonstrated that  $A\beta$ -induced cerebrovascular smooth muscle cell death is significantly suppressed by dexamethasone<sup>8)</sup>. We also have reported the postmortem findings of a CAA patient treated by corticosteroid in which diminishing of the cerebrovascular amyloid deposits was noted in comparison with the previous biopsy findings<sup>9)10)</sup>. To address the long-term preventive effect of corticosteroid therapy for CAA-related hemorrhages we studied three cases with this disorder by quantitative analyses of brain images including positron emission tomography (PET) combined with a novel tracer, (11)C-labeled-(2-[2-dimethylaminothiazol-5-yl]ethenyl)-6-(2-[fluoro]ethoxy) benzoxazole ([11C]BF-227). [11C]BF-227 is a tracer having specific binding to amyloid fibrils including  $A\beta$  amyloid fibrils<sup>11)</sup>, and the usefulness of this [11C]BF-227 amyloid-PET was previously reported for the evaluation of cerebral amyloid deposits in patients with Alzheimer's disease<sup>12)</sup> and transthyretin-derived amyloid deposition on myocardium<sup>13)</sup>. The present case study aimed to obtain evidence that corticosteroid therapy is effective for the prevention of recurrence of CAA-related hemorrhages, paying special attention to the usefulness of [11C]BF-227 amyloid-PET in evaluating cerebrovascular amyloid deposits in

patients non-invasively.

## II Subjects and Methods

The subjects were the following three cases who were diagnosed as having probable (G3) or possible (G4) CAA on the basis of validation of the Boston criteria<sup>14)</sup>.

## III Case Reports

Case 1 was a 66-year-old male when he first visited us. During the previous 2 years he had gradually suffered from cognitive decline including speech disturbance and memory loss. He underwent magnetic resonance imaging (MRI) at another hospital, which showed bilateral white matter degeneration with multiple microbleeds, and he was hospitalized in March 2008. Cerebral angiography was normal and revised Hasegawa dementia scale (HDS-R) was 17 out of 30. He was discharged with oral administration of cilostazole 200 mg/day but three months later he developed intractable headache and CT showed two small hematomas in the left parietal and occipital lobes (**Fig. 1A**). He was suspected to be suffering from CAA-related hemorrhages. Thus, cilostazole was stopped and he was given an initial dose of prednisolone at 50 mg/day in August 2008. The dose of prednisolone was gradually reduced and was tapered off six months later. Six months after from cessation of corticosteroid therapy he suffered hemorrhages in the left fronto-parietal lobe (**Fig. 1B**). Prednisolone 40 mg/day was, therefore, started again in August 2009 and he was referred to us: he was 162.3 cm tall and weighted 56.5 kg. His pulse rate was 63 per minute and was regular, and blood pressure was 135/76 mmHg. His general condition was good and showed no neurological disability. Routine laboratory data were all normal. PET with BF227 showed positive shadow mainly in the bilateral occipital lobes (**Fig. 2A**). Prednisolone was gradually reduced, until being kept at 10 mg/day. In April 2011 he developed slight paresis in the right leg and a small hematoma in the left frontal lobe was seen on CT (**Fig. 1C**). He received an additional steroid pulse therapy (methylpred-

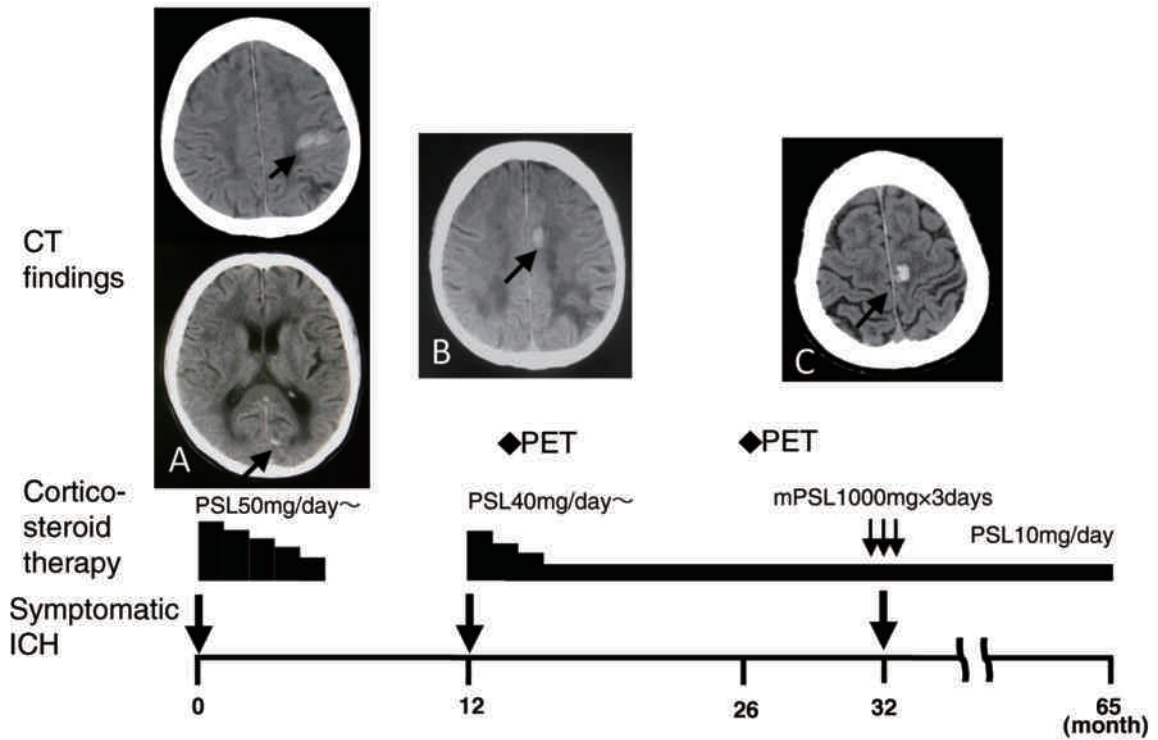


Fig. 1 CT findings and clinical course of case 1.

A : CT finding of initial cerebral hemorrhages, B : recurrent cerebral hemorrhage after cessation of prednisolone, C : recurrent cerebral hemorrhage even when taking a small dose of prednisolone. All arrows indicate hematomas on CT images. Abbreviations : PSL : prednisolone, ICH : intracranial hemorrhage.

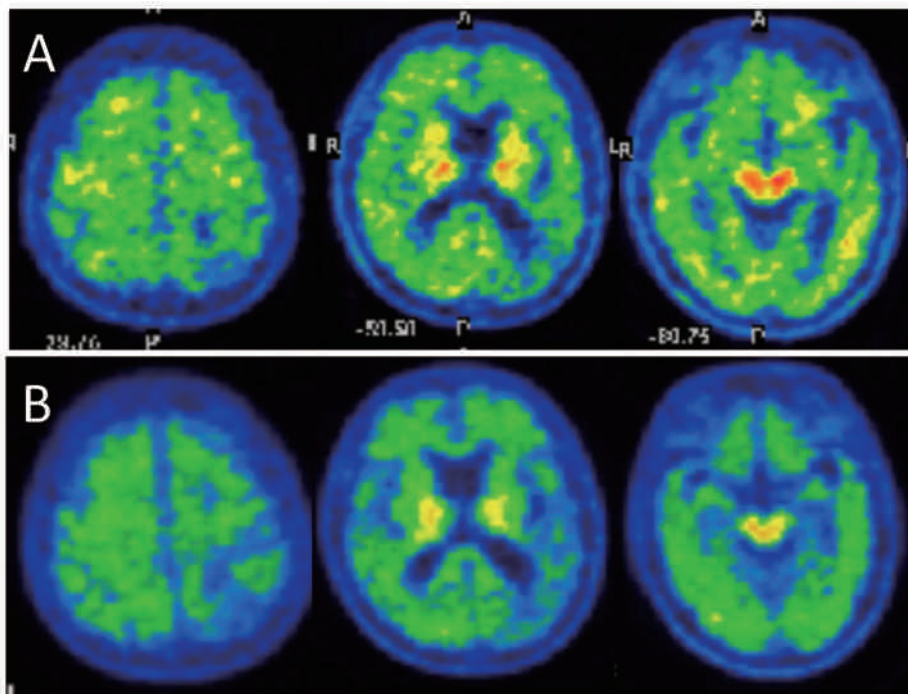


Fig. 2 BF227 PET findings in case 1.

A : before corticosteroid treatment, B : after that. In panel A patchy distribution of increased uptake of a tracer is seen mainly in frontal and occipital lobes, while in panel B this finding is less impressive.

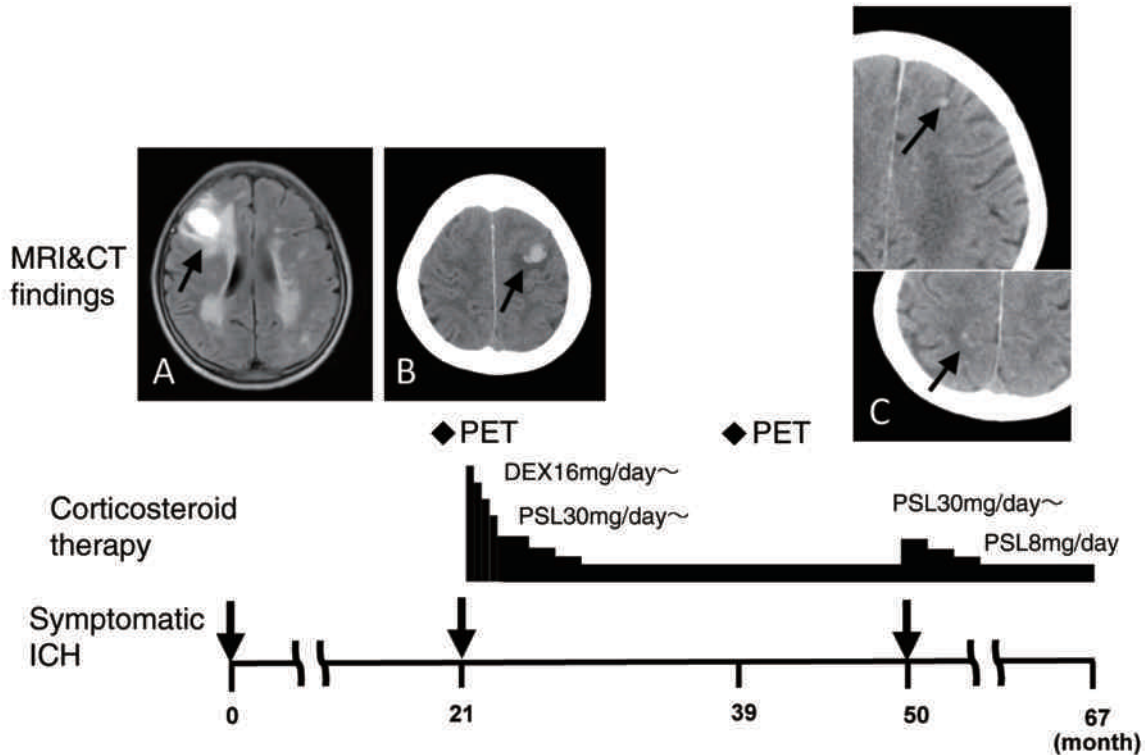


Fig. 3 MRI and CT findings, and clinical course of case 2.

A: MRI flair image of a subcortical hematoma, B: CT finding of recurrent cerebral hemorrhage, C: CT findings of two recurrent simultaneous small hemorrhages. All arrows indicate hematomas on MRI and CT images. Abbreviations: PSL: prednisolone, ICH: intracranial hemorrhage.

nisolone 1 g/day for three days) and his leg weakness improved. Since that event he has been free of cerebral hemorrhage for 33 months (**Fig. 1**).

Case 2 was a 69-year-old female who had a history of cerebral hemorrhages: in May 2008 she suddenly developed disorientation of time and day, and confused communication. MRI at another hospital revealed a subcortical hematoma in the right frontal lobe (**Fig. 3A**). Her symptoms gradually recovered but MRI showed multiple microbleeds in the bilateral temporal-occipital lobes. She was referred to us in February 2010. On examination she was 141.0 cm tall and weighted 42.2 kg. Her pulse rate was 67 per minute and was regular, and blood pressure was 126/80 mmHg. Since she had been suffering from severe osteoarthropathy of the thoracolumbar spine she used a stick when walking. Mini-mental state examination (MMSE) was 18 out of 30 and PET with BF227 showed positive shadow in the bilateral temporal-occipital lobes (**Fig. 4A**).

In March she complained of headache and difficulty in writing and CT disclosed a small hematoma in the left frontal lobe (**Fig. 3B**). In April 2010 she started to be treated with dexamethasone 16 mg/day, which was then switched to prednisolone 30 mg/day. The dose of this drug was gradually reduced, and has since been kept at 8 mg/day. She showed two simultaneous small hemorrhages at 29 months after starting the corticosteroid therapy, and her dose of prednisolone was temporarily increased to 30 mg/day (**Fig. 3C**) and then decreased to 8 mg/day. During the remaining 17 months she has not suffered any cerebral hemorrhages.

Case 3 was a 75-year-old woman who developed cognitive decline two years ago. One year before her visit to us she experienced right hemiparesis and aphasia. She was transferred to another hospital where she was found to have a cerebral hemorrhage in her left frontal lobe (**Fig. 5A**). Although her motor disability gradually recovered, her cognitive



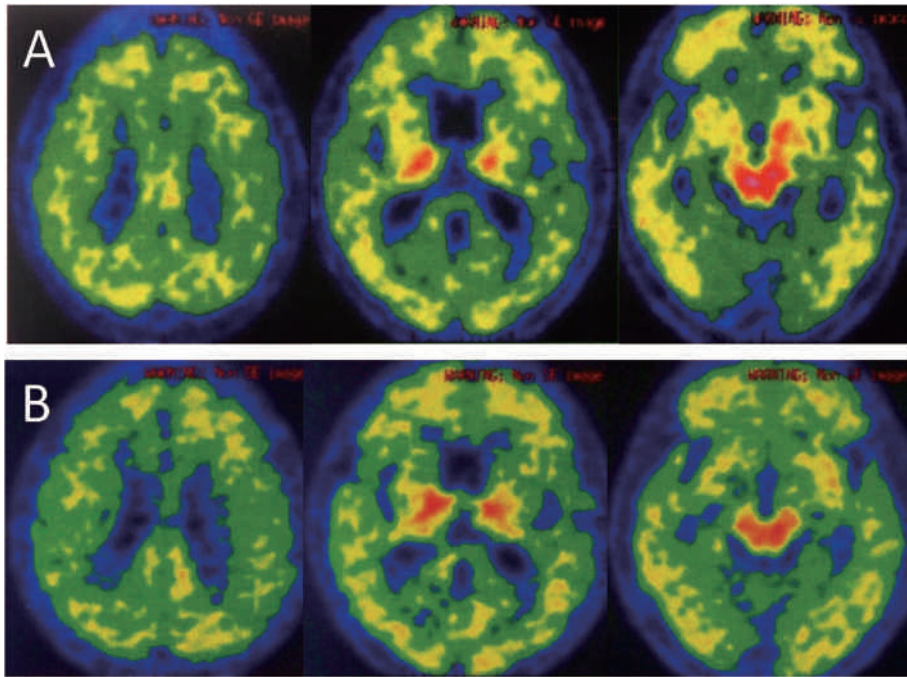


Fig. 4 BF227 PET findings in case 2.

A: before corticosteroid treatment, B: after that. Although both panels show patchy distribution of increased uptake of a tracer mainly in frontal and occipital lobes, panel B seems to be more highly visualized.

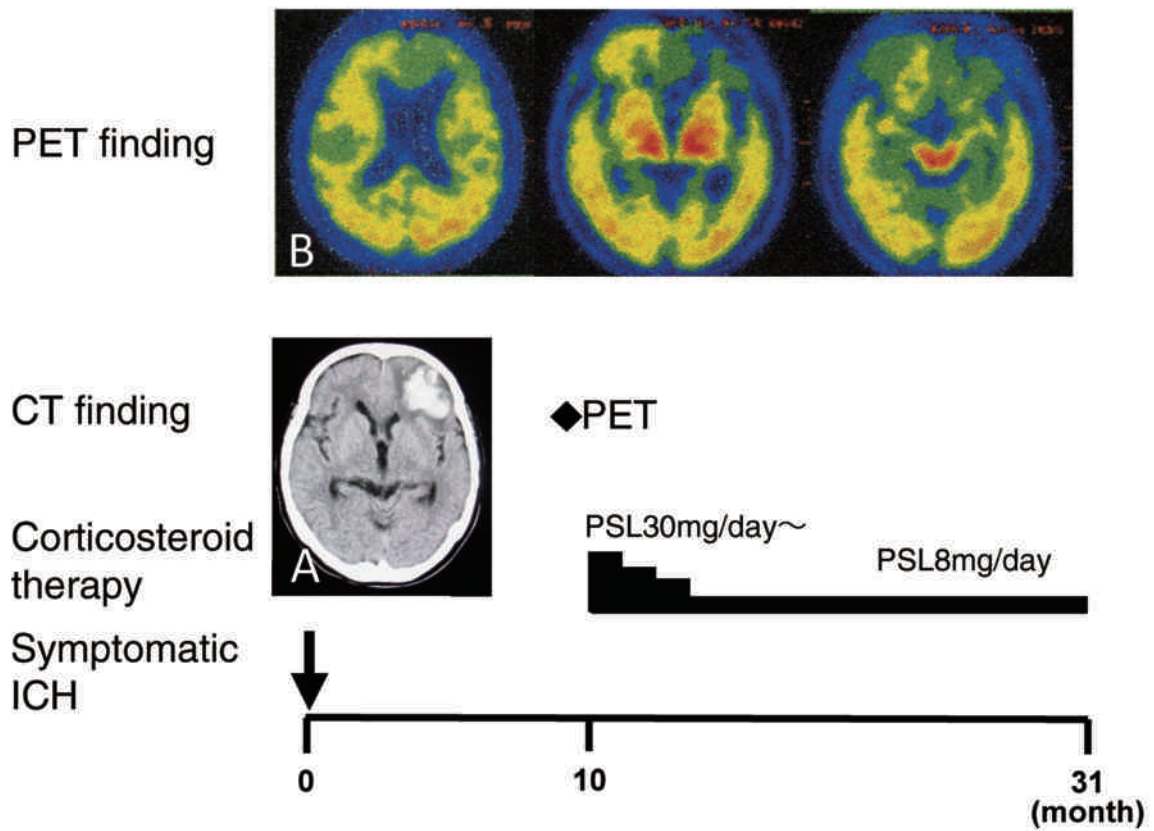


Fig. 5 BF227 PET and CT findings, and clinical course in case 3.

A: CT finding of a left frontal lobe hematoma, B: PET scan showing positive shadow mainly in bilateral occipital lobes.

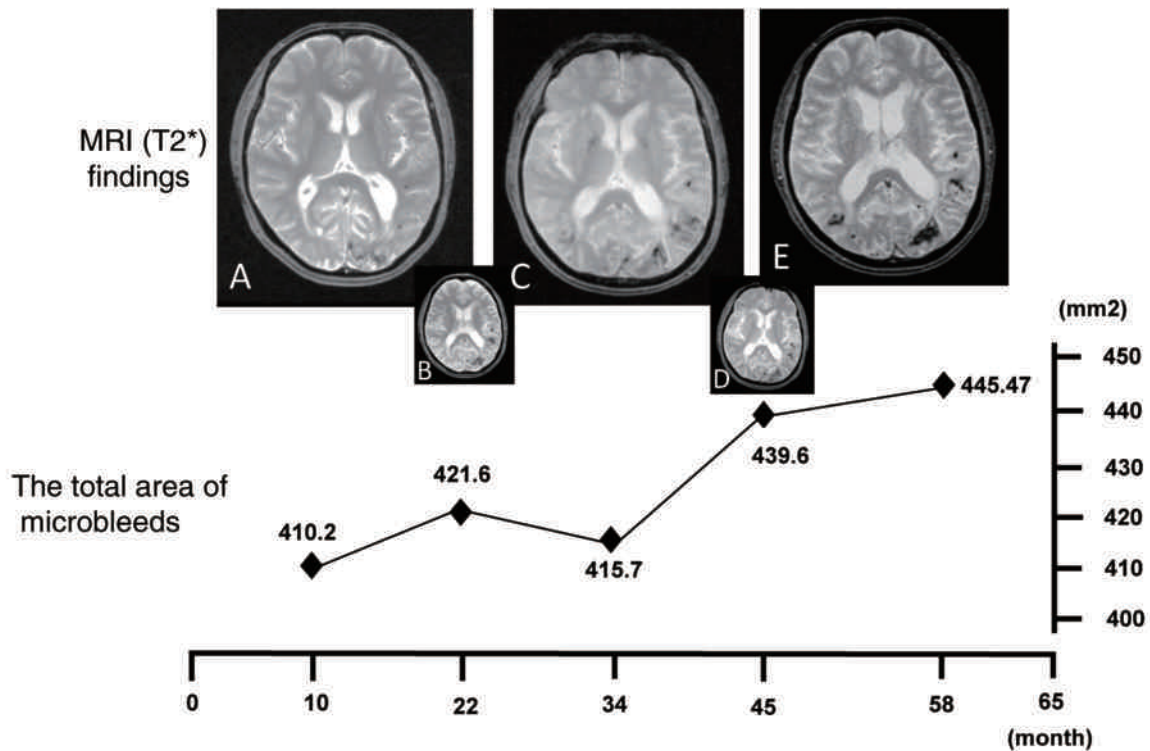


Fig. 6 Serial changes of MRI T2\*-weighted images and calculated values indicating microbleed area in case 1.

Comparing between panels A and E microbleed-related lesions have apparently expanded in the latter.

state did not improve. She was, therefore, referred to our hospital in November 2011. At examination she was 148.7 cm and weighted 50.3 kg. Her pulse rate was 72 per minute and was regular, blood pressure being 128/76 mmHg. Her general condition was good and she looked apathetic, but lacked any specific neurological deficits. MMSE was 17 out of 30 and MRI showed an abnormal lesion in the left frontal lobe, indicating an old hematoma, while microbleeds were barely visible in the temporal lobes. A regimen of 8 mg of galantamine twice daily improved her cognitive function, raising her MMSE score to 25 out of 30. Then she underwent PET with BF227, showing marked uptake mainly in parietal and occipital cortical regions (**Fig. 6B**). She was diagnosed as having possible CAA (G4) and was given an initial dose of prednisolone at 30 mg/day in February 2012. The dose of prednisolone was gradually reduced, until being kept at 8 mg/day (**Fig. 5**). She has been free of cerebral hemorrhage for 22 months.

#### IV Quantitative Analysis of Brain Images

##### A MRI analysis

To detect cerebral microhemorrhages or microbleeds T2\*-weighted MR imagery was employed<sup>15)16)</sup>: this imagery was repeatedly obtained from 3 cases. For the three serial photographs including a large area of the fronto-temporo-occipital lobes the total area of microbleeds was calculated by computer-assisted morphometry with the use of Image J software (NIH, USA) and, the numbers obtained were serially compared before and after corticosteroid therapy.

##### B [(11)C]BF-227 amyloid-PET analysis

[(11)C]BF-227 amyloid-PET scan was performed at the Department of Radiology, Minami-Tohoku General Hospital, Kouriyama, Fukushima. The [(11)C]BF-227 PET study was carried out using a PET SET-2400 W scanner (Shimadzu Inc., Tokyo, Japan). After intravenous injection of 211–366 mBq of [(11)C]BF-227, dynamic serial PET images were obtained from 20 to 60 minutes with each subject's

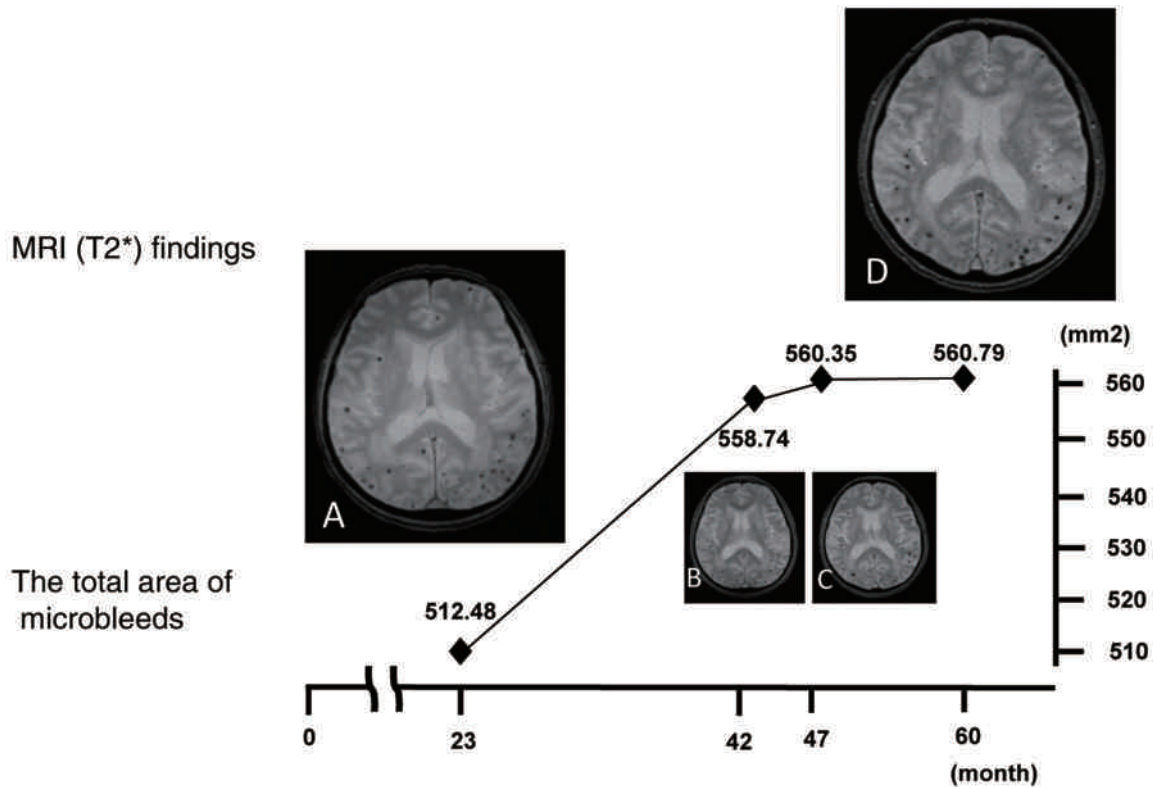


Fig. 7 Serial changes of MRI T2\*-weighted images and calculated values indicating microbleed area in case 2.

The distribution of microbleeds seen on panels A and D is typical for CAA and the number of these lesions increased at an advanced stage.

eyes closed. The regional standardized uptake value ratio (SUVR), which reflected the ratio of regional cerebral SUV to cerebellar, was calculated as an index of BF-277 binding. Actually in Cases 1 and 2, SUVR for amyloid plaque deposition on the temporal-occipital area was evaluated before treatment and about a year after that. The study protocol was approved by the local ethics committee.

## V Results

In case 1 the total area of microhemorrhages on T2\*-weighted MR images extended from 410.2 to 445.5 mm<sup>2</sup> during the 48-month observation period (Fig. 6A, 6E) and SUVR in his PET scan showed 2.0 to 2.2 in a 14-month follow-up period (Fig. 2A, 2B). In case 2 the total area of microhemorrhages extended from 512.5 to 560.8 mm<sup>2</sup> during the 27-month observation period (Fig. 7A, 7D) and SUVR in her PET revealed 1.5 to 1.4 in a 17-month follow-up period (Fig. 4A, 4B). In case 3 the total area of

microhemorrhages ranged from 152.5 to 154.1 mm<sup>2</sup> during the 13-month observation period (Fig. 8A, 8B). SUVR of amyloid plaque deposition on BF227PET before therapy was 1.44 (Fig. 5B), but the next PET scan using this machine could not be performed because of the Great East Japan Earthquake.

## VI Discussion

CAA usually involves small and medium-sized vessels of the cerebral cortex, subcortex, and leptomeninges<sup>1)2)17)</sup>. This finding can be confirmed only by histopathological examination of brain tissues<sup>18)</sup>, but recent advances in brain imaging can provide very reliable information on cerebrovascular amyloid deposits in living individuals: a CT finding of intracerebral hemorrhage with a distinctive cortical-subcortical distribution is the first clue for the possibility of CAA<sup>16)</sup> and this suspicion becomes more confident if the patients are aged and

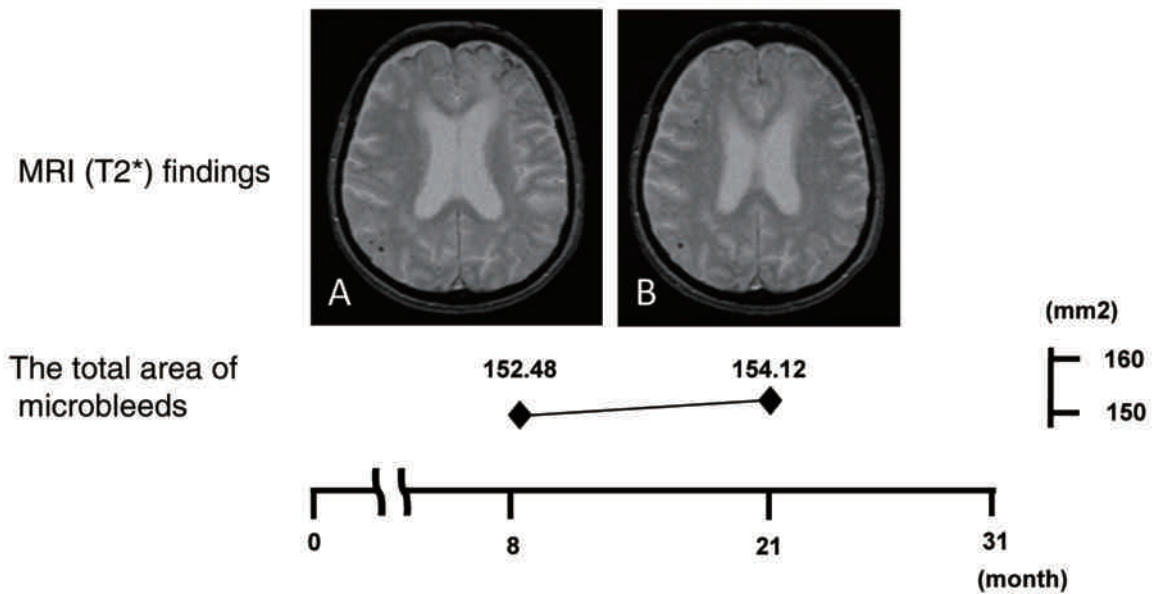


Fig. 8 Two panels of MRI T2\*-weighted images and calculated values indicating microbleed area in case 3.

There is no significant change in microbleed-related areas between panels A and B.

have no history of hypertension. Next the patients should undergo MR imaging including a T2\*-weighted gradient-echo sequence. This MR imaging can sensitively disclose deposits of hemosiderin ascribable to previous minor hemorrhages or microbleeds<sup>15)16)</sup>. Although microbleeds are associated with some neurological conditions such as Binswanger's disease, traumatic brain injury, or primary angiitis of the central nervous system, they are most frequently observed in patients with a long history of hypertension or those with CAA<sup>16)</sup>. It has been shown that cortico-subcortical distribution of microbleeds is different between hypertension and CAA, the latter being located mostly in the posterior half of the brain, with a predilection for the parietal lobes<sup>19)20)</sup>. Recently, the direct *in vivo* demonstration of cerebral A $\beta$  amyloid deposits has become possible using a PET combined with novel amyloid-specific tracers: a Pittsburgh Compound-B (PiB) tracer has been used worldwide<sup>21)–23)</sup>, while our BF-227 tracer is domestic and has been applied for patients with mild cognitive impairment or Alzheimer's disease<sup>12)</sup>, producing very sensitive detection of A $\beta$ -derived senile plaque amyloid deposition.

Among the present three cases 1 and 2 possessed many microbleeds on T2\*-weighted MR images, the distribution of which was typical for CAA. Additionally, in these three cases, A $\beta$  amyloid deposition on an extensive area of cerebral cortex was indirectly shown by a positive BF-227 PET scan. The experience of the use of a PiB PET scan, of course, has revealed that cortical PiB retention is a feature not only of Alzheimer's disease, but also of functionally normal aged brain with A $\beta$  amyloid deposition, mild cognitive impairment, CAA and dementia with Lewy bodies associated with Alzheimer's pathology<sup>21)22)</sup>. In considering the differential diagnosis of these five brain conditions the clinical histories of non-hypertensive subcortical hemorrhages in our three cases strongly suggested that amyloid deposited as CAA was the dominant source of this BF-227 PET signal, ensuring the clinical diagnosis of CAA.

The usefulness of corticosteroid therapy is well known for CAA-related inflammation<sup>24)</sup>: this pathology coexists with CAA and isolated cerebral angiitis<sup>25)</sup> and is alternatively called A $\beta$ -related angiitis and cerebral amyloid inflammatory vasculopathy<sup>26)</sup>, causing diffuse deep white matter degeneration. However, this therapeutic strategy



was applied to a limited number of cases with CAA-derived hemorrhages<sup>67)</sup>. In this study we evaluated the long-term preventive effect of corticosteroid therapy for CAA-related hemorrhages in 3 cases. In case 1 symptomatic hemorrhage occurred 6 months after the cessation of corticosteroid therapy, upon which corticosteroid therapy was restarted and has been maintained with a low dose of prednisolone, resulting in an absence of symptomatic cerebral hemorrhages for 33 months. Similarly in cases 2 and 3, freedom from symptomatic cerebral hemorrhages has been 17 to 22 months respectively with low dose corticosteroid therapy. After treatment, SUVR of amyloid plaque deposition showed slight changes: it was increased in case 1, but decreased in case 2, both being insignificant for estimating any alteration in cerebrovascular amyloid deposits. We quantitatively examined another CAA-related brain lesion, that is, the area of microbleeds on T2\*-weighted MR imagery. Since visualization of this lesion is known to be changeable either in different machines or different imaging conditions, we did not use the same machine under similar conditions in the series in this study. Even when considering this methodological bias, the lesions involved by microbleeds apparently extended in cases 1 and 2, indicating that CAA-related subclinical hemorrhages worsened irrespective of the use of corticosteroid therapy. In fact cases 1 and 2 experienced one symptomatic attack with small cerebral hemorrhages in spite of taking a low dose of prednisolone. On the basis of all these findings it is likely that corticosteroid therapy is clinically effective for the long-term prevention of recurrence of CAA-related hemorrhages, while the MRI findings are not supportive of our tentative conclusion.

It has been shown that in patients with Alzheimer's

disease immunization therapy can significantly reduce the A $\beta$  amyloid plaque burden in the brain<sup>27)28)</sup>, and we have recently reported that regression of cerebrovascular A $\beta$  amyloid deposits occurred in a case after corticosteroid treatment<sup>9)</sup> in which proteomic analysis of the crude amyloid fractions isolated from the leptomeningeal vessels in CAA cases disclosed that the quantity and molecular pattern of A $\beta$  and its derivatives were clearly different between the CAA case with and the one without corticosteroid treatment<sup>10)</sup>. The latter finding suggests that corticosteroid influences the turn-over of constituent amyloid fibril protein<sup>29)</sup> on cerebrovascular walls with A $\beta$  amyloid deposits. Other actions of corticosteroid are surmised to reduce brain edema around hemorrhages, secondarily decreasing mechanical stress for CAA affected vessels with vascular fragility or to suppress CAA-related perivascular inflammation<sup>30)</sup> leading to vascular rupture. However, the detailed molecular basis for the beneficial effects of corticosteroid on this cerebrovascular amyloid lesion remains unclear. To demonstrate the effectiveness of corticosteroid therapy for the prevention of recurrent CAA-related hemorrhages more precisely, further studies including a double-blind clinical trial on a large scale are required.

## VII Acknowledgment

The authors thank Dr. Toshiyuki Saginoya, Department of Radiology, Minami-Tohoku General Hospital, Kouriyama, Fukushima, for useful comments on BF227 PET scan. This work was supported by a grant from the Intractable Disease Division, the Ministry of Health and Welfare, Amyloidosis Research Committee, Japan.

## References

- 1) Biffi A, Greenberg SM: Cerebral amyloid angiopathy: a systematic review. *J Clin Neurol* 7: 1-9, 2011
- 2) Attems J: Sporadic cerebral amyloid angiopathy: pathology, clinical implications, and possible pathomechanisms. *Acta Neuropathol* 110: 345-359, 2005
- 3) Hirohata M, Yoshita M, Ishida C, Ikeda SI, Tamaoka A, Kuzuhara S, Shoji M, Ando Y, Tokuda T, Yamada M: Clinical features of non-hypertensive lobar intracerebral hemorrhage related to cerebral amyloid angiopathy. *Eur*

- J Neurol 17 : 823-829, 2010
- 4) O'Donnell HC, Rosand J, Knudsen KA, Furie KL, Segal AZ, Chiu RI, Ikeda D, Greenberg SM : Apolipoprotein E genotype and the risk of recurrent lobar intracerebral hemorrhage. *N Engl J Med* 342 : 240-245, 2000
  - 5) Campbell DM, Bruins S, Vogel H, Sher LM, Wijman CAC : Intracerebral hemorrhage caused by cerebral amyloid angiopathy in a 53-year-old man. *J Neurol* 255 : 597-598, 2008
  - 6) Hoshi K, Yoshida K, Nakamura A, Tada T, Tamaoka A, Ikeda S : Cessation of cerebral hemorrhage recurrence associated with corticosteroid treatment in a patient with cerebral amyloid angiopathy. *Amyloid* 7 : 284-288, 2000
  - 7) Machida K, Tojo K, Naito K, Gono T, Nakata Y, Ikeda S : Cortical petechial hemorrhage, subarachnoid hemorrhage and corticosteroid-responsive leukoencephalopathy in a patient with cerebral amyloid angiopathy. *Amyloid* 15 : 60-64, 2008
  - 8) Previti ML, Zhang W, Van Nostrand WE : Dexamethasone diminishes the pro-inflammatory and cytotoxic effects of amyloid  $\beta$ -protein in cerebrovascular smooth muscle cells. *J Neuroinflammation* 3 : 18-26, 2006
  - 9) Machida K, Tsuchiya-Suzuki A, Sano K, Arima K, Saito Y, Kametani F, Ikeda S : Postmortem findings in a patient with cerebral amyloid angiopathy actively treated with corticosteroid. *Amyloid* 19 : 47-52, 2012
  - 10) Kametani F, Ikeda S : Proteomic analysis of leptomenigeal amyloid fibril extracts of cerebral amyloid angiopathy (CAA) patients with or without corticosteroid therapy. *Amyloid* 20 : 277-278, 2013
  - 11) Kudo Y, Okamura N, Furumoto S, Tashiro M, Furukawa K, Maruyama M, Itoh M, Iwata R, Yanai K, Arai H : 2-(2-[2-Dimethylaminothiazol-5-yl]ethenyl)-6-(2-[fluoro]ethoxy) benzoxazole : a novel PET agent for in vivo detection of dense amyloid plaques in Alzheimer's disease patients. *J Nucl Med* 8 : 553-561, 2007
  - 12) Furukawa K, Okamura N, Tashiro M, Waragai M, Furumoto S, Iwata R, Yanai K, Kudo Y, Arai H : Amyloid PET in mild cognitive impairment and Alzheimer's disease with BF-227 : comparison to FDG-PET. *J Neurol* 257 : 721-727, 2010
  - 13) Furukawa K, Ikeda S, Okamura N, Tashiro M, Tomita N, Furumoto S, Iwata R, Yanai K, Kudo Y, Arai H : Cardiac positron-emission tomography images with an amyloid-specific tracer in familial transthyretin-related systemic amyloidosis. *Circulation* 125 : 556-557, 2012
  - 14) Knudsen KA, Rosand J, Karluk D, Greenberg SM : Clinical diagnosis of cerebral amyloid angiopathy : validation of the Boston criteria. *Neurology* 56 : 537-539, 2001
  - 15) Walker DA, Broderick DF, Kotsenas AL, Rubino FA : Routine use of gradient-echo MRI to screen for cerebral amyloid angiopathy in elderly patients. *Am J Radiol* 182 : 1547-1550, 2004
  - 16) Chao CP, Kotsenas AL, Broderick DF : Cerebral amyloid angiopathy : CT and MR imaging findings. *RadioGraphics* 26 : 1517-1531, 2006
  - 17) Revesz T, Ghiso J, Lashley T, Plant G, Rostagno A, Frangione B, Holton JL : Cerebral amyloid angiopathy : a pathologic, biochemical, and genetic view. *J Neuropathol Exp Neurol* 62 : 885-898, 2003
  - 18) Hendricks HT, Franke CL, Theunissen PH : Cerebral amyloid angiopathy : diagnosis by MRI and brain biopsy. *Neurology* 40 : 1308-1310, 1990
  - 19) Rosand J, Muzikansky A, Kumar A, Wisco J, Smith EE, Betensky RA, Greenberg SM : Spatial clustering of hemorrhages in probable cerebral amyloid angiopathy. *Ann Neurol* 58 : 459-462, 2005
  - 20) Lee S-H, Kim S-M, Kim N, Yoon B-W, Roh J-K : Cortico-subcortical distribution of microbleeds is different between hypertension and cerebral amyloid angiopathy. *J Neurol Sci* 258 : 111-114, 2007
  - 21) Klunk WE, Engler H, Nordberg A, Wang Y, Blomqvist G, Holt DP, Bergström M, Savitcheva I, Huang G-F, Estrada S, Ausén B, Debnath ML, Barletta J, Price JC, Sandell J, Lopresti BJ, Wall A, Koivisto P, Antoni G, Mathis CA, Långström B : Imaging brain amyloid in Alzheimer's disease with Pittsburgh Compound-B. *Ann Neurol* 55 : 306-319, 2004
  - 22) Bacskai BJ, Frosch MP, Freeman SH, Raymond SB, Augustinack JC, Johnson KA, Irizarry MC, Klunk WE,

- Mathis CA, DeKosky ST, Greenberg SM, Hyman BT, Growdon JH : Molecular imaging with Pittsburgh Compound B confirmed at autopsy. *Arch Neurol* 64 : 431-434, 2007
- 23) Johnson KA, Gregas M, Becker JA, Kinnecom C, Salat DH, Moran EK, Smith EE, Rosand J, Rents DM, Klunk WE, Mathis CA, Price JC, DeKosky ST, Fischman AJ, Greenberg MG : Imaging of amyloid burden and distribution in cerebral amyloid angiopathy. *Ann Neurol* 62 : 229-234, 2007
- 24) Eng JA, Frosch MP, Choi K, Rebeck GW, Greenberg SM : Clinical manifestations of cerebral amyloid angiopathy-related inflammation. *Ann Neurol* 55 : 250-256, 2004
- 25) Scolding NJ, Joseph F, Kirby PA, Mazanti I, Gray F, Mikol J, Ellison D, Hilton DA, Williams TL, Mackenzie JM, Xuereb JH, Love S : A $\beta$ -related angiitis : primary angiitis of the central nervous system associated with cerebral amyloid angiopathy. *Brain* 128 : 500-515, 2005
- 26) Harkness KAC, Coles A, Pohl U, Xuereb JH, Baron JC, Lennox GG : Rapidly reversible dementia in cerebral amyloid inflammatory vasculopathy. *Eur J Neurol* 11 : 59-62, 2004
- 27) Nicoll JA, Wilkinson D, Holmes C, Steart P, Markham H, Weller RO : Neuropathology of human Alzheimer disease after immunization with amyloid- $\beta$  peptide : a case report. *Nat Med* 9 : 448-452, 2003
- 28) Boche D, Zotova E, Weller RO, Love S, Neal JW, Pickering RM, Wilkinson D, Holmes C, Nicoll JAR : Consequence of A $\beta$  immunization on the vasculature of human Alzheimer's disease brain. *Brain* 131 : 3299-3310, 2008
- 29) Tsuchiya-Suzuki A, Yazaki M, Sekijima Y, Kametani F, Ikeda S : Steady turnover of amyloid fibril proteins in gastric mucosa after liver transplantation in familial amyloid polyneuropathy. *Amyloid* 20 : 156-163, 2013
- 30) Hawkes CA, McLaurin J : Selective targeting of perivascular macrophages for clearance of  $\beta$ -amyloid in cerebral amyloid angiopathy. *Proc Natl Acad Sci USA* 106 : 1261-1266, 2009

(2014. 2. 3 received; 2014. 2. 18 accepted)

---