

Bacteremia Caused by *Yokenella regensburgei* in a Patient with Diabetes Mellitus

Hiromasa FUKATSU^{1)*}, Akihiro YASHIO²⁾ and Takayuki HONDA³⁾

1) Department of Clinical Laboratory Investigation, Graduate School of Medicine, Shinshu University

2) Department of Emergency and Critical Care Medicine, Shinshu University School of Medicine

3) Department of Laboratory Medicine, Shinshu University Hospital

Yokenella regensburgei rarely causes human infections, and there is no strong evidence to support its clinical importance. We report the first case in Japan of bacteremia caused by *Y. regensburgei* in a patient with diabetic gangrene. A 74-year-old man was admitted to our hospital. He had type 2 diabetes mellitus, and underwent surgical amputation of both lower limbs due to gangrene. *Y. regensburgei* was isolated from swabbing of the wounds on the limbs and the blood samples. The case was successfully treated by intravenous administration of ampicillin-sulbactam and ceftazidime. *Shinshu Med J* 65 : 113–116, 2017

(Received for publication October 31, 2016 ; accepted in revised form December 12, 2016)

Key words : *Yokenella regensburgei*, bacteremia, diabetes mellitus

I Introduction

The genus *Yokenella* belongs to the family *Enterobacteriaceae* and comprises one species, *Yokenella regensburgei*¹⁾. *Y. regensburgei* has been isolated from well water, the intestinal tract of insects, reptiles, and salad. Only a few cases of human infection with *Y. regensburgei* have been reported²⁾⁻⁸⁾; therefore, at present, its clinical significance is not well understood. Furthermore, *Y. regensburgei* shares some biochemical characteristics with *Hafnia alvei*. Thus, it is difficult to accurately differentiate between *Y. regensburgei* and *H. alvei* by routine identification techniques. In this paper, we report the first case of bacteremia caused by *Y. regensburgei* in a patient with diabetic gangrene in Japan, which could be identified using 16S rRNA gene sequence analysis.

II Case Report

A 74-year-old man with type 2 diabetes mellitus

was admitted to the emergency department with a decreased level of consciousness. On admission, the patient had gangrene of the lower limbs. On Day 3 after the admission, the patient underwent surgical amputation of both lower limbs due to the gangrene. The laboratory examination revealed the following : a hemoglobin A1c count of 9.4 %, a white blood cell (WBC) count of 10,270 cells/ μ l, a C-reactive protein (CRP) level of 27.75 mg/dl, a fibrinogen level of 432 mg/dl, a platelet count of 5.3×10^4 cells/ μ l, and a D-dimer level of 10.7 μ g/ml. On Day 6 after the amputation, the patient had a temperature of 38 °C. Bacteriological examination was performed by swabbing the wounds on the limbs. On Day 8 after the amputation, body temperature was 38.5 °C, blood pressure 71/48 mmHg, and respiratory rate 24 breaths/min. Laboratory examination revealed a WBC count of 7,690 cells/ μ l, a CRP of 18.35 mg/dl, fibrinogen levels of 363 mg/dl, a platelet count of 13.6×10^4 cells/ μ l, and D-dimer levels of 7.7 μ g/ml. Two sets of blood samples from peripheral veins were collected for culture in BACTEC Plus Aerobic/F and Plus Anaerobic/F Mediums bottles (Nippon Becton Dickinson Co., Ltd., Tokyo, Japan) using a BACTEC FX system (Nippon Becton Dickinson

* Corresponding author : Hiromasa Fukatsu
Department of Clinical Laboratory Investigation, Graduate School of Medicine, Shinshu University, 3-1-1 Asahi, Matsumoto, Nagano 390-8621, Japan
E-mail : 15mz004k@shinshu-u.ac.jp

Table 1 Antimicrobial susceptibility results of *Y. regensburgei* isolate

Antimicrobial agent	MIC ($\mu\text{g}/\text{mL}$)	Susceptibility ^a
Ampicillin	16	I
Amikacin	≤ 4	S
Amoxicillin-clavulanic acid	$>16/8$	R
Aztreonam	≤ 8	S
Ceftazidime	≤ 1	S
Cefaclor	>16	R
Cefazolin	>16	R
Cefcapene	0.5	S
Cefmetazole	32	I
Cefpirome	≤ 8	S
Cefoperazone-sulbactam	$\leq 16/8$	S
Cefotiam	>16	R
Cefotaxime	≤ 8	S
Flomoxef	>32	R
Fosfomycin	≤ 4	S
Gentamicin	≤ 1	S
Imipenem	2	S
Levofloxacin	≤ 1	S
Minocycline	2	S
Piperacillin	≤ 8	S
Sulfamethoxazole-Trimethoprim	$\leq 2/38$	S

^aS, susceptible ; I, intermediate ; R, resistant

Co., Ltd., Tokyo, Japan). A combination of clindamycin, meropenem, and piperacillin-tazobactam was administered as antibiotic prophylaxis for bacterial infection and continued until Day 9 after the amputation. Doripenem (2 g/day) was commenced on Day 7 after the amputation and was administered for 6 days.

Two sets of blood samples turned positive, showing gram negative rods on Gram staining. Gram-negative and rod-shaped bacteria grew on the sheep blood agar (Nippon Becton Dickinson Co., Ltd., Tokyo, Japan) after 24 hours at 35 °C in aerobic cultivation from the swabbing and the blood samples. Colonies were whitish-gray in color, with a fishy odor, and measured 2-4 mm in diameter. The isolate was identified as *Y. regensburgei* or *H. alvei* by MicroScan Neg Combo 6.11J panel (Beckman Coulter, Co., Ltd., Tokyo, Japan). MALDI-TOF MS analysis of the isolate was performed with the MALDI Biotyper system (Bruker Daltonics, Yokohama, Japan) using alpha-cyano-4-hydroxycinnamic acid matrix (Bruker Daltonics). The isolate was identified as *Kosakonia*

cowanii or *Y. regensburgei* with a score value of 1.729 and 1.716, respectively. 16S rRNA gene sequence analysis of the isolate showed 99.9 % (1433/1434 bp) identity with *Y. regensburgei* JCM 2403 (GenBank accession no. AB519796). The isolate was identified as *Y. regensburgei*. The MicroScan Neg Combo 6.11J showed the minimum inhibitory concentrations of antimicrobial agents (Table 1). The Cefinase disk procedure (Nippon Becton Dickinson Co., Ltd., Tokyo, Japan) demonstrated that the isolate produced β -lactamase. Culture of the wound sample showed a few smooth colonies, in addition to predominant colonies of *Y. regensburgei*. The smooth colonies were identified as *Candida glabrata* by RapID Yeast Plus (AMCO Co., Ltd., Tokyo, Japan). Following antimicrobial susceptibility testing, ampicillin-sulbactam (6 g/day) and ceftazidime (4 g/day) were commenced on Day 11 until Day 20 after the amputation. On Day 16 after the amputation, laboratory examination revealed the following: a WBC count of 3,620 cells/ μL , a CRP of 7.14 mg/dl, fibrinogen levels of 194 mg/dl, a platelet count of 5.0×10^4 cells/ μL , and D-dimer levels of 35.5

Bacteremia caused by *Yokenella regensburgei*

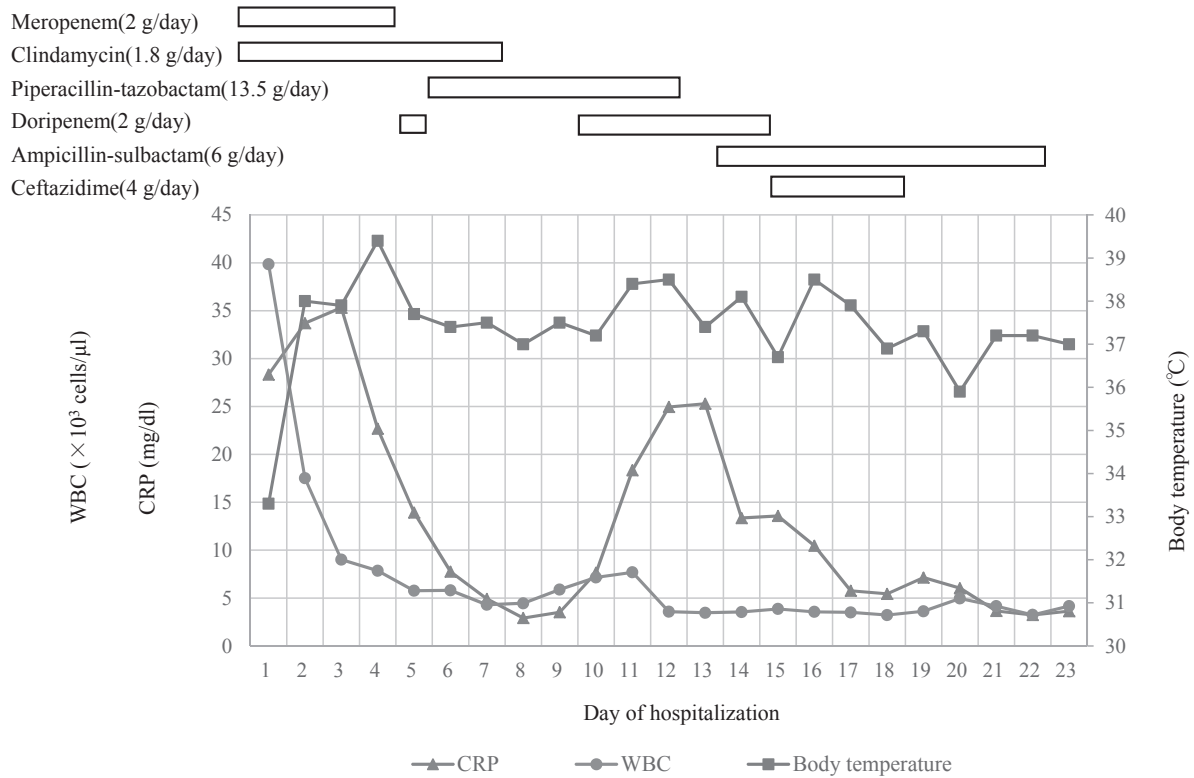


Fig. 1 Clinical course of the present case

μ g/ml. *Y. regensburgei* was not cultured from the wounds or from blood samples obtained 7 days after treatment with ampicillin-sulbactam and ceftazidime, and the patient improved (Fig. 1).

III Discussion

This case is the first report of bacteremia caused by *Y. regensburgei* in a patient with diabetic gangrene in Japan. *Y. regensburgei* rarely causes an infection with clinical symptoms and findings. In this case, *Y. regensburgei* may have infected the wound after surgical amputation, causing bacteremia. There are only 8 reports of infection with *Y. regensburgei* in humans, and these involved patients with diabetes mellitus, liver disease or renal disease, or patients after stem cell transplantation^{2,4,6-8}. Of note, two cases involved patients with *Y. regensburgei* limb wound infection, as in this case^{2,8}.

16S rRNA gene sequencing is useful for the identification of *Y. regensburgei*. *Y. regensburgei* was first recognized and reported as "atypical *Hafnia alvei*". On occasion, members of the genus *Hafnia* can also be mistaken for *Y. regensburgei*⁹. In this case, it was

difficult to differentiate between *Y. regensburgei* and *H. alvei* by biochemical characterization using MicroScan Neg Combo 6.11J panel. Moreover, MALDI Biotyper system could not differentiate between *Y. regensburgei* and *Kosakonia cowanii*. A logarithmic score value of identification from 1.700 to 1.999 by MALDI Biotyper system will be reported as 'probable genus identification', indicating that the genus identification is reliable. The MALDI Biotyper system may be unable to differentiate between *Y. regensburgei* and *Kosakonia cowanii* because only one reference spectrum for *Y. regensburgei* was registered with reference spectra in the MALDI Biotyper library (ver.5.0.0.0). The addition of further reference spectra for *Y. regensburgei* will enhance the rapid identification of *Y. regensburgei* to the genus and species level by MALDI Biotyper.

Here, the patient was successfully treated with doripenem, ampicillin-sulbactam, and ceftazidime. Stock et al.³ demonstrated that *Y. regensburgei* were resistant *in vitro* to cefazolin, cefaclor, and amoxicillin-clavulanic acid, by production of AmpC β -lactamases. The isolate in our case showed resistance to first-

and second-generation cephalosporins and had similar antimicrobial susceptibility, except for cefotiam. Previous reports showed that *Y. regensburgei* infection improved with ciprofloxacin, ceftriaxone, levofloxacin, or piperacillin-tazobactam treatment²⁾⁴⁾⁵⁾⁷⁾⁸⁾. However, carbapenem or third-generation cephalosporins may be necessary to treat bacteremia by *Y. regensburgei* producing AmpC β -lactamase. Conversely, *Enterobacteriaceae* with plasmid-mediated extended-spectrum beta-lactamases or carbapenemase is often detected in clinical practice¹⁰⁾¹¹⁾. There-

fore, antimicrobial susceptibility tests may be crucial before administering antibiotics to treat *Y. regensburgei* infection.

In conclusion, this is the first report of bacteremia caused by *Y. regensburgei* in Japan. Although it is difficult to identify *Y. regensburgei* by routine identification techniques, 16S rRNA gene sequence analysis is useful for correctly identifying it. Additional cases may be necessary to evaluate the clinical pathogenicity of *Y. regensburgei* and optimal antibiotic treatment.

References

- 1) Kosako Y, Sakazaki T, Yoshizaki E: *Yokenella regensburgei* gen. nov., sp. nov.: a new genus and species in the family *Enterobacteriaceae*. Jpn J Med Sci Biol 37: 117-124, 1984
- 2) Abbott SL, Janda JM: Isolation of *Yokenella regensburgei* ("*Koserella trabulsii*") from a patient with transient bacteremia and from a patient with a septic knee. J Clin Microbiol 32: 2854-2855, 1994
- 3) Stock I, Sherwood KJ, Wiedemann B: Antimicrobial susceptibility patterns, β -lactamases, and biochemical identification of *Yokenella regensburgei* strains. Diagn Microbiol Infect Dis 48: 5-15, 2004
- 4) Lo YC, Chuang YW, Lin YH: *Yokenella regensburgei* in an immunocompromised host: a case report and review of the literature. Infection 39: 485-488, 2011
- 5) Jain S, Gaiind R, Gupta KB, Dawar R, Kumar D, Paul P, Sardana R, Deb M: *Yokenella regensburgei* infection in India mimicking enteric fever. J Med Microbiol 62: 935-939, 2013
- 6) Bhowmick T, Weinstein MP: A deceptive case of cellulitis caused by a gram-negative pathogen. J Clin Microbiol 51: 1320-1323, 2013
- 7) Fill MA, Stephens JL: Abdominal abscess and septic shock secondary to *Yokenella regensburgei*. Int J Infect Dis 9: 1-3, 2009
- 8) Lee SM, Kang YJ, Huh HJ, Ki CS, Lee NY: First report of *Yokenella regensburgei* isolated from the wound exudate after disarticulation due to diabetic foot infection in Korea. Ann Clin Microbiol 18: 135-139, 2015
- 9) Sakazaki R: Genus XV. *Hafnia*. Brenner DJ, Krieg NR, Staley JT (eds), In: Bergey's Manual of Systematic Bacteriology vol. 2, pp 681-685, Springer, New York, 2005
- 10) van Duin D, Kaye KS, Neuner EA, Bonomo RA: Carbapenem-resistant *Enterobacteriaceae*: a review of treatment and outcomes. Diagn Microbiol Infect Dis 75: 115-120, 2013
- 11) Bradford PA: Extended-spectrum β -lactamases in the 21st century: characterization, epidemiology, and detection of this important resistance threat. Clin Microbiol Rev 14: 933-951, 2001

(2016. 10. 31 received ; 2016. 12. 12 accepted)