

A Case of Olfactory Neuroblastoma (Esthesioneuroblastoma) Presenting with Anemia Due to Nasal Bleeding

Daisuke GOMI, Shigeru SASAKI, Nodoka SEKIGUCHI, Takashi KOBAYASHI
Akiyuki SAKAMOTO and Tomonobu KOIZUMI*

Department of Comprehensive Cancer Therapy, Shinshu University School of Medicine

A 69-year-old man was referred to our hospital because of occasional nosebleeds over a period of 6 months. Physical examinations were unremarkable except for anemia. Laboratory findings on admission indicated a hemoglobin level of 7.8 g/dL. Magnetic resonance imaging revealed a mass occupying the right nasal cavity and infiltrating the bones of the paranasal sinus. Histological findings revealed olfactory neuroblastoma (esthesioneuroblastoma) and the disease was diagnosed to be at a locally inoperable advanced stage. Concurrent chemoradiotherapy (cisplatin plus etoposide and 60 Gy in 30 fractions of 2.0 Gy) was performed. Chemoradiotherapy failed to show significant tumor size reduction, but the nosebleeds stopped. The patient remains disease-free over 3 years after treatment. Although olfactory neuroblastoma is an extremely rare nasal tumor, we should be aware of the disease as a potential cause of nasal bleeding and anemia. *Shinshu Med J* 64 : 247–252, 2016

(Received for publication March 15, 2016 ; accepted in revised form May 13, 2016)

Key words : epistaxis, chemoradiotherapy, cisplatin, VP-16, radiotherapy

I Introduction

Olfactory neuroblastoma (ONB), or esthesioneuroblastoma, is a rare tumor originating from the olfactory neuroepithelium, which was first described by Berger et al. in 1924¹⁾. ONB accounts for approximately 2 %–3 % of all sinonasal tumors with an incidence of approximately 0.4 cases per million²⁾. Clinically, ONB presents most commonly as a large, unilateral, polypoid, glistening, red-gray mass in the superior nasal cavity. Therefore, the primary clinical symptoms are unilateral nasal obstruction and epistaxis^{3)–7)}. We encountered a case of ONB with occasional epistaxis over a period of 6 months and subsequently presenting with persistent nasal bleeding after biopsy examination. The patient was treated

with chemoradiotherapy and remains disease-free over 3 years after treatment. Here, we describe the clinical course and discuss the disease and therapy.

II Case Presentation

A 69-year-old man was referred to our hospital because of occasional nosebleeds over a period of 6 months. Physical examinations were unremarkable except for anemia and identification of a mass in the right nasal cavity. There was no superficial lymph node swelling. Laboratory findings indicated a hemoglobin level of 8.7 g/dL (MCV 83.0 fl, MCH 24.6 pg, MCHC 29.7 %). Computed tomography (CT) and magnetic resonance imaging (MRI) showed a hypervascular mass occupying the right nasal cavity and infiltrating the bones of the paranasal sinus (**Fig. 1, 2**). After biopsy of the right nasal mass, the patient went home. Two days later, he had a persistent nosebleed and was taken by ambulance to our hospital where he was admitted. Gauze packing and intravenous hemostatic drugs

* Corresponding author : Tomonobu Koizumi
Department of Comprehensive Cancer Therapy, Shinshu University School of Medicine, 3-1-1 Asahi, Matsumoto, Nagano 390-8621, Japan
E-mail : tomonobu@shinshu-u.ac.jp.

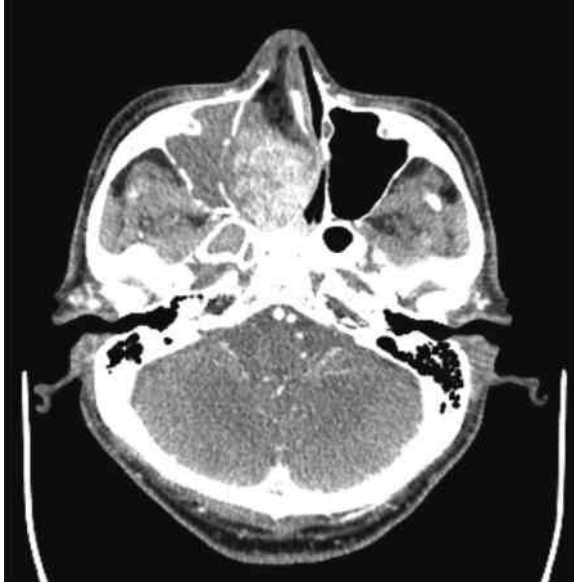
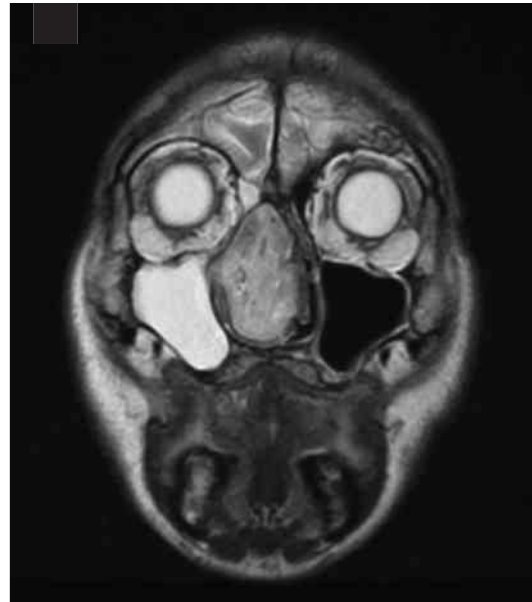
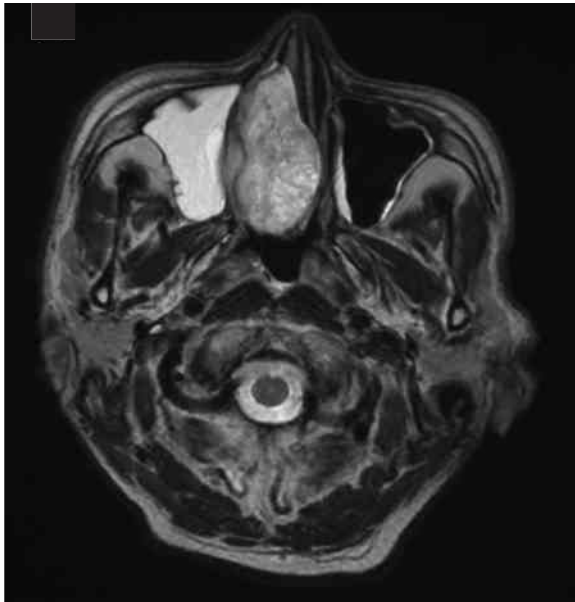Fig. 1 Enhanced computed tomography (CT) showing a contrast-enhanced hypervascular mass in the right nasal cavity.



A

B

Fig. 2 Magnetic resonance imaging (MRI) A ; axial image, B ; coronal image showed a homogenous contrast-enhanced mass occupying the right nasal cavity and infiltrating the bones of the paranasal sinus.

were applied. The bleeding showed marked reduction, but his anemia progressed and his hemoglobin level decreased to 7.8 g/dL. Histological findings showed groups of atypical small round cells with hyperchromatic nuclei under the epithelium (**Fig. 3**). The immunohistochemical findings revealed that the atypical cells were negative for cytokeratin (CK) AE1/AE3, S-100 protein, and melanoma-associated antigen (HMB) 45 (**Fig. 4**), and positive for

chromogranin A and synaptophysin, neuron-specific enolase (NSE) (**Fig. 5**). These observations were consistent with the histological findings of ONB, although Flexner-Wintersteiner and/or Homer Wright rosettes were not observed. In addition, tumor cells were negative for CD 99 and bcl2 in immunohistochemical examination, distinguishing them from Ewing sarcoma and primitive neuroectodermal tumor. Ki-67 labeling index was 7 % in

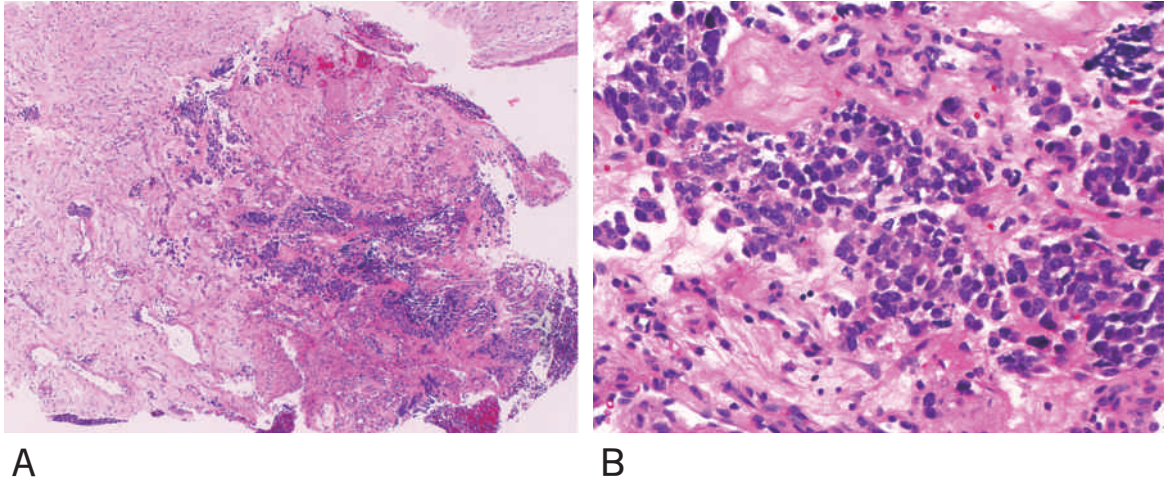


Fig. 3 Hematoxylin and eosin staining, low- (A) and high-power fields (B). Groups of atypical small round cells with hyperchromatic nuclei were observed under the epithelium. Flexner-Wintersteiner and/or Homer Wright rosettes were not observed in the present case.

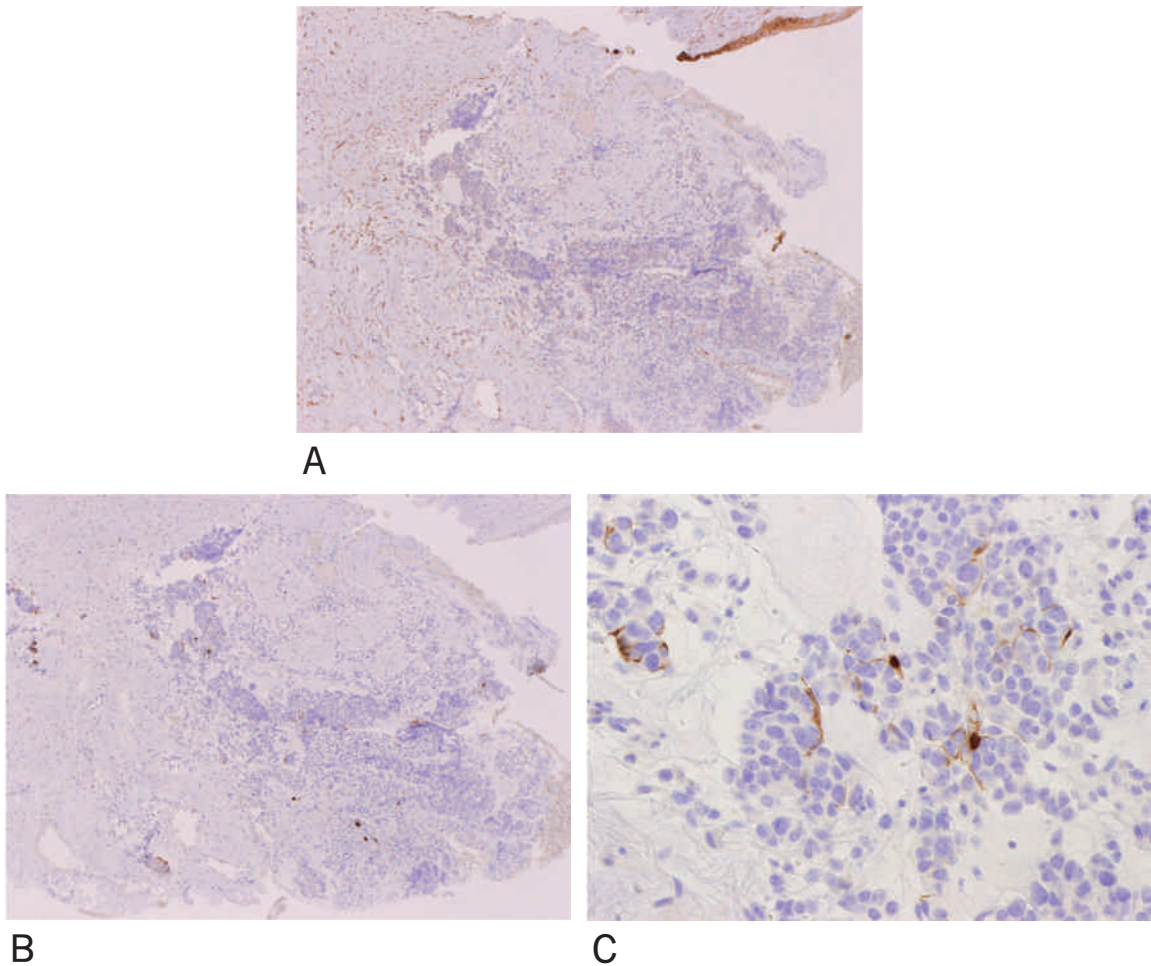


Fig. 4 Immunohistochemical findings indicated that malignant cells were negative for cytokeratin (CK) AE1/AE3 (A) or S-100 protein in the low- power field (B). S-100 protein-positive cells were observed in the high-power field (C), but these cells seemed to be sustentacular cells.

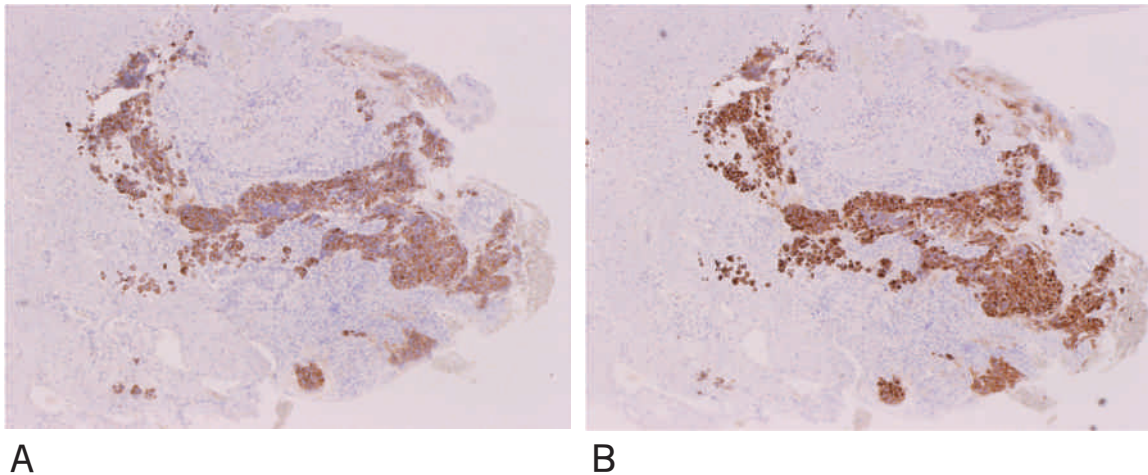


Fig. 5 Immunohistochemical findings indicated that malignant cells were positive for chromogranin A (A) and synaptophysin (B).

the present case.

There was no distant metastasis, but surgical excision was anyway impossible because of the locally advanced nature of the tumor. He was treated with concurrent chemoradiotherapy, and received a dose of 60 Gy in 30 fractions of 2.0 Gy over 6 weeks. Chemotherapy was initiated with cisplatin (CDDP) at 80 mg/m² intravenously on days 1 and 29, and etoposide (VP-16) at 100 mg/m² intravenously on days 1 - 3 and 29 - 31. Although chemoradiotherapy failed to significantly reduce the tumor size, the tumor remained stable and there were no further episodes of nasal bleeding after treatment. The patient has shown progression-free survival for over 3 years.

III Discussion

In general, ONB is a slow-growing tumor with long-standing symptomatology³⁾⁻⁸⁾. The clinical symptoms are unilateral nasal obstruction and epistaxis, including pain, excessive lacrimation, rhinorrhea visual disturbances, and anosmia³⁾⁻⁸⁾. In our case, recurrent epistaxis was observed 6 months before admission. However, the patient presented with persistent nasal bleeding after biopsy and developed further anemia, which was a noteworthy clinical manifestation in the present case. Thus, extreme caution should be taken in the approach to the biopsy, due to the potential risk of significant bleeding

However, histological diagnosis is essential for ONB because of the broad and complex histological findings in tumors arising from the sinonasal tract, including squamous cell carcinoma, sinonasal undifferentiated carcinoma, small cell neuroendocrine carcinoma, rhabdomyosarcoma, Ewing sarcoma lymphoma, malignant melanoma, etc.³⁾⁹⁾. In addition there are no specific clinical and radiographic findings in patients with ONB that could be useful for differential diagnosis from these nasal tumors. Histologically, primitive-appearing "small round blue cells" with finely granular chromatin, a distinctive lobular and often coalescing architectural growth pattern are remarkable findings in ONB³⁾⁹⁾. Furthermore, immunohistochemical staining, including neuroendocrine immunophenotype without significant cytokeratin expression and positivity for S-100³⁾⁹⁾¹⁰⁾, confirm the diagnosis. These findings were consistent with those in the present case.

There is no universally accepted staging system for ONB. Kadish et al.⁸⁾ proposed a staging system for ONB based on the radiographic extent of the tumor: stage A, disease in only the nasal cavity; stage B, disease confined to the nasal cavity and paranasal sinuses; and stage C, lesions with distant spread from the nasal cavity, usually involving the base of the skull, orbit, or intracranial cavity. The tumor in the present case was considered to be Kadish stage C. This staging system has been

widely utilized and correlates well with prognosis. A study of 311 patients based on the Surveillance, Epidemiology, and End Results database showed that disease-specific survival at 10 years was correlated with “modified” Kadish staging (83 %, 49 %, 39 %, and 13 % for stages A, B, C, and D, respectively)¹¹. In this analysis, original Kadish C was divided into stage C (beyond the sinuses, including the orbit or intracranial extension) and D (distant metastasis) in the “modified” Kadish staging.

Surgery followed by radiotherapy is generally accepted as the gold standard treatment in ONB regardless of Kadish stage, with the possible exception of disease metastasis^{3)–8)12)13)}. Several case series studies demonstrated the longest survival times in patients receiving the modalities, compared with either surgery or radiation alone^{4)–8)12)13)}. However, non-surgically treated or inoperable subjects were included among ONB patients with Kadish C, as in the present case. Takenaka et al.⁷⁾ summarized 104 Japanese patients with ONB reported from 1990 to 2013 and found that approximately half of the patients were stage Kadish C. They reported that 40 % were non-surgically treated patients and that survival was significantly poorer compared with surgically treated patients.

Combined modality treatment with chemoradiation has been increasingly adopted for these inoperable patients over the last two decades^{5)14)–16)}. The efficacy of chemotherapy using CDDP, cyclophosphamide, vincristine, doxorubicin, or VP-16, etc., with and without radiotherapy was reported^{14)–16)}, although there have been no broad reports of useful

chemotherapy regimens in patients with advanced metastatic ONB to date. Fitzek et al.⁵⁾ examined the usefulness of neoadjuvant CDDP + VP-16 chemotherapy in 19 cases of neuroendocrine tumors in the sinonasal tract, including nine cases of ONB. They found that 13 patients showed a significant response to two cycles of CDDP + VP-16 with a response rate of 68.4 %. In addition, Gupta et al.¹⁴⁾ reported a case of ONB with extensive involvement of the nasal cavities, nasopharynx, paranasal sinuses, and orbit that showed a complete response to concurrent chemoradiation with CDDP + VP-16 chemotherapy. The chemotherapy regimen with concurrent radiotherapy has been widely accepted in limited stage cases of small cell lung cancer¹⁷⁾, in which the tumor cells were of neuroendocrine origin as well as ONB. Therefore, we selected CDDP + VP-16 combined concurrent radiotherapy in the present case. Unfortunately, the combined chemoradiotherapy failed to reduce the tumor size and the residual mass was still inoperable. However, the patient has remained free of symptoms, including epistaxis, for over 3 years. Combined chemoradiation might be efficacious for local control of this disease.

In summary, we described a case of olfactory neuroblastoma that showed occasional epistaxis over a period of 6 months, and subsequently developed persistent nose bleeds after obtaining a biopsy specimen of the primary tumor. We should be aware of the disease as a cause of nasal bleeding, and further studies regarding therapeutic strategies for inoperable olfactory neuroblastoma are warranted.

References

- 1) Berger L, Luc G, Richard D : L'esthesioneuroepitheliome olfactif. Bull Assoc Franc Etude Cancer 13 : 410-412, 1924
- 2) McCormack LJ, Harris HE : Neurogenic tumors of the nasal fossa. JAMA 157 : 318-321, 1955
- 3) Thompson LD : Olfactory neuroblastoma. Head Neck Patho 3 : 252-259, 2009
- 4) Diaz EM Jr, Johnigan RH 3rd, Pero C, El-Naggar AK, Roberts DB, Barker JL, DeMonte F : Olfactory neuroblastoma : the 22-year experience at one comprehensive cancer center. Head Neck 27 : 138-149, 2005
- 5) Fitzek MM, Thornton AF, Varvares M, Ancukiewicz M, Mcintyre J, Adams J, Rosenthal S, Joseph M, Amrein P : Neuroendocrine tumors of the sinonasal tract. Results of a prospective study incorporating chemotherapy, surgery, and combined proton-photon radiotherapy. Cancer 94 : 2623-2634, 2002
- 6) Dulguerov P, Allal AS, Calcaterra TC : Esthesioneuroblastoma : a meta-analysis and review. Lancet Oncol 2 : 683-

690, 2001

- 7) Takenaka Y, Yamamoto M, Cho H, Nakahara S, Yasui T, Yamamoto Y, Nishiike S, Inohara H: Treatment outcome and failure pattern of olfactory neuroblastoma: a clinical analysis of 14 cases and meta-analysis of Japanese cases. *Nihon Jibiinkoka Gakkai Kaiho* 117: 666-672, 2014 [Article in Japanese]
- 8) Kadish S, Goodman M, Wang CC: Olfactory neuroblastoma. A clinical analysis of 17 cases. *Cancer* 37: 1571-1576, 1976
- 9) Faragalla H, Weinreb I: Olfactory neuroblastoma: a review and update. *Adv Anat Pathol* 16: 322-331, 2009
- 10) Taxy JB, Bharani NK, Mills SE, Frierson HF Jr, Gould VE: The spectrum of olfactory neural tumors. A light-microscopic immunohistochemical and ultrastructural analysis. *Am J Surg Pathol* 10: 687-695, 1986
- 11) Jethanamest D, Morris LG, Sikora AG, Kutler DI: Esthesioneuroblastoma: a population based analysis of survival and prognostic factors. *Arch Otolaryngol Head Neck Surg* 133: 276-280, 2007
- 12) McLean JN, Nunley SR, Klass C, Moore C, Müller S, Johnstone PA: Combined modality therapy of esthesioneuroblastoma. *Otolaryngol Head Neck Surg* 136: 998-1002, 2007
- 13) Platek ME, Merzianu M, Mashtare TL, Papat SR, Rigual NR, Warren GW, Singh AK: Improved survival following surgery and radiation therapy for olfactory neuroblastoma: analysis of the SEER database. *Radiat Oncol* 6: 41, 2011
- 14) Gupta S, Husain N, Sundar S: Esthesioneuroblastoma chemotherapy and radiotherapy for extensive disease: a case report. *World J Surg Oncol* 9: 118, 2011
- 15) Aljumaily RM, Nystrom JS, Wein RO: Neoadjuvant chemotherapy in the setting of locally advanced olfactory neuroblastoma with intracranial extension. *Rare Tumors* 3: e1, 2011
- 16) Turano S, Mastroianni C, Manfredi C, Biamonte R, Ceniti S, Liguori V, De Simone R, Conforti S, Filice A, Rovito A, Viscomi C, Patitucci G, Palazzo S: Advanced adult esthesioneuroblastoma successfully treated with cisplatin and etoposide alternated with doxorubicin, ifosfamide and vincristine. *J Neurooncol* 98: 131-135, 2010
- 17) Stinchcombe TE, Gore EM: Limited-stage small cell lung cancer: current chemoradiotherapy treatment paradigms. *Oncologist* 15: 187-195, 2010

(2016. 3. 15 received; 2016. 5. 13 accepted)