

Efficacy of Temporary Transvenous Pacing to Prevent Atropine-resistant Bradycardia during Surgery for a Tumor in the Brainstem Region : A Case Report

Yuki YOSHIYAMA*, Yuki SUGIYAMA, Susumu IDE, Satoshi FUSEYA
Toru MURAKAMI and Mikito KAWAMATA

Department of Anesthesiology and Resuscitology, Shinshu University School of Medicine

When surgery is performed in the brainstem region, the parasympathetic cardiac reflex via the vagus nerve may occur, possibly resulting in bradycardia/asystole and hypotension. We report a case in which temporary cardiac pacing was useful to prevent recurrent atropine-resistant bradycardia during surgery in the brainstem region. A 42-year-old woman underwent resection of a large ependymoma that extended from the midbrain to the medulla oblongata. She had no episodes of syncope, preoperative bradycardia, or arrhythmia. Because the anticipated long duration of surgical manipulation in the brainstem region came with a high risk of bradycardia/asystole occurrence due to tumor removal, a transvenous pacing (TVP) wire was temporarily implanted before surgery. Just after the beginning of tumor removal, severe bradycardia (28 bpm) and hypotension occurred. Tumor removal was paused, and 0.5 mg of atropine was administered intravenously. The heart rate immediately increased to 57 bpm and hemodynamics were stable for 2 min ; however, severe bradycardia (13 bpm) and hypotension recurred 1 min after the resumption of tumor removal. TVP (back-up VVI pacing at 40 bpm) was initiated, and bradycardia and hypotension did not occur again. The subsequent course was uneventful and there were no neurological abnormalities. These findings suggested that atropine was only initially effective in this patient after surgical manipulation was started, and that placement of a TVP wire is useful even when atropine-resistant bradycardia occurs during brainstem surgery. *Shinshu Med J 64 : 153–157, 2016*

(Received for publication November 17, 2015 ; accepted in revised form January 27, 2016)

Key words : brainstem region surgery, vagal reflex, atropine-resistant bradycardia, transvenous pacing

I Introduction

Surgery in the brainstem region often induces temporary hemodynamic changes, including bradycardia/asystole and hypotension¹⁾. These hemodynamic changes are thought to be a result of a parasympathetic reflex, such as the vagal reflex, although the precise mechanisms underlying these changes remain unclear. Here we report a case in

which a transvenous pacing (TVP) wire was temporarily implanted before surgery because the anticipated long duration of surgical manipulation in the brainstem region came with a high risk of bradycardia/asystole occurrence due to tumor removal. In this case, surgery induced bradycardia was found to be atropine-resistant and occurred frequently ; therefore TVP was effective and indispensable during surgical manipulation in the brainstem region.

II Case Report

A 42-year-old female, 165 cm tall and weighing 41 kg, presented with paroxysmal vomiting and weight

* Corresponding author : Yuki Yoshiyama
Department of Anesthesiology and Resuscitology, Shinshu University School of Medicine, 3-1-1 Asahi, Matsumoto, Nagano 390-8621, Japan
E-mail : yoshiyama@shinshu-u.ac.jp

loss for 2 years, and vertigo for 4 months. She was diagnosed by MRI with a large brain tumor, which originated in the fourth ventricle, extending from the midbrain to the medulla oblongata and partially invading the cerebellum (**Fig. 1, 2**). The patient had not experienced any preoperative episodes of syncope, arrhythmia, including bradycardia, or orthostatic hypotension. Electrocardiogram showed normal sinus rhythm and a heart rate (HR) of 71 bpm. No abnormalities, including cardiac function abnormalities, were identified by preoperative tests. The patient was scheduled to undergo resection of the tumor, and no premedication was administered.

Anesthesia was induced with 100 μg of fentanyl and propofol via a target-controlled infusion (TCI) at an effect-site concentration of 4.0 $\mu\text{g}/\text{ml}$. After loss of consciousness, 40 mg of rocuronium was administered for intubation. Anesthesia was maintained by TCI of propofol at an effect-site concentration of 2.5–3.0 $\mu\text{g}/\text{ml}$ and remifentanyl 0.15–0.20 $\mu\text{g}/\text{kg}/\text{min}$. After the induction of anesthesia, a TVP catheter (Eledyn EB 10, B. Braun Medical Inc., Berlin, Germany) was inserted via the right internal jugular vein under fluoroscopic guidance, and the tip of the catheter was placed on the apical region of the right ventricle at a distance of 20 cm. VVI pacing was confirmed by a pacing rate of 100 bpm when the HR of the patient was 65 bpm (**Fig. 3A, B**), and the stimulation threshold was 1 mA. Following confirmation, pacing was suspended. During surgery, a direct current defibrillator with transcutaneous pacing (TCP) function was made available. Surgery was performed in the prone position.

Intraoperative neurophysiological monitoring was performed, including use of motor evoked potentials (MEP), somatosensory evoked potentials (SEP), and auditory brainstem response (ABR). HR and systolic blood pressure (SBP) of the patient was 64–81 bpm and 95–118 mmHg, respectively, from the start of surgery to the beginning of tumor removal. Severe bradycardia (28 bpm) and decrease of SBP from 110 to 55 mmHg occurred immediately after the start of tumor resection. Pausing of tumor

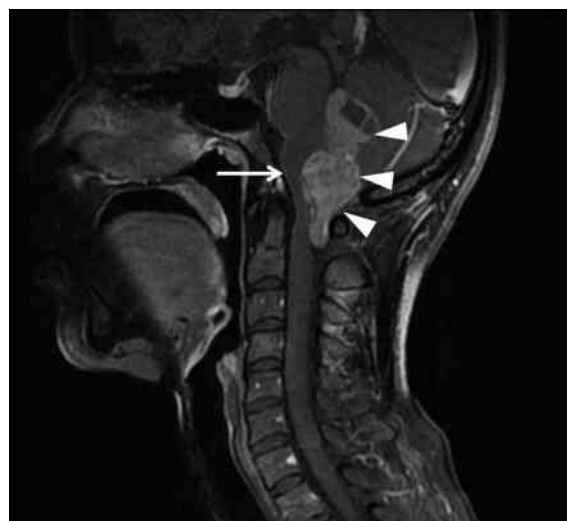

Fig. 1 Preoperative contrast-enhanced T1-weighted MRI scans, showing a large ependymoma (white arrowheads) in the fourth ventricle located on the dorsal medulla oblongata (white arrow).

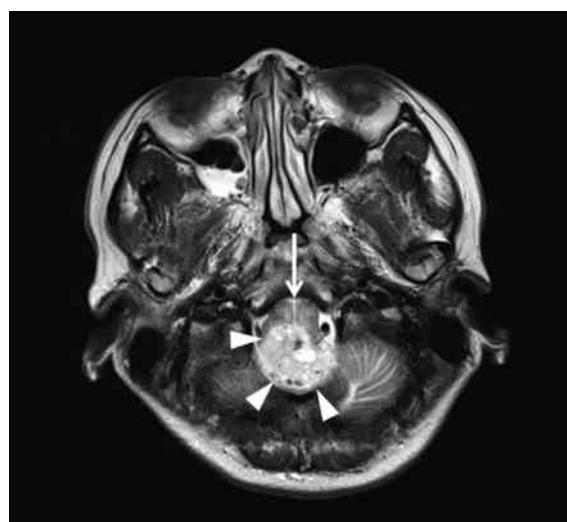


Fig. 2 Preoperative T2-weighted MRI scans, showing a large tumor (white arrowheads) located on the dorsal medulla oblongata (white arrow).

removal and administration of 0.5 mg atropine resulted in immediate return of HR and SBP to 57 bpm and 94 mmHg, respectively, and hemodynamics were stable for 2 min; however, 1 min after resumption of tumor removal, severe bradycardia (13 bpm) due to sinus arrest and second degree atrioventricular block (Wenckebach block) recurred despite prophylactic atropine administration (**Fig. 3C**). Therefore, we initiated TVP (back-up VVI pacing at 40 bpm) (**Fig. 3D**).

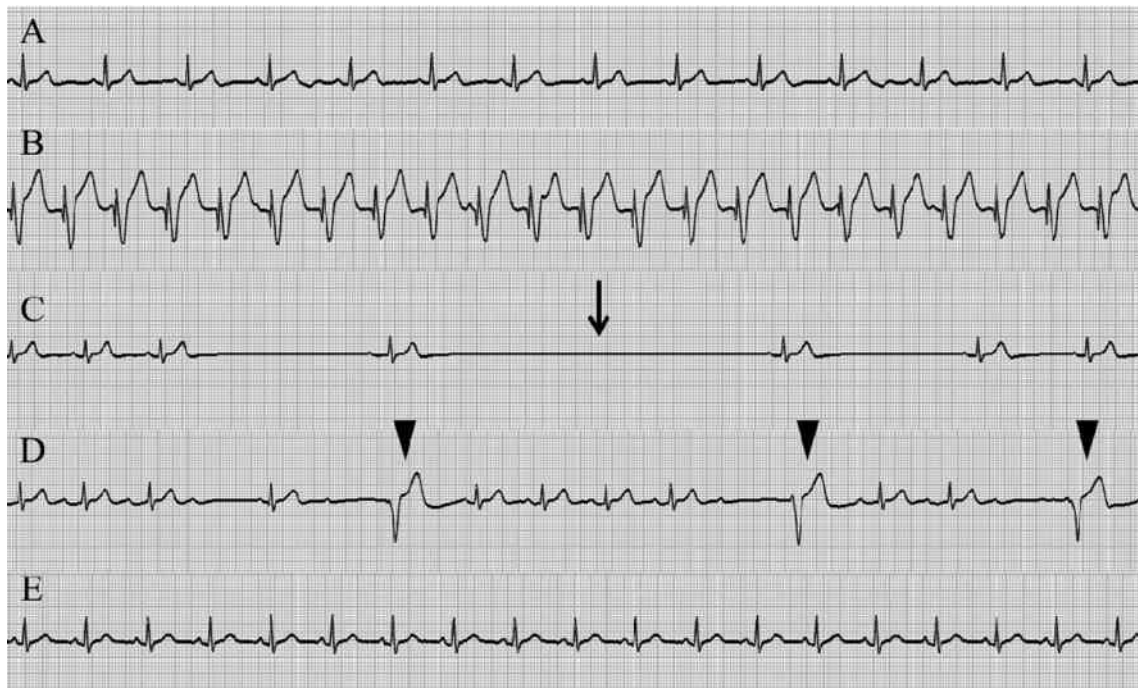


Fig. 3 Perioperative electrocardiograms before surgery (A) and during VVI pacing at 100 bpm (B). Atropine-resistant bradycardia (13 bpm) due to surgical manipulation was seen (black arrow) (C). Back-up pacing (black arrowheads) was started (D). No bradycardia was seen after surgery (E).

No significant changes were observed in neurophysiological parameters, such as 10 % increase in latency and 50 % decrease in amplitude in MEP and SEP, and 1 msec increase in latency and 50 % decrease in amplitude of v wave in ABR during surgery. The surgery and anesthesia duration was 683 min and 863 min, respectively. Total intraoperative blood loss was 600 g and total urine volume was 2,350 ml. Total infusion volume was 3,700 ml (crystalloid fluid 2,200 ml; colloid fluid 1,500 ml). Although TVP was required 36 times through the duration of the tumor removal, bradycardia/arrhythmia did not occur after the end of tumor removal (**Fig. 3E**); therefore, the pacing wire was removed before the patient left the operating room. After surgery, the patient was referred to the ICU for post-operative follow-up; the postoperative course was uneventful, and no neurological abnormalities were noted. The trachea was extubated, and the patient was transferred to the general ward on the second postoperative day. Radiation therapy was initiated 19 days postoperatively, and the subsequent course was uneventful. The patient was dis-

charged 89 days postoperatively.

III Discussion

Acute changes in hemodynamics induced by surgical manipulation occasionally occur during neurosurgery, especially in surgeries in the brainstem region. It has been reported that surgical compression of the medulla oblongata causes acute bradycardia and hypotension¹⁾, as was seen in the present patient. Mechanisms underlying bradycardia induced by compression of the medulla oblongata are thought to be as follows. The excitatory nerve fibers extending from the nucleus tractus solitarius (nTS), which is located on the dorsal side of the medulla oblongata, activate the caudal ventrolateral medulla (CVLM) of the medulla oblongata. From the CVLM, GABAergic inhibitory nerve fibers then inhibit the activity of the rostral ventrolateral medulla (RVLM). Because the RVLM controls the sympathetic nervous system, its inhibition leads to suppression of sympathetic activity, and results in bradycardia. Additionally, excitatory nerve pathways from the nTS to the nucleus am-

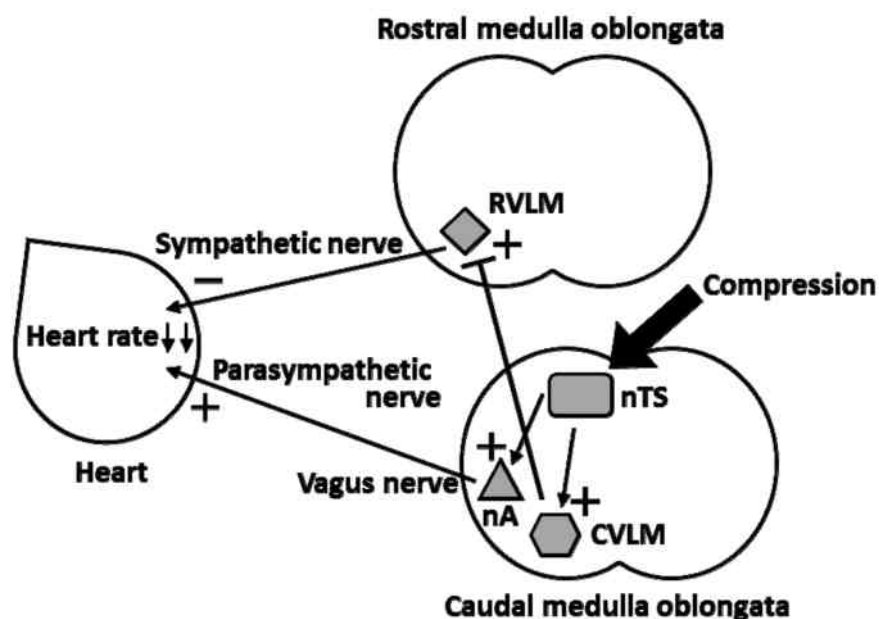


Fig. 4 Schematic drawing of the mechanism of heart rate control. Nucleus tractus solitarius (nTS) induces both inhibition of sympathetic nerve and activation of parasympathetic nerve, therefore compression of nTS causes severe bradycardia. RVLM=rostral ventrolateral medulla, CVLM=caudal ventrolateral medulla, nA=nucleus ambiguus.

biguus and vagus nerve can activate parasympathetic nerves and thus induce bradycardia (Fig. 4).

Some reports pointed out the usefulness of TVP in neurosurgery²⁾³⁾. In the present case, we predicted that severe and recurrent bradycardia, which is life-threatening during microsurgery in the prone position, might occur multiple times throughout the long duration of surgery. Therefore, we inserted a TVP catheter prior to surgery and confirmed that temporary pacing operated correctly after the positional change to avoid malposition of the TVP catheter⁴⁾. Indeed, bradycardia first occurred at the start of brain stem tumor removal. Although administration of atropine was effective for the first incident of bradycardia, it was insufficient to inhibit the second incident induced by resumption of surgery. When the second incident occurred, we thought that the initial administration of atropine was still in effect, because the duration of atropine action is normally 1-2 hr. Therefore, we speculate that predominant parasympathetic activity induced by general anesthesia and/or activation of parasympathetic activity induced by surgical manipulation may have been stronger than the inhibition of parasympathetic

activity by atropine, and this imbalance resulted in atropine-resistant bradycardia.

Some studies have reported atropine-resistant bradycardia in patients with spinal cord injury⁵⁾⁶⁾. Cervical spinal cord injury-induced bradycardia is thought to be due to the disruption of cardiac sympathetic activity. Although reducing parasympathetic activity may indirectly, yet weakly, affect sympathetic activity, atropine may possibly be ineffective in increasing heart rate in such cases.

If atropine is ineffective against these types of bradycardia, temporary cardiac pacing should be required. There are two choices for temporary pacing, TCP and TVP. It has been reported that there are no differences in hemodynamics between the use of TCP and TVP⁷⁾, and that TCP is a safe and effective alternative method to prophylactic TVP⁸⁾. In the present case, TVP was used to avoid the potential risk of TCP-induced body movement, which may lead to interruption of microsurgery and severe complications, such as neuronal injury. The incidence of complications related to TVP insertion, such as arterial puncture, pneumothorax, hemopericardium, infection, and displacement of the pacing

wire, has been reported to be 15.0–28.8 %⁹⁾¹⁰⁾.

We inserted the TVP wire just prior to the operation to avoid TVP wire malposition. It has been shown that 17 % of TVP pacing wires required repositioning in the first 12 hr after insertion⁴⁾, and the median time to TVP wire displacement was 1 day (range, 0.04–8)¹⁰⁾. Therefore, TCP was also made available in case of intraoperative TVP failure due to wire malposition or other TVP malfunctions during surgery¹¹⁾. Although no study has reported a change in TVP wire position when the patient is moved to the prone position, in the present study, proper TVP wire position was confirmed after the

positional change.

In conclusion, intraoperative TVP was effective for treating intractable atropine-resistant bradycardia during surgery for a tumor in the brainstem region. The present findings suggest that atropine was only initially effective against bradycardia induced by surgical manipulation during brainstem surgery, and TVP should be inserted prior to surgery for prevention of recurrent atropine-resistant bradycardia in such cases, even if the patient has had no preoperative episode of syncope, arrhythmia including bradycardia, or orthostatic hypotension.

References

- 1) Endo T, Sato K, Takahashi T, Kato M: Acute hypotension and bradycardia by medulla oblongata compression in spinal surgery. *J Neurosurg Anesthesiol* 13 : 310–313, 2001
- 2) Agrawal A, Timothy J, Cincu R, Agarwal T, Waghmare LB: Bradycardia in neurosurgery. *Clin Neurol Neurosurg* 110 : 321–327, 2008
- 3) Della Puppa A, Rustemi O, Giofrè G, Leoni L: Brainstem surgery assisted by temporary trans-venous pacing to prevent severe bradycardia. *Acta Neurochirurgica* 156 : 431–432, 2014
- 4) Murphy JJ: Current practice and complications of temporary transvenous cardiac pacing. *BMJ* 312 : 1134, 1996
- 5) Pasnoori VR, Leesar MA: Use of aminophylline in the treatment of severe symptomatic bradycardia resistant to atropine. *Cardiol Rev* 12 : 65–68, 2004
- 6) Sakamoto T, Sadanaga T, Okazaki T: Sequential use of aminophylline and theophylline for the treatment of atropine-resistant bradycardia after spinal cord injury: a case report. *J Cardiol* 49 : 91–96, 2007
- 7) Toumanidis ST, Danopoulos A, Vassilopoulos N, Nanas SN, Kostamis P, Sideris DA, Mouloupoulos SD: Acute effects of external and internal pacing on ejection fraction in patients with severe cardiac failure. *Acta Cardiol* 49 : 25–41, 1994
- 8) Buran MJ: Transcutaneous pacing as an alternative to prophylactic transvenous pacemaker insertion. *Crit Care Med* 15 : 623–624, 1987
- 9) Ferri LA, Farina A, Lenatti L, Ruffa F, Tiberti G, Piatti L, Savonitto S: Emergent transvenous cardiac pacing using ultrasound guidance: a prospective study versus the standard fluoroscopy-guided procedure. *Eur Heart J Acute Cardiovasc Care* [Epub : Feb. 11, 2015] doi : 10.1177/2048872615572598
- 10) Betts TR: Regional survey of temporary transvenous pacing procedures and complications. *Postgrad Med J* 79 : 463–465, 2003
- 11) Austin JL, Preis LK, Crampton RS, Beller GA, Martin RP: Analysis of pacemaker malfunction and complications of temporary pacing in the coronary care unit. *Am J Cardiol* 49 : 301–306, 1982

(2015. 11. 17 received; 2016. 1. 27 accepted)