

29. **CHOLECYSTOCOLONIC FISTULA: DEMONSTRATING THE NEED FOR FURTHER IMAGING ASSESSMENT FOLLOWING AN ABNORMAL ULTRASOUND EXAM**

Andrew J. Gauger¹, James Wilcox².

¹ Second-year Medical Student, Indiana University School of Medicine, Indianapolis, United States.

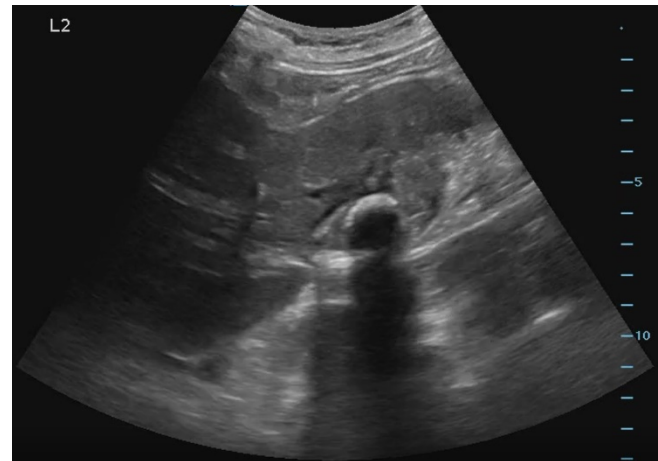
² MD, Indiana University School of Medicine, Indianapolis, United States.

 <https://www.youtube.com/watch?v=0JIMP5Fyl7s&t=27569s>

INTRODUCTION: Point of care ultrasound (PoCUS) is a diagnostic tool that can efficiently answer targeted clinical questions at the bedside. Such questions include confirming or ruling out the presence of a specific complication suspected by the clinician, like an abdominal aortic aneurysm, for example. Proper identification of any such complication is reliant upon a fundamental knowledge and recognition of normal anatomy in each view, so the ultrasound provider can distinguish normal from a variety of hallmark pathologic signs. A positive finding warrants immediate changes in management, often including further imaging to guide interventions. However, indeterminate, or incidental findings unrelated to the patient's chief complaint can be found. While usually benign, sometimes these findings are indicative of an underlying pathology not initially suspected by the physician. In these settings, PoCUS has limited diagnostic value, and therefore it is important to highlight the need for further imaging following discovery of abnormal or incidental findings on an ultrasound exam. **CASE:** The patient was a 75-year-old female with COPD, coronary artery disease and hypertension. Her overall health declined after an admission for COVID pneumonia, which required treatment for oxygen. She never improved completely and was diagnosed with pulmonary fibrosis, likely secondary to COVID-19. She presented to our outpatient clinic for follow up from a recent hospitalization for respiratory decompensation and heart failure. During the visit she complained of intermittent right sided abdominal pain which had been present for a couple weeks. It was not associated with eating, and the pain did improve some after passing gas. The decision was made to perform a bedside ultrasound of her gallbladder to look for gallstones. Upon visualizing her gallbladder, hyperechoic shadowing in a smooth, circumferential nature filled the gallbladder. The differential included porcelain gallbladder, stone filled gallbladder, or emphysematous cholecystitis. She was referred for further imaging, but before she could get imaging completed, she presented to the emergency department due to worsening pain. A CT scan of the abdomen showed an ill-defined soft tissue mass with surrounding inflammation involving the inferior right hepatic lobe, gallbladder and cecal visualization. Overall, given the surrounding inflammation this was favored to represent perforated cholecystitis with inflammatory fistula. Interventional radiology attempted to place a drain which was unsuccessful but did demonstrate fistulization with the colon. She later had a cholecystectomy performed, with a pathology report which detailed results showing metastatic poorly differentiated adenocarcinoma with signet ring and mucinous features. Oncology was consulted for treatment options, but unfortunately the patient passed away from cardiopulmonary compromise before treatment could be initiated. **CONCLUSION:** This case demonstrates the importance of follow up imaging for abnormal bedside ultrasound studies which do not follow the typical PoCUS pathway. Point of care ultrasound is used to answer a binary question, "Does my patient have a gallstone?" for example. If there are abnormal findings, or findings which do not correlate with the history and physical examination,

more advanced imaging assessment is required and should be ordered by the point of care ultrasound provider.

Figure. Gallbladder Bedside Ultrasound Examination.



Key words: Ultrasound; Diagnostic; Intestinal Fistula; Colonic Neoplasms; Adenocarcinoma; Incidental Findings. (Source: MeSH-NLM).