

Our Nuts and Bolts in the Permanent Pacemakers' Explanation Techniques

Shahab Saidullah¹, Bakhtawar Shah², Salman Habib³, Asma Rauf⁴

¹Assistant Professor of Cardiology, PIMS hospital, Islamabad

²Principal Medical Officer, Hayatabad Medical Centre, Peshawar

³Post-Graduate Resident, Department of Cardiology, PIMS Hospital, Islamabad

⁴Consultant Cardiologist, Bilal Hospital, Rawalpindi

Author's Contribution

^{1,2}Substantial contributions to the conception or design of the work, the acquisition Final approval of the version to be published^{4,3}
Drafting the work or revising it critically for important intellectual content, analysis, or interpretation of data for the work

Funding Source: None

Conflict of Interest: None

Received: Mar 03, 2022

Accepted: Aug 25, 2022

Address of Correspondent

Dr. Shahab Saidullah

Assistant Professor of Cardiology,

PIMS hospital, Islamabad

shahab_saidullah@yahoo.com

ABSTRACT

Objective: Our goal is to share our two decades of experience with implantable electrical device explanation at our electrophysiology centre at Hayat Abad Medical Complex in Peshawar.

Methodology: After baseline patient were brought nil by mouth to catheterization laboratory (Cath: lab). A temporary pacemaker (TPM) implanted for backup. In case of box change, a new device is attached after checking the integrity of the lead and device placed in the same pocket. But if of lead extraction was also needed, then stylet was put inside the lead and with twisting movement and mild traction the lead removed and new lead implanted with Seldinger's technique, battery attached and wound closed in layers.

Results: Out of 1670, there were 1535 (91.9%) new implantations and 135 (8.08%) repeat procedures. The pulse generator was replaced without lead replacement in 59 (3.5%) patients. In 36 (2.15%) patients, the ventricular lead or atrial lead was successfully reposition. A total of 32 (1.9%) successful explanations were performed in the study period.

Conclusion: The explanation of devices like implantation needs special gadgets and training for the safe and successful procedure.

Keywords: Permanent pacemakers, explantation techniques, temporary pacemaker (TPM), internal jugular vein (IJV), femoral vein.

Cite this article as: Saidullah S, Shah B, Habib S, Rauf A. Our Nuts and Bolts in the Permanent Pacemakers' Explanation Techniques. *Ann Pak Inst Med Sci.* 2022; 18(3):234-239. doi. 10.48036/apims.v18i3.490

Introduction

Explantation, like the implantation of devices is an art. A box change may be needed alone or it may accompany by lead extraction. If it is just box change then the strategy from very start is different to make it as simple as possible but if lead extraction is part of the procedure then it should be planned differently before incision to shorten the procedure time and minimize the complication rate. For successful explantation if the role of gadgets and expertise cannot be subvert, then at the same time a well-planned procedure cannot be undermine.

With increasing volume of implantation of devices in cardiology¹ the number of explantation² and re-implantation of devices also increasing linearly.³ This may be due to complication like lead or device erosion⁵,

insulation break⁴, lead fracture⁵ and infection on the site of implantation⁶ or it may be due to depletion of pulse generator.⁷ In case of erosion or infection of the device and leads, the whole hardware needs to be explanting all together.⁵ While in case of depletion of pulse generator the device need to be re-implanted on the same site, after explantation of previous pulse generators. When we try to explants the whole hardwires then the recovery of the device is not that difficult but to explants the lead: is cumbersome most of the time.⁸ It need to be made free from the surrounding tissue where the granulation tissue hold it badly and at the same time one need to take care of the vascular bundle so not to damage them unduly.⁹ The lead handling also needs proper care because if the lead gets damage before explantation then the procedure of explantation become very difficult because the stylit could not be put in the lead and then it needs to be helped

by the surgeon or cut it down and left part of the lead in the chest of the patient which remain a permanent threat for infection and erosion.¹⁰ In the present days of implantation we use screwing leads mostly. These leads not only ensure stability soon after the implantation¹¹ but the explantation is also relatively easy in the cardiac catheterization laboratory.¹² However, the past two decades have seen the tined leads mostly¹³ and still we are getting occasionally patients with these leads in our laboratory. There are two draw backs to these leads. The stability issues¹⁴ one and two the explantation¹⁵ if it is needed due to any reasons. Tined leads instead of having active fixing materials there are small tines that protrude backward just proximal to the tip, made of plastic materials, make these leads more difficult to position at the right ventricular apex as the tines tended to anchor on intracardiac structures.¹⁶ Once properly positioned, they induce inflammatory reaction.¹⁷ in the cardiac chambers and then they are hold in position by the granulation tissue¹⁸ which grows around them after they induced inflammation.¹⁹ This tissue takes months to get matured. During this period, these leads remain vulnerable to dislodgment.²⁰ Once in place and then if there is need of explantation due to any reasons, then the granulation tissue inside the heart will not let it come out very easily.²¹ Therefore, to reduce the burden of granulation tissue, the actively fixing leads are coated with steroids which reduce the inflammatory process leads to reduce the burden of granulation tissue, which will definitely improve the pacing quality and lead extraction will be much convenient if it is needed.¹⁷

The explantation of pulse generator due to depletion needs different approach to minimally damage the surrounding tissue, preserve lead integrity and stability but not at the cost of space for new device. Similarly prevention of infection after re-implantation is another issue which needs to be address properly. At time the new incision makes the site vulnerable for lead erosion which demands proper precautions to prevent this dreaded complication. Different people use different approaches to recover the device. We conducted this study at Hayat Abad Medical Complex Peshawar to shear our experience in the field of pacemaker's explantation and box change.

Methodology

Study protocol was approved from the ethical committee of postgraduate medical institute in Peshawar. The data recovered at the electrophysiology department of

Hayatabad Medical Complex Peshawar spans the years 2010 to 2020. A total of 1670 procedures were carried out. The data collected was analyzed with SPSS version 23 for statistical significance.

Of these, there were 59 box change and 32 lead extractions. All patients who presented for box change or device explantation were prepared in accordance with standard protocol. Baseline investigation including full blood count (FBC), renal function test, virology done and bleeding disorders rule out. Patient brought nil by mouth to catheterization laboratory (cath: lab). Temporary pacemaker (TPM) implanted for backup, mostly from internal jugular vein (IJV) or femoral vein if the access from IJV was not possible due to any reason. The lead integrity was checked on programmer, if found intact then the incision was made in way that the existing pocket for device is used without extending the pocket caudally. Therefore, we used to put our incision two to three centimeter superior to the box and by blunt dissection caudally we expose the device. However a caution was exercised for the unpredicted complication during the procedure. If there was a need for the lead extraction due to damage while recovering the device, then the access to the lead should be easy and without any further extension of the incision. In that case by blunt dissection toward the lead the lead sleeve is recovered. It is made free from its surrounding tissue.

On the other hand, if there was a definite reason for lead to be extracted, then it was a different strategy. If there was device erosion, figure 1(a,b), then the device was recovered through the site of erosion and it was detached from the lead. Now, an incision was made on the sleeve of the lead and carefully dissected the tissue to recover the lead. The battery end of the lead is pulled out through this incision. But if the lead extraction is intended due any other reason apart from erosion, then we located the sleeve under fluoroscopy, put our incision there, then, with blunt dissection recover the device first and then make the lead free from the surrounding tissue and detached from the device.

Now the stylet is passed in the lead, unscrew it in case of screwing lead and then with a slight rotatory movement and traction on the lead try to make it free from the surrounding tissue. Most of the time, in case of screwing lead, it come out easily but the tine lead offer great resistance as compare to the screwing lead. As a result, whenever there is a tense situation, we keep the surgical

suit on hand. Once the lead is out, we check the heart for any effusion on echocardiography.

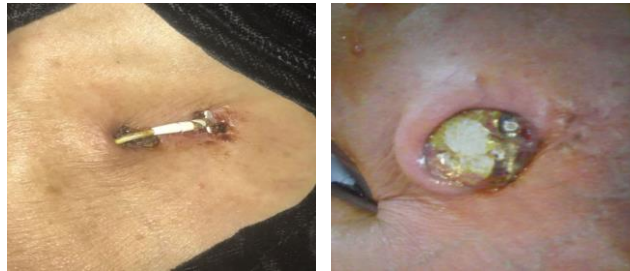

Figure 1(a). Lead and device erosion.

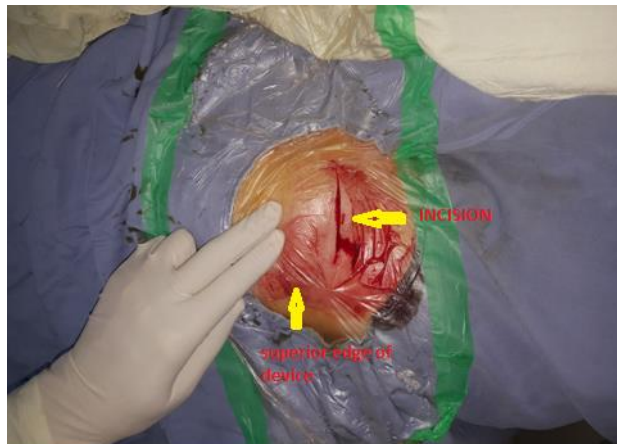


Figure 1(b). Device explantation-incision line away from device

Results

A total of 1670 were performed during the study period. There were 1535 (91.9%) new implantations and 135 (8.08%) repeat procedures. Pulse generator was replaced without lead replacement in 59 (3.5%) patients. In three patients, the devices were upgraded from single chamber device to dual chamber devices by placing the right atrial lead and replacing the single chamber device to dual chamber device. In 36 (2.15%) patients the ventricular lead or atrial lead was successfully reposition where leads were displaced after initial implantation. We were not able to pull out the lead in 3 (0.17%) cases due to intense fibrosis and patients were sent to cardiac surgeon for leads extraction because of infected nature of the leads. Out of 1670 patients 32 (1.9%) patients' devices were successfully explanted. In one patient, during the procedure, the patient became symptomatic, complaining of breathlessness, and on operating table trans-thoracic echocardiography was performed. There was mild rim of pericardial fluid. A temporary device was implanted, and patient was observed in coronary care unit for 24 hour. Patient remains stable and no further intervention

was needed for pericardial fluid. PPM was implanted on 3rd day of the initial procedure. One patient where the lead impedance was high and patient was shifted to operating room for replacement, a new lead was implanted and the damaged lead was buried in tissue and not explanted due to fibrosis. One patient whose device was scheduled for explanations, but explanations was postponed and new device was implanted on the right side leaving the old device incite because the patient was not ready to accept any complication related to explanation.

Procedure	N	%
IMPLANTATION	1535	91.9
FAILED	1	.1
POSTPONED	1	.1
BOX CHANGE	59	3.5
UPGRATION OF DEVICE	3	.2
REPOSITION	36	2.2
LEAD Abandoned	3	.2
EXPLANTATION & NEW DEVICE + LEAD IMPLANTATION	32	1.9
Total	1670	100.0

Discussion

On the one hand, device explantation³ has increased globally as the prevalence of patients using pacemakers, implantable cardioverter defibrillators, and cardiac resynchronization devices has increased.^{1,2} who are at risk of device complications⁵⁻⁸ requiring removal while on the other hand box change^{4, 9} and reuse of all properly functioning intravascular leads is a common practice in cardiology.²⁷ The difficulty in lead extraction is proportional to the indwelling time of the leads because of increasing fibrosis around areas of contact between the lead and surrounding vasculature and myocardium.²⁸ Extraction success has increased with use of modern extraction techniques incorporating use of a laser powered sheath that is able to be selectively applied to disrupt adherent tissue,^{29, 30} compared with older traction-only or non-powered telescoping sheath-based methods.²⁷ However these facilities for extraction of leads are not available in every center and if these are available still the risk of extraction with these modern tools is significant.³⁰ Therefore, to avoid increased fibrosis some centers recommend prophylactic extraction of leads particularly in young patient who may be expected for several box changes in their life time.²⁷ However, there are significant data available regarding modern extraction risk and outcomes for leads of different ages. Therefore, there is another debate going on that whether the lead should be abandoned or the risk of

extraction should be exercised.³⁰ According to them if there are no risks to abandoned leads, then elective extraction never needs to be performed.³⁰ However, if the risks of abandoned leads outweigh the risks of extraction, then the abandoned leads should be removed. Two studies, one from Deckx S et al, one in 2014 and the other from Sideris S. et al in 2015 in literature which show high rates of complications from abandoned pacing leads.^{12, 13} But evidence of some studies goes against this school of thought. The risks of extraction have remained remarkably constant, even as success rates have improved.^{29, 30} It is, therefore, essential that an operator should predict his or her own results and expertise besides modern tools of extraction when performing these operations.³⁰

We think that extraction or box change is an art which should be done in a scientific and rational way. Box change has no alternative but the procedure should be done in way to be made minimally invasive. However the lead integrity must be checked before and during the procedure and all care should be exercised to avoid any damage to the lead during the recovery of box. Though the incision for box change is slightly different from the explanation of the entire assembly and device, one should be prepared for the unexpected, as lead is sometimes intact from every expect on programmer before opening the area but becomes damaged during device recovery and must be replaced. It happened to us in one case the lead was well functioning but the pulse generator was exhausted. We recovered the device and unplugged the lead but due to rust, which is not a documented complication in devices, the lead could not be separated and just a bit more traction badly damaged the lead figure: 2.



Figure 2. Detaching from pulse generator, the Lead damage due to rust inside the socket of device

Therefore, we planned our initial incision in such a way to meet these both requirements. Nonetheless, box

change should never be directly linked with explantation of lead, because every lead is not needed to be pulled or be able to be pulled. But at the same time being predicting pulling difficult we should not leave a nidus for future infection. Therefore we think that before going to procedure the plan should be clear, whether we are just do box change or the lead will need to be extracted. Besides all this, at times despite our all efforts one cannot extract the lead then it should be dealt with in two ways. One, if the risk of infection is low, we cut the lead very distally near the insertion and secure the cut end in the tissue so that there is no future embolization. The other strategy is, if there is any suspicion of infection or future embolization, the surgical team should be involved in any way along with proper protocol against infection. But if the surgical suit is not available at the spot then a temporary wire should be passed and once the lead is pulled out by the surgeon PPM is planned. We think that lead extraction should neither be a provisional approach nor it is cost effective to pull out every lead, rather it should be decided before taking patients to the cath: lab and every case needs to be individualised accordingly.

Conclusion

There is no single rule for lead extraction. Every patient needs to be individualized before a procedure, and then the procedure should be planned accordingly. If the lead is not reusable due to any reason, then every effort should be made to pull it out. On the other hand, if the lead integrity is intact and there is no evidence of any infection, then pulling every lead is not cost effective. However, explantation is a difficult procedure, and it should be planned according to the experience of the operator and available resources.

References

1. Korantzopoulos P, Letsas KP, Liu T, Fragakis N, Efremidis M, Goudevenos JA. Anticoagulation and antiplatelet therapy in implantation of electrophysiological devices. *Europace*. 2011 Dec; 13(12):1669-80.
<https://doi.org/10.1093/europace/eur210>
2. Lin YS, Hung SP, Chen PR, Yang CH, Wo HT, Chang PC, Wang CC, et al. Risk factors influencing complications of cardiac implantable electronic device implantation: infection, pneumothorax and heart perforation: a nationwide population-based cohort study. *Medicine (Baltimore)*. 2014 Dec; 93(27):e213.
<https://doi.org/10.1097/MD.000000000000213>

3. Ribeiro S, Leite L, Oliveira J, Pereira MJ, Pinheiro C, Ermida P, et al. Transvenous removal of cardiac implantable electronic device leads. *Rev Port Cardiol.* 2015 Dec;34(12):739-44. <https://doi.org/10.1016/j.repce.2015.11.002>
4. Pallab Chatterjee, Anuj Kumar Sharma, Pranay Pratap, Ajay Dabas, Bharat Mishra, and Samiksha Mehare Salvage of Infected Cardiac Implantable Electrical Devices with Subpectoral Plane Pocket Revision *Indian J Plast Surg.* 2021 Sep; 54(3): 344-349. <https://doi.org/10.1055/s-0041-1735417>
5. Shah B, Awan ZA, Khan ZA. Lead erosion in permanent pacemaker: a cumbersome complication. *J Ayub Med Coll Abbottabad.* 2014 Apr-Jun;26(2):174-7
6. Bhattacharyya PJ, Agrawal S, Barkatky JC, Bhattacharyya AK. Medial subclavicular musculotendinous complex and insulation break: Rare cause of late pacemaker lead malfunction. *Indian Heart J.* 2015 Dec;67 Suppl 3:S89-91. <https://doi.org/10.1016/j.ihj.2015.07.008>
7. Kusumoto F M, Schoenfeld M H, Wilkoff B L. 2017 HRS expert consensus statement on cardiovascular implantable electronic device lead management and extraction. *Heart Rhythm.* 2017;14(12):e503-e551. <https://doi.org/10.1016/j.hrthm.2017.09.001>
8. Azevedo AI, Primo J, Gonçalves H, Oliveira M, Adão L, et al. Lead Extraction of Cardiac Rhythm Devices: A Report of a Single-Center Experience. *Front Cardiovasc Med.* 2017 Apr 13;4:18 <https://doi.org/10.3389/fcvm.2017.00018>
9. Bharat V. Redo surgery after permanent pacemaker implantation: performance indicator of surgical techniques and pacing technology. *Indian Heart J.* 2004 Jan-Feb; 56(1):40-3.
10. Sideris S, Kasiakogias A, Pirounaki M, Gatzoulis K, Sotiropoulos I, Dilaveris P, et al. Transvenous extraction of cardiac rhythm device leads: a report of the experience from a single referral centre in Greece. *Hellenic J Cardiol* 2015; 56:55-60.
11. Deckx S, Marynissen T, Rega F, Ector J, Nuyens D, Heidebuchel H, et al. Predictors of 30-day and 1-year mortality after transvenous lead extraction: a single-centre experience. *Europace* (2014) 16:1218-25 <https://doi.org/10.1093/europace/eut410>
12. Gutiérrez Carretero E, Arana Rueda E, Lomas Cabezas J M. Infections in cardiac implantable electronic devices: diagnosis and management in a referral center. *Rev Esp Cardiol (Engl Ed.* 2017;70(05):355-362. <https://doi.org/10.1016/j.recesp.2016.09.016>
13. Bohm A, Pinter A, Duray G, Lehoczy D, Dudas G, Tomcsanyi I, Preda I. Complications due to abandoned noninfected pacemaker leads. *Pacing Clin Electrophysiol.* 2001; 24:1721-1724. <https://doi.org/10.1046/j.1460-9592.2001.01721.x>
14. Minale C, Bardos P, Bisping HJ, et al: Improved technique in permanent atrial pacing. *Thorac Cardiovasc Surg* 1980; 28: 433-435. <https://doi.org/10.1055/s-2007-1022446>
15. Jung C Y, Kim T G, Kim S E, Chung K J, Lee J H, Kim Y H. Safe and simplified salvage technique for exposed implantable cardiac electronic devices under local anesthesia. *Arch Plast Surg.* 2017;44(01):42-47. <https://doi.org/10.5999/aps.2017.44.1.42>
16. Karagoz T, Celiker A, Hallioglu O, et al: Unusual extraction of an active fixation ventricular pacing lead with outer coil fracture in a child. *Europace* 2003; 5: 185-187. <https://doi.org/10.1053/eupc.2002.0293>
17. Kristiansen H, Hovstad T, Vollan G, Faerstrand S. Right ventricular pacing and sensing function in high posterior septal and apical lead placement in cardiac resynchronization therapy. *Indian Pacing Electrophysiol J.* 2012;12(1):4-14. [https://doi.org/10.1016/S0972-6292\(16\)30458-2](https://doi.org/10.1016/S0972-6292(16)30458-2)
18. Durante-Mangoni E, Mattucci I, Agrusta F, Tripodi M F, Utili R. Current trends in the management of cardiac implantable electronic device (CIED) infections. *Intern Emerg Med.* 2013;8(06):465-476. <https://doi.org/10.1007/s11739-012-0797-6>
19. Gutiérrez Carretero E, Arana Rueda E, Lomas Cabezas J M. Infections in cardiac implantable electronic devices: diagnosis and management in a referral center. *Rev Esp Cardiol (Engl Ed.* 2017;70(05):355-362. <https://doi.org/10.1016/j.recesp.2016.09.016>
20. Liu L, Tang J, Peng H, Wu S, Lin C, Chen D, et al A long-term, prospective, cohort study on the performance of right ventricular pacing leads: comparison of active-fixation with passive-fixation leads. *Sci Rep.* 2015 Jan 7;5:7662. <https://doi.org/10.1038/srep07662>
21. Sandoe JA, Barlow G, Chambers JB, Gammage M, Guleri A, Howard P, Olson E, Perry JD, Prendergast BD, Spry MJ, Steeds RP, Tayebjee MH, Watkin R; British Society for Antimicrobial Chemotherapy; British Heart Rhythm Society; British Cardiovascular Society; British Heart Valve Society; British Society for Echocardiography. Guidelines for the diagnosis, prevention and management of implantable cardiac electronic device infection. Report of a joint Working Party project on behalf of the British Society for Antimicrobial Chemotherapy (BSAC, host organization), British Heart Rhythm Society (BHRS), British Cardiovascular Society (BCS), British Heart Valve Society (BHVS) and British Society for

- Echocardiography (BSE). *J Antimicrob Chemother.* 2015 Feb;70(2):325-59. doi: 10.1093/jac/dku383. Epub 2014 Oct 29. PMID: 25355810. <https://doi.org/10.1093/jac/dku383>
22. Brodbeck WG, MacEwan M, Colton E, Meyerson H, Anderson JM. Lymphocytes and the foreign body response: Lymphocyte enhancement of macrophage adhesion and fusion. *J Biomed Mater Res (Part A)* August 2005; 74A(2):222-229. <https://doi.org/10.1002/jbm.a.30313>
 23. Sideris S, Kasiakogias A, Pirounaki M, Gatzoulis K, Sotiropoulos I, Dilaveris P, et al. Transvenous extraction of cardiac rhythm device leads: a report of the experience from a single referral centre in Greece. *Hellenic J Cardiol.* 2015; 56:55-60.
 24. Trigano AJ, Taramasco V, Paganelli F, Gerard R & Levy S. Incidence of perforation and other mechanical complications during dual active fixation. *Pacing Clin Electrophysiol* 1996; 19: 1828-1831. <https://doi.org/10.1111/j.1540-8159.1996.tb03234.x>
 25. Mendenhall GS, Saba S. Prophylactic lead extraction at implantable cardioverter-defibrillator generator change. *Circ Arrhythm Electrophysiol.* 2014 Apr;7(2):330-6. <https://doi.org/10.1161/CIRCEP.113.001151>
 26. Smith MC, Love CJ. Extraction of transvenous pacing and ICD leads. *Pacing Clin Electrophysiol.* 2008;31:736-752. <https://doi.org/10.1111/j.1540-8159.2008.01079.x>
 27. Wilkoff BL, Byrd CL, Love CJ, Hayes DL, Sellers TD, Schaerf R, Reiser C, et al. Pacemaker lead extraction with the laser sheath: results of the pacing lead extraction with the excimer sheath (PLEXES) trial. *J Am Coll Cardiol.* 1999; 33:1671-1676. [https://doi.org/10.1016/S0735-1097\(99\)00074-1](https://doi.org/10.1016/S0735-1097(99)00074-1)
 28. Byrd CL, Wilkoff BL, Love CJ, Sellers TD, Reiser C. Clinical study of the laser sheath for lead extraction: the total experience in the United States. *Pacing Clin Electrophysiol.* 2002; 25:804-808. <https://doi.org/10.1046/j.1460-9592.2002.t01-1-00804.x>
 29. Wazni O, Epstein LM, Carrillo RG, Love C, Adler SW, Riggio DW, et al. Lead extraction in the contemporary setting: the LEXIcon study: an observational retrospective study of consecutive laser lead extractions. *J Am Coll Cardiol.* 2010; 55: 579-586. <https://doi.org/10.1016/j.jacc.2009.08.070>
 30. Henrikson CA, Maytin M, Epstein LM. Think before you pull--not every lead has to come out. *Circ Arrhythm Electrophysiol.* 2010 Aug;3(4):409-12 <https://doi.org/10.1161/CIRCEP.110.952242>